

Effect of low intensity pulsed ultrasound on orthodontically induced root resorption caused by  
torque: A prospective double blinded controlled clinical trial

By  
Hasnain Raza

A thesis submitted in partial fulfilment of the requirements for the degree of

Master of Science  
In  
Medical Sciences- Oral Biology

University of Alberta

©Hasnain Raza 2015

## ABSTRACT

Orthodontically induced root resorption (OIIRR) is an undesirable consequence of orthodontic treatment and may lead to permanent loss of root structure. A previous clinical trial demonstrated the effect of LIPUS on tipping type of OTM and reported that LIPUS can promote cementogenesis. However, the effect of LIPUS on other types of OTM still remains unclear. Therefore, the aim of this study was to evaluate the effects of LIPUS on OIIRR caused by torque in human subjects. The study sample consisted of 10 healthy human patients between the ages of 12-35 years at the start of the study who required extraction of all first premolars as a part of their routine orthodontic treatment plan. A 15 degree twist was applied in the arch wire using 0.019 x 0.025 TMA wire producing a torque (buccal root) at the bracket level of approximately 5 N-mm. Using a split mouth design, randomization and blinding, one side of the arch received LIPUS for twenty minutes per day for four weeks at an incident intensity of 30mW/cm<sup>2</sup> of the transducers surface area. The other side served as a self-control which received a sham transducer. After 4 weeks, all first premolars were extracted for regular orthodontic treatment and a micro-CT analysis was performed of these extracted teeth. Comparison between the two groups was performed using Linear mixed model analysis. LIPUS treated teeth showed significantly less damage compared to control as LIPUS reduced the total volume of resorption lacunae by a mean difference of (0.537 +/- 0.092 mm<sup>3</sup>) (P<0.001) and percentage of root resorption by a mean difference of (0.33 +/- 0.05) (P<0.001). Also, significantly less number of resorption lacunae were found on all root surfaces in LIPUS group compared to control except for the distal surface. LIPUS significantly reduced the number of RL at the apical third and middle third of the root. This reduction in the severity of OIIRR can be clinically significant considering

more extensive OIIRR which occurs during the entire course of orthodontic treatment. However, future long term studies are required to determine the efficacy of LIPUS in reducing the severity of OIIRR to a clinical significant level over an extended period of time, as during regular orthodontic treatment.

**Key words:** Orthodontic root resorption, torque, Low intensity pulsed ultrasound, LIPUS,

## **PREFACE**

This thesis is an original work by Hasnain Raza. The research project, of which this thesis is a part, received research ethics approval from the University of Alberta Research Ethics Board, Project Name “orthodontically induced root resorption”, No. MS14\_Pro 00001454\_REN7, 9<sup>th</sup> April 2015 (approval renewal date).

## **ACKNOWLEDGEMENTS**

Thanks to my supervisor (Tarek El-Bialy) and the rest of my committee members (Paul Major, Douglas Dederich). Thanks to Harmanpreet Kaur, Yuchin Wu, Saleh Al Daghreer and Imran Khan for helping me in using Sky Scan software and Sung Hyun Kang who helped me statistics.

## TABLE OF CONTENTS

### CHAPTER 1: INTRODUCTION

1.1	Statement of problem.....	2
1.2	Literature review.....	4
1.2.1	Definition and molecular biology.....	4
1.2.2	Theories of orthodontic tooth movement.....	6
1.2.3	Types of cementum.....	7
1.2.4	Healing of orthodontically induced root resorption.....	7
1.2.5	Diagnosis and prevalence.....	8
1.2.6	Etiology.....	10
1.2.7	Orthodontically induced root resorption and torque.....	11
1.2.8	Treatment option and challenges.....	12
1.2.9	Low intensity pulsed ultrasound.....	17
1.2.9.1	Hypothetical mechanism of action.....	18
1.2.9.2	Application in Medicine and Dentistry.....	19
1.2.10	Ultrasound and orthodontically induced root resorption.....	20
1.3	Objectives and hypothesis.....	25

<b>CHAPTER 2: MATERIALS AND METHODS.....</b>	<b>26</b>
2.1 Ethics approval.....	27
2.2 Study sample.....	27
2.2.1 Sample size calculation.....	27
2.2.2 Inclusion criteria.....	28
2.3 Experimental design and treatment mechanics.....	28
2.4 Blinding and randomization.....	31
2.5 LIPUS application.....	32
2.6 Sample preservation for micro-CT.....	33
2.7 image reconstruction for micro-CT.....	34
2.8 Analysis of reconstructed images of micro-CT.....	34
2.9 Intra-rater reliability measurements.....	36
2.10 Statistical analysis.....	36
<b>CHAPTER 3: RESULTS.....</b>	<b>37</b>
3.1 Intra-rater reliability measurements.....	38
3.2 Root resorption.....	38
<b>CHAPTER 4: DISCUSSION.....</b>	<b>49</b>

REFERENCES.....	61
-----------------	----



## LIST OF TABLE

<b>2.1</b> Results of Torque calibration measurements performed in the biomechanics lab.....	30
<b>3.1</b> Comparison of root resorption measured variables between LIPUS and control along with statistical analysis results.....	44
<b>3.2</b> The mean number of resorption lacunae at each level/third of the root.....	45
<b>3.3</b> comparison of resorption lacunae count at each level of the root in between LIPUS and control group.....	45
<b>3.4</b> Comparison of outcomes of root resorption measured variables between the upper and Lower teeth in LIPUS group.....	46
<b>3.5</b> Comparison of outcomes of root resorption measured variables between the upper and Lower teeth in control group.....	47
<b>3.6</b> Details of individual patients in the study.....	48

## LIST OF FIGURES

2.1 Biology of tooth movement.....	4
2.2 Intraoral pictures of the patient showing orthodontic appliances and arch wire.....	29
2.3 Biomechanics of torque application.....	29
2.4 Torque calibration measurements performed in the biomechanics lab.....	31
2.5 Micro-CT image showing the tooth with cemento enamel junction.....	34
2.6 Micro-CT image showing the measurement of deepest point of resorption lacunae.....	35
3.1 Three dimensional illustration of the micro-CT image of the mandibular premolar showing Root resorption caters.....	40
3.2 Bar graph of total volume of RL (mm <sup>3</sup> ) in LIPUS and control group.....	41
3.3 Bar graph of percentage of tooth root resorbed in LIPUS and control group.....	41
3.4 Bar graph of RL count on different root surfaces in LIPUS and control group.....	42
3.5 Bar graph of height and depth of RL (mm) in LIPUS and control group .....	42
3.6 Bar chart of RL count at different level/third of the root.....	43
3.7 Bar chart of RL count at different level/third of the root in LIPUS and control group.....	43
4.1: CBCT images of two patient replicating the clinical ultrasound application.....	53

## **LIST OF ABBREVIATIONS**

**ALP:** alkaline phosphatase.

**BMP:** Bone morphogenic protein.

**CBCT:** cone beam computed tomography

**CEJ:** cemento enamel junction

**COL-I:** Collagen type-I.

**CS:** Corticosteroids

**DMP:** Dentin matrix protein.

**DPP:** Dentin Phosphophyren.

**DSP:** Dentin Sialoprotein.

**DSPP:** Dentin Sialophosphoprotein.

**EARR:** External apical root resorption.

**ECM:** Extra cellular matrix

**FAK:** Focal adhesion kinase

**GCF:** Gingival cervical fluid

**H & E:** Hematoxylin and Eosin.

**HEBP:** Hydroxy ethylidene bisphosphonate

**hsp:** Heat shock protein.

**Hz:** Hertz

**ICC:** Intra-class correlation coefficient.

**LED:** light emitting diode

**LLLT:** Low level laser therapy

**IL-** : Interleukin.

**LIPUS:** Low Intensity Pulsed Ultrasound.

**MAPK:** Mitogen activated protein kinase

**M-CSF:** Macrophage colony stimulating factor.

**MMP:** Metalloproteases

**mRNA:** Messenger Ribo Nucleic Acid

**OIIRR:** Orthodontically induced inflammatory root resorption.

**OPG:** Osteo-protegrin.

**OPN:** Osteopontin.

**PDL:** Periodontal ligament.

**PG:** Prostaglandin

**PTH:** Parathyroid hormone.

**RANKL:** Receptor activator nuclear- $\kappa$  ligand.

**RGD:** Arginine Glycine Aspartic acid

**RL:** Resorption lacunae.

**ROI:** Region of interest

**RR:** Root resorption

**RT-PCR:** Real time polymerase chain reaction.

**TGF:** Transforming growth factor.

**TNF:** Tumor necrosis factor.

**TNF-R:** Tumor necrosis receptor family.

**TRAP:** Tartrate resistant acid phosphatase.

**TVRL:** Total volume of resorption lacunae

**VEGF:** Vascular endothelial growth factor.

**W:** Watt.

**μ-CT:** Micro-computed tomography.

## CHAPTER 1: INTRODUCTION

---

## **1.1 Statement of problem**

Orthodontically induced root resorption (OIIRR) is an unavoidable consequence of orthodontic treatment and may lead to permanent loss of root structure. The prevalence of OIIRR is high. OIIRR has been reported as the second most common type of root resorption (RR) after pulpal infection related root resorption(1). Histological studies have reported the incidence of OIIRR to be greater than 90%(2). A study which evaluated OIIRR by cone beam computed tomography (CBCT) showed that the clinical prevalence of minor to severe OIIRR ranges from 94% to 6.6% respectively(3). It was reported that 6.6% of the patients who underwent orthodontic treatment had at least one tooth with OIIRR greater than 4 mm in length(3).

Several risk factors have been proposed for OIIRR which include genetic predisposition, individual's biologic variability and treatment mechanics. It has been widely associated with the type of orthodontic tooth movement and magnitude of applied force per unit area(4). Torque force induces bucco-lingual or facio-lingual rotation of the tooth and is measured by the relative crown and root inclination perpendicular to the line of occlusion(5). Proper tooth long axis angulation relative to the occlusal plane have a great significance in dental esthetics and is considered to have a substantial impact on stability of an ideal occlusal relationship in orthodontic treatment(5). Torque has been identified as one of the major risk factor for root resorption(4)(6), particularly the lingual root torque, in which the root apices are moved against the lingual cortical plate(6).

Several studies have been performed to explore potential treatment for OIIRR(7)(8)(9)(10) but no clinically acceptable modality have been established except for low intensity pulsed

ultrasound (LIPUS)(11). Previous studies investigating the effects of LIPUS on OIIRR have reported that LIPUS cannot only prevent OIIRR but can also promote cementum regeneration and repair(11)(12)(13) (14). The only clinical trial which evaluated the effects of LIPUS on OIIRR was performed by El-Bialy et al(11). They used a small sample of female patients subjected to tipping type orthodontic tooth movement and reported that LIPUS therapy was not only effective in significantly reducing the severity of root resorption caused by tipping but it also promoted cementum regeneration and repair(11).

The effect on LIPUS on other types of orthodontic tooth movement still remains unclear. Also El-Bialy et al(11) studied RR by scanning electron microscopy which provides a two dimensional picture of the resorption caters. Based on these findings, the present clinical trial is aimed to determine the possible inhibitory effects of LIPUS on orthodontically induced root resorption caused by torque OTM by using micro computed tomography.



## 1.2 Literature review

### 1.2.1 Definition and molecular biology:

Orthodontically induced inflammatory root resorption (OIIRR) is a side effect related to the biological tissue response to orthodontic tooth movement. When an orthodontic force is applied on a tooth, it compresses the periodontal ligaments (PDL) in the direction of force and produce tension on the opposite side. This initiates a localized inflammation in the surrounding periodontium and enables the tooth to move in the direction of force. This type of inflammatory process which occurs due to mechanical loading of tooth is an unavoidable consequence of orthodontic treatment and may lead to permanent loss of root structure.

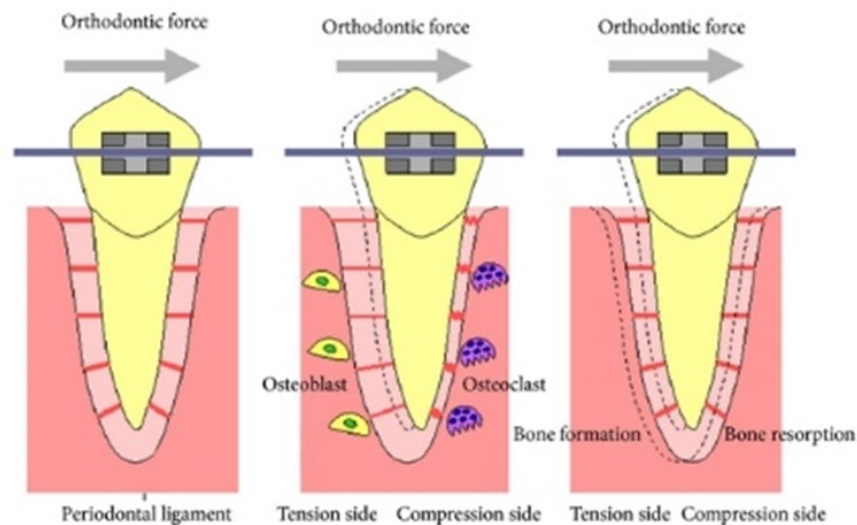


Fig 1: Diagrammatic representation of biology of tooth movement; arrows indicate the direction of force application and tooth movement.

OIRR is a consequence of hyalinised zone elimination process(15). Primary cells involved in the elimination of necrotic tissue formed as result of mechanical loading during orthodontic tooth movement are tartrate resistant acid phosphate (TRAP) negative macrophage like cells(16). Macrophages are phagocytic blood cells and their work is to remove the necrotic tissue. Recently it has been reported that alteration of M1/M2 macrophage ratio can also effect OIRR(17). Macrophages are divided into two distinct phenotypes in vitro, M1 and M2(18), where M1 promotes inflammation by producing large amounts of pro inflammatory cytokines such as tumor necrosis factor  $\alpha$  (TNF $\alpha$ )(19) and M2 inhibit inflammation by producing interleukin 10 (IL-10)(20). In addition to macrophages, odontoclast cells and osteoclast cells have also been found involved in elimination of necrotic tissue(21). These cells are primarily responsible for resorption of mineralized tissue during orthodontic tooth movement and are cytochemically similar to each other, secreting TRAP, Cathepsin-K and MMP-9(22). Cathepsin-K is a cysteine proteases that is specific for osteoclastic bone matrix solubilisation. MMP-9 is type of metalloproteinases which promotes osteoclastic precursor cell migration from the blood vessels into the bone matrix. The expression of Cathepsin-k and MMP-9 in odontoclast cells is lower than that in osteoclast, thus explaining that dental root suffers less damage during orthodontic tooth movement compared to bone(22). The differentiation and proliferation of odontoclast and osteoclast are influenced by receptor activator of nuclear factor- $\kappa$ B ligand (RANKL)(23), osteoprotegerin (OPG)(24) and pro-inflammatory cytokines like TNF $\alpha$  and interleukin-1Beta (IL-1 $\beta$ )(25). RANKL and OPG are members of TNF protein family and play a significant role in root resorption(26). RANKL promotes osteoclast differentiation whereas OPG inhibits osteoclastogenesis(24).

Elimination of necrotic tissue from the inflamed periodontium can damage the outer protective layer of surrounding root structure which consist of cementoblast cells and cementoid and can lead to root resorption(27). This resorption process continues until all the necrotic tissue has been eliminated and the orthodontic force is either discontinued or decreased below a certain level(28)(29).

### **1.2.2 Theories of orthodontic tooth movement:**

Orthodontic tooth movement is the result of biologic tissue response to an externally applied force. When an orthodontic force is applied on the tooth, it disturbs the physiologic equilibrium of the dento facial complex, resulting in tooth movement in the direction of applied force(30). The classic research about orthodontic tooth movement performed by sandstedt; 1904 (31), Oppenhiem; 1911 (32) and Schwarz; 1932 (33) led to the development of “Pressure tension” hypothesis. They proposed that, when an orthodontic force is applied on the tooth, it compresses the PDL in the direction of force and produces PDL tension on the opposite side. This leads to occlusion of blood vessels in the pressurized zone resulting in decreased cell replication and increased clastic activity. Whereas, on the tension side, the stretch in the PDL leads to increased production of PDL fiber bundles and increased bone formation(31)(32)(33). Bien in 1966(34) proposed the blood flow or fluid dynamic theory for orthodontic tooth movement. He proposed that orthodontic forces compresses the PDL in the direction of force vector. This occludes the blood vessels in these compressed zones which results in their stenosis. The blood vessels beyond the stenosis swells up and forms aneurysms. This allows the blood gasses to escape into the interstitial fluid, thus creating a favorable environment for bone resorption(34). Bassett and Becker in 1962(35) proposed the piezoelectric theory for orthodontic tooth movement.

According to this theory, the applied orthodontic force tends to bend the adjacent alveolar bone. This creates an area of concavity and convexity which are associated with negative charge and positive charges respectively. The negative charge results in bone formation whereas the positive charge results in bone resorption(35).

### **1.2.3 Types of cementum**

Cementum is a specialized mineralized tissue covering the dentin of the root and helps in anchoring the teeth to the surrounding alveolar bone. The composition of cementum is similar to bone except that it is avascular and the organic matrix is largely collagen. Cementum along with the bone and PDL forms a structural unit which plays an important role during orthodontic tooth movement (OTM)(36). Cementum is classified into four different types(37). The Acellular A fibrillar Cementum (AAC) is found only at the cervical region of the tooth at the cemento enamel junction. The Acellular Extrinsic fiber Cementum (AEC) is observed at the coronal third of the root and is mainly responsible for anchoring the teeth in its alveolus. The Cellular Intrinsic fiber Cementum (CIC) is localized at the middle, apical and furcation region of the root and has regenerative potential. The cellular mixed fiber cementum is found mainly in the apical and furcation areas of the root and also plays a role in anchoring the teeth in its alveolus(37).

### **1.2.4 Healing of orthodontically induced root resorption:**

The resorbed root surface starts to heal naturally with the invasion of fibroblast like cells into the active resorption sites from the surrounding PDL(29). The repair process begins as early as first week of retention depending upon the magnitude of applied force(38). Conflicting information exist in the literature regarding the repair process. Some studies indicate that repair process

begins at the periphery of resorption lacunae(29), occur in all directions(39) or start at the center of resorption lacunae and extends towards its periphery(40). At the beginning, new acellular cementum is deposited in the bottom of resorption caters followed by cellular cementum, however, the nature of newly deposited cementum may vary depending upon the magnitude of applied force(40). Some studies suggest that the reparative cementum is principally cellular in nature(41) and some reported that the reparative cementum is a combination of cellular and acellular cementum(40). It is also documented that the amount of reparative cementum formed in the resorption caters is directly proportional with the retention time and inversely proportional with the magnitude of applied force(40).

The reparative process is unable to completely heal the resorption caters even after long retention periods. In one of the study it was reported that after twelve weeks of retention only 62.5% of resorption healing was observed(39). Similar results were reported by another investigator who found that the repair ranges from 28% to 78% after 1 and 8 weeks of retention respectively(38). This can severely affect the overall root structure and can result in root shortening at the end of orthodontic treatment.

#### **1.2.5 Diagnosis and Prevalence:**

OIIRR has been reported as the second most common type of root resorption (RR) after pulpal infection related root resorption(1). Histologically root resorption is classified into: cemental or surface resorption with re modelling, dentinal resorption with repair and circumferential apical root resorption. Histological studies have reported the incidence of OIIRR to be greater than 90%(2).

Clinically, root resorption is graded on a four point scale(42) where 1; irregular root contour, 2; apical root resorption less than 2mm of original root length, 3; apical root resorption from 2 mm to one-third of original root length and 4; apical root resorption greater than one-third of original root length. Several diagnostic tools are available to clinically detect RR including peri-apical radiographs, panoramic radiographs, lateral cephalogram and cone beam computed tomography (CBCT). RR is a three dimensional change in the root structure and conventional two dimensional diagnostic methods cannot provide an accurate estimate of the amount of RR. Several studies have reported that conventional two dimensional radiographs tends to either under estimate or overestimate RR compared to CBCT(43)(44)(45). CBCT provides an accurate three dimensional image of the teeth and is widely used in orthodontic clinics as a diagnostic tool for orthodontic patients. A clinical study which evaluated OIIRR by CBCT reported the incidence of OIIRR to be 94%(3). They was also reported that 6.6% of the patients who underwent orthodontic treatment had at least one tooth with apical root shortening greater than 4 mm of original root length(3). Maxillary incisors are found to be more susceptible to OIIRR than any other teeth in the oral cavity followed by mandibular incisors and first molars(4). A positive correlation was found between OIIRR of maxillary incisors and large pre-treatment of increased overjet as seen in class II division I malocclusion(46)(47)(48).

Micro-CT is an x-ray imaging technology that has been used to visualize mineralized tissue in three dimension and is the current gold standard for the quantification of OIIRR(49). In an ex vivo analysis of orthodontically treated human teeth using micro-CT, Wierzbicki et al(50) found that the number, height, depth and volume of resorption lacunae were significantly greater in the orthodontically treated teeth compared to control(50). Several other investigators have also used

micro-CT to study root resorption caused by different types of orthodontic tooth movement(51)(52)(53).

Apart from clinical radiological methods and micro-CT, diagnosis of OIIRR by the presence of biological markers such as dentin matrix protein 1 (DMP 1), dentin phosphophoryn (DPP) and dentin sialoprotein (DSP) in gingival cervical fluid (GCF) of patients undergoing active orthodontic treatment has shown promising results(54). A significantly higher level of DSP and DPP was observed in patients with severe OIIRR compared to patients with mild OIIRR(54). DSP and DPP are non-collagenous dentin specific matrix protein involved in the mineralization of pre dentin into dentin(55). Whereas, DMP 1 is present in bone as well as in dentin(56) and can be an indicator of bone remodelling rather than OIIRR during orthodontic treatment.

#### **1.2.6 Etiology:**

It is widely accepted that OIIRR effect is multifactorial which results from a combination of individuals biologic variability, genetic predisposition and mechanical factors(4).

Genetics seems to play an important role in determining the severity of RR due to orthodontic treatment. In one of the study, it was reported that the genetic makeup of the patients rather than the treatment received was associated with the severity of RR(57). It has been reported that the allele at IL-1 $\beta$  gene, which is responsible for decreasing the production IL-1 cytokine, can significantly increase the risk of RR(58). On the contrary, in a retrospective study it was found that local factors rather than the genetic factors were responsible for OIIRR in human subjects(59).

Biologic factors are beyond clinicians control and include previous history of RR(60), root proximity to cortical bone(6), reduced root length and thin alveolar bone(61). Previously, it was accepted that teeth with a history of trauma and abnormal root morphology are more prone to RR than healthy teeth, however, recent clinical studies does not support this finding(4).

Mechanical factors or treatment related factors are also considered to play a role in OIIRR(4). There is a limited evidence suggesting that continuous forces tends to produce more OIIRR than discontinuous forces as it allows the resorbed cementum to heal naturally(4). It was found that heavy forces produced more OIIRR than light forces as heavy forces tend to produce resorption lacunae at a faster rate, thus compromising tissue repair(4). Extended duration of orthodontic treatment can also increase the risk of OIIRR(62)(63), although, some investigators do not agree with this finding(64)(65).

#### **1.2.7 Orthodontically induced root resorption and torque:**

There are several different types of orthodontic tooth movement including tipping movement, bodily movement, intrusive movement, extrusive movement, root up righting and rotation. All these tooth movements corresponds to different force magnitudes depending upon the severity of mal-alignment and can cause RR(11)(66)(51)(52)(53).

Torque is defined as the type of force that tends to rotate an object about its axis. In orthodontics, torque refers to third order relationship of a rectangular arch wire in a rectangular bracket slot (67). It is a type of force which induces bucco-lingual or facio-lingual rotation of the tooth and is measured by the relative crown and root inclination perpendicular to the line of occlusion(5). Proper tooth long axis angulation relative to the occlusal plane has a great significance in dental



esthetics and is considered to have a substantial impact on the stability of an ideal occlusal relationship in orthodontic treatment(68). Torque (force couple) has been identified as one of the major risk factor for root resorption(53)(6)(69)(70)(71)(72), particularly, when the roots are moved against the lingual cortical plate(6). It was observed that severe root resorption was 4.5 times more likely if teeth are subjected to torque and 20 times more likely if the root is moved against the lingual cortical plate(6).

### **1.2.8 Treatment options and challenges:**

Several different types of modalities have been tested in order to treat or prevent OIIRR. These include pharmacological and non-pharmacological substances.

Pharmacological agents have long been used in medicine and dentistry, however controversial results exist in the literature regarding their effect on OIIRR. These include corticosteroids (CS), Bisphosphonate, tetracycline (doxycycline), fluoride and thyroxin.

Corticosteroids (CS) are a group of anti-inflammatory drugs used to treated several inflammatory conditions such as asthma, allergy, dermatitis etc. They are known to be immunosuppressant in nature and can also interfere with the normal metabolic process. Numerous side effects of CS have been documented including disturbances of mineralized tissue metabolism and wound healing, increase risk of infection and decreased bone formation and osteoporosis(73). CS have been shown to inhibit the differentiation of pro-osteoblast into osteoblast and can decrease collagen synthesis from mature osteoblasts(74). Controversial data exist in the literature regarding the effect of CS on OIIRR. Ashcraft et al(75) applied active orthodontic tooth movement in rabbits for 14 days and observed increased tooth movement and increased RR in rabbits

treated with 15 mg/kg of cortisone compared to control. Similar results were reported by Verna et al(76) who found greater RR in the rats treated with 8 mg/kg per day of methyl prednisolone compared to control. On the contrary, Ong et al(77) administered 1mg/kg of prednisolone in rats and applied active orthodontic treatment for 14 days and observed decrease RR in the treatment group compared to control. However they did not observe any difference in the amount of tooth movement between the two groups. The effect of CS on OIIRR was found to be dose dependent, however no clinical trial is available to date to confirm its effectiveness on humans.

Bisphosphonates are potent blockers of bone resorption(78). Several different types of bisphosphonates are available to treat patients with metabolic disorders associated with increase bone resorption(79). They are known to have a very high affinity for hydroxyapatite crystals and bone bounded bisphosphonates are thought to play a very important role in inhibiting osteoclastic activity(80). Overwhelming evidence exists suggesting that bisphosphonates inhibits bone resorption by decreasing osteoclast differentiation and proliferation(79)(81)(82)(83). Since odontoclast and osteoclast are cytochemically similar to each other, it is possible that bisphosphonates may also inhibit OIIRR(78)(83) by effecting odontoclast activity. However, contradicting evidence exist in the literature. Igarashi et al(78) in experimental rat model demonstrated the dose dependent effect of tropical bisphosphonates on OIIRR. Using a split mouth design, they divided 53 male rats into 3 groups, each having different concentrations of bisphosphonates; 125, 250 or 500  $\mu\text{mol/L}$ . After 3 weeks of active orthodontic tooth movement they observed significantly less RR on the treatment side compared to control with 500  $\mu\text{mol/L}$  having least amount of RR. However no significant differences were found in the number of odontoclast between the two groups. Moreover they also concluded that bisphosphonates did

not inhibit repair of resorption lacunae(78). Similar results were reported by Igarashi et al(83) who observed less resorption caters in the bisphosphonate group compared to control with the least amount of resorption caters in the teeth with highest concentration of systematic bisphosphonates (0.5 mg P/kg). Moreover, this study also highlighted the inhibitory effect of bisphosphonates on orthodontic tooth movement. The teeth with the highest dose of bisphosphonates (0.5 mg P/KG) did not appear to move much beyond the dimensions of PDL even after 21 day of active treatment(83). On the contrary Alatli et al(84) injected 1-hydroxyethylidene-1-bisphosphonate (HEBP) in rats and observed alteration of the cementum surface. The injected HEBP inhibits formation of acellular extrinsic fiber cementum and delayed formation of cellular mixed fiber cementum thus increasing the susceptibility of the root surface to OIIRR(84).

Tetracycline are a group of broad-spectrum antibiotic used in the treatment of a variety of bacterial infections including periodontitis(85). Apart from its anti-microbial effects, tetracycline also exhibit anti-inflammatory properties by inhibiting metalloproteinases thus preventing collagen degradation(86). Among tetracycline's, doxycycline has shown to be effective in reducing root resorption after a variety of dental procedures including muco-periosteal flap surgery in rats(87) and re-implanted teeth in monkeys(88). Mavragani et al(85) in an experimental rat model demonstrated inhibitory effects of low doses of doxycycline (20 mg/ml) on RR and alveolar bone loss. They observed that the rats treated with doxycycline had less RR and alveolar bone loss compared to non-doxycycline group. Specific side effects of doxycycline include gastrointestinal disturbances and emergence of tetracycline resistant microorganisms(89).

Fluoride is widely used in dentistry due to its anti-cariogenic properties. It changes the molecular structure of mineralized tissue i.e. replaces hydroxyl group of calcium hydroxyapatite crystals and forms calcium fluoroapatite crystals, making it more resistant to acid demineralization (90). It can also inhibit osteoclastic activity by blocking calcium ion release(91) and can also promote bone formation by increasing the number of osteoblast(92). However, high doses of fluoride can cause fluorosis, an irreversible condition characterized by discoloration or pitting of enamel surface(93). Controversial data exist in the literature regarding the effect of fluoride on OIIRR. Some investigators have shown positive effect of fluoride(7)(94), while others did not confirm this positive effect(95)(96). In a clinical trial Ersan et al (97) demonstrated the dose dependent effect of fluoride on OIIRR after 4 weeks of experimental force application. They observed decreased RR in patients with high fluoride (2 ppm) intake and heavy orthodontic force (225 gm.) compared to low fluoride (0.05 ppm) intake and heavy force (225 gm.)(97). However, this effect was not significant after 12 weeks of retention(96). It has been proposed that the effectiveness of fluoride on OIIRR depends upon several factors such as calcium and vitamin D consumption, difference of species, duration of fluoride supply and individual sensitiveness to fluoride(98).

L-thyroxin is a synthetic form of a naturally occurring hormone, the thyroid hormone (T4) secreted by thyroid gland. T4 plays a major role in regulating protein, fat and carbohydrate metabolism. It also influences bone remodeling by regulating the maturation of different cell population involved in bone growth(99). It has been shown that administration of L-thyroxin in rats during 10 days of tooth movement decreased the amount of RR compared to control(100). Similar results were reported by Shirazi et al(101) who found out that increasing doses of L-thyroxin decrease the extent of RR while increasing tooth movement. On the contrary, no

significant differences were found in monocyte production of IL-1 $\beta$  and TNF- $\alpha$  with L-thyroxin compared to control(102).

Non-pharmacological agents have been used for the prevention/treatment of OIIRR and have shown good results.

Low level laser therapy (LLLT) is a type of photobiomodulation therapy and has been used in medicine for more than a decade for its anti-inflammatory and regenerative properties(103). Low level laser with wave length of 600-1000 nm can stimulate the ongoing biological processes in the living tissues by promoting collagen synthesis(8), osteogenic cell proliferation and differentiation(104), and increasing local blood flow(8). It has been shown that LLLT accelerates tooth movement during orthodontic treatment by increasing the response of the surrounding tissues to orthodontic force i.e. inflammatory process(105), however, this effect is still controversial(8). Animal experiments have demonstrated that LLLT can be effective in reducing the severity of OIIRR by decreasing the RANKL/OPG ratio and can also enhance repair by stimulating osteoblast and fibroblast(8)(9). However, the exact mechanism of action is still unclear(8). Systemic effects of LLLT have also been reported indicating that apart from experimental site, it can also effect the untreated side of the studied subject by stimulating the release of growth factor and cytokines in the circulatory system(106).

Light emitting diode (LED) is also a type of photobiomodulation therapy with the wavelength between 630-1000 nm generated by using LED arrays(10). The difference between LLLT and LED is that laser has a characteristic of coherency while LED is not coherent, therefore has fewer side effects(10). The only study which demonstrated the effect LED on orthodontic tooth movement

and OIIRR was performed by Ekizer et al(10). In an experimental rat model they observed significant increase in orthodontic tooth movement and decrease in RR in the experimental group compared to control with no systemic side effects(10).

Echistatin is an arginine-glycine-aspartic acid (RGD) containing peptide known for its anti resorptive effects on mineralized tissue(107). It reduces bone resorption by blocking the attachment of osteoclast cells to the mineralized tissue by interacting with the functional part of the integrin structure and preventing tight seal formation which is essential for the demineralization process(108). Echistatin specifically binds with  $\alpha\beta3$  integrin receptor expressed by osteoclast(109). The only study which evaluated the effect of Echistatin on OIIRR was performed by Talic NF et al(110). In an experimental rat model, they demonstrated that systemically delivered Echistatin can significantly reduce the severity of OIIRR, however, the exact mechanism of action is still unclear(110).

Low level laser therapy, LED mediated photobiomodulation therapy and Echistatin have shown positive effects in reducing RR, however, the number of studies are very limited and no clinical trial is available to establish their effect on humans.

### **1.2.9 Low intensity pulsed ultrasound (LIPUS)**

Ultrasound is an acoustic energy with frequencies above the level of human hearing. It is a form of mechanical energy which can be transmitted into body tissues as high frequency acoustic pressure waves(111). Different intensities of ultrasound have distinct effects on body tissues(112)(113). Therapeutic ultrasound intensity ranges from 30-70 W/cm<sup>2</sup>, operative ultrasound (shock waves) 0.05-27,000 W/cm<sup>2</sup> and diagnostic ultrasound intensity ranges from 5-

50 mW/cm<sup>2</sup> (114). Low intensity pulsed ultrasound also known as LIPUS has gained popularity in the recent years due to its stimulatory effects on body tissues. The most widely used parameters of LIPUS are: pulsed frequency of 1.5 MHz, a signal burst width of 200  $\mu$ s, a signal repetition frequency of 1 kHz and an intensity of 30 mW/cm<sup>2</sup>(114)(115)(116).

#### **1.2.9.1 Hypothetical mechanism of action:**

LIPUS has gained popularity, however, the biologic mechanism involved in LIPUS stimulated tissue repair has not yet been fully discovered(114)(117). While propagating through the living tissues, sound energy is absorbed by the cells at a rate proportional to the density of the tissues(118)(119), and, this absorption results in the conversion of sound energy into mechanical agitation of the molecules in the target cells(120). Based on this phenomenon, it has been proposed that the anabolic effects of LIPUS are most likely due to either mechanical stimuli and/or Acoustic micro streaming (121)(122). It has been proposed that LIPUS interacts with the cell through and an integrin molecule which act as a mechano-receptor on the cell membrane(123)(124). Signals from LIPUS passes through the cell via integrin molecule and results in activation and phosphorylation of focal adhesion kinase (FAK) which initiates signal transduction mechanism(125). Also it can increases tyrosine phosphorylation of several signaling proteins, activation of serine/threonine kinase and alteration in cellular phospholipids and calcium level(126). Also LIPUS stimulation can activate integrin associated signaling pathways, such as the mitogen activated protein kinase (MAPK) pathway(127) and the Rho pathway(128) which are important in different cell functions. The integrin molecule may also function as a bridge between extracellular matrix, cyto-skeleton proteins and actin filaments(129). LIPUS stimulation can also induce cyclooxygenase (COX-2) expression through integrin, integrin linked

kinase and p300 pathway in human chondrocytes resulting in an increased production of prostaglandin E<sub>2</sub> (PE<sub>2</sub>) which plays an important role in bone metabolism(129).

Apart from mechanical stimuli, LIPUS can also induce non-thermal changes in the living tissues which can be cyclic or noncyclic in nature(114). The main non cyclic effect of LIPUS therapy is presumably acoustic micro streaming which alters local cell environment by changing the concentration gradient around the cell membrane(122). This change in the concentration gradient effects the diffusion of ions across the cell membrane thus promoting fluid flow induced circulation and re-distribution of nutrients, oxygen and signalling molecules(130).

Several in vitro and in vivo studies have been conducted to examine the mechanism responsible for LIPUS stimulated effects in living tissues. One of such study demonstrated that ultrasound induce changes in the rates of influx and efflux of potassium ions in rat thymocytes(122). It has also been reported that LIPUS accelerated fracture healing is mediated by intra cellular calcium signalling(131). Also, ultrasound therapy increased transforming growth factor  $\beta$  (TGF  $\beta$ ) by osteoblast and decreased the concentration of interleukin 6 (IL-6) and tumour necrosis factor  $\alpha$  (TNF- $\alpha$ ) thus preventing bone loss(132). Moreover, ultrasound stimulates the release of vascular endothelial growth factor (VEGF) which is associated with endothelial cell proliferation and migration(133).

#### **1.2.9.2 Applications of ultrasound (LIPUS) in Medicine and Dentistry**

LIPUS application has shown to have therapeutic effects on bone remodeling. In vivo studies have demonstrated that LIPUS application can enhance bone regeneration and repair(134), accelerate bone fracture healing(135) and promote osteogenesis at the site of distraction(135). Thus, LIPUS



stimulation is clinically established, widely used, and United states Food and Drug Administration (FDA) has approved LIPUS bone stimulator to accelerate fracture healing(115).

Unlike medicine, ultrasound therapy is relatively new to dentistry and is in use in dental research for just a decade. It has shown to have stimulatory effect on a variety of cells including cementoblast(136), odontoblast like cells(137), osteoblast(134), chondrocytes(138), gingival cells(139)(140) and periodontal ligament cells(141). LIPUS is found to be effective in preventing RR caused by orthodontic tooth movement(11)(14)(12)(13) and tooth re-implantation(142). Also, it improves bone healing during sinus augmentation procedures in humans (143) and mandibular distraction in animals(144)(145). Stimulatory effects of LIPUS on periodontal ligament cells have also been studied. In an in vitro experiment Inubushi et al(136) applied LIPUS on human periodontal ligaments cells (immature cementoblast cells) derived from extracted human pre molars and observed increased differentiation of immature cementoblast and increased Alkaline phosphatase (ALP) activity resulting in the periodontal tissues regeneration and repair(136). Also, LIPUS has found to be effective in promoting periodontal tissue regeneration after injury(146) and surgery(147). Stimulatory effects of LIPUS on odontoblast cells have also been reported(137). In another study it was reported that LIPUS stimulate odontoblast cells to secrete pre-dentin(148)(149)(150). A recent study by El-Bialy et al(151) showed that gingival multi potent cells can be differentiated into neural cells which can be a future technique for dental pulp tissue engineering.

#### **1.2.10 Ultrasound and orthodontically induced root resorption:**

Cementum is a specialized mineralized tissue covering the outer surface of the root and assist in anchoring teeth to the surrounding alveolar bone. Although, the composition of cementum is similar to bone, there are several structural and functional differences between them(136). Unlike bone, cementum has a very limited remodeling potential(152) which can be lost by disease or inflammation(153). Therefore, regeneration of cementum by ultrasound has gained popularity among the clinicians in the recent years. El-Bialy et al(154) in an experimental rabbit model demonstrated that LIPUS application can enhance mandibular growth with continuous incisor eruption and root formation.

Cementoclastogenesis is depended upon the balance between RANKL and OPG levels in cementoblast(155). Increasing RANKL/OPG ratio increases cementoclast activity and vice versa. In an in vitro experiment, Bona et al(156) demonstrated that ultrasound cannot only prevent OIIRR by inhibiting cementoclastogenesis but can also promote cementum regeneration and repair. They observed decrease RANKL/OPG ratio in ultrasound (150 mW/cm<sup>2</sup>) treated cells compared to control, thus decreasing cementoclast activity and subsequent decrease in OIIRR. Also they observed increased number of cementoblast cells after ultrasound (30 mW/cm<sup>2</sup> and 150 mW/cm<sup>2</sup>) exposure compared to control(156). Similar but interesting results were reported by Inubushi et al(14). In an in vitro experiment they demonstrated that LIPUS exposure (30 mW/cm<sup>2</sup>) increased the RANKL mRNA expression levels in cementoblast and osteoblast, however, the OPG mRNA expression levels were only increased in cementoblast, thus, suggesting that LIPUS therapy promotes osteoclastogenesis and prevents cementoclastogenesis(14). Also they observed that after two weeks of experimental force application that the number of odontoclast cells were significantly lower, while the number of osteoclast cells were significantly

higher in LIPUS group ( $150 \text{ mW/cm}^2$ ) compared to control(14). Moreover, they also observed decreased resorption area and increased root thickness in LIPUS ( $150 \text{ mW/cm}^2$ ) compared to control(14). The stimulatory effect of LIPUS on osteoclastic activity was also reported by El-Bialy et al(150). In an in vitro experiment they observed increased osteoclasts within the periodontal ligament in the LIPUS ( $30 \text{ mW/cm}^2$ ) group compared to control suggesting that LIPUS therapy can facilitate orthodontic tooth movement. Also they observed increased cementum and pre-dentin thickness in the LIPUS treated cells compared to control(150).

Alkaline phosphatase (ALP) is a protein found in all body tissues and it escalates the calcification process of mineralized tissue. It is also considered as an early phenotype marker for mature cementoblast(156). Type I collagen (COL-I) is one of the major constituent of bone and extracellular matrix (ECM). Increase in COL-I synthesis is closely associated with development of differentiated and mineralized tissue(157). Runx-2 is an osteoblast specific transcription factor and regulates osteoblast differentiation and gene expression(158). It is assumed that Runx-2 found in human periodontal ligament cells may have the same effect on cementoblast differentiation as it has on osteoblast(136). Inubushi et al(136) in an in vitro experiment demonstrated that expression levels of ALP, COL-I and Runx-2 mRNA significantly increased in LIPUS ( $30 \text{ mW/cm}^2$ ) treated cells compared to control. Moreover, they showed that collagen synthesis, ALP activity and protein levels of Runx-2 increased significantly after LIPUS exposure, thus promoting cementum regeneration and repair(136). Similar results were reported by Bona et al(159) who observed increased expression level of ALP mRNA ( $150 \text{ mW/cm}^2$ ) and increased calcium content ( $100 \text{ mW/cm}^2$  and  $150 \text{ mW/cm}^2$ ) in ultrasound treated cells compared to control. In a short term in vitro experiment, Scheven et al(160) demonstrated the effect of ultrasound on

odontoblast-like cells and observed that the expression of Collagen-I, Osteopontin (OPN), TGF- $\beta$ 1 and heat shock protein (hsp) increased after ultrasound application. An interesting finding of this study was the effect of ultrasound on hsp 25/27, suggesting the role of this protein in response of odontoblasts to ultrasound(160).

Prostaglandin E2 (PGE2) is one of the important signalling molecules produced by cells and their role in regulating bone metabolism has been well established. It is assumed that different effects of PGE2 are explained in part by the activation of different receptors including EP1, EP2, EP3 and EP4(161), where EP2 and EP4 are responsible for mediating bone formation(162). In an in vitro experiment Rego et al (163) observed increased PGE2 formation in LIPUS (30 mW/cm<sup>2</sup>) treated cells compared to control. Also, the gene expression levels of ALP, bone morphogenic protein 2 (BMP-2) and osteopontin (OPN) significantly increased in LIPUS treated group compared to control(163). In addition, LIPUS stimulation upregulated the mRNA expression levels of EP2 and EP4, however, the mRNA expression levels of EP1 and EP3 which were unaffected, thus, suggesting that LIPUS therapy can promote cementoblast differentiation through EP2/EP4 receptor pathway(163).

Apart from in vitro experiments, in vivo studies had also been conducted to evaluate the effect of LIPUS on OIIRR. In a clinical trial, El-Bialy et al(11) demonstrated the stimulatory effect of LIPUS on cementum regeneration and repair. Using a split mouth design, they tipped the premolars facially with an initial force level of 50 gm accompanied with LIPUS therapy (30 mW/cm<sup>2</sup>) on left side whereas the right side was used as a control. LIPUS was applied for 20 min/day for four weeks after which the teeth were extracted and were analyzed. A significant decrease in the number and surface area of resorption lacunae was observed in the LIPUS treated premolars

compared to control. Also LIPUS treated premolars showed significant deposition of new cellular cementum (reparative cementum) compared to control(11).

In an experimental dog model, Al-Daghreer et al(12) observed less root resorption in the LIPUS (30 mW/cm<sup>2</sup>) treated teeth compared to control. They reported that number of resorption lacunae, total volume of resorption lacunae and percentage of tooth root resorption was significantly less in the LIPUS group compared to control. Also, they observed deposits of new cellular cementum on LIPUS treated roots compared to control. Moreover, they also noted that LIPUS treated group exhibited significantly thicker cementum on middle and apical third of the root compared to control. The distribution of osteoclast and odontoclast along the root surfaces were also reported. Significantly higher number of osteoclast cells were found at middle and apical third of the LIPUS treated root compared to control, whereas, the number of odontoclast cells were significantly higher at all the three root levels in control group compared to ultrasound(12), thus, confirming previous findings about the effects of LIPUS on osteoclastogenesis and cementoclastogenesis(14)(15). Similar results were reported by liu et al(13). In an experimental rat model, they observed that the total number and surface area of resorption lacunae was significantly higher in the positive control group (only OTM with no LIPUS) compared to ultrasound (100 and 150 mW/cm<sup>2</sup>). Also, a large amount of new cementum was found in both LIPUS treated groups (100 and 150 mW/cm<sup>2</sup>). Moreover, the RANKL/OPG ratio was significantly lower in ultrasound groups (100 mW/cm<sup>2</sup>) compared to positive control(13).

### **1.3 Objectives and hypothesis**

#### **General objective:**

To determine the effectiveness of LIPUS in preventing orthodontically induced root resorption caused by torque force application in human subjects by using micro computed tomography.

#### **Specific objectives:**

To measure root resorption variables as follows:

- Number of resorption lacunae on each root surface.
- Height of resorption lacunae
- Deepest depth of resorption lacunae
- Total volume of resorption lacunae
- Percentage of tooth root resorbed
- Distribution of resorption lacunae in different levels/thirds of the root.

#### **Applied objective:**

To introduce LIPUS as a potential adjuvant non-invasive modality during application of torque with the aim of preventing its deleterious effects on tooth i.e. preventing root resorption.

#### **General hypothesis**

LIPUS application for 20 min/day when applied during torque application will be effective in reducing the severity of OIIRR caused by torque in human patients.

## CHAPTER 2: MATERIALS AND METHODS

---

## **2.1 Ethical approval**

This clinical trial has been approved by the Health Research Ethics Board (HREB), University of Alberta, Canada (Pro 00001454) and all the study participants signed a written informed consent before the start of the experiment.

## **2.2 Study sample:**

The study participants consisted of 12 healthy individuals, 2 males and 10 females, with the mean age of 15.5 +/- 5.48 years at the beginning of the study. All the study participants completed and signed a written informed consent before the start of the experiment. If the participants were 16 years or under, the parents or guardians were asked to complete and sign the written informed consent on behalf of the study participant. During the experiment, 2 patients (both females) were eliminated due to non-compliance and their data was not considered for analysis as they did not complete two thirds of the experiment. Finally 10 patients, 2 males and 8 females completed the study and their data were analyzed.

### **2.2.1 Sample size calculation:**

The sample size for this study was calculated based on the data published by El-Bialy et al(11).

The sample size for the study was calculated based on the following formula(164):

$$n = \sigma^2 * (Z_{1-\alpha/2} + Z_{1-\beta})^2 / d^2$$

$$n = (120)^2 * (1.96 + 0.84)^2 / (100)^2$$

$$n = 12$$

The sample size for this study was determined to be 12 subjects per group. The statistical significance level and the power of the test were set at 0.05 and 0.80 respectively.



### **2.2.2 Inclusion criteria:**

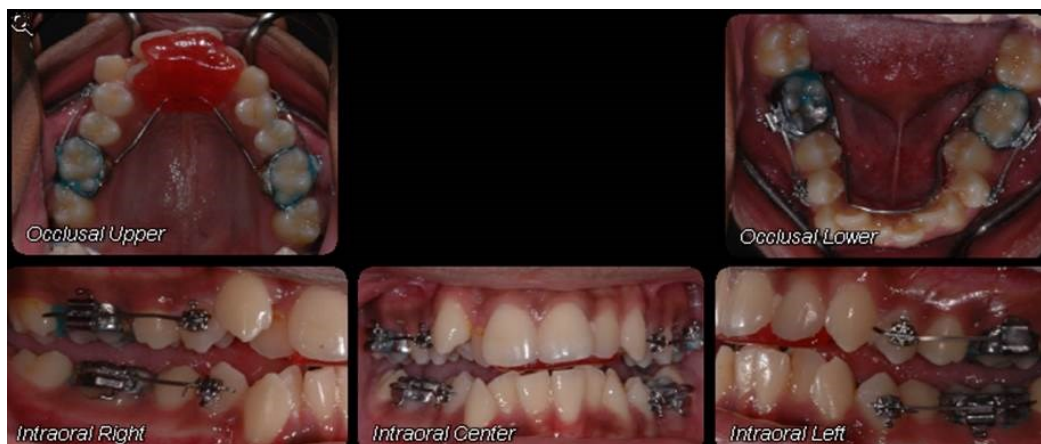The study participants were selected according to a strict criteria: Scheduled to receive orthodontic treatment and extraction of their first maxillary and mandibular premolars of both i.e. right and left side as a part of their routine orthodontic treatment plan, adolescents or adults between the ages of 12-35 years, Apical root development of all the first premolars should be completed, first premolars were sound with no history of trauma/caries or root canal therapy, available for follow-up visits, willing and able to sign a written informed consent, healthy individuals with good oral hygiene and compliance.

### **2.3 Experimental design and treatment mechanics:**

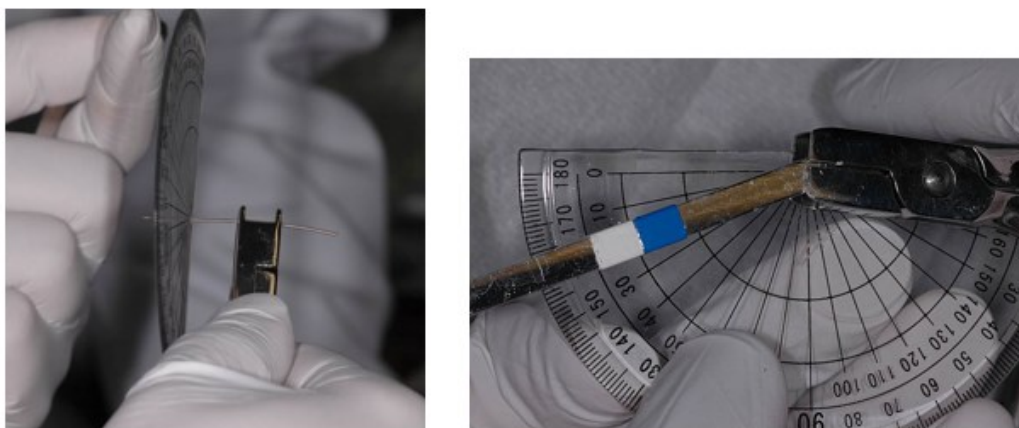
The study design for this clinical trial was a prospective split mouth double blinded controlled clinical trial. The study was conducted at the graduate orthodontic clinic, University of Alberta, Canada.

The patients visited the orthodontic clinic over a period of four weeks which was the length of the clinical trial. At the start of the study, metal bands were fitted on the maxillary and mandibular first permanent molars and an alginate impression was taken and was poured in plaster for fabrication of Nance appliance and lingual arch appliance in order to provide maximum anchorage. After one week, a standardized Nance appliance and a lingual arch appliance was constructed and bonded to the maxillary and mandibular molars respectively with multi cure glass ionomer cement (3M Unitek, Monrovia, California) (fig 2). Brackets (Synergy R, Rocky Mountain Orthodontics, Denver, CL, USA) for the maxillary and mandibular first premolars were bonded on both sides i.e. the right and the left side using “0.021 x 0.025” wires to ensure

that they were at zero torque at the initial bonding. Then, a 15° twist was applied in the arch wire (0.019 x 0.025 TMA, Rocky Mountain Orthodontics, Denver, Colorado, USA) so as to facilitate movement of all the first premolars, producing torque (buccal root torque) at the bracket level of approximately 5 N-mm (fig 3). The torque value was calibrated in the bio-mechanics lab at university of Alberta, Canada (table 1) (fig 4). LIPUS application was started on the same day the orthodontic force was applied and continued for four weeks. LIPUS device was given to the patients with all the instructions.



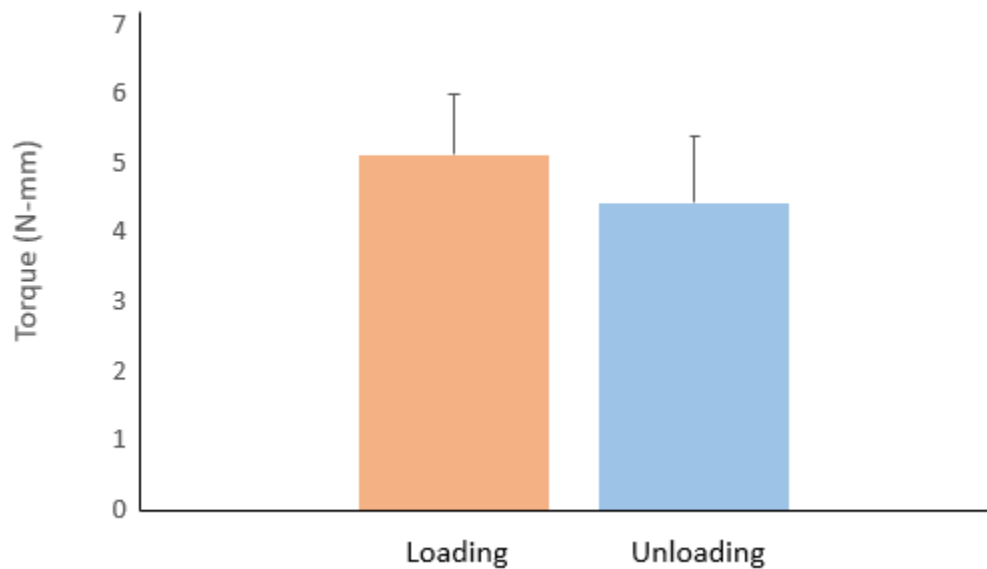
**Fig 2:** Intraoral pictures of the patient showing orthodontic appliances and arch wire



**Fig 3:** Biomechanics of torque application.

**Table 1:** Results of Torque calibration measurements performed in the biomechanics lab

<b>S.no</b>	<b>Degree</b>	<b>Loading</b>	<b>Unloading</b>
1.	15	3.320	3.248
2.	15	3.213	2.779
3.	15	4.202	3.984
4.	15	6.579	6.890
5.	15	11.415	10.291
6.	15	0.401	0.371
7.	15	10.096	10.467
8.	15	5.677	3.605
9.	15	3.891	3.144
10.	15	3.399	0.544
11.	15	0.670	0.344
12.	15	9.215	9.399
13.	15	9.072	8.607
14.	15	2.212	0.935
15.	15	3.694	1.989
<b>Mean</b>	<b>15</b>	<b>5.1371</b>	<b>4.43986</b>



**Fig 4:** Torque calibration measurements (N-mm) (mean +/- SE) performed in the biomechanics lab

## 2.4 Blinding and randomization

Before the start of the study, inactive (placebo) and active LIPUS devices were blinded and coded with subsequent numbers using randomization software and were recorded in a case form. Sealed opaque envelopes containing the treatment configuration (identification of active and non-active sides of device) were provided to the study coordinator. The placebo and active LIPUS devices were indistinguishable in appearance and during function. The clinician, the study coordinator and the patient, all were blinded to the active and control (inactive) sides. The devices were allocated to the patients in the order of their inclusion to the study. The outcome

assessor was also blinded to LIPUS treated and control teeth and the blinding code was not broken until all the data was collected and was analyzed.

## **2.5 LIPUS application**

Each subject in the study received dental LIPUS system configured to apply LIPUS in a split mouth design. Both the upper and lower first premolars on one side of the dental arch were randomly selected to receive LIPUS therapy with torque i.e. the treatment side, while, the other half only received torque with no LIPUS therapy i.e. the control side. The control side, however, received a sham transducer. The clinician, the study coordinator and the patient, all were blinded to which side is active and which side is control (inactive) LIPUS applicator (transducer).

LIPUS was applied to one side of the arch and the other side was used as a self-control. The control side, however, received a sham transducer that was applied without activation of the circuit within the transducer, so that the patients were not aware which side was the experimental and which side was the control. There was no way to visually detect the difference in device configuration in the split mouth design and there was no heat generated on the active side.

Ultrasound was applied for twenty minutes per day, for four weeks by a custom-built ultrasound device that provides adjustable output parameters and long-term operation stability (Smile Sonica Inc., Edmonton, AB, Canada). The LIPUS device was set to generate ultrasound pulses with a repetition rate of 1 KHz. Each pulse had a square envelope with duration of 200 microseconds and a pulse frequency of 1.5 MHz. The ultrasound transducer had an emitting area of 1.56 cm<sup>2</sup> and it generated a temporal average ultrasound power of 47 mW (or a temporal average

ultrasound intensity of 30 mW/cm<sup>2</sup>). The patients were instructed to apply the ultrasound transducer to the first premolars, in the muco-buccal fold (below the gum line). Intra-oral ultrasound gel was used to couple the ultrasound energy between the transducer and the muco-buccal fold. If the transducers were not placed properly in the mouth or gel is not used, the device warned the subject by displaying a message on the screen with advice on correct usage. In addition, once the treatment was activated for each daily use, the device automatically counted 20 minutes and switched off at the end of the 20 minute treatment period.

Before and after the experiment, ultrasound devices were inspected for consistency of electrical waveforms (1 KHz modulation, 200 microseconds pulse duration, and 1.5MHz carrier frequency). This confirmed that LIPUS devices provided steady ultrasound power output and maintained the desired electrical parameters throughout the experiment. The Dental LIPUS Devices were programmed to ensure that only one of the transducers is active/emits ultrasound and the other one was passive (placebo).

After four weeks, the ultrasound devices were collected, orthodontic appliances and wires were removed and all the first premolars were extracted and were placed in an individually marked containers of deionized water(165). Patient compliance was verified by checking the patient daily logs. If necessary, the device time counter was accessed to confirm total usage time.

## **2.6 Sample preservation for micro-CT:**

After four weeks, all the first premolars were extracted and were stored in separate containers of deionized water for one week (Milli Q, Millipore, Bedford, Mass), which was found to be an appropriate storage medium(165). The extracted teeth were prepared for micro-CT scanning

using the same method as described by Bartley et al(53). All the residual periodontal-ligaments and soft-tissue fragments were removed by placing the teeth in an ultrasonic bath for 10 minutes. The extracted teeth were then disinfected in 70% alcohol for 30 minutes and were stored in Milli Q again(53).

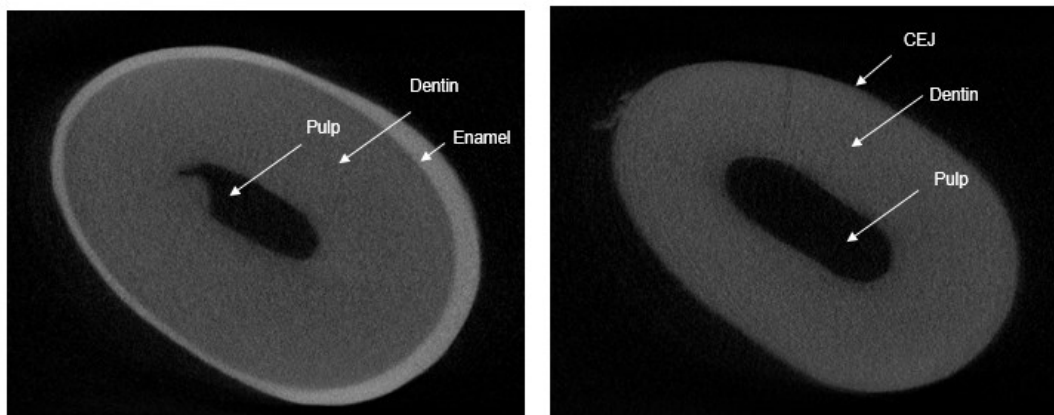
## **2.7 Image reconstruction for micro-CT:**

The extracted tooth samples were air dried for a minimum of 48 hours and scanned in a SkyScan® 1076 micro-CT scanner and associated software (Version 2.6.0) at a resolution of 9µm using an x-ray source potential of 100kV, amperage of 100µA, and power of 10W through 180° with a rotation step of 0.9° at x12 magnification, to produce serial cross-sectional images composed of isotropic 19.4 mm<sup>3</sup> voxel. Finally the images were reconstructed using NRecon© (Version 1.4.4) from SkyScan®. Reconstructed images were analyzed using CT Analyser (Version 1.6.1.0, Skyscan N.V. Kontich, BE).

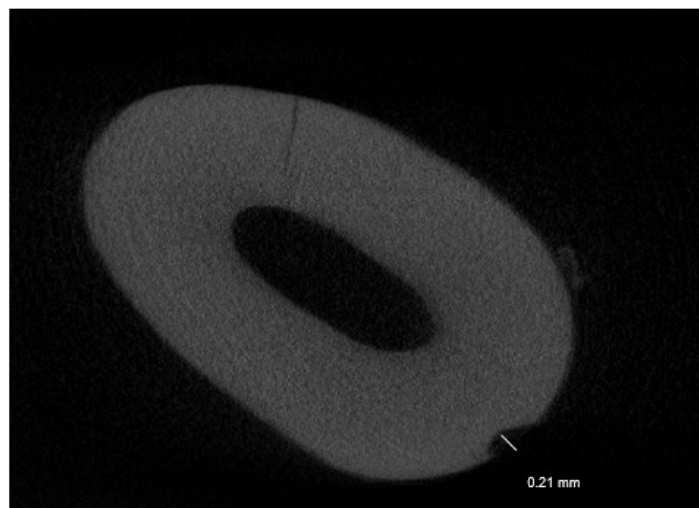
## **2.8 Analysis of the reconstructed images of micro-CT:**

Analysis of the reconstructed images was performed by the same method as described Wierzbicki et al(50). Resorption lacunae (RL) were analyzed over the whole length of the tooth, starting at the cemento-enamel junction (CEJ) and proceeding to the root apex (fig 5). Location and number of resorption lacunae, height of resorption lacunae (amount of slices over which resorption is found) and deepest point of resorption (mm) (fig 6) were measured. The volume of RL was calculated by selecting the surface area of the lacunae with the region of interest (ROI) tool including the estimated root periphery over all the slices the lacunae was present and allowing the algorithm in CT analyser software to calculate the volume. The percentage of tooth root

resorbed was calculated by adding the volume of all RL to the estimated tooth root volume, as determined by the micro-CT software(50). The roots of the teeth were divided into thirds (cervical, middle and apical) to analyze the distribution of resorption lacunae along the entire root length. When all the measurements were completed, the blinding code was broken and the variables were averaged for the ultrasound and control group.



**Fig 5:** Micro-CT image showing the tooth with cemento enamel junction



**Fig 6:** Micro-CT image showing the measurement of deepest point of resorption lacunae



## **2.9 Intra-rater reliability measurements**

All the parameters; number and location of RL, height of RL, deepest point of RL, total volume of RL and percentage of tooth root resorbed, were measured by the same investigator two times with one week interval to test the intra-rater reliability and measurement error.

## **2.10 Statistical analysis:**

The collected data was analyzed using the Statistical package for the Social Sciences software (SPSS version 20) for windows. Data was evaluated at individual level, so that descriptive analysis was performed for each variable by group (Ultrasound vs. Control). Due to split mouth design, the data had matched-pair structure and the data sets were not independent of each other. Also, the data was collected repeatedly from the same subject (or patient) where repeated factor is upper/lower and left/right, and so we had 4 measurements for each subject. As a result, measurements might have had correlated structure within the subject. To deal with outcomes measured on the same subject, we performed a linear mixed model assuming specific covariance (or correlation) structure of outcome variable (e.g., compound symmetry etc.). Intra-rater reliability for all the variables were determined using the intra-class correlation coefficient in the same SPSS software.

## CHAPTER 3: RESULTS

---

### **3.1 Intra-rater reliability measurements**

The intra-rater reliability test results varied among the measured variables where there was an absolute agreement on the number of resorption lacunae on each root surface. The measurement reproducibility of other variables were very high where the ICC values ranged from 0.981 to 0.997. The ICC value for the height of RL was found to be 0.995, for the depth of RL 0.981 and finally for the total volume of RL and the percentage of root resorption, it was calculated to be 0.997.

### **3.2 Root resorption:**

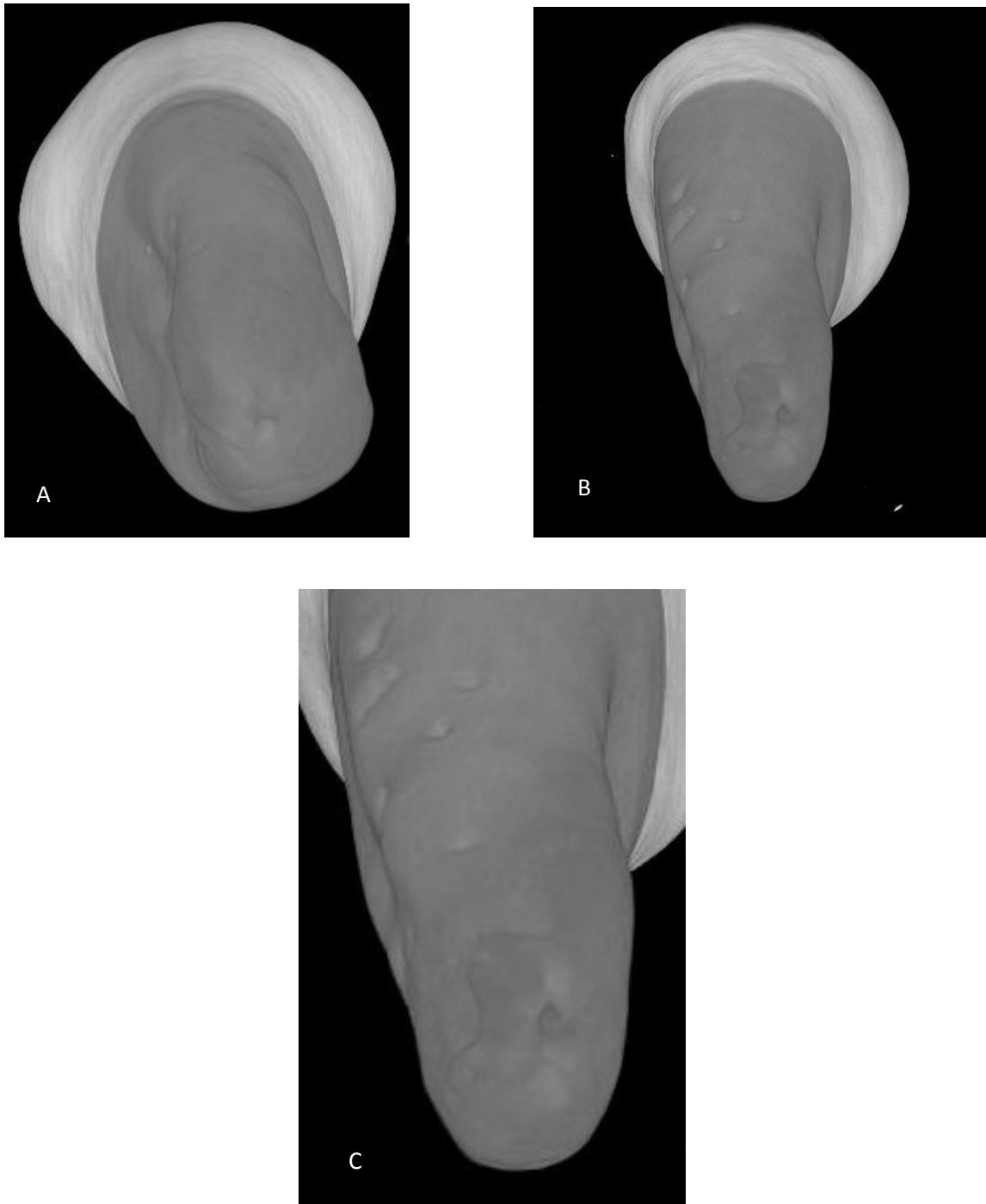
Overall, the result of the study demonstrated that LIPUS treated teeth showed significantly less damage when subjected to torque compared to the control group (Fig 7). The mean RL volume of the LIPUS group was ( $0.481 \pm 0.059 \text{ mm}^3$ ) which was significantly smaller than the control ( $1.019 \pm 0.092 \text{ mm}^3$ ) ( $P < 0.001$ ) (fig 8) (Table 2). Also, the mean percentage of root resorption of the LIPUS group ( $0.214 \pm 0.02$ ) was significantly smaller than the control ( $0.546 \pm 0.067$ ) ( $P < 0.001$ ) (fig 9) (Table 2).

The RL count showed that LIPUS treated teeth had less number of mean RL on all root surfaces compared to control (Fig 10) (Table 2). LIPUS treated teeth had significantly less number of RL on buccal surface by a mean difference of ( $2.789 \pm 0.88$ ), on mesial surface ( $3.0 \pm 0.83$ ) and on palatal/lingual surface by a mean difference of ( $2.3 \pm 0.89$ ) ( $P < 0.05$ ). As for the distribution of RL, the pattern was similar between both the groups. All root surfaces had approximately the same mean number of RL in each group (LIPUS and control group) with buccal surface having slightly higher count compared to mesial, distal and palatal/lingual surface (Fig 10) (Table 2).

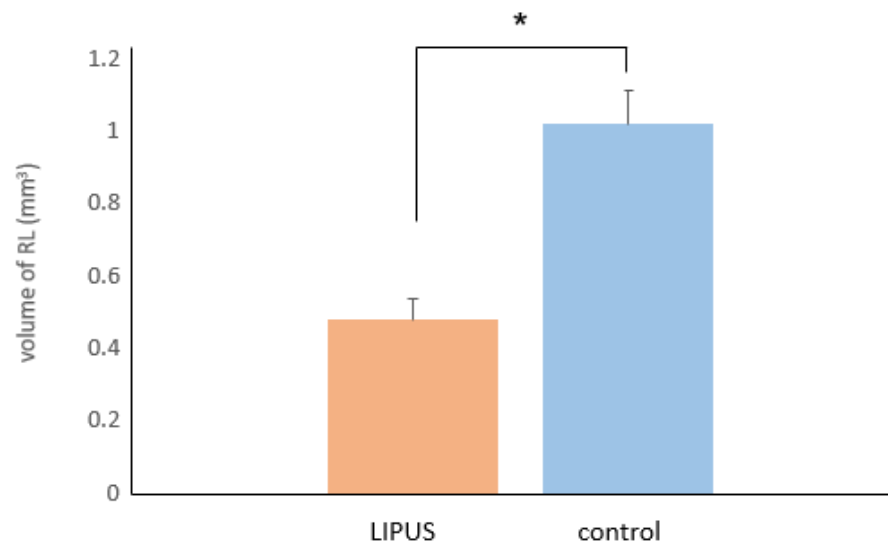
The values for the corono-apical height and depth of RL were also found to be significantly different between the two groups with a mean difference of (0.22 +/- 0.05 mm) and (0.016 +/- 0.006 mm) respectively (fig 11) (table 2) ( $P < 0.05$ ).

When the results were separated and analyzed by thirds, more root resorption was observed at the apical region than at other levels of the root (fig 12, 13) (table 3 and 4). The apical region had the highest mean number of RL (16.68 +/- 0.818) followed by middle third (8.15 +/- 0.829) and cervical third (4.38 +/- 0.38) (Fig 12) (Table 3). LIPUS significantly reduced the number of RL at the apical level and middle level of the root compared to control (Fig 13) (Table 4) ( $P < 0.05$ ). However, no significant differences were found in the number of RL at the cervical level in between the LIPUS and control group (Fig 13) (Table 4) ( $P > 0.05$ ).

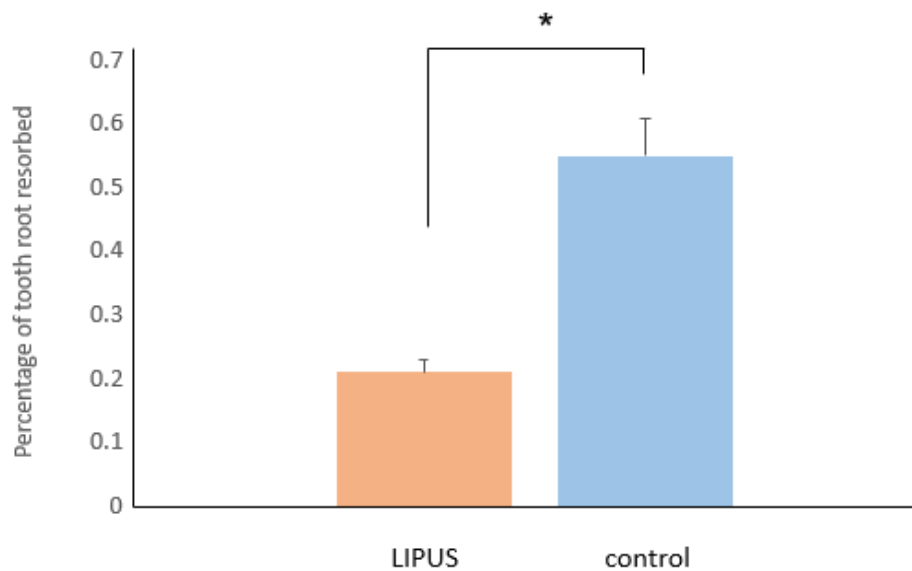
No significant differences were found in the severity of OIIRR between the upper and the lower teeth in both the groups ( $P > 0.05$ ) (table 5 and 6). We were unable to evaluate the effect of torque on difference age groups due to fairly small number of study participants. And for the variable of gender, it was not possible to compare because the study sample consisted of 2 males and 8 females.



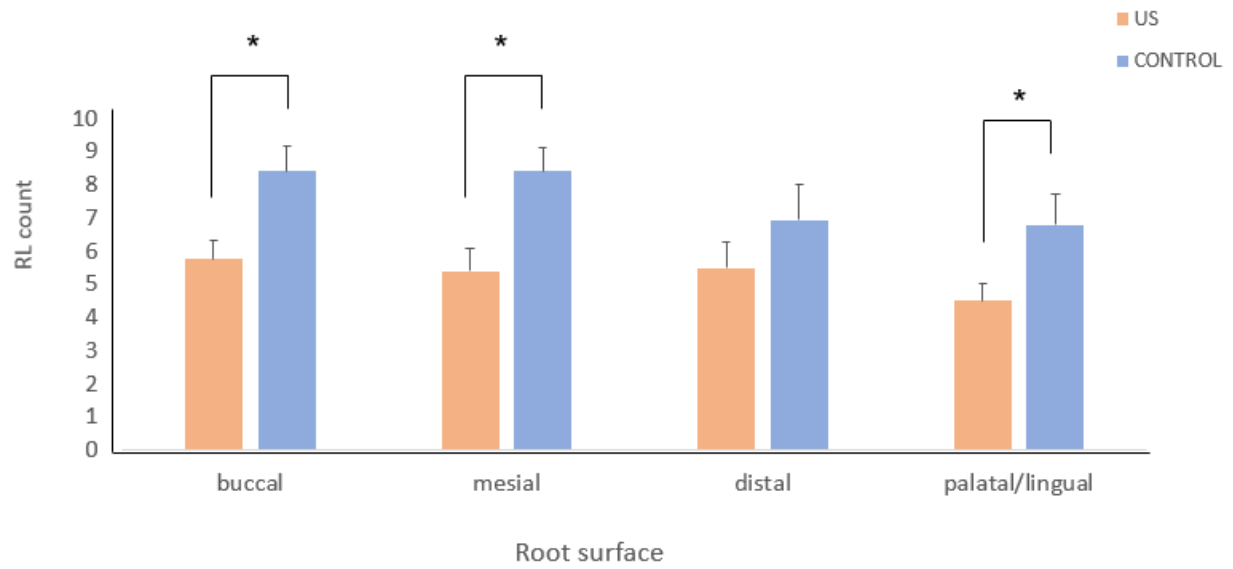
**Fig 7:** Three dimensional illustration of the micro-CT image of the mandibular premolar showing root resorption caters **(A)** LIPUS treated premolar **(B)** Control premolar **(C)** Root resorption crater in detail



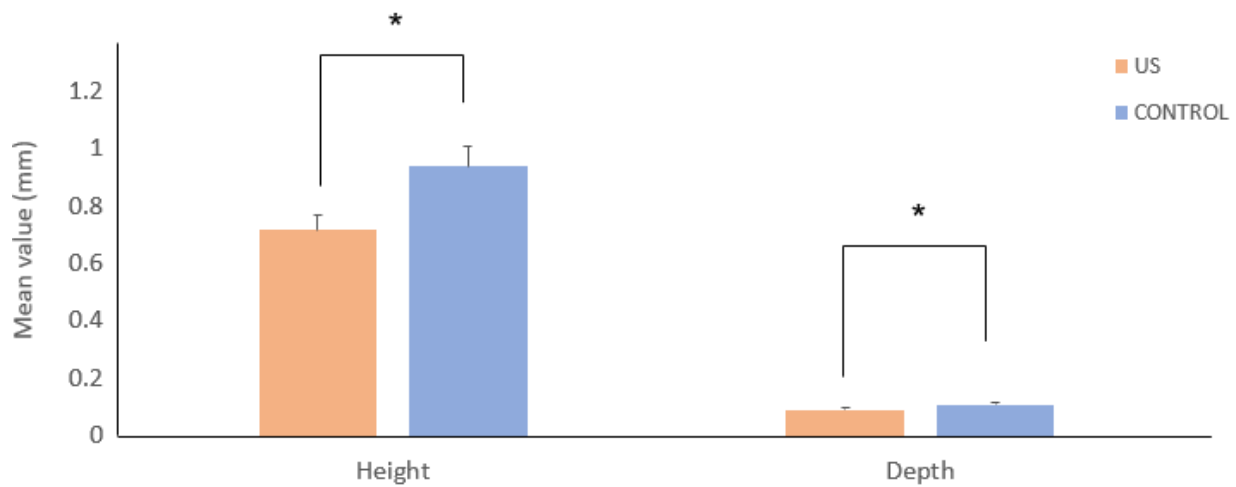
**Fig 8:** Micro-CT analysis of Total volume of RL (mm<sup>3</sup>) (mean  $\pm$  SE) in LIPUS and control group  
(\*= $p < 0.05$ )



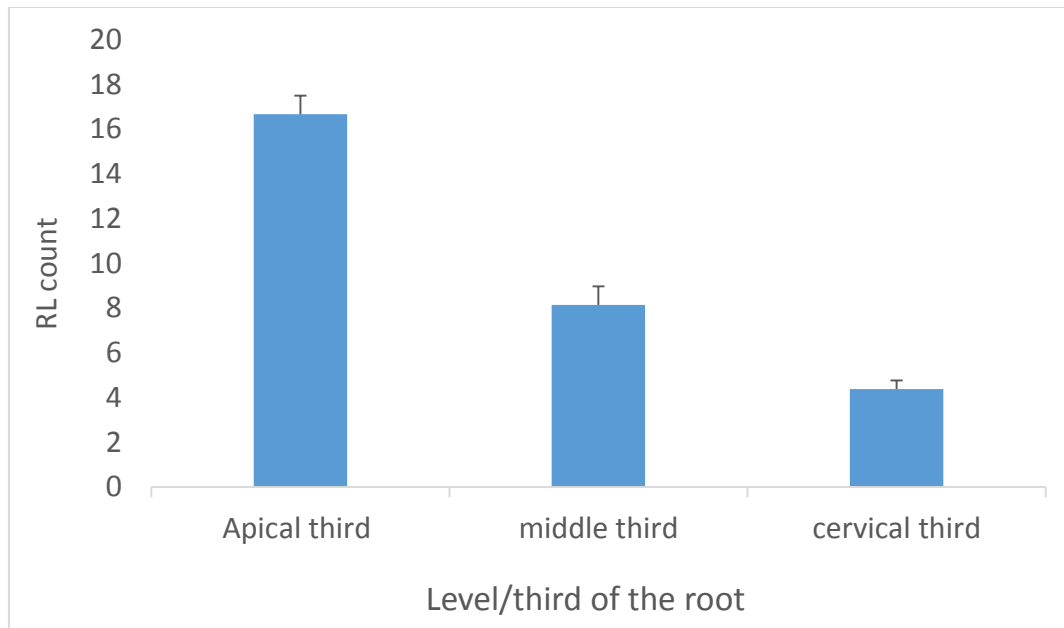
**Fig 9:** Micro-CT analysis of Percentage of tooth root resorbed (mean  $\pm$  SE) in LIPUS and control group (\*= $p < 0.05$ )



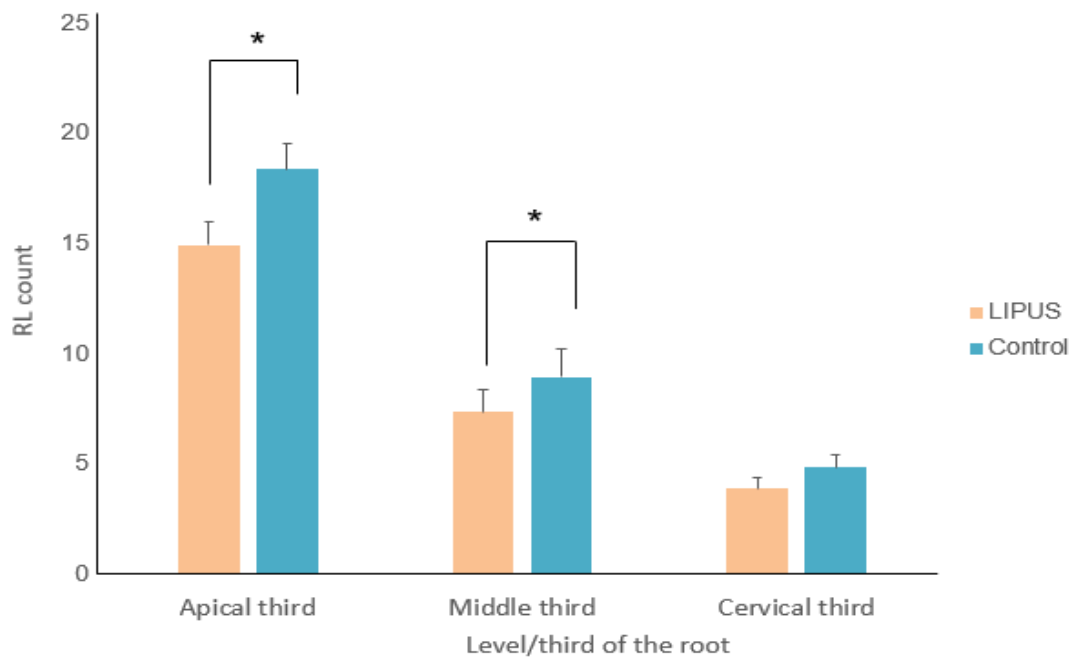
**Fig 10:** Micro-CT analysis of RL count (mean +/- SE) on different root surfaces in LIPUS and control group (\*= $p < 0.05$ )



**Fig 11:** Micro-CT analysis of Height and Depth of RL (mm) (mean +/- SE) in LIPUS and control group (\*= $p < 0.05$ )



**Fig 12:** Micro-CT analysis of overall RL count (mean  $\pm$  SE) at different level/third of the root for both the groups i.e. LIPUS and control group



**Fig 13:** Micro-CT analysis of RL count (mean  $\pm$  SE) at different level/third of the root in LIPUS and control group (\*= $p < 0.05$ )



**Table 2:** Comparison of root resorption measured variables between LIPUS and control groups along with statistical analysis results

(STE: Standard error; mm: millimeters)

Outcome	Group	N	Mean of raw data (STE)	Linear mixed model (P value)
Number of resorption lacunae on buccal surface	LIPUS	20	5.75 (.602)	0.005
	Control	20	8.40 (.796)	
Number of resorption lacunae on mesial surface	LIPUS	20	5.40 (.701)	0.006
	Control	20	8.40 (.709)	
Number of resorption lacunae on distal surface	LIPUS	20	5.50 (0.766)	0.121
	Control	20	6.95 (1.07)	
Number of resorption lacunae on palatal/lingual surface	LIPUS	20	4.50 (0.52)	0.019
	Control	20	6.80 (0.91)	
Height of resorption lacunae (mm)	LIPUS	80	0.72 (0.05)	0.007
	Control	80	0.94 (0.07)	
Depth of resorption lacunae (mm)	LIPUS	80	0.09 (0.005)	.025
	Control	80	0.11 (0.006)	
Total volume of resorption lacunae (mm <sup>3</sup> )	LIPUS	20	0.48 (0.059)	< 0.001
	Control	20	1.01 (0.092)	
Percentage of tooth root resorbed (%)	LIPUS	20	0.21 (0.02)	< 0.001
	Control	20	0.55 (0.06)	

**Table 3:** The mean number of resorption lacunae at each level/third of the root

(STE: Standard error)

Part/third of the root	N	Mean of the raw data (STE)
Cervical third	40	4.38 (0.38)
Middle third	40	8.15 (0.829)
Apical third	40	16.68 (0.818)

**Table 4:** Comparison of resorption lacunae count at each level/third of the root between LIPUS and control group along with statistical analysis results.

(STE: Standard error)

Outcome	Group	N	Mean of raw data (STE)	Linear mixed model (P value)
Cervical third	LIPUS	20	3.90 (0.492)	0.079
	Control	20	4.85 (0.595)	
Middle third	LIPUS	20	7.35 (1.027)	0.046
	Control	20	8.95 (1.29)	
Apical third	LIPUS	20	14.95 (1.022)	0.01
	Control	20	18.40 (1.127)	

**Table 5:** Comparison of outcomes of root resorption measured variables between the upper and lower teeth in LIPUS group.

(STE: Standard error)

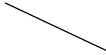
Outcome	Group	N	Mean of raw data (STE)	Linear mixed model (P value)
Number of resorption lacunae on buccal surface	upper	10	6.58 (0.898)	0.169
	lower	10	5.0 (0.775)	
Number of resorption lacunae on mesial surface	upper	10	4.90 (0.781)	0.667
	lower	10	5.90 (1.187)	
Number of resorption lacunae on distal surface	upper	10	6.50 (1.26)	0.333
	lower	10	4.50 (0.8)	
Number of resorption lacunae on palatal/lingual surface	upper	10	5.90 (0.623)	0.021
	lower	10	3.10 (0.58)	
Percentage of tooth root resorption	upper	10	0.22 (0.038)	0.959
	lower	10	0.20 (0.029)	
Total volume of RL (mm <sup>3</sup> )	upper	10	0.58 (0.11)	0.139
	lower	10	0.40 (0.039)	

**Table 6:** Comparison of outcomes of root resorption measured variables between the upper and lower teeth in control group.

(STE: Standard error)

Outcome	Group	N	Mean of raw data (STE)	Linear mixed model (P value)
Number of resorption lacunae on buccal surface	upper	10	9.30 (1.3)	0.171
	lower	10	7.50 (0.87)	
Number of resorption lacunae on mesial surface	upper	10	8.80 (1.14)	0.360
	lower	10	8.0 (0.882)	
Number of resorption lacunae on distal surface	upper	10	8.50 (1.59)	0.064
	lower	10	5.40 (1.33)	
Number of resorption lacunae on palatal/lingual surface	upper	10	7.80 (1.54)	0.235
	lower	10	5.80 (0.96)	
Percentage of tooth root resorption	upper	10	0.64 (0.11)	0.059
	lower	10	0.44 (0.06)	
Total volume of RL (mm <sup>3</sup> )	upper	10	1.08 (.154)	0.241
	lower	10	0.91 (0.112)	

**Table 7: Details of individual patients in the study.**

	<b>Patients age</b>	<b>Patients gender</b>	<b>LIPUS application</b>
1	16 years	Female	Left
2	23 years	Female	left
3	14 years	Female	Right
4	14 years	Female	Right
5	22 years	Female	Left
6	17 years	Female	Right
7	16 years	Female	Right
8	32 years	Female	Left
9	17 years	Male	left
10	16 years	male	Right

## CHAPTER 4: DISCUSSION

---

Some degree of root resorption is an unavoidable consequence of orthodontic treatment and occurs due to mechanical loading of the teeth which initiates a localized inflammation in the surrounding periodontium resulting in root loss. The etiology of root resorption is multifactorial which includes a combination of individual's biologic variability, genetic predisposition and mechanical factors(4). Torque is considered as one of the most important forces of the edgewise arch system(166) and has been identified as a major risk factor for root resorption(6)(71)(72)(72)(53).

Low intensity pulsed ultrasound is a special type of acoustic pulsed energy which has shown to have stimulatory effects on a variety of cells including cementoblast(136), odontoblast-like cells(137), chondrocytes(138), gingival cells(139)(140) and periodontal ligament cells(141). Also, its non-invasive nature and simple mode of application has made it an attractive choice of adjuvant therapy during different dental procedures including orthodontic treatment(11) and maxillary sinus augmentation(143). Based on these findings the present clinical trial evaluated the inhibitory effects of LIPUS on OIIRR caused by torque.

The study was designed as a split mouth double blind randomized clinical trial. Split mouth design was preferred over other study designs as it eliminates a large portion of inter individual variability from the estimates of the treatment effect(167). Also, necessary steps were taken to ensure adequacy of blinding and randomization in order to eliminate the influence of unknown confounding factors and to obtain unbiased results.

The study was limited to the first premolars, as they are the most frequently extracted teeth during orthodontic treatment, making them an ideal candidate for this experiment. The amount

of force generated by 15 degree of twist in the arch wire during four weeks was sufficient to study the effect of torque on OIIRR as previous investigators have observed considerable amount of root resorption after this time(53).

The LIPUS parameters used in this experiment were clinically acceptable as no deleterious effects had been previously reported(11). It was found to be effective in not only preventing OIIRR, but, also in promoting cementum regeneration and repair(11)(12)(13).

This clinical trial demonstrated that LIPUS treated teeth showed significantly less damage when subjected to torque compared to the control group, thus confirming previous findings about the preventive effects of LIPUS on OIIRR(11)(14)(12)(13). Studies evaluating the effects of LIPUS on OIIRR have demonstrated that LIPUS application cannot only promote cementogenesis by increasing ALP activity(136)(159)(163), collagen-I synthesis(136) and protein levels of Runx-2(136) but can also inhibit cementoclastogenesis by decreasing RANKL/OPG ratio(14)(13).

LIPUS application was found to be effective in significantly reducing the severity of OIIRR caused by torque as evident by the low values of total volume of resorption lacunae and percentage of root resorption. LIPUS reduced the total volume of resorption lacunae and percentage of root resorption by more than 50 percent. This may be due to the anabolic effect of LIPUS on cementoblast proliferation and differentiation(136). LIPUS when applied for 15 minutes per day, enhanced the early cementoblastic differentiation of human periodontal ligament cells by increasing ALP activity. This may have resulted in acceleration of the healing mechanism(136). Consistent with this finding, Al Daghreer et al(12) also observed significant decrease in total volume of resorption lacunae (68%) and percentage of root resorption (70%) in LIPUS group



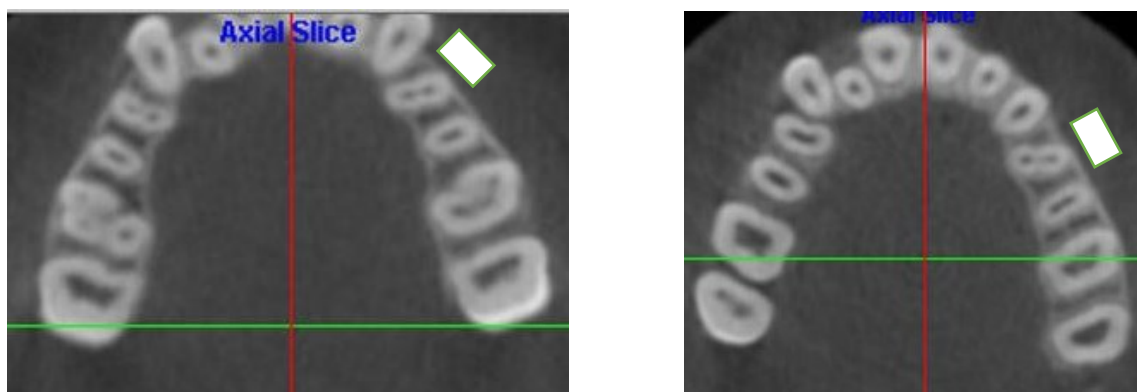
compared to control. El-Bialy et al(11) also reported significantly less RL area in the LIPUS treated pre-molars compared to control. Similar results were reported by Liu et al(13) who also observed decrease RL area in the LIPUS group compared to control.

Wierzbicki et al(50) reported the mean percentage of root resorption of the teeth after undergoing one year of regular orthodontic treatment to be 0.88% compared to 0.55% of the control group in this study, where the teeth were subjected to a fairly low level of torque for only 4 weeks. This further signifies the deleterious effect of torque on root resorption.

The resorption process is represented by the number of resorption lacunae on each root surface, however, the number of lacunae does not necessarily indicates the severity of the process(12). LIPUS application reduced the number of RL on all root surfaces compared to the control. The anti-inflammatory property of LIPUS may have played a role in producing this effect(168). LIPUS, when applied for 3 weeks, reduced the inflammatory activity of synovitis by decreasing the concentration of TNF- $\alpha$  or IL-1 $\beta$ (168). As these cytokines are also involved in the proliferation and differentiation of odontoclast cells(25), it can be suggested that LIPUS produced the same effect during orthodontic tooth movement, resulting in decrease formation of resorption lacunae. Also, it has been demonstrated that LIPUS can inhibit osteoclast activity by decreasing the RANKL/OPG ratio(14). Our findings are in accordance with previously reported results which showed significantly less number of RL in LIPUS treated teeth compared to control(11)(14)(12)(13). El-Bialy et al(11) in a clinical trial observed decreased number of RL in LIPUS treated premolars compared to control. Al Daghreer et al(12) in an experimental dog model observed decreased number of RL in the LIPUS group compared to control. Liu et al(13) in

experimental rat model also reported decreased number of RL in the LIPUS treated teeth compared to control.

In the present experiment, it was observed that LIPUS application significantly reduced the number of RL on all root surfaces compared to control except for the distal surface. The distal surface in LIPUS group showed lower number of RL compared to control, however, this difference was not significant. This can be attributed to the variability in tooth morphology or mal alignment. Most of the patients in this experiment had their first premolars rotated i.e. disto-palatal rotation, making ultrasound penetration less towards the distal surface (fig 14). Vafaeian et al(169) in a finite element model analysis demonstrated the quantitative relationship between the thicknesses of regenerated cementum and ultrasound power. He reported a non-uniform distribution of ultrasound pressure amplitudes on different root surfaces. This may account for the variability in the stimulatory and inhibitory effects of LIPUS on different root surfaces. He observed greater cementum thickness in areas of the root which received greater ultrasound pressure and vice versa(169).



**Fig 14:** CBCT images of two patients with an ultrasound transducer (white box), replicating the ultrasound application during the experiment. This image shows that the buccal and mesial

surface are closest to the ultrasound transducer, receiving maximum exposure, while the distal and palatal surface are furthest receiving least ultrasound exposure.

The severity and distribution pattern of resorption lacunae across the root surface is determined by the direction and magnitude of force application(170)(171). More severe root resorption is expected to occur in areas under high stress or compression compared to areas under tension(170)(171). In this study, the distribution pattern of RL on different root surfaces was similar between both the groups where all root surfaces had approximately the same mean number of RL. It might be possible that other than the compression side, some form of clastic activity also occurred on the tension side resulting in the formation of resorption lacunae as was seen in this experiment. Although, root resorption has been widely associated with compressive forces(172)(171), few investigators have reported root resorption with tensile forces(170)(173)(174). In a clinical study, Chan et al(170) reported root resorption with heavy tensile forces. William et al(173) also observed root resorption on tension side in rats. Al Daghreer et al(174) also observed resorption lacunae on tension side in dogs. These results indicate that the traditional opinion that OIIRR only occurs under areas of compression appears to be incorrect. It seems that OIIRR may be related to the expression of some biologic markers such as RANKL and OPG, that when present in the area, produces resorption lacunae even on the tension side.

The height and the depth of resorption lacunae of the LIPUS treated teeth was found to be significantly less for the treatment side than the control side, confirming the preventive effect of

LIPUS on OIIRR. The average height and depth of resorption lacunae of the control teeth from this experiment was found to be 0.94 mm and 0.11 mm respectively. This is in agreement with Wierzbicki et al(50) who showed comparable results (height 0.867 mm and depth 0.143 mm).

No significant differences were found in the severity of OIIRR caused by torque in between the upper and lower pre-molars in both the groups. One possible explanation of this could be relatively lower torque magnitude used in this experiment which was approximately 5 N-mm. As contact with the cortical plate, particularly the lingual cortical plate is considered as a major risk factor for OIIRR(6)(69), lower torque magnitude used in this experiment might have prevented the contact of the roots of both the upper and lower premolars with their respective cortical plate. However, Future long term clinical trials evaluating the effect of torque on OIIRR will be more helpful in better understanding this effect.

The present study evaluated the effect of LIPUS on OIIRR caused by torque over a period of four weeks. Considerable amount of root damage was observed during this time period and it is possible that the damage would have been greater if the teeth were moved for a longer period of time, as during regular orthodontic treatment. The results of this study demonstrated that LIPUS was effective in significantly reducing the total volume of RL and percentage of root resorption by more than 50 percent compared to control. This reduction in the severity of OIIRR can be clinically significant considering more extensive OIIRR which occurs during the entire course of orthodontic treatment. Therefore, it can be extrapolated that LIPUS therapy can be an effective modality for patients who are at high risk of root resorption or patients who experience severe root resorption during initial phase of orthodontic treatment. However, further long term clinical trials are required to determine the efficacy of LIPUS in reducing the severity of OIIRR to

a clinical significant level over extended period of time, as during regular orthodontic treatment. These studies will provide a more detailed insight on the stimulatory and inhibitory effects of LIPUS on cementogenesis and cementoclastogenesis respectively.

In the present clinical trial we were unable to measure the amount of orthodontic tooth movement occurred as a result of continues torque application over a period of four weeks. However, previous studies have highlighted that LIPUS application can accelerate orthodontic tooth movement while inhibiting OIIRR(14)(12)(175). Xue et al(175) in an experimental rat model demonstrated that LIPUS can accelerate orthodontic tooth movement via activation of Bone Morphogenic Protein-2 (BMP-2) signalling pathway.

In the present study, more root resorption was observed at apical third followed by middle third and cervical third. This is because torque results in compressive forces being concentrated at the apex(70)(176) which is more susceptible to root resorption(177)(178). Schwarz(33) reported that the optimal force for orthodontic tooth movement should not exceed the capillary blood pressure which ranges from 0.002 – 0.0047 MPa(179). Areas where the orthodontic force exceeds the capillary blood pressure root resorption can occur and vice versa. Hohmann et al(70) in a finite element model analysis studied the effect of torque on PDL hydrostatic pressure. He observed maximum root resorption at the apical region where orthodontic force exceeded the capillary blood pressure(70). Barley et al(53) applied 2.85 N-mm (285 g-mm) of torque and observed more resorption at the apical level than at middle and cervical level. Casa et al(71) applied 6 N-mm of torque and reported severe root resorption at the apex.

Apical RR is clinically significant as RL can accumulate at the apical region and can lead to permanent root shortening and a reduced crown to root ratio(180). In some cases, this decrease in crown to root ratio can be significant and can affect the long term viability of the dentition and can result in compromised tooth function. It has been reported that teeth with apical root shortening are more prone to periodontitis as the disease progresses more rapidly to a critical alveolar bone level(4). The present study demonstrated that LIPUS application significantly reduced the number of RL at the apical third in the treatment teeth compared to control. This reduction in the number of RL at the apical region can be clinically significant as it can prevent apical root shortening resulting in improved prognosis. However, future long term clinical trial evaluating the effect of LIPUS on OIIRR will be more effective in better understanding this effect as it will provide more detailed insight of the effect of LIPUS in preventing apical root shortening to a clinically significant level.

The present study also highlighted the deleterious effect of torque on OIIRR. Considerable amount of RR was observed after application of continuous torque (5 N-mm) over a period of four weeks. Consistent with this finding, Barley et al(53) also reported severe RR with 2.85 N-mm (285 g-mm) of torque. Casa et al(71) applied 6 N-mm of torque over a period of four weeks and observed severe root resorption of cementum extending into the underlying root dentin. Therefore, the commonly accepted idea that 5 N-mm to 20 N-mm of torque is clinically acceptable is not valid.

In addition to force magnitude, the time interval between force activation should also be assessed as another essential factor effecting OIIRR. Studies evaluating the effect of torque on OIIRR has reported severe RR with continuous torque application over a period of four

weeks(53)(71) including the results of this study. As this corresponds to the usual time interval between two orthodontic appointments, further activation of orthodontic force or orthodontic appliance during this time can greatly increase the risk of OIIRR. Although, LIPUS application significantly reduced the severity of OIIRR by enhancing cementum repair, however, It was not able to completely heal the resorption caters during this time. Therefore, longer time interval between activations should be considered, especially for patients who are at high risk of OIIRR or patients who experience root resorption during initial phases of orthodontic treatment. This will allow the resorbed cementum to heal and prevent further root resorption. Further long term clinical trial evaluating the effect of LIPUS on OIIRR will be helpful in determining the efficacy of LIPUS in accelerating cementum regeneration and repair over extended period of time.

#### **Clinical implication:**

Torque is considered as a major risk factor for root resorption(6)(69). This study highlighted the inhibitory effects of LIPUS on root resorption caused by torque under clinical settings. Considering large amount of patients undergoing orthodontic treatment every year(181) and the high prevalence of OIIRR(182)(3),it can be suggested that LIPUS, when applied during orthodontic tooth movement can be an effective preventive modality for patients who are at high risk of root resorption or patients who experience severe root resorption during initial phase of orthodontic treatment.

#### **Limitation:**

Although, the results of the present clinical trial are in accordance with the published literature, there were a couple of limitations in conducting of this study. Firstly, we experienced two patient

dropouts during the experiment, which might have affected the statistical power of the study. Secondly, the presence of pre-existing idiopathic root resorption cannot be ruled out as we were unable to analyze the teeth in three dimensions before extraction. Therefore, caution needs to be exercised when incorporating these results into clinical practices.

#### **Future research:**

Future long term randomized clinical trials evaluating the effect of LIPUS on OIIRR are required as they will provide a more detailed insight on the stimulatory and inhibitory effects of LIPUS on cementogenesis and cementoclastogenesis over an extended period of time, as during regular orthodontic treatment respectively. These studies will help in establishing the efficacy of LIPUS as a modality that can reduce the severity of OIIRR to clinically significant level. Also these studies will help in improving our current understanding of the effect of orthodontic force on OIIRR. And will enable us to assess the actual damage suffered by the teeth undergoing regular orthodontic treatment which usually comprises over a period of 2 years.

#### **Conclusion:**

From the present clinical trial following conclusions can be drawn:

- Daily application of LIPUS for 20 min/day significantly reduced the severity of OIIRR caused by torque in human subjects as evident by low values of the total height and depth of resorption lacunae, total volume of resorption lacunae and percentage of root resorption.
- LIPUS significantly reduced the number of resorption lacunae on all root surfaces except for distal surface. The distal root surface difference was not significant.



- LIPUS significantly reduced the number of resorption lacunae at the apical and middle third level of the root.
- After applying torque, maximum number of resorption lacunae were seen at the apical third followed by middle third and cervical third.

## References:

1. Tsesis I, Fuss Z, Rosenberg E, Taicher S. Radiographic evaluation of the prevalence of root resorption in a Middle Eastern population. *Quintessence Int Berl Ger* 1985. 2008 Feb;39(2):e40–44.
2. Harry MR, Sims MR. Root resorption in bicuspid intrusion. A scanning electron microscope study. *Angle Orthod*. 1982 Jul;52(3):235–58.
3. Lund H, Gröndahl K, Hansen K, Gröndahl H-G. Apical root resorption during orthodontic treatment. A prospective study using cone beam CT. *Angle Orthod*. 2012 May;82(3):480–7.
4. Weltman B, Vig KWL, Fields HW, Shanker S, Kaizar EE. Root resorption associated with orthodontic tooth movement: a systematic review. *Am J Orthod Dentofac Orthop Off Publ Am Assoc Orthod Its Const Soc Am Board Orthod*. 2010 Apr;137(4):462–476; discussion 12A.
5. Profitt W, Ackerman J. *Diagnosis and treatment planning in orthodontics*. St Louis: C.V. Mosby; 1994.
6. Kaley J, Phillips C. Factors related to root resorption in edgewise practice. *Angle Orthod*. 1991;61(2):125–32.
7. Gonzales C, Hotokezaka H, Karadeniz EI, Miyazaki T, Kobayashi E, Darendeliler MA, et al. Effects of fluoride intake on orthodontic tooth movement and orthodontically induced root resorption. *Am J Orthod Dentofac Orthop Off Publ Am Assoc Orthod Its Const Soc Am Board Orthod*. 2011 Feb;139(2):196–205.
8. Seifi M, Atri F, Yazdani MM. Effects of low-level laser therapy on orthodontic tooth movement and root resorption after artificial socket preservation. *Dent Res J*. 2014 Jan;11(1):61–6.
9. Altan AB, Bicakci AA, Mutaf HI, Ozkut M, Inan VS. The effects of low-level laser therapy on orthodontically induced root resorption. *Lasers Med Sci*. 2015 Jan 30;
10. Ekizer A, Uysal T, Güray E, Akkuş D. Effect of LED-mediated-photobiomodulation therapy on orthodontic tooth movement and root resorption in rats. *Lasers Med Sci*. 2015 Feb;30(2):779–85.
11. El-Bialy T, El-Shamy I, Graber TM. Repair of orthodontically induced root resorption by ultrasound in humans. *Am J Orthod Dentofac Orthop Off Publ Am Assoc Orthod Its Const Soc Am Board Orthod*. 2004 Aug;126(2):186–93.
12. Al-Daghreer S, Doschak M, Sloan AJ, Major PW, Heo G, Scurtescu C, et al. Effect of low-intensity pulsed ultrasound on orthodontically induced root resorption in beagle dogs. *Ultrasound Med Biol*. 2014 Jun;40(6):1187–96.
13. Liu Z, Xu J, E L, Wang D. Ultrasound enhances the healing of orthodontically induced root resorption in rats. *Angle Orthod*. 2012 Jan;82(1):48–55.

14. Inubushi T, Tanaka E, Rego EB, Ohtani J, Kawazoe A, Tanne K, et al. Ultrasound stimulation attenuates resorption of tooth root induced by experimental force application. *Bone*. 2013 Apr;53(2):497–506.
15. Brudvik P, Rygh P. The initial phase of orthodontic root resorption incident to local compression of the periodontal ligament. *Eur J Orthod*. 1993 Aug;15(4):249–63.
16. Brudvik P, Rygh P. Non-clast cells start orthodontic root resorption in the periphery of hyalinized zones. *Eur J Orthod*. 1993 Dec;15(6):467–80.
17. He D, Kou X, Luo Q, Yang R, Liu D, Wang X, et al. Enhanced M1/M2 macrophage ratio promotes orthodontic root resorption. *J Dent Res*. 2015 Jan;94(1):129–39.
18. Gordon S, Taylor PR. Monocyte and macrophage heterogeneity. *Nat Rev Immunol*. 2005 Dec;5(12):953–64.
19. Dale DC, Boxer L, Liles WC. The phagocytes: neutrophils and monocytes. *Blood*. 2008 Aug 15;112(4):935–45.
20. Hunter MM, Wang A, Parhar KS, Johnston MJG, Van Rooijen N, Beck PL, et al. In vitro-derived alternatively activated macrophages reduce colonic inflammation in mice. *Gastroenterology*. 2010 Apr;138(4):1395–405.
21. Brudvik P, Rygh P. Multi-nucleated cells remove the main hyalinized tissue and start resorption of adjacent root surfaces. *Eur J Orthod*. 1994 Aug;16(4):265–73.
22. Tsuchiya M, Akiba Y, Takahashi I, Sasano Y, Kashiwazaki J, Tsuchiya S, et al. Comparison of expression patterns of cathepsin K and MMP-9 in odontoclasts and osteoclasts in physiological root resorption in the rat molar. *Arch Histol Cytol*. 2008 Sep;71(2):89–100.
23. Sasaki T. Differentiation and functions of osteoclasts and odontoclasts in mineralized tissue resorption. *Microsc Res Tech*. 2003 Aug 15;61(6):483–95.
24. Boyle WJ, Simonet WS, Lacey DL. Osteoclast differentiation and activation. *Nature*. 2003 May 15;423(6937):337–42.
25. Zhang D, Goetz W, Braumann B, Bourauel C, Jaeger A. Effect of soluble receptors to interleukin-1 and tumor necrosis factor alpha on experimentally induced root resorption in rats. *J Periodontal Res*. 2003 Jun;38(3):324–32.
26. Low E, Zoellner H, Kharbanda OP, Darendeliler MA. Expression of mRNA for osteoprotegerin and receptor activator of nuclear factor kappa beta ligand (RANKL) during root resorption induced by the application of heavy orthodontic forces on rat molars. *Am J Orthod Dentofac Orthop Off Publ Am Assoc Orthod Its Const Soc Am Board Orthod*. 2005 Oct;128(4):497–503.
27. Hellsing E, Hammarstrom L. The hyaline zone and associated root surface changes in experimental orthodontics in rats: a light and scanning electron microscope study. *Eur J Orthod*. 1996 Feb;18(1):11–8.

28. Brudvik P, Rygh P. Transition and determinants of orthodontic root resorption-repair sequence. *Eur J Orthod.* 1995 Jun;17(3):177–88.
29. Brudvik P, Rygh P. The repair of orthodontic root resorption: an ultrastructural study. *Eur J Orthod.* 1995 Jun;17(3):189–98.
30. Proffit W. Biologic basis of orthodontic therapy. In: Proffit WR, Fields HW, editors. *Contemporary orthodontics*. 3rd ed. St Louis: C.V. Mosby; 2000.
31. Sandstedt C. Einige beiträge zur theorie der zahnregulierung. *Nord Tandlaeg Tidskr.* 1904;(5):235–56.
32. Oppenheim A. Tissue changes, particularly of the bone, incident to tooth movement. *Am Orthod.* 1911;3:57–67.
33. Schwarz AM. Tissue changes incidental to orthodontic tooth movement. *Int J Orthod Oral Surg Radiogr.* 1932 Apr;18(4):331–52.
34. Singh. G. Text book of orthodontics. revised. Japee brothers publisher; 2008. 217-218 p.
35. Bassett CA, Becker RO. Generation of electric potentials by bone in response to mechanical stress. *Science.* 1962 Sep 28;137(3535):1063–4.
36. Ten Cate's Oral Histology: Development, Structure, and Function, 8e: Antonio Nanci: 8th ed. St Louis: Mosby; 2012. 4-5 p.
37. Color Atlas of Dental Medicine: Periodontology: Herbert F. Wolf, Edith M. Rateitschak-Pluss, Klaus H. Rateitschak, Thomas M. Hassell. Thieme; 3rd edition edition; 2004. 14-15 p.
38. Owman-Moll P, Kurol J, Lundgren D. Repair of orthodontically induced root resorption in adolescents. *Angle Orthod.* 1995;65(6):403–408; discussion 409–410.
39. Gonzales C, Hotokezaka H, Darendeliler MA, Yoshida N. Repair of root resorption 2 to 16 weeks after the application of continuous forces on maxillary first molars in rats: a 2- and 3-dimensional quantitative evaluation. *Am J Orthod Dentofac Orthop Off Publ Am Assoc Orthod Its Const Soc Am Board Orthod.* 2010 Apr;137(4):477–85.
40. Cheng LL, Türk T, Elekdağ-Türk S, Jones AS, Yu Y, Darendeliler MA. Repair of root resorption 4 and 8 weeks after application of continuous light and heavy forces on premolars for 4 weeks: a histology study. *Am J Orthod Dentofac Orthop Off Publ Am Assoc Orthod Its Const Soc Am Board Orthod.* 2010 Dec;138(6):727–34.
41. Bosshardt DD, Schroeder HE. How repair cementum becomes attached to the resorbed roots of human permanent teeth. *Acta Anat (Basel).* 1994;150(4):253–66.
42. Malmgren O, Goldson L, Hill C, Orwin A, Petrini L, Lundberg M. Root resorption after orthodontic treatment of traumatized teeth. *Am J Orthod.* 1982 Dec;82(6):487–91.

43. Durack C, Patel S, Davies J, Wilson R, Mannocci F. Diagnostic accuracy of small volume cone beam computed tomography and intraoral periapical radiography for the detection of simulated external inflammatory root resorption. *Int Endod J*. 2011 Feb;44(2):136–47.
44. Dudic A, Giannopoulou C, Leuzinger M, Kiliaridis S. Detection of apical root resorption after orthodontic treatment by using panoramic radiography and cone-beam computed tomography of super-high resolution. *Am J Orthod Dentofac Orthop Off Publ Am Assoc Orthod Its Const Soc Am Board Orthod*. 2009 Apr;135(4):434–7.
45. Patel S, Dawood A, Wilson R, Horner K, Mannocci F. The detection and management of root resorption lesions using intraoral radiography and cone beam computed tomography - an in vivo investigation. *Int Endod J*. 2009 Sep;42(9):831–8.
46. Tieu LD, Saltaji H, Normando D, Flores-Mir C. Radiologically determined orthodontically induced external apical root resorption in incisors after non-surgical orthodontic treatment of class II division 1 malocclusion: a systematic review. *Prog Orthod*. 2014;15:48.
47. Sameshima GT, Sinclair PM. Predicting and preventing root resorption: Part II. Treatment factors. *Am J Orthod Dentofac Orthop Off Publ Am Assoc Orthod Its Const Soc Am Board Orthod*. 2001 May;119(5):511–5.
48. Linge L, Linge BO. Patient characteristics and treatment variables associated with apical root resorption during orthodontic treatment. *Am J Orthod Dentofac Orthop Off Publ Am Assoc Orthod Its Const Soc Am Board Orthod*. 1991 Jan;99(1):35–43.
49. Dudic A, Giannopoulou C, Martinez M, Montet X, Kiliaridis S. Diagnostic accuracy of digitized periapical radiographs validated against micro-computed tomography scanning in evaluating orthodontically induced apical root resorption. *Eur J Oral Sci*. 2008 Oct;116(5):467–72.
50. Wierzbicki T, El-Bialy T, Aldaghreer S, Li G, Doschak M. Analysis of orthodontically induced root resorption using micro-computed tomography (Micro-CT). *Angle Orthod*. 2009 Jan;79(1):91–6.
51. Harris DA, Jones AS, Darendeliler MA. Physical properties of root cementum: part 8. Volumetric analysis of root resorption craters after application of controlled intrusive light and heavy orthodontic forces: a microcomputed tomography scan study. *Am J Orthod Dentofac Orthop Off Publ Am Assoc Orthod Its Const Soc Am Board Orthod*. 2006 Nov;130(5):639–47.
52. Montenegro VCJ, Jones A, Petocz P, Gonzales C, Darendeliler MA. Physical properties of root cementum: Part 22. Root resorption after the application of light and heavy extrusive orthodontic forces: a microcomputed tomography study. *Am J Orthod Dentofac Orthop Off Publ Am Assoc Orthod Its Const Soc Am Board Orthod*. 2012 Jan;141(1):e1–9.
53. Bartley N, Türk T, Colak C, Elekdağ-Türk S, Jones A, Petocz P, et al. Physical properties of root cementum: Part 17. Root resorption after the application of 2.5° and 15° of buccal root torque for 4 weeks: a microcomputed tomography study. *Am J Orthod Dentofac Orthop Off Publ Am Assoc Orthod Its Const Soc Am Board Orthod*. 2011 Apr;139(4):e353–360.
54. Balducci L, Ramachandran A, Hao J, Narayanan K, Evans C, George A. Biological markers for evaluation of root resorption. *Arch Oral Biol*. 2007 Mar;52(3):203–8.

55. Bègue-Kirn C, Ruch JV, Ridall AL, Butler WT. Comparative analysis of mouse DSP and DPP expression in odontoblasts, preameloblasts, and experimentally induced odontoblast-like cells. *Eur J Oral Sci.* 1998 Jan;106 Suppl 1:254–9.
56. George A, Sabsay B, Simonian PA, Veis A. Characterization of a novel dentin matrix acidic phosphoprotein. Implications for induction of biomineralization. *J Biol Chem.* 1993 Jun 15;268(17):12624–30.
57. Ong D, Medland P, Ho C. Severe external apical root resorption associated with orthodontic treatment. *Ann R Australas Coll Dent Surg.* 2006 Sep;18:53–5.
58. Al-Qawasmi RA, Hartsfield JK, Everett ET, Flury L, Liu L, Foroud TM, et al. Genetic predisposition to external apical root resorption. *Am J Orthod Dentofac Orthop Off Publ Am Assoc Orthod Its Const Soc Am Board Orthod.* 2003 Mar;123(3):242–52.
59. Sehr K, Bock NC, Serbasis C, Hönemann M, Ruf S. Severe external apical root resorption--local cause or genetic predisposition? *J Orofac Orthop Fortschritte Kieferorthopädie OrganOfficial J Dtsch Ges Für Kieferorthopädie.* 2011 Aug;72(4):321–31.
60. Brezniak N, Wasserstein A. Root resorption after orthodontic treatment: Part 1. Literature review. *Am J Orthod Dentofac Orthop Off Publ Am Assoc Orthod Its Const Soc Am Board Orthod.* 1993 Jan;103(1):62–6.
61. Picanço GV, de Freitas KMS, Cançado RH, Valarelli FP, Picanço PRB, Feijão CP. Predisposing factors to severe external root resorption associated to orthodontic treatment. *Dent Press J Orthod.* 2013 Feb;18(1):110–20.
62. Maués CPR, Nascimento RR do, Vilella O de V. Severe root resorption resulting from orthodontic treatment: Prevalence and risk factors. *Dent Press J Orthod.* 2015 Feb;20(1):52–8.
63. Jung Y-H, Cho B-H. External root resorption after orthodontic treatment: a study of contributing factors. *Imaging Sci Dent.* 2011 Mar;41(1):17–21.
64. Artun J, Van 't Hullenaar R, Doppel D, Kuijpers-Jagtman AM. Identification of orthodontic patients at risk of severe apical root resorption. *Am J Orthod Dentofac Orthop Off Publ Am Assoc Orthod Its Const Soc Am Board Orthod.* 2009 Apr;135(4):448–55.
65. Makedonas D, Lund H, Hansen K. Root resorption diagnosed with cone beam computed tomography after 6 months and at the end of orthodontic treatment with fixed appliances. *Angle Orthod.* 2013 May;83(3):389–93.
66. Nakano T, Hotokezaka H, Hashimoto M, Sirisoontorn I, Arita K, Kurohama T, et al. Effects of different types of tooth movement and force magnitudes on the amount of tooth movement and root resorption in rats. *Angle Orthod.* 2014 Nov;84(6):1079–85.
67. Jayade V, Annigeri S, Jayade C, Thawani P. Biomechanics of torque from twisted rectangular archwires. A finite element investigation. *Angle Orthod.* 2007 Mar;77(2):214–20.

68. Gioka C, Eliades T. Materials-induced variation in the torque expression of preadjusted appliances. *Am J Orthod Dentofac Orthop Off Publ Am Assoc Orthod Its Const Soc Am Board Orthod*. 2004 Mar;125(3):323–8.
69. Parker RJ, Harris EF. Directions of orthodontic tooth movements associated with external apical root resorption of the maxillary central incisor. *Am J Orthod Dentofac Orthop Off Publ Am Assoc Orthod Its Const Soc Am Board Orthod*. 1998 Dec;114(6):677–83.
70. Hohmann A, Wolfram U, Geiger M, Boryor A, Sander C, Faltin R, et al. Periodontal ligament hydrostatic pressure with areas of root resorption after application of a continuous torque moment. *Angle Orthod*. 2007 Jul;77(4):653–9.
71. Casa MA, Faltin RM, Faltin K, Sander FG, Arana-Chavez VE. Root resorptions in upper first premolars after application of continuous torque moment. Intra-individual study. *J Orofac Orthop Fortschritte Kieferorthopädie Organ Official J Dtsch Ges Für Kieferorthopädie*. 2001 Jul;62(4):285–95.
72. Casa MA, Faltin RM, Faltin K, Arana-Chavez VE. Root resorption on torqued human premolars shown by tartrate-resistant acid phosphatase histochemistry and transmission electron microscopy. *Angle Orthod*. 2006 Nov;76(6):1015–21.
73. Delany AM, Dong Y, Canalis E. Mechanisms of glucocorticoid action in bone cells. *J Cell Biochem*. 1994 Nov;56(3):295–302.
74. Lems WF, Jacobs JW, Van Rijn HJ, Bijlsma JW. Changes in calcium and bone metabolism during treatment with low dose prednisone in young, healthy, male volunteers. *Clin Rheumatol*. 1995 Jul;14(4):420–4.
75. Ashcraft MB, Southard KA, Tolley EA. The effect of corticosteroid-induced osteoporosis on orthodontic tooth movement. *Am J Orthod Dentofac Orthop Off Publ Am Assoc Orthod Its Const Soc Am Board Orthod*. 1992 Oct;102(4):310–9.
76. Verna C, Hartig LE, Kalia S, Melsen B. Influence of steroid drugs on orthodontically induced root resorption. *Orthod Craniofac Res*. 2006 Feb;9(1):57–62.
77. Ong CK, Walsh LJ, Harbrow D, Taverne AA, Symons AL. Orthodontic tooth movement in the prednisolone-treated rat. *Angle Orthod*. 2000 Apr;70(2):118–25.
78. Igarashi K, Adachi H, Mitani H, Shinoda H. Inhibitory effect of the topical administration of a bisphosphonate (risedronate) on root resorption incident to orthodontic tooth movement in rats. *J Dent Res*. 1996 Sep;75(9):1644–9.
79. Fleisch H. Bisphosphonates. Pharmacology and use in the treatment of tumour-induced hypercalcaemic and metastatic bone disease. *Drugs*. 1991 Dec;42(6):919–44.
80. Flanagan AM, Chambers TJ. Dichloromethylenebisphosphonate (Cl2MBP) inhibits bone resorption through injury to osteoclasts that resorb Cl2MBP-coated bone. *Bone Miner*. 1989 Apr;6(1):33–43.
81. Jung A, Bisaz S, Fleisch H. The binding of pyrophosphate and two diphosphonates by hydroxyapatite crystals. *Calcif Tissue Res*. 1973 Mar 30;11(4):269–80.

82. Adachi H, Igarashi K, Mitani H, Shinoda H. Effects of topical administration of a bisphosphonate (risedronate) on orthodontic tooth movements in rats. *J Dent Res*. 1994 Aug;73(8):1478–86.
83. Igarashi K, Mitani H, Adachi H, Shinoda H. Anchorage and retentive effects of a bisphosphonate (AHBuBP) on tooth movements in rats. *Am J Orthod Dentofac Orthop Off Publ Am Assoc Orthod Its Const Soc Am Board Orthod*. 1994 Sep;106(3):279–89.
84. Alatli I, Hammarström L. Root surface defects in rat molar induced by 1-hydroxyethylidene-1,1-bisphosphonate. *Acta Odontol Scand*. 1996 Feb;54(1):59–65.
85. Mavragani M, Brudvik P, Selvig KA. Orthodontically induced root and alveolar bone resorption: inhibitory effect of systemic doxycycline administration in rats. *Eur J Orthod*. 2005 Jun;27(3):215–25.
86. Harris ED, Welgus HG, Krane SM. Regulation of the mammalian collagenases. *Coll Relat Res*. 1984 Dec;4(6):493–512.
87. Grevstad HJ. Doxycycline prevents root resorption and alveolar bone loss in rats after periodontal surgery. *Scand J Dent Res*. 1993 Oct;101(5):287–91.
88. Cvek M, Cleaton-Jones P, Austin J, Lownie J, Kling M, Fatti P. Effect of topical application of doxycycline on pulp revascularization and periodontal healing in reimplanted monkey incisors. *Endod Dent Traumatol*. 1990 Aug;6(4):170–6.
89. Skidmore R, Kovach R, Walker C, Thomas J, Bradshaw M, Leyden J, et al. Effects of subantimicrobial-dose doxycycline in the treatment of moderate acne. *Arch Dermatol*. 2003 Apr;139(4):459–64.
90. Robinson C, Kirkham J, Weatherell J. Fluoride in teeth and bone. In: Fejerskov OEJ, Burt BA, eds. *Fluoride in Dentistry*. Copenhagen, Denmark: Munksgaard Textbook; 1996. 69–83 p.
91. Krieger NS, Tashjian AH. Parathyroid hormone stimulates bone resorption via a Na-Ca exchange mechanism. *Nature*. 1980 Oct 30;287(5785):843–5.
92. Turner CH, Garetto LP, Dunipace AJ, Zhang W, Wilson ME, Grynpas MD, et al. Fluoride treatment increased serum IGF-1, bone turnover, and bone mass, but not bone strength, in rabbits. *Calcif Tissue Int*. 1997 Jul;61(1):77–83.
93. Abanto Alvarez J, Rezende KMPC, Marocho SMS, Alves FBT, Celiberti P, Ciamponi AL. Dental fluorosis: exposure, prevention and management. *Med Oral Patol Oral Cir Bucal*. 2009 Feb;14(2):E103–107.
94. Lim E, Belton D, Petocz P, Arora M, Cheng LL, Darendeliler MA. Physical properties of root cementum: part 15. Analysis of elemental composition by using proton-induced x-ray and gamma-ray emissions in orthodontically induced root resorption craters of rat molar cementum after exposure to systemic fluoride. *Am J Orthod Dentofac Orthop Off Publ Am Assoc Orthod Its Const Soc Am Board Orthod*. 2011 Feb;139(2):e193–202.
95. Foo M, Jones A, Darendeliler MA. Physical properties of root cementum: Part 9. Effect of systemic fluoride intake on root resorption in rats. *Am J Orthod Dentofac Orthop Off Publ Am Assoc Orthod Its Const Soc Am Board Orthod*. 2007 Jan;131(1):34–43.



96. Karadeniz EI, Gonzales C, Turk T, Isci D, Sahin-Saglam AM, Alkis H, et al. Effect of fluoride on root resorption following heavy and light orthodontic force application for 4 weeks and 12 weeks of retention. *Angle Orthod.* 2013 May;83(3):418–24.
97. Karadeniz EI, Gonzales C, Nebioglu-Dalci O, Dwarte D, Turk T, Isci D, et al. Physical properties of root cementum: part 20. Effect of fluoride on orthodontically induced root resorption with light and heavy orthodontic forces for 4 weeks: a microcomputed tomography study. *Am J Orthod Dentofac Orthop Off Publ Am Assoc Orthod Its Const Soc Am Board Orthod.* 2011 Nov;140(5):e199–210.
98. Franke J. [Effect of fluoride on the skeletal system]. *Z Für Gesamte Inn Med Ihre Grenzgeb.* 1984 Jul 1;39(13):293–7.
99. Persson EC, Engström C, Thilander B. The effect of thyroxine on craniofacial morphology in the growing rat. Part I: A longitudinal cephalometric analysis. *Eur J Orthod.* 1989 Feb;11(1):59–66.
100. Pouprouk E, Loberg E, Engström C. Thyroid function and root resorption. *Angle Orthod.* 1994;64(5):389–393; discussion 394.
101. Shirazi M, Dehpour AR, Jafari F. The effect of thyroid hormone on orthodontic tooth movement in rats. *J Clin Pediatr Dent.* 1999;23(3):259–64.
102. Rossi M, Whitcomb S, Lindemann R. Interleukin-1 beta and tumor necrosis factor-alpha production by human monocytes cultured with L-thyroxine and thyrocalcitonin: relation to severe root shortening. *Am J Orthod Dentofac Orthop Off Publ Am Assoc Orthod Its Const Soc Am Board Orthod.* 1996 Oct;110(4):399–404.
103. Karu T. Primary and secondary mechanisms of action of visible to near-IR radiation on cells. *J Photochem Photobiol B.* 1999 Mar;49(1):1–17.
104. Yaakobi T, Maltz L, Oron U. Promotion of bone repair in the cortical bone of the tibia in rats by low energy laser (He-Ne) irradiation. *Calcif Tissue Int.* 1996 Oct;59(4):297–300.
105. Genc G, Kocadereli I, Tasar F, Kilinc K, El S, Sarkarati B. Effect of low-level laser therapy (LLLT) on orthodontic tooth movement. *Lasers Med Sci.* 2013 Jan;28(1):41–7.
106. Inoue K, Nishioka J, Hukuda S. Suppressed tuberculin reaction in guinea pigs following laser irradiation. *Lasers Surg Med.* 1989;9(3):271–5.
107. Horton MA, Taylor ML, Arnett TR, Helfrich MH. Arg-Gly-Asp (RGD) peptides and the anti-vitronectin receptor antibody 23C6 inhibit dentine resorption and cell spreading by osteoclasts. *Exp Cell Res.* 1991 Aug;195(2):368–75.
108. Teitelbaum SL. Bone resorption by osteoclasts. *Science.* 2000 Sep 1;289(5484):1504–8.
109. Nakamura I, Tanaka H, Rodan GA, Duong LT. Echistatin inhibits the migration of murine pre-fusion osteoclasts and the formation of multinucleated osteoclast-like cells. *Endocrinology.* 1998 Dec;139(12):5182–93.

110. Talic NF, Evans C, Zaki AM. Inhibition of orthodontically induced root resorption with echistatin, an RGD-containing peptide. *Am J Orthod Dentofac Orthop Off Publ Am Assoc Orthod Its Const Soc Am Board Orthod*. 2006 Feb;129(2):252–60.
111. Buckley MJ, Banes AJ, Levin LG, Sumpio BE, Sato M, Jordan R, et al. Osteoblasts increase their rate of division and align in response to cyclic, mechanical tension in vitro. *Bone Miner*. 1988 Jul;4(3):225–36.
112. Saito M, Soshi S, Tanaka T, Fujii K. Intensity-related differences in collagen post-translational modification in MC3T3-E1 osteoblasts after exposure to low- and high-intensity pulsed ultrasound. *Bone*. 2004 Sep;35(3):644–55.
113. Lyon R, Liu XC, Meier J. The effects of therapeutic vs. high-intensity ultrasound on the rabbit growth plate. *J Orthop Res Off Publ Orthop Res Soc*. 2003 Sep;21(5):865–71.
114. Tanaka E, Kuroda S, Horiuchi S, Tabata A, El-Bialy T. Low-Intensity Pulsed Ultrasound in Dentofacial Tissue Engineering. *Ann Biomed Eng*. 2015 Feb 12;
115. Watanabe Y, Matsushita T, Bhandari M, Zdero R, Schemitsch EH. Ultrasound for fracture healing: current evidence. *J Orthop Trauma*. 2010 Mar;24 Suppl 1:S56–61.
116. Busse JW, Bhandari M, Kulkarni AV, Tunks E. The effect of low-intensity pulsed ultrasound therapy on time to fracture healing: a meta-analysis. *CMAJ Can Med Assoc J J Assoc Medicale Can*. 2002 Feb 19;166(4):437–41.
117. Rego EB, Takata T, Tanne K, Tanaka E. Current status of low intensity pulsed ultrasound for dental purposes. *Open Dent J*. 2012;6:220–5.
118. Smith NB, Temkin JM, Shapiro F, Hynynen K. Thermal effects of focused ultrasound energy on bone tissue. *Ultrasound Med Biol*. 2001 Oct;27(10):1427–33.
119. Tsaklis P. Presentation of Acoustic Waves Propagation and Their Effects Through Human Body Tissues. *J Hum Mov*. 2010 Jun 1;58–65.
120. Rooney J. Nonlinear phenomena. In: Edmonds PD, editor. *Methods of experimental physics*. Ultrason N Y Acad Press. 1981;19:299–353.
121. Khan Y, Laurencin CT. Fracture repair with ultrasound: clinical and cell-based evaluation. *J Bone Joint Surg Am*. 2008 Feb;90 Suppl 1:138–44.
122. Chapman IV, MacNally NA, Tucker S. Ultrasound-induced changes in rates of influx and efflux of potassium ions in rat thymocytes in vitro. *Ultrasound Med Biol*. 1980;6(1):47–58.
123. Ingber DE. Mechanosensation through integrins: cells act locally but think globally. *Proc Natl Acad Sci U S A*. 2003 Feb 18;100(4):1472–4.
124. Pounder NM, Harrison AJ. Low intensity pulsed ultrasound for fracture healing: a review of the clinical evidence and the associated biological mechanism of action. *Ultrasonics*. 2008 Aug;48(4):330–8.

125. Sato M, Nagata K, Kuroda S, Horiuchi S, Nakamura T, Karima M, et al. Low-intensity pulsed ultrasound activates integrin-mediated mechanotransduction pathway in synovial cells. *Ann Biomed Eng.* 2014 Oct;42(10):2156–63.
126. Giancotti FG, Ruoslahti E. Integrin signaling. *Science.* 1999 Aug 13;285(5430):1028–32.
127. Schlaepfer DD, Hunter T. Integrin signalling and tyrosine phosphorylation: just the FAKs? *Trends Cell Biol.* 1998 Apr;8(4):151–7.
128. Riveline D, Zamir E, Balaban NQ, Schwarz US, Ishizaki T, Narumiya S, et al. Focal contacts as mechanosensors: externally applied local mechanical force induces growth of focal contacts by an mDia1-dependent and ROCK-independent mechanism. *J Cell Biol.* 2001 Jun 11;153(6):1175–86.
129. Hsu H-C, Fong Y-C, Chang C-S, Hsu C-J, Hsu S-F, Lin J-G, et al. Ultrasound induces cyclooxygenase-2 expression through integrin, integrin-linked kinase, Akt, NF-kappaB and p300 pathway in human chondrocytes. *Cell Signal.* 2007 Nov;19(11):2317–28.
130. Manaka S, Tanabe N, Kariya T, Naito M, Takayama T, Nagao M, et al. Low-intensity pulsed ultrasound-induced ATP increases bone formation via the P2X7 receptor in osteoblast-like MC3T3-E1 cells. *FEBS Lett.* 2015 Jan 30;589(3):310–8.
131. Parvizi J, Parpura V, Greenleaf JF, Bolander ME. Calcium signaling is required for ultrasound-stimulated aggrecan synthesis by rat chondrocytes. *J Orthop Res Off Publ Orthop Res Soc.* 2002 Jan;20(1):51–7.
132. Li JK, Chang WH, Lin JC, Ruaan RC, Liu HC, Sun JS. Cytokine release from osteoblasts in response to ultrasound stimulation. *Biomaterials.* 2003 Jun;24(13):2379–85.
133. Reher P, Doan N, Bradnock B, Meghji S, Harris M. Effect of ultrasound on the production of IL-8, basic FGF and VEGF. *Cytokine.* 1999 Jun;11(6):416–23.
134. Hasuike A, Sato S, Udagawa A, Ando K, Arai Y, Ito K. In vivo bone regenerative effect of low-intensity pulsed ultrasound in rat calvarial defects. *Oral Surg Oral Med Oral Pathol Oral Radiol Endod.* 2011 Jan;111(1):e12–20.
135. Bashardoust Tajali S, Houghton P, MacDermid JC, Grewal R. Effects of low-intensity pulsed ultrasound therapy on fracture healing: a systematic review and meta-analysis. *Am J Phys Med Rehabil Assoc Acad Physiatr.* 2012 Apr;91(4):349–67.
136. Inubushi T, Tanaka E, Rego EB, Kitagawa M, Kawazoe A, Ohta A, et al. Effects of ultrasound on the proliferation and differentiation of cementoblast lineage cells. *J Periodontol.* 2008 Oct;79(10):1984–90.
137. Scheven BA, Man J, Millard JL, Cooper PR, Lea SC, Walmsley AD, et al. VEGF and odontoblast-like cells: stimulation by low frequency ultrasound. *Arch Oral Biol.* 2009 Feb;54(2):185–91.
138. Iwabuchi Y, Tanimoto K, Tanne Y, Inubushi T, Kamiya T, Kunimatsu R, et al. Effects of low-intensity pulsed ultrasound on the expression of cyclooxygenase-2 in mandibular condylar chondrocytes. *J Oral Facial Pain Headache.* 2014;28(3):261–8.

139. Shiraishi R, Masaki C, Toshinaga A, Okinaga T, Nishihara T, Yamanaka N, et al. The effects of low-intensity pulsed ultrasound exposure on gingival cells. *J Periodontol*. 2011 Oct;82(10):1498–503.
140. Mostafa NZ, Uludağ H, Dederich DN, Doschak MR, El-Bialy TH. Anabolic effects of low-intensity pulsed ultrasound on human gingival fibroblasts. *Arch Oral Biol*. 2009 Aug;54(8):743–8.
141. Hu B, Zhang Y, Zhou J, Li J, Deng F, Wang Z, et al. Low-intensity pulsed ultrasound stimulation facilitates osteogenic differentiation of human periodontal ligament cells. *PloS One*. 2014;9(4):e95168.
142. Rego EB, Inubushi T, Miyauchi M, Kawazoe A, Tanaka E, Takata T, et al. Ultrasound stimulation attenuates root resorption of rat replanted molars and impairs tumor necrosis factor- $\alpha$  signaling in vitro. *J Periodontal Res*. 2011 Dec;46(6):648–54.
143. Kim SH, Hong KS. Histologic evaluation of low-intensity pulsed ultrasound effects on bone regeneration in sinus lift. *J Periodontal Implant Sci*. 2010 Dec;40(6):271–5.
144. El-Bialy TH, Royston TJ, Magin RL, Evans CA, Zaki AE, Frizzell LA. The effect of pulsed ultrasound on mandibular distraction. *Ann Biomed Eng*. 2002 Dec;30(10):1251–61.
145. El-Bialy TH, Elgazzar RF, Megahed EE, Royston TJ. Effects of ultrasound modes on mandibular osteodistraction. *J Dent Res*. 2008 Oct;87(10):953–7.
146. Wang Y, Chai Z, Zhang Y, Deng F, Wang Z, Song J. Influence of low-intensity pulsed ultrasound on osteogenic tissue regeneration in a periodontal injury model: X-ray image alterations assessed by micro-computed tomography. *Ultrasonics*. 2014 Aug;54(6):1581–4.
147. Ikai H, Tamura T, Watanabe T, Itou M, Sugaya A, Iwabuchi S, et al. Low-intensity pulsed ultrasound accelerates periodontal wound healing after flap surgery. *J Periodontal Res*. 2008 Apr;43(2):212–6.
148. Al-Daghreer S, Doschak M, Sloan AJ, Major PW, Heo G, Scurtescu C, et al. Long term effect of low intensity pulsed ultrasound on a human tooth slice organ culture. *Arch Oral Biol*. 2012 Jun;57(6):760–8.
149. Al-Daghreer S, Doschak M, Sloan AJ, Major PW, Heo G, Scurtescu C, et al. Short-term effect of low-intensity pulsed ultrasound on an ex-vivo 3-d tooth culture. *Ultrasound Med Biol*. 2013 Jun;39(6):1066–74.
150. El-Bialy T, Lam B, Aldaghreer S, Sloan AJ. The effect of low intensity pulsed ultrasound in a 3D ex vivo orthodontic model. *J Dent*. 2011 Oct;39(10):693–9.
151. El-Bialy T, Alhadlaq A, Wong B, Kucharski C. Ultrasound effect on neural differentiation of gingival stem/progenitor cells. *Ann Biomed Eng*. 2014 Jul;42(7):1406–12.
152. Bosshardt DD, Selvig KA. Dental cementum: the dynamic tissue covering of the root. *Periodontol* 2000. 1997 Feb;13:41–75.

153. Ouyang H, Franceschi RT, McCauley LK, Wang D, Somerman MJ. Parathyroid hormone-related protein down-regulates bone sialoprotein gene expression in cementoblasts: role of the protein kinase A pathway. *Endocrinology*. 2000 Dec;141(12):4671–80.
154. el-Bialy TH, el-Moneim Zaki A, Evans CA. Effect of ultrasound on rabbit mandibular incisor formation and eruption after mandibular osteodistraction. *Am J Orthod Dentofac Orthop Off Publ Am Assoc Orthod Its Const Soc Am Board Orthod*. 2003 Oct;124(4):427–34.
155. Boabaid F, Berry JE, Koh AJ, Somerman MJ, McCauley LK. The role of parathyroid hormone-related protein in the regulation of osteoclastogenesis by cementoblasts. *J Periodontol*. 2004 Sep;75(9):1247–54.
156. Dalla-Bona DA, Tanaka E, Inubushi T, Oka H, Ohta A, Okada H, et al. Cementoblast response to low- and high-intensity ultrasound. *Arch Oral Biol*. 2008 Apr;53(4):318–23.
157. Lynch MP, Stein JL, Stein GS, Lian JB. The influence of type I collagen on the development and maintenance of the osteoblast phenotype in primary and passaged rat calvarial osteoblasts: modification of expression of genes supporting cell growth, adhesion, and extracellular matrix mineralization. *Exp Cell Res*. 1995 Jan;216(1):35–45.
158. Yamaguchi A, Komori T, Suda T. Regulation of osteoblast differentiation mediated by bone morphogenetic proteins, hedgehogs, and Cbfa1. *Endocr Rev*. 2000 Aug;21(4):393–411.
159. Dalla-Bona DA, Tanaka E, Oka H, Yamano E, Kawai N, Miyauchi M, et al. Effects of ultrasound on cementoblast metabolism in vitro. *Ultrasound Med Biol*. 2006 Jun;32(6):943–8.
160. Scheven BA, Millard JL, Cooper PR, Lea SC, Walmsley AD, Smith AJ. Short-term in vitro effects of low frequency ultrasound on odontoblast-like cells. *Ultrasound Med Biol*. 2007 Sep;33(9):1475–82.
161. Li M, Thompson DD, Paralkar VM. Prostaglandin E(2) receptors in bone formation. *Int Orthop*. 2007 Dec;31(6):767–72.
162. Minamizaki T, Yoshiko Y, Kozai K, Aubin JE, Maeda N. EP2 and EP4 receptors differentially mediate MAPK pathways underlying anabolic actions of prostaglandin E2 on bone formation in rat calvaria cell cultures. *Bone*. 2009 Jun;44(6):1177–85.
163. Rego EB, Inubushi T, Kawazoe A, Tanimoto K, Miyauchi M, Tanaka E, et al. Ultrasound stimulation induces PGE(2) synthesis promoting cementoblastic differentiation through EP2/EP4 receptor pathway. *Ultrasound Med Biol*. 2010 Jun;36(6):907–15.
164. Rosner B. *Fundamentals of Biostatistics*. 7th Edition. Brooks/Cole; 2011. 232 p.
165. Malek S, Darendeliler MA, Rex T, Kharbanda OP, Srivicharnkul P, Swain MV, et al. Physical properties of root cementum: part 2. Effect of different storage methods. *Am J Orthod Dentofac Orthop Off Publ Am Assoc Orthod Its Const Soc Am Board Orthod*. 2003 Nov;124(5):561–70.
166. Rauch E. Torque and its application to orthodontics. *Am J Orthod*. 1959 Nov;15(11):817–30.

167. Lesaffre E, Philstrom B, Needleman I, Worthington H. The design and analysis of split-mouth studies: what statisticians and clinicians should know. *Stat Med*. 2009 Dec 10;28(28):3470–82.
168. Nakamura T, Fujihara S, Yamamoto-Nagata K, Katsura T, Inubushi T, Tanaka E. Low-intensity pulsed ultrasound reduces the inflammatory activity of synovitis. *Ann Biomed Eng*. 2011 Dec;39(12):2964–71.
169. Vafaeian B, Al-Daghreer S, El-Rich M, Adeeb S, El-Bialy T. Simulation of Low-Intensity Ultrasound Propagating in a Beagle Dog Dentoalveolar Structure to Investigate the Relations between Ultrasonic Parameters and Cementum Regeneration. *Ultrasound Med Biol*. 2015 Aug;41(8):2173–90.
170. Chan E, Darendeliler MA. Physical properties of root cementum: part 7. Extent of root resorption under areas of compression and tension. *Am J Orthod Dentofac Orthop Off Publ Am Assoc Orthod Its Const Soc Am Board Orthod*. 2006 Apr;129(4):504–10.
171. Reitan K. Initial tissue behavior during apical root resorption. *Angle Orthod*. 1974 Jan;44(1):68–82.
172. Reitan K. Biomechanical principles and reactions. In: Graber TM, Swain BF, eds. *Orthodontics: current principles and techniques*. St. Louis: C.V. Mosby; 1985. 101-92 p.
173. Williams S. A histomorphometric study of orthodontically induced root resorption. *Eur J Orthod*. 1984 Feb;6(1):35–47.
174. Al-Daghreer SM. Analysis of the biological effects of therapeutic ultrasound on orthodontically induced tooth root resorption repair [Internet] [Ph.D.]. [Canada]: University of Alberta (Canada); 2012 [cited 2015 Apr 14]. Available from: <http://search.proquest.com/login.ezproxy.library.ualberta.ca/pqdtglobal/docview/1220488134/abstract/D7BAA3D285144F82PQ/1?accountid=14474>
175. Xue H, Zheng J, Cui Z, Bai X, Li G, Zhang C, et al. Low-intensity pulsed ultrasound accelerates tooth movement via activation of the BMP-2 signaling pathway. *PloS One*. 2013;8(7):e68926.
176. Puente MI, Galbán L, Cobo JM. Initial stress differences between tipping and torque movements. A three-dimensional finite element analysis. *Eur J Orthod*. 1996 Aug;18(4):329–39.
177. Henry JL, Weinmann JP. The pattern of resorption and repair of human cementum. *J Am Dent Assoc* 1939. 1951 Mar;42(3):270–90.
178. Srivicharnkul P, Kharbanda OP, Swain MV, Petocz P, Darendeliler MA. Physical properties of root cementum: Part 3. Hardness and elastic modulus after application of light and heavy forces. *Am J Orthod Dentofac Orthop Off Publ Am Assoc Orthod Its Const Soc Am Board Orthod*. 2005 Feb;127(2):168–176; quiz 260.
179. Dorow C, Sander F-G. Development of a model for the simulation of orthodontic load on lower first premolars using the finite element method. *J Orofac Orthop Fortschritte Kieferorthopädie OrganOfficial J Dtsch Ges Für Kieferorthopädie*. 2005 May;66(3):208–18.

180. Proffit W, Fields H, Sarver D. Contemporary orthodontics. Philadelphia: Elsevier; 2006.
181. Ohazama A, Courtney J-M, Sharpe PT. Opg, Rank, and Rankl in tooth development: co-ordination of odontogenesis and osteogenesis. J Dent Res. 2004 Mar;83(3):241–4.
182. Makedonas D, Lund H, Gröndahl K, Hansen K. Root resorption diagnosed with cone beam computed tomography after 6 months of orthodontic treatment with fixed appliance and the relation to risk factors. Angle Orthod. 2012 Mar;82(2):196–201.