

University of Alberta

Vitreol growth hormone: a marker of ocular disease?

by

Misagh Ziaei



A thesis submitted to the Faculty of Graduate Studies and Research
in partial fulfillment of the requirements for the degree of

Master of Science

Department of Physiology

Edmonton, Alberta

Fall 2007



Library and
Archives Canada

Bibliothèque et
Archives Canada

Published Heritage
Branch

Direction du
Patrimoine de l'édition

395 Wellington Street
Ottawa ON K1A 0N4
Canada

395, rue Wellington
Ottawa ON K1A 0N4
Canada

Your file *Votre référence*
ISBN: 978-0-494-33385-3
Our file *Notre référence*
ISBN: 978-0-494-33385-3

NOTICE:

The author has granted a non-exclusive license allowing Library and Archives Canada to reproduce, publish, archive, preserve, conserve, communicate to the public by telecommunication or on the Internet, loan, distribute and sell theses worldwide, for commercial or non-commercial purposes, in microform, paper, electronic and/or any other formats.

The author retains copyright ownership and moral rights in this thesis. Neither the thesis nor substantial extracts from it may be printed or otherwise reproduced without the author's permission.

AVIS:

L'auteur a accordé une licence non exclusive permettant à la Bibliothèque et Archives Canada de reproduire, publier, archiver, sauvegarder, conserver, transmettre au public par télécommunication ou par l'Internet, prêter, distribuer et vendre des thèses partout dans le monde, à des fins commerciales ou autres, sur support microforme, papier, électronique et/ou autres formats.

L'auteur conserve la propriété du droit d'auteur et des droits moraux qui protègent cette thèse. Ni la thèse ni des extraits substantiels de celle-ci ne doivent être imprimés ou autrement reproduits sans son autorisation.

In compliance with the Canadian Privacy Act some supporting forms may have been removed from this thesis.

Conformément à la loi canadienne sur la protection de la vie privée, quelques formulaires secondaires ont été enlevés de cette thèse.

While these forms may be included in the document page count, their removal does not represent any loss of content from the thesis.

Bien que ces formulaires aient inclus dans la pagination, il n'y aura aucun contenu manquant.


Canada

ABSTRACT

Excess and deficiency of endocrine growth hormone (GH) have been correlated with ocular disease. Locally-derived GH from the vitreoretinal space may also correlate with ocular disease, exerting autocrine/paracrine actions in the eye. In human controls and both non-diabetics and diabetics with ocular disease, GH immunoreactivity was detected by Western immunoblot in the neural retina and vitreous humour, and quantified by ELISA in the vitreous humour. GH-immunoreactive proteins of sizes 22 kDa and >45 kDa were characterized. Levels of uncorrected and protein-corrected vitreous GH were significantly lower in diabetics than in controls matched for age, gender, and plasma GH. Non-diabetics with macular holes had significantly lower levels of uncorrected vitreous GH than controls. In non-diabetics and diabetics, levels of protein-corrected vitreous GH showed a positive linear correlation with levels of protein-corrected vitreous free IGF-1, suggesting IGF-1 dependence of retinal GH action. Therefore, reduced locally-derived, ocular GH may be a marker of ocular disease.

DEDICATIONS

This thesis is dedicated to the countless Iranian Bahá'í youth and young adults who would give so much for an opportunity to get a college or university education. The thesis is also dedicated to the Bahá'í Institute for Higher Education (BIHE) students who arose to sacrificially earn their graduate degrees abroad and return to their nation of birth, hoping to be of service to their countrymen.

ACKNOWLEDGEMENTS

I would like to thank Dr. Steve Harvey and Dr. Esmond Sanders for the opportunity, resources, and assistance to do this fascinating study and for their patience, flexibility and guidance. I would also like to give a special thanks to Dr. Yves Sauvé for his constant encouragement, support, and quirky sense of humour. I would like to thank Dr. Michael Walter for agreeing to be on my examining committee. Each of these individuals has helped me see what it means to be a critically-thinking, focused and successful scientist.

My thanks and appreciation go out to Drs. Ian MacDonald, Matthew Tennant, Bradley Hinz, and Mark Greve and all the nursing staff, administrative staff, and residents who helped me in enrolling patients, collecting samples, and who provided stimulating and insightful conversation. Special thanks go out to Bonnie Kissick for her patience and for helping to coordinate and plan my trips to the hospital to collect samples. A special thanks goes out to Ben Bablitz in the Department of Laboratory Science for his technical assistance and for his donation of Drabkin's reagent. Big thanks go out to Valerie Taylor and all the technicians and pathologists in the Department of Laboratory Medicine and Pathology for their assistance in obtaining control plasma samples and for pulling up their sleeves when needed.

My warmest thanks go out to my two lovely and gifted sisters, Mahtab and Neda. They were constantly on my mind throughout this journey, and Neda's phone calls were a constant source of happiness and peace-of-mind.

None of this would have been possible without the support, love, encouragement, guidance, and sacrificial assistance of my tireless, hard-working, and loving parents, Fakhroddin and Zahra. It is on the shoulders of giants that I stand.

And last, but not least, I would like to thank my beloved wife Jamál, who has been a constant support, help-mate, shoulder to lean on, and a constant source of encouragement.

TABLE OF CONTENTS

Abstract

Dedications

Acknowledgements

List of Tables

List of Figures

List of Abbreviations

I. LITERATURE REVIEW	1
A. Preamble	2
B. Pituitary growth hormone (GH).....	4
1. Synthesis and Secretion	4
a. Isohormones.....	5
b. Variants.....	6
2. Roles in growth and metabolism.....	7
3. Roles in ocular function	8
a. GH excess	8
b. GH deficiency	9
4. Roles in diabetes mellitus (DM)	10
a. GH and diabetic retinopathy (DR).....	12
C. Extrapituitary GH.....	13
1. Autocrine/paracrine GH.....	13
a. Distribution in the visual system	13
b. Ocular effects	14
D. Insulin-like growth factor 1 (IGF-1).....	15
1. Synthesis and roles.....	15
2. IGF-1 and ocular disease	16
a. Endocrine IGF-1 and DR.....	17
b. Autocrine/paracrine IGF-1 and DR	18
E. The human eye.....	18
1. Anatomy of the vitreous humour	18
2. Anatomy of the retina	20
3. Blood-retinal barrier (BRB).....	21
4. Disorders of the eye	22
a. Diabetic Retinopathy (DR).....	24
1. Etiology.....	24
2. Treatment.....	25
F. Summary	25
G. Hypothesis and Aims	26
II. MATERIALS AND METHODS	27
A. Vitreous samples.....	28
B. Vitreous Hemorrhage.....	29
C. Blood samples.....	30
D. Protein assay	31
E. Western Immunoblotting	31

F. GH Enzyme-Linked ImmunoSorbent Assay (ELISA)	33
G. Free IGF-1 ELISA	34
H. Statistical analysis.....	35
III. RESULTS	41
A. Western Immunoblots.....	42
B. ELISAs.....	43
IV. DISCUSSION	62
A. Characterization of GH in vitreous and retina	63
B. Quantification of GH and IGF-1 immunoreactivity by ELISA.....	65
1. Total vitreal protein and GH levels.....	65
2. Uncorrected vitreous GH.....	67
3. Protein-corrected vitreous GH.....	69
4. Plasma GH.....	70
5. Uncorrected and protein-corrected vitreous GH correlates with plasma GH	73
6. Uncorrected and protein-corrected vitreous free IGF-1.....	73
7. Plasma free IGF-1	74
8. IGF-1 dependence of GH action.....	75
C. Other variables.....	76
1. Metabolic factors	76
2. Gender.....	77
3. Free versus total IGF-1	77
D. Reduced vitreous GH – beneficial or insidious?.....	78
E. Future work.....	80
V. REFERENCES	82

LIST OF TABLES

Table 1	Sample information for diabetic patients with ocular disease, sorted by age.	36
Table 2	Sample information for non-diabetic patients with various ocular disorders, sorted by age.	37
Table 3	Sample information for samples of control vitreous from cadavers with no known history of ocular disease, sorted by age.	39
Table 4	Sample information for samples of control plasma from volunteers with no known history of ocular disease or DM, sorted by age.	40
Table 5	Statistically significant differences in total corrected vitreous protein (corrected for hemoglobin), uncorrected vitreous GH, protein-corrected vitreous GH and plasma free IGF-1 grouped by ocular conditions.	46
Table 6	Statistically significant correlations between vitreous and plasma GH and free IGF-1.	47

LIST OF FIGURES

Figure 1	Western immunoblot of GH-immunoreactive proteins in adult human vitreous from a male cadaver, age 67, with no known history of ocular disease.	48
Figure 2	Western immunoblot of GH-immunoreactive proteins in adult human retina (lane R) from a 57 year old male with no known history of ocular disease.	49
Figure 3	Western immunoblot of GH-immunoreactive proteins in adult human vitreous from patients with ocular disease.	50
Figure 4	Total protein corrected for hemoglobin in adult vitreous.	51
Figure 5	Levels of uncorrected vitreous GH in adult patients.	52
Figure 6	Levels of GH corrected for total vitreal protein in the vitreous of adult humans.	53
Figure 7	Uncorrected and protein-corrected vitreous GH levels in diabetics without PDR and diabetics with PDR.	54
Figure 8	Plasma GH levels in adults.	55
Figure 9	Uncorrected vitreous free IGF-1 in adults.	56
Figure 10	Levels of free IGF-1 corrected for total vitreal protein in the vitreous of adult humans.	57
Figure 11	Plasma free IGF-1 levels in adults.	58
Figure 12	Total uncorrected vitreal protein versus uncorrected vitreous GH in non-diabetics with ocular disease.	59
Figure 13	Total uncorrected vitreal protein versus uncorrected vitreous GH in diabetics with ocular disease.	60
Figure 14	Uncorrected vitreous GH versus plasma GH in diabetics with ocular disease.	61

LIST OF ABBREVIATIONS

ALS	Acid labile subunit
BBB	Blood-brain barrier
BRB	Blood-retinal barrier
BRVO	Branch retinal vein occlusion
BSA	Bovine serum albumin
CNS	Central nervous system
CSF	Cerebrospinal fluid
DM	Diabetes mellitus
DR	Diabetic retinopathy
ECL	Enhanced chemiluminescence
ED	Embryonic day
ELISA	Enzyme-linked immunosorbent assay
ERM	Epiretinal membrane
GH	Growth hormone
GHBP	Growth hormone binding protein
GHR	Growth hormone receptor
GHRH	Growth hormone releasing hormone
Hb	Hemoglobin
hGH-N	Human growth hormone – normal
HRP	Horseradish peroxidase
ICAM-1	Intracellular adhesion molecule-1
IDDM	Insulin-dependent diabetes mellitus

IGF-1	Insulin-like growth factor-1
IGFBP	Insulin-like growth factor binding protein
IL-6	Interleukin-6
kDa	Kilodalton
mRNA	Messenger ribonucleic acid
MH	Macular hole
NIDDM	Non-insulin-dependent diabetes mellitus
PAGE	Polyacrylamide gel electrophoresis
PDR	Proliferative diabetic retinopathy
PEDF	Pigment epithelium-derived factor
pH	Power of the hydrogen ion
RD	Retinal detachment
RGC	Retinal ganglion cell
RHYNS	Retinitis pigmentosa, hypopituitarism, nephronophthisis, and mild skeletal dysplasia
RPE	Retinal pigmented epithelium
RPM	Revolutions per minute
SDS	Sodium dodecyl sulfate
SEM	Standard error of the mean
TGF- β	Transforming growth factor- β
TIMP-1	Tissue inhibitor of metalloproteinase-1
TMB	Tetramethylbenzidine
TBS	Tris-buffered saline
TTBS	Tween-20 tris-buffered saline

VEGF Vascular endothelial growth factor

w/v Weight per volume

I. LITERATURE REVIEW

A. Preamble

Growth hormone (GH) is traditionally considered to be a collection of functionally-related proteins secreted by somatotrophs of the pituitary gland into the bloodstream, through which they are transported to their ubiquitous target sites. GH, then, is an *endocrine* hormone. GH moieties have different biological activity in various tissues, and are involved in processes such as growth and metabolism (Harvey et. al., 1995). GH can act directly on cells or can act indirectly via a host of other factors such as insulin-like growth factor-1 (IGF-1; Le Roith et al., 2001).

Pathophysiological states of circulating GH excess and deficiency have been associated with various ocular pathologies. Excess circulating GH has been associated with several ocular diseases including diabetic retinopathy (DR), an ocular complication involving neovascularization of the retina which occurs in both insulin-dependent and non-insulin dependent diabetics. DR remains the major cause of acquired blindness in young people and adults in developed countries (Chiarelli et al., 2005), with approximately 80% of insulin-dependent diabetics of 10 years duration being affected (Klein et al., 1992).

Conversely, congenital GH deficiency is also associated with various ocular disorders including refractive errors of the eye (Parentin et al., 2004), visuomotor defects (Shurka and Laron, 1975), and altered retinal vascularization due to reduced vessel branching points (Hellstrom et al., 1999).

The discovery of extrapituitary GH – that is, GH produced in non-pituitary cells throughout the body – has added a further dimension to GH research. GH is known to be

produced in cells of the brain, immune system, placenta, mammary gland, and testis (Harvey and Hull, 1997), among others. Locally-produced GH may bypass the bloodstream and act on neighbouring cells (as a *paracrine*) and/or on the originating cell itself (as an *autocrine*).

Recently, extrapituitary GH has been detected at high concentrations in the retina and vitreous humour of the embryonic chick (Baudet et al., 2003), which can be considered a model system for ocular development (Bahr, 2000). The retina is a tissue posterior to the lens of the eye that receives light and transduces it into electrical signals that are relayed to the brain. The vitreous humour is the translucent, gel-like matrix adjacent to the retina which gives the eye its shape and which allows for penetration of light through the eye. The detection of GH in the retina and vitreous raises the possibility that GH – acting as an endocrine and/or an autocrine/paracrine factor – may be involved in human ocular development. As well, the discovery of extrapituitary GH in the perinatal and adult rat (Harvey et al., 2006) suggests roles for local GH in normal ocular function.

The eye is a repository of many peptide factors, working in synergy to ensure homeostasis. An imbalance in one or more of these factors in the vitreous may contribute to ocular disorders, and thus these factors could be considered as markers of ocular disease. Such factors include vascular endothelial growth factor (VEGF; Funatsu et al., 2002b), transforming growth factor- β (TGF- β ; Boulton et al., 1997), intracellular adhesion molecule-1 (ICAM-1; Funatsu et al., 2006), leptin (Maberley et al., 2006) and IGF-1 (Simo et al., 2003). Given the range of ocular pathologies associated with GH

excess and deficiency, the finding of localized GH in the embryonic chick and adult rat retina and vitreous humour, the ability of GH to promote proliferation of human retinal endothelial cells (Rymaszewski et al., 1991) and its role in ischemia-induced retinal neovascularization (Smith et al., 1997), levels of GH in the human eye may be correlated with various ocular disorders.

B. Pituitary growth hormone (GH)

1. SYNTHESIS AND SECRETION

Growth hormone (GH) is traditionally considered to be a collection of structurally related polypeptides produced by somatotroph cells of the anterior pituitary (adenohypophysis) and secreted into the bloodstream, through which they are transported to their ubiquitous systemic target sites (Butler and Le Roith, 2001). Approximately half of the circulating GH is bound by a GH binding protein (GHBP), the extracellular component of the GH receptor (GHR; Baumann, 2001). Circulating GHBP primarily stabilizes serum GH concentration and extends its half-life in the bloodstream (Baumann et al., 1987). GHBP has an apparent molecular weight of 60-65 kDa, depending on its state of glycosylation (Baumann, 2002).

The hGH (human GH) proteins are synthesized primarily by the hGH-N (Normal) gene in the pituitary gland (Baumann, 1991; Sami, 2007). GH secretion and release from the pituitary are modulated by two opposing hypothalamic hormones. GH-releasing hormone (GHRH) stimulates synthesis and secretion of GH (Gick et al., 1984; Lengyel, 2006) whereas somatostatin – also known as somatotropin release inhibiting factor (SRIF) –

inhibits GH release (Fukata et al., 1985). In addition, plasma factors such as IGF-1 can down-regulate GH secretion (Chen et al., 2005), and GH itself can inhibit its own secretion via an auto-feedback mechanism (Harvey et al., 1995; Ridderstrale, 2005).

Age and gender also affect GH secretion. Secretion peaks at late puberty and steadily declines throughout adulthood and senescence (Sherlock and Toogood, 2007) – a phenomenon known as the somatopause – such that after age 60 plasma GH levels are < 20% of that during late puberty (Ho and Hoffman, 1993). Premenopausal women have higher plasma GH concentration than men (Ho et al., 1987), since estrogen can modulate GH secretion and possibly its clearance and action (Leung et al., 2004).

A. Isohormones

Following stimulation of GH synthesis and its release, the majority of hGH in blood serum is monomeric with a molecular weight of 22 kilodaltons (kDa) (Stolar et al., 1984b; De Palo et al., 2006b). However, several immunoreactive GH isohormones are also released from the pituitary and into the blood stream. These isohormones differ in their primary structure (Baumann, 1991), likely due to processing of the mRNA transcript (DeNoto et al., 1981; Popii and Baumann, 2004). In human pituitary and serum, they have molecular weights of 17.5 kDa and 20 kDa (Lewis et al., 1980; Lecomte et al., 1987; Lewis et al., 2000). Immunoreactive GH of 12 kDa and 30 kDa in human serum have also been reported (Baumann et al., 1985).

B. Variants

In addition, hGH can undergo a variety of post-translational modifications in mammals, including glycosylation to yield a 24 kDa variant (Haro et al., 1996; Lewis et al., 2000), deamidation (Lewis et al., 1981; Popii and Baumann, 2004), phosphorylation (Liberti and Joshi, 1986), and acylation (Lewis et al., 1979).

The hGH protein can also be found in dimerized/oligomerized and proteolytically cleaved forms (Lewis et al., 2000). Homodimers which are linked via disulfide bonds are known to be extremely stable under strong reducing and denaturing conditions (Grigorian et al., 2005). They have a molecular weight of approximately 45 kDa, while oligomers of 62 kDa, 80 kDa, and 110 kDa have also been resolved in blood plasma by electrophoretic separation (Stolar et al., 1984a).

Proteolytic cleavage of 22 kDa monomer GH results in a moiety of 17 kDa found in serum (Sinha and Jacobsen, 1994; De Palo et al., 2006a). Additionally, cleaved monomer GH can link together covalently to re-form a 22 kDa moiety which appears as a 24 kDa moiety on electrophoretic gels (Maciag et al., 1980). This variant can be reduced to 8 kDa and 14 kDa moieties *in vitro* by endogenous proteases associated with liver membranes (Schepper et al., 1984). Detectable GH in the blood plasma, then, can be a conglomeration of various isohormones and variants of the hGH-N gene product.

2. ROLES IN GROWTH AND METABOLISM

GH, as its name suggests, is required for post-embryonic growth. Circulating GH secreted by the pituitary reaches cell-surface receptors in the liver modulating a subsequent release of hepatic insulin-like growth factor I (IGF-1) and other factors into circulation (Le Roith et al., 2001). IGF-1, in turn, acts in an endocrine and/or autocrine/paracrine (see below) manner on the epiphyseal plate of long bones leading to somatic growth (Juil, 2003). Thus, GH action in growth and metabolism can be IGF-1 dependent. However, direct (non-IGF-1-mediated) effects of GH on postnatal growth (Isaksson et al., 1982; Wang et al., 1999) and other processes such as skeletal muscle cell fusion (Sotiropoulos et al., 2006) and proliferation of beta cells in the pancreas (Billestrup and Nielsen, 1991) have also been suggested.

GH also has an effect on fat, protein, and carbohydrate metabolism. In particular, its effects are anabolic and are likely dependent on local production and autocrine/paracrine action of IGF-1 (Butler and Le Roith, 2001). GH-deficient individuals offer clear evidence of GH's metabolic effects; they show increased body fat and decreased lean body mass and skeletal muscle (Takahashi and Satozawa, 2002). Acute administration of GH has a lipolytic effect on fat and can lead to a rise in circulating levels of free fatty acids and glycerol (Jorgensen et al., 2007). GH promotes protein synthesis in muscle and treatment with GH in GH-deficient individuals results in increased muscle size (Kostyo, 1968; Moller et al., 2007). Acute GH administration leads to insulin-like effects on carbohydrate metabolism, while in the long term GH stimulation causes hyperglycemia,

enhanced hepatic gluconeogenesis and glycogenolysis, and a state of insulin-resistance (Butler and Le Roith, 2001).

3. ROLES IN OCULAR FUNCTION

There is a possibility that pituitary GH exerts an endocrine effect on the eye. In healthy mice, intraperitoneal injection of GH affects electroretinogram readings, demonstrating a GH effect on retinal ganglion cell (RGC) function (Hattori and Fukuchi, 1974). Human retinal microvascular endothelial cells *in vitro* express receptors for GH and respond to exogenous GH stimulation by proliferating (Rymaszewski et al., 1991), supporting a role for GH in retinal angiogenesis. Opticin, a proteoglycan present in vitreous and which binds GH (Sanders et al., 2003) may help ensure the needed supply of GH for retinal angiogenesis (Forrester, 2004). In the human eye, both excess and deficiency of circulating GH are believed to play a role in a variety of ocular disorders (reviewed by Harvey et al, 2007).

A. GH excess

Elevated serum GH levels have been associated with various ocular disorders. The effects of excess GH are thought to be indirect. Specifically, elevated levels of glucose as a result of GH excess are implicated in local ischemia and a rise in reactive oxygen species, both of which can lead to ischemia-induced neovascularization (Butler and Le Roith, 2001; Kowluru et al., 2001) and apoptotic death of retinal capillary endothelial cells, which itself can induce ischemia (Frank, 2004). These indirect GH effects are underscored by the fact that long term, tight control of blood glucose and free fatty acids

is an important preventative and treatment measure for those with DR (Boehm, 2007). Whether through direct or indirect effects, high plasma GH levels lead to retinal neovascularization in a mouse model of retinopathy due to retinal ischemia (Smith et al., 1997). Similarly, elevated plasma GH levels played a direct or indirect role in retinopathy of human infants, as elevated plasma GH in one-month-old preterm infants was associated with the development of retinopathy of prematurity (Hikino et al., 2001). Non-neovascular ocular disorders are also associated with serum GH excess. High levels of serum GH may be implicated in the etiology of open-angle glaucoma, possibly raising intraocular pressure by modifying the sclero-corneal trabecular meshwork (Greco et al., 1979). Pituitary adenomas, which can cause hypersecretion of GH, can exert pressure on the optic nerve which can affect vision (Chanson and Salenave, 2004). In addition, tumors of the choroid have been reported in patients with acromegaly, a state of congenital GH excess (Corcuff et al., 1997). GH hypersecretion was also observed in a patient with neurofibromatosis type I and an optic nerve glioma, likely as a result of reduced somatostatin secretion (Drake et al., 2000).

B. GH deficiency

GH deficiency is also implicated in various ocular diseases. Children with congenital GH deficiency show altered retinal vascularization in the form of reduced vessel branching points (Hellstrom et al., 1999; Parentin et al., 2004), implicating GH as an important factor in normal retinal angiogenesis. Optic disc and nerve hypoplasia as well as septo-optic dysplasia are also associated with GH deficiency (Hoyt et al., 1970; Willnow et al., 1996), with early GH therapy suggested as a therapeutic measure to prevent sight-

threatening sequelae (Mutz et al., 1984). Furthermore, refractive errors of the eye, most notably hyperopia, are common in children with GH deficiency and are related to the shorter axial length of the eye (Parentin et al., 2004). Well-timed GH replacement therapy can result in a normal ametropization process in these children (Parentin and Perissutti, 2005). Patients with Laron dwarfism, characterized by short stature, lower-than-average intelligence and GH resistance, also show visuomotor defects (Shurka and Laron, 1975) related to refractive errors of the eye (Bourla et al., 2006). Jacobsen syndrome, a condition caused by chromosomal deletion on chromosome 11, is associated with a variety of disorders including pituitary GH deficiency, ptosis, colobomas of the choroids and retina, glaucoma, and cataracts (Pivnick et al., 1996). In addition, those with RHYNS (Retinitis pigmentosa, Hypopituitarism, Nephronophthisis, and mild Skeletal dysplasia) syndrome, marked by retinitis pigmentosa and reductions in photoreceptor responses, are GH deficient (Di Rocco et al., 1997; Hedera and Gorski, 2001). Cockayne syndrome, a rare childhood disorder characterized by pigmentary degeneration of the retina, is similarly associated with pituitary GH deficiency (Park et al., 1994). All of these studies point to endocrine and/or autocrine/paracrine GH as an essential factor in the development and proper function of the human eye. Finally, postmenopausal women with idiopathic macular holes had lower systemic levels of GH than age-matched women without macular holes (Kmera-Muszynska and Zgliczynski, 2000).

4. ROLES IN DIABETES MELLITUS (DM)

Diabetes mellitus is a metabolic disease characterized by hyperglycemia and is often accompanied by reduced or absent sensitivity to circulating insulin. Diabetes may be

characterized as insulin-dependent diabetes mellitus (IDDM, requiring regular injections of insulin) or non-insulin-dependent diabetes mellitus (NIDDM, with individuals usually on oral hypoglycemic treatment). More than seventy years ago, evidence began to accumulate that circulating GH had a role in the etiology of diabetes mellitus. Houssay and Biasotti first described improvement of hyperglycemia in experimentally diabetic dogs following hypophysectomy, or removal of the pituitary (Biasotti and Houssay, 1932). Subsequent studies reported that repeated injection of anterior pituitary extract – of which GH was the active component – maintained adult dogs in a permanent diabetic state (Cotes and Crichton, 1949). Long-term GH treatment leads to insulin-resistance (Butler and Le Roith, 2001) and eventually to diabetes with fasting hyperglycemia (Sonksen et al., 1993).

In humans, plasma GH levels were found to be elevated in insulin-dependent diabetics (Johansen and Hansen, 1969; Lundbaek et al., 1970). In addition, those with IDDM had abnormally high spontaneous and stimulated GH secretion compared to non-diabetic controls (Powell et al., 1966; Holt et al., 2003). Plasma GH levels are likewise increased in non-obese subjects with NIDDM compared to non-obese controls (Hansen, 1973), while plasma GH levels are decreased in obese subjects with NIDDM compared to obese controls (Kjeldsen et al., 1975). Obesity itself is likely the reason for this decrease, as obesity is common in NIDDM and suppresses spontaneous and stimulated GH secretion (Scacchi et al., 1999).

A. GH and diabetic retinopathy (DR)

Circulating GH has long been implicated in diabetic retinopathy (DR), an ocular disease involving neovascularization of the retina (see below). Poulsen described recovery from DR in a patient with Simmond's disease (1953), characterized by damage to the pituitary gland. In insulin-dependent diabetics, circulating GH levels were shown to be higher in those with than without retinopathy (Powell et al., 1966; Kaneko et al., 1985). GH-deficient dwarfs with glucose intolerance had lower-than-expected incidence of DR (Merimee, 1978), despite the lack of an appropriately matched control group in that study (Winegrad and Greene, 1978; Alzaid et al., 1994). Cultured human retinal endothelial cells were shown to proliferate following treatment with GH (Rymaszewski et al., 1991). Additionally, somatostatin-like immunoreactivity was shown to be reduced in the vitreous of patients with proliferative DR (PDR; (Simo et al., 2002). As native GH has been implicated as an angiogenic factor (Corbacho et al., 2002) – particularly in ischemia-induced retinal neovascularization (Smith et al., 1997) – high serum GH levels may play a pro-angiogenic role in the diabetic eye.

There is, however, controversy surrounding the role of GH in the etiology of DR.

Curiously, patients with acromegaly – a state of congenital GH excess – rarely present with DR (Ballantine et al., 1981). One study found DR-like retinal changes following GH replacement therapy in two non-diabetic patients (Koller et al., 1998) and a recent study implicated GH therapy in the progression of retinopathy in a non-diabetic patient with short stature and hypermetropia (Paterson et al., 2007). Subsequent cessation of GH replacement therapy resulted in full remission of retinopathy (Hansen et al., 2000;

Paterson et al., 2007). However, another study (larger and cross-sectional) found no retinal changes following GH replacement therapy in GH-deficient patients (Blank et al., 2000; Urban et al., 2005).

C. Extrapituitary GH

1. AUTOCRINE/PARACRINE GH

Complimenting the endocrine actions of GH are its autocrine/paracrine effects exerted in extrapituitary sites of GH production. The visual systems of embryonic domestic fowl (Baudet et al., 2003; Harvey et al., 2004) and neonatal and adult rats (Harvey et al., 2006) have been reported to be sites of GH synthesis and autocrine/paracrine GH action.

A. Distribution in the visual system

In the visual system of the embryonic chick, GH immunoreactivity was detected in the vitreous humour, in RGCs, and in the retinal pigmented epithelium (RPE; Baudet et al., 2003; Harvey et al., 2003). Interestingly, this GH-immunoreactive protein was primarily associated with a protein of size 15 kDa rather than the monomer 22 kDa protein (Baudet et al., 2003). GHR immunoreactivity, as well as GH and GHR mRNA were also detected in the neural retina and RPE (Harvey et al., 2001; Harvey et al., 2003). This novel discovery indicates local, extrapituitary GH production within the eye. Local GH production is further suggested by GH immunoreactivity detected at embryonic day 7 (ED7), prior to the differentiation of pituitary somatotrophs (Baudet et al., 2003) at ED12 (Harvey et al., 1998) and the appearance of GH immunoreactivity in the bloodstream at ED 17 (Harvey et al., 1979). Moreover, the BRB has been shown to

exclude the passage of circulating GH into the eye (James and Cotlier, 1983; Cunha-Vaz, 1997), further suggesting the presence of local GH in the vitreoretinal space. The chick eye is relevant since it has been used as a model for retinal neurogenesis (de la Rosa and de Pablo, 2000), human ocular development and ametropia (Lawrence and Azar, 2002; Choh and Sivak, 2005). Recently, GH immunoreactivity and GH mRNA were also detected in the neural retina of perinatal and adult rats, particularly in RGCs and their axons in the optic fiber layer (Harvey et al., 2006). In plasma and vitreous of neonatal rats, expression of GH has a specific ontogenic pattern from birth to weaning, with compartment-specific differences in plasma and vitreous GH levels (Modanlou et al., 2006). Specifically, while retinal GH levels remained constant from birth to weaning, both plasma and vitreous levels of GH declined with age, with levels being comparable at birth but vitreous levels much lower than plasma levels at postnatal days 7, 14, and 21 (Modanlou et al., 2006). These findings suggest that the plasma, retina, and vitreous comprise three separate compartments of immunoreactive GH, at concentrations that can change with age.

B. Ocular effects

In vertebrates, GH is a factor involved in the morphological development of the eye (Diaz-Casares et al., 2005). Studies in embryonic chicks have demonstrated that during development, extrapituitary GH in the vitreoretinal space acts as an autocrine/paracrine factor involved in retinal differentiation (Harvey et al., 2003; Harvey et al., 2004). Retinal GH also exerts an anti-apoptotic effect on differentiating retinal ganglion cells during development both *in vitro* and *in vivo* (Sanders et al., 2005). GH can stimulate IGF-1

synthesis in the teleost eye (Otteson et. al., 2002) and chicken GH can increase retinal IGF-1 mRNA levels in cultured embryonic chick retina (Baudet et. al., 2003), although rat retinal IGF-1 levels are reported to be GH independent (Gerhardinger et. al., 2001). Extrapituitary GH in the eye, then, may have roles in human ocular development and function.

D. Insulin-like growth factor 1 (IGF-1)

1. SYNTHESIS AND ROLES

Insulin-like growth factor-I (IGF-1), historically known as somatomedin C (Daughaday et al., 1972), is a peptide of 7649 daltons which shares structural homology and biological properties with insulin (Zapf et al., 1984). Circulating IGF-1 is largely synthesized in the liver (Jansen et al., 1983) and is released into circulation in response to GH stimulation. The majority of IGF-1 – more than 99 percent – circulates in serum complexed with various binding proteins (Juul, 2003). There are six known IGF binding proteins (IGFBP) of sizes 24 kDa, 30 kDa (Hardouin et al., 1989), 32 kDa (Bienvenu et al., 2004), 34 kDa, 38.5 kDa, and 41.5 kDa (Hardouin et al., 1989). IGF-1 may also bind to other serum binding proteins, such as acid labile subunit (ALS). IGFBP-3 along with ALS binds the majority of IGF-1 in circulation, in a 150 kDa complex (Jones and Clemmons, 1995). Free, unbound IGF-1 may represent the biologically active fraction of IGF-1 in circulation (Juul et al., 1997; Chen et al., 2005) although it accounts for less than 1% of the total circulating IGF-1 (Juul, 2003). At physiological pH, free IGF-1 is likely dimerized (Cooke et al., 1991) with a molecular weight of 15 159 daltons (Koyama et al., 2003).

IGF-1 can also be produced in a variety of tissues other than the liver, where it may exert local autocrine/paracrine effects. Endocrine and/or autocrine/paracrine IGF-1 have extensive roles in metabolism (Le Roith et al., 2001), spatial learning and memory (Svensson et al., 2006), neurogenesis (Hernandez-Sanchez et al., 1995), and cell survival (Kurmasheva and Houghton, 2006; Seigel et al., 2006), to name a few.

2. IGF-1 AND OCULAR DISEASE

Serum IGF-1 has been shown to affect ocular function. This effect is underscored by the finding that monomer IGF-1 crosses the BBB (Reinhardt and Bondy, 1994; Armstrong et al., 2000; Carro and Torres-Aleman, 2006), possibly in a carrier-mediated manner (Pulford and Ishii, 2001) and that the BBB is similar in function to the BRB (Lightman et al., 1987). In the vitreous of patients with DR and macular hole, changes have been noted in expression of IGFBPs of size 30 kDa and 34 kDa (Boulton et al., 1997), further implicating IGF-1 in the etiology of ocular disease.

Levels of serum IGF-1 have been linked to ocular disorders of the eye. In preterm one-month-old infants, decreased serum IGF-1 levels were associated with retinopathy of prematurity (Hikino et al., 2001). Postmenopausal women with idiopathic macular holes had lower systemic levels of IGF-1 than age-matched women without macular holes (Kmera-Muszynska and Zgliczynski, 2000). IGF-1 receptor/binding protein has also been detected in epiretinal membranes of diabetic origin (Ulbig et al., 1995), raising the possibility that IGF-1 may be involved in the formation of epiretinal membranes in

diabetic patients. Of note, Van Setten et. al. (2002) measured high levels of IGF-1 in subretinal fluid following retinal detachment in a diabetic patient with acromegaly.

A. Endocrine IGF-1 and DR

Plasma IGF-1 has been implicated in the etiology of DR. Controversy, however, surrounds plasma IGF-1's role in this disease, likely due to methodological differences in IGF-1 assays. A transient increase in serum IGF-1 levels has been reported in the early stage of retinal neovascularization in DR (Merimee et al., 1983; Hyer et al., 1989b), while other studies have shown no association between incidence of DR and plasma IGF-1 level (Wang et al., 1995; Frystyk et al., 2003), although one study did find decreased plasma total IGF-1 levels in diabetics compared to controls (Frystyk et al., 2003).

Decreased plasma free IGF-1 is associated with diabetes (Feldmann et al., 2000; Frystyk et al., 2003) but is not associated with PDR (Frystyk, 2004). Those with IDDM and DR had similar levels of plasma free IGF-1 as diabetics without DR (Frystyk et al., 2003).

Studies measuring IGF-1 levels in human vitreous humour from adult patients have shown that increased total (Meyer-Schwickerath et al., 1993; Burgos et al., 2000) and free IGF-1 (Simo et al., 2003) in the vitreous is associated with PDR. In both cases, diffusion of IGF-1 from the plasma into the vitreous likely accounts for at least some of the measured IGF-1, as leakiness of the BRB is a hallmark of DR (Pfeiffer et al., 1997; Felinski and Antonetti, 2005).

B. Autocrine/paracrine IGF-1 and DR

Contribution of locally-produced retinal IGF-1 to the etiology of PDR cannot be dismissed (Frystyk et al., 2003), with IGF-1 possibly playing an autocrine/paracrine role. The human retina produces IGF-1 and its receptor/binding proteins (Spoerri et al., 1998), and IGF-1 mRNA is decreased in diabetic versus non-diabetic retinae (Spoerri et al., 1998; Gerhardinger et al., 2001). This correlates with another study showing decreased intraocular (locally-produced) IGF-1 in the vitreous of patients with proliferative DR (Simo et al., 2003). This local IGF-1 is likely produced in the retina and exerts autocrine/paracrine effects in the eye, affecting the incidence of DR.

E. The human eye

The human eye is composed of several structures that, together, enable vision. Light enters the eye through the cornea, passes through the aqueous humour, strikes the lens and undergoes refraction, and enters the vitreous humour before striking the retina at the posterior end of the eye.

1. ANATOMY OF THE VITREOUS HUMOUR

The anatomy of the vitreous humour has been extensively reviewed by Bishop (2000). In brief, the human vitreous humour is a clear, gel-like extracellular matrix composed mainly of water but also containing phagocytic cells called hyalocytes (Grabner et al., 1980; Bishop, 2000), unbranched collagen fibrils which contain macromolecules such as proteoglycans (Sanders et al., 2003), and hyaluronan (Bishop, 2000). Under normal

conditions, the volume of adult human vitreous is approximately 4.5 mL and is found attached to the retina and adjacent to the lens.

The vitreous is also a reservoir for various systemic and local factors, some of which have been correlated to ocular disease. Boulton et al. (1997) correlated intravitreal growth factor levels and state of ocular disease for several growth factors including transforming growth factor- β (TGF- β), IGF-1, and epidermal growth factor (EGF). Decreased intravitreal free IGF-1 has previously been mentioned as a marker of PDR in a subset of patients (Simo et al., 2003). Increased vitreal levels of vascular endothelial growth factor (VEGF) and intracellular adhesion molecule-1 (ICAM-1) have been implicated in diabetic macular edema (Funatsu et al., 2005b), as have elevated levels of angiotensin II (Funatsu et al., 2002a). Levels of both VEGF and angiotensin II in the vitreous were elevated in those with active PDR compared to those with quiescent PDR, demonstrating that these two factors serve as ocular markers of the severity of PDR (Funatsu et al., 2002b). Locally-produced cellular fibronectin in the vitreous and aqueous humours was significantly higher in diabetics and those with uveitis compared to controls (Probst et al., 2004). Aqueous humour levels of VEGF and interleukin-6 (IL-6) were elevated in patients with macular edema as a result of branch retinal vein occlusion (BRVO), and levels of VEGF served as an ocular marker of the severity of disease (Noma et al., 2005). This study is relevant as vitreous levels of these factors correlate with levels in the aqueous humour (Funatsu et al., 2005a). Patients with neovascular glaucoma had increased transforming growth factor (TGF)-beta 1 and 2 levels in aqueous humour (Yu et al., 2007). Differences in the levels of tissue inhibitor of metalloproteinase (TIMP)-1

and -2 have been correlated to incidence of DR, proliferative vitreoretinopathy, retinal detachment, vitreous hemorrhage, and epiretinal membrane (Matsuo et al., 1998). And, levels of leptin in the vitreous of patients with PDR were increased when compared to patients with non-diabetic proliferative vitreoretinopathy (Maberley et al., 2006). As a body fluid, then, the vitreous may be diagnostically sampled and analyzed for markers of ocular disease (Uy and Foster, 1999; Funatsu et al., 2006).

2. ANATOMY OF THE RETINA

The anatomy of the human retina is reviewed and described in detail by Cohen (1992). The retina is an extension of the central nervous system (CNS) which includes the brain and spinal cord. It has a laminar structure containing two major layers: the pigmented layer and the neural layer. The pigmented layer – also called the retinal pigmented epithelium (RPE) – is composed of epithelial cells containing melanin, which helps absorb stray light entering the eye (Cohen, 1992). The neural layer is further divided into layers of specialized cells, called nuclear layers. The first of these nuclear layers and closest to the RPE is the outer nuclear layer, which contains the cell bodies of RPE-embedded, light-sensitive rod and cone photoreceptor cells. The inner nuclear layer contains cell bodies for bipolar cells, horizontal cells, and amacrine cells, which serve as interneurons. Bipolar and amacrine cells synapse onto RGCs in the ganglion cell layer. Between the outer and inner nuclear layers is the outer plexiform layer, where photoreceptors synapse onto bipolar and horizontal cells. Between the ganglion cell layer and the inner nuclear layer is the inner plexiform layer, where RGCs synapse onto bipolar and amacrine cells (Miller, 1989). RGCs transmit electrical impulses received from the

interneurons to the visual cortex of the brain via the optic nerve, where a visual image is constructed. GH immunoreactivity has been detected in RGCs of embryonic chicks and perinatal and adult rats (Baudet et al., 2003; Harvey et al., 2006) and in the RPE of embryonic chicks (Baudet et al., 2003). These discoveries lend strong support to the notion of local, extrapituitary GH production in the eye.

3. BLOOD-RETINAL BARRIER (BRB)

The blood-retinal barrier (BRB) is essential for maintenance of homeostasis in the eye by providing a selectively permeable barrier to water and solutes such as inflammatory cells and antibodies (Felinski and Antonetti, 2005). It shares similar microanatomy and developmental origin with the blood-brain barrier (BBB; Manfre et al., 1997), and may be subdivided into the inner and outer BRB (Cunha-Vaz, 1976; Cunha-Vaz, 2004). The inner BRB is comprised of tight junctions between retinal endothelial cells in the vasculature of the inner retina, while the outer BRB consists of tight junctions between cells of the RPE which prevents infiltration of water and solutes from the fenestrated capillaries of the choroid (Cunha-Vaz, 1976; Lightman et al., 1987). In bovines, exogenous ^{125}I -labelled human GH was unable to penetrate the BRB, while ^{125}I -labelled insulin did seem to penetrate the barrier (James and Cotlier, 1983). BRB infiltration of GH and IGF-1 in humans without neovascular eye disease remains to be studied.

However, the structurally-similar BBB has been shown to be permeable to exogenous ^{125}I -labelled GH, most likely via simple diffusion (Coculescu, 1999; Pan et al., 2005), as well as to ^{125}I -labelled IGF-1 (Reinhardt and Bondy, 1994). The BBB excludes passage of many peptide hormones (Coculescu, 1999) but allows for passage of others, notably

albumin (Pardridge et al., 1985) and insulin, and vasopressin, the latter being transported via receptor-mediated transcytosis (Pardridge, 1986). Insulin can influence IGF-1 levels in the circulation (Feldmann et al., 2000), thereby affecting GH levels. Albumin has been used as a marker of permeability of blood vessels (Spranger et al., 2001). Studies of GH penetration across the BBB may be relevant to further understanding GH penetration across the BRB, given the similarity between the BRB and BBB. Despite evidence for transport of GH through the BBB via simple diffusion, GH receptors are found at the choroid plexus and raise the possibility of a specific transport mechanism at the blood-cerebrospinal fluid (CSF) barrier (Lai et al., 1991; Nyberg, 2000).

Increased permeability of the BRB is observed in patients with various ocular disorders, such as DR, macular degeneration, and retinitis pigmentosa (Cunha-Vaz, 2004), leading to infiltration of solutes and fluid into the vitreous. VEGF upregulation seems to play an important role in the early breakdown of the inner BRB in experimental DR (Antonetti et al., 1998; Qaum et al., 2001). In neovascularization seen in patients with DR, the BRB is immature and newly-formed blood vessel walls are weak and susceptible to leakage (Funatsu et al., 2006).

4. DISORDERS OF THE EYE

Many sight-threatening ocular disorders can affect the eye. Epiretinal membranes are avascular fibrocellular membranes which grow on the inner surface of the retina and can cause visual impairment (Ting and Kwok, 2005). They are more common to the elderly and can be idiopathic (Ting and Kwok, 2005) or associated with diabetes mellitus

(Mitchell et al., 1997). Growth factors such as IGF-1 (Ulbig et al., 1995), VEGF and TGF- β -2 have been detected in fibroglial cells of epiretinal membranes. The interaction between these latter two growth factors may affect epiretinal membrane formation (Mandelcorn et al., 2003). The established treatment for epiretinal membranes involves pars plana vitrectomy (Geerts et al., 2004).

Another ocular disorder is the macular hole, which primarily affects elderly women (La Cour and Friis, 2002). A macular hole results from an opening in the retina at the fovea causing loss of central vision (Cavallerano and Woodcome, 1994). Idiopathic macular holes are thought to have several possible etiologies, such as changes in the retinal vasculature or traction from shrinking vitreous in elderly patients causing tearing of the retina (Ho et al., 1998), the latter potentially induced by a thin epiretinal membrane (Bresgen and Heimann, 1995). Growth factors such as GH and IGF-1 may play a role in the disorder (Kmera-Muszynska and Zgliczynski, 2000), and treatment with TGF-beta 2 can improve visual acuity and promote flattening of the retina (Glaser et al., 1992; Smiddy et al., 1993).

A third ocular disorder involves retinal detachment. As its name suggests, retinal detachment involves detachment of the neural retina from its epithelium. Detachment can occur following trauma, while in the elderly, detachment can be caused by traction of the vitreous. In some 5-10% of cases, proliferative vitreoretinopathy disallows the reattachment of the detached retina (Asaria and Charteris, 2006). The presence of this neovascularization implicates growth factors, among them IGF-1 (van Setten et al.,

2002), TGF-beta 2, bFGF, and interleukins (Kon et al., 1999). Treatment of retinal detachment is surgical, involving pars plana vitrectomy, laser treatment, and intraocular injection of gas (Brucker and Hopkins, 2006).

A. Diabetic Retinopathy (DR)

1. Etiology

DR is a major ocular complication of diabetes mellitus, whose progression is multifactorial and complex. It usually begins to manifest approximately 5 years after clinical onset of diabetes and can usually be readily observed 15-25 years after onset (Lundbaek et al., 1971). It is an ocular disorder initially characterized by non-proliferative DR, involving retinal edema, breakdown of the BRB, microaneurysms, and other microvascular abnormalities (Funatsu et al., 2006) and leads to proliferative DR (PDR), involving neovascularization of the retina along with hemorrhaging and possible retinal detachment (Chiarelli et al., 2005; Funatsu et al., 2006). This neovascularization stems from local ischemia in retinal capillaries and subsequent alteration of growth factor levels (Das and McGuire, 2003). Angiogenesis occurs in the retina following a disruption in the balance between angiogenesis stimulators such as VEGF and IGF-1, and angiogenesis inhibitors such as pigment epithelium-derived factor (PEDF) and angiostatin (Funatsu et al., 2006). A host of such growth factors have been implicated in the etiology of DR, including GH (Frystyk, 2005), IGF-1 (Meyer-Schwickerath et al., 1993), and VEGF (Adamis et al., 1994), and risk factors for DR include hypertension, hyperlipidemia, smoking, and poor metabolic control (Chiarelli et al., 2005).

2. Treatment

Hypophysectomy and replacement of all hormones except GH was used as an early treatment for DR. This fell out of favour as a viable treatment since it led to fatal hypoglycemia (Zimmerman and Molnar, 1977) and was replaced with laser photocoagulation therapy along with strict control of blood sugar, lipids, and pressure (Boehm, 2007). Given the supposed role of serum GH in the progression of DR, somatostatin and antagonists of the GH receptor have been therapeutic targets for DR. Somatostatin analogues, which reduce serum GH levels, met with initial success in inhibiting progression of PDR and reducing vascularization in some cases (McCombe et al., 1991). Subsequent studies have confirmed the effectiveness of analogues such as octreotide (Lang, 2004), especially in the nonproliferative or early proliferative stages (Grant et al., 2000). These analogues are currently the best option for patients who fail to respond to photocoagulation therapy (Boehm, 2007). GH antagonists, on the other hand, have thus far been unsuccessful in stopping progression or inducing regression of DR (Growth Hormone Antagonist for Proliferative Diabetic Retinopathy Study Group, 2001).

F. Summary

GH is a peptide hormone secreted by the pituitary gland into the bloodstream, exerting its effects as an endocrine hormone and becoming involved in many processes such as growth and metabolism (Harvey et al., 1995). With the discovery of local, extrapituitary GH production in tissues throughout the body, the possibility is raised of local autocrine/paracrine effects of GH (Harvey et al., 1997). Both elevated and decreased levels of circulating GH have been implicated in the etiology of various ocular disorders,

such as DR (Powell et al., 1966) and macular holes (Kmera-Muszynska and Zgliczynski, 2000). The role of circulating and extrapituitary GH in the human vitreoretinal space in the etiology of various ocular diseases has not, to date, been assessed. As other peptide factors residing in the vitreous have been linked to ocular disease, such as IGF-1 (Simo et al., 2003) and VEGF (Funatsu et al., 2002b), GH in the vitreous may similarly be a marker of ocular disease. This possibility will be assessed in the present study by determining the presence of GH in the human retina and vitreous and the concentration of GH in the vitreous of controls and patients with ocular disease. As GH action may be IGF-1 dependent, levels of IGF-1 in the vitreous of controls and patients with ocular disease will also be assessed.

G. Hypothesis and Aims

GH in the retina and vitreous of adult humans, either from the circulation or from local, extrapituitary production may be a marker of ocular disease. This possibility will be assessed by determining the presence and concentration of GH in adult human vitreous in relation to the incidence of various types of ocular disease. Levels of circulating and vitreous GH will be compared with those in subjects with no history of ocular disease. Changes in vitreous GH may also be related to changes in IGF-1 concentration in the vitreous, thus the relationship between GH and free IGF-1 levels in the vitreous of individuals with and without ocular disease will also be compared.

II. MATERIALS AND METHODS

A. Vitreous samples

Vitreous samples were obtained via standard pars plana vitrectomy – a surgical technique involving removal of the vitreous by introducing an aspirator/cutter tool and local light source into the eye through the pars plana – from patients at the Royal Alexandra Hospital (Edmonton, AB, Canada) by Dr. Matt Tennant, Dr. Mark Greve and Dr. Bradley Hinz. Ethics approval was obtained for the study and informed written consent was obtained from patients enrolled in the study. Samples were collected in sterile tubes, clarified by centrifugation at 13,000 g for 5 min at 4°C, and stored at -80°C prior to use. The study included patients with both insulin-dependent (IDDM; n=12) or non-insulin-dependent diabetes mellitus (NIDDM; n=14). Diabetic patients had proliferative DR (PDR; n=18) or other ocular disorders (n=8; Table 1). The study also included non-diabetic patients requiring vitrectomy for other, non-diabetic ocular conditions (n=44), comprising epiretinal membrane (n=11), retinal detachment (n=12), macular hole (n=11), vitreous hemorrhage (n=3), subretinal hemorrhage (n=2), central retinal vein occlusion (n=1), vitreous opacity/debris (n=2), and dislocated lens (n=2; Table 2). Cadaverous vitreous samples from individuals with no known history of ocular disease were obtained via the comprehensive tissue centre of the University of Alberta Hospital and served as controls (n=15; Table 3). All donor eyes were screened and had their corneas and scleras accepted for transplantation. Diabetic (including IDDM and NIDDM groups), non-diabetic (including groups of those with epiretinal membrane, macular hole, and retinal detachment), and control groups were age and gender matched. Mean age of diabetics with IDDM was 49 ± 5.7 years, mean age of diabetics with NIDDM was 65 ± 3.6 years,

mean age of non-diabetics with ocular disease was 57 ± 2.2 years, and mean age of controls was 54.6 ± 3.2 years. The mean of all samples was 58.0 ± 1.8 years.

B. Vitreous Hemorrhage

Blood contamination in some vitreous samples can introduce a variable in the analysis of vitreal protein levels. As erythrocytes have roughly double the concentration of protein compared to serum protein levels (Simo et al., 2003), total vitreal proteins were therefore corrected for vitreous hemoglobin (Hb). Total vitreous proteins were adjusted for vitreal hemoglobin as described by Ambati et al. (1997):

$$P_{\text{corrected}} = (P_{\text{measured}} \times Hb_{\text{blood}}) - (P_{\text{blood}} \times Hb_{\text{vitreous}}) / (Hb_{\text{blood}} - Hb_{\text{vitreous}})$$

(where $P_{\text{corrected}}$ is the concentration of corrected vitreous proteins, P_{measured} is the total vitreal protein measured by dye-binding assay, Hb_{blood} is the hemoglobin concentration in blood, P_{blood} is the protein concentration of blood plasma, and Hb_{vitreous} is the hemoglobin concentration in vitreous, all expressed as $\mu\text{g}/\text{uL}$). $P_{\text{corrected}}$ was used in subsequent statistical analyses. Where plasma hemoglobin values could not be obtained, the concentration of corrected total vitreous protein was calculated by subtracting the concentration of vitreous HgB from the concentration of total vitreous protein. In the same sample, results obtained with this calculation were comparable to those with the equation above.

Vitreous hemoglobin levels were determined using the method of Harboe (Harboe, 1959), which has been validated for measuring micromolar concentrations of hemoglobin (Fairbanks et al, 1992). Vitreous samples were diluted with deionized distilled water to lyse erythrocytes, vortexed for 10 seconds, and sonicated for 3 seconds to further disrupt erythrocyte plasma membranes. Following centrifugation at 12,500 g for 5 minutes at 4°C, absorbance was read at 415, 380, and 450 nm with a spectrophotometer (Ultrospec 2000, Amersham Pharmacia Biotech, Uppsala, Sweden). Vitreous hemoglobin concentration was computed as described by Fairbanks et al. (1992):

$$X = DF[1.65(A_{415}) - 0.93(A_{380}) - 0.73(A_{450})]$$

where X is the concentration of vitreous hemoglobin in µg/uL, DF is the dilution factor used, and A is the absorbance at each wavelength.

C. Blood samples

Venous blood from diabetics and non-diabetics with ocular disease was collected at the time of vitreoretinal surgery in sterile tubes containing heparin sulfate as an anti-coagulant. Mean age of patients with IDDM was 49 ± 5.6 years, mean age of patients with NIDDM was 66 ± 3.5 years, and mean age of non-diabetics with ocular disease was 59 ± 2.5 years. Control plasma samples (n=8) were drawn from non-diabetic volunteers with no known history of ocular disease or ocular surgery (Table 4). Mean age of controls was 55.6 ± 1.4 years. The mean age of all samples was 59.6 ± 2.0 years. All blood donors were fasting for at least 12 hours prior to collection, and all collections were by medical

staff between 7 am – 3 pm. Blood hemoglobin was assessed using 20 μ L of whole blood in 5 mL Drabkin's reagent (Sigma-Aldrich, St. Louis, MI), mixed and incubated at room temperature for at least 15 minutes, the absorbance of the solution measured at 540 nm (Ultrospec 2000, Amersham Pharmacia Biotech, Uppsala, Sweden), and the value compared to a standard reference graph. Blood was centrifuged at approx. 1085 g (Coolspin 2, MSE, London, UK) for 10 min at 4°C to obtain plasma, which was aliquoted and stored at -20°C until assayed. Following thawing and prior to assay, plasma samples were clarified by centrifugation at 12,500 g for 5 minutes at 4°C.

D. Protein assay

Total protein concentration was determined in duplicate (5 μ L aliquots) with a dye-binding protein assay (Bio-Rad Laboratories, Mississauga, ON) using bovine serum albumin (BSA) as the standard. Absorbance at 595 nm was measured using a spectrophotometer (Multiskan Ascent, Thermo Electron Corporation, Vantaa, Finland). The sensitivity of the assay was 40.0 ng/ μ L, obtained by calculating the mean plus 3 standard deviations of the zero standard, loaded 8 times in replicate.

E. Western Immunoblotting

Vitreous samples were mixed with sample buffer (10% [w/v] glycerol, 0.5% [w/v] 2- β -mercaptoethanol, 0.4% [w/v] SDS, 0.001% [w/v] bromophenol blue at pH 6.8) and loaded onto polyacrylamide gels. Some vitreous samples required concentrating prior to Western immunoblot analysis. Samples were concentrated using a Nanosep device with a molecular weight cutoff of 10 kDa (Pall Corporation, Mississauga, Ontario), with the

retentate used for Western immunoblot analysis. Proteins were separated by sodium dodecyl sulfate polyacrylamide gel electrophoresis (SDS-PAGE) under reducing conditions. Broad-range molecular markers (Bio-Rad) and positive loading control corresponding to pure recombinant GH (National Institutes of Health, Bethesda, MD) were also loaded. Proteins were then transferred via electrophoresis to a nitrocellulose membrane (0.45 μ m pore size; Bio-Rad) in transfer buffer (25 mM Tris, 192 mM glycine, 20% [w/v] methanol) at 100V for 1 h 20 min. After transfer, non-specific binding sites were blocked with 5% (w/v) nonfat dry milk in Tris-buffered saline (TBS; [25 mM Tris HCl, 0.5 M NaCl at pH 7.6]) containing Tween-20 (TTBS) for 1 h at room temperature. Characterization of GH was performed on membranes transferred from 8% gels. GH immunoreactivity was detected using a polyclonal antibody raised in goat against hGH (R&D Systems, Minneapolis, MN) diluted 1:50 in TTBS/5% nonfat dry milk.

In some experiments, GH antibody was pre-absorbed with recombinant GH (NIH, Bethesda, MD) for at least 3.5 hours in an ice bath prior to incubation with the membrane, in an antigen:antibody ratio of 150:1. Following an overnight incubation at 4°C, the membrane was washed with TTBS (3x for 5 minutes each) and then incubated for 1.5 hours at room temperature with secondary biotinylated rabbit anti-goat IgG (Sigma, St. Louis, MO) diluted 1:2000 in TTBS/5% nonfat dry milk. Incubation of the membrane with only secondary antibody served as a negative control. Immunoreactivity was visualized using ABC reagents (Vector Laboratories) at room temperature. After washing, the blots were developed using an enhanced chemiluminescence detection system (ECL kit; Amersham) and exposed to Kodak X-AR film.

F. GH Enzyme-Linked ImmunoSorbent Assay (ELISA)

GH levels in blood plasma and vitreous were measured using an ultrasensitive hGH ELISA kit, 22-hGH-E022 (ALPCO, Salem, NH), suitable for measuring hGH concentration in blood serum and plasma. 100 μ L of GH calibrators (0.05, 0.15, 0.3, 0.6, and 1 ng/mL) along with control serum and neat, undiluted vitreous and plasma samples were loaded onto the wells of a microtiter plate pre-coated with high affinity polyclonal rabbit antiserum. After a 2 hour incubation at room temperature on a shaker (350 RPM), the wells were washed manually with a vacuum aspirator (3x) and a biotinylated anti-hGH antibody was added to the wells. Following incubation for 1 hour at room temperature, horseradish peroxidase (HRP)-labelled Streptavidin was added. This was followed by a third incubation of 30 minutes at room temperature. The wells were again washed (3x) and a 3,3', 5,5' tetramethylbenzidine (TMB) substrate solution was added to the wells and allowed to react with the HRP. Wells were incubated for 10 minutes at room temperature in the dark. The reaction was stopped with a solution of 0.2 M sulfuric acid and the colour reaction measured spectrophotometrically (Multiskan Ascent, Thermo Electron Corporation, Vantaa, Finland) at a wavelength of 450 nm with a reference wavelength of 620 nm. The kit reports specificity to human GH with no cross-reactivity with prolactin. The measured sensitivity of the kit was 6.3 pg/mL. Interassay coefficients of variance were 8.1% at 0.39 ng/mL over 9 assays and 5.2% at 0.01 ng/mL over 3 assays. The intra-assay coefficients of variance were 1% at 0.39 ng/mL from 6 replicates, 2.5% at 0.01 ng/mL from 8 replicates, and 2% at 6.3 pg/mL from 4 replicates.

G. Free IGF-1 ELISA

In addition to GH and for comparison, levels of free IGF-1 in blood plasma and vitreous were measured with an ultrasensitive free IGF-1 ELISA kit, DSL-10-9400 (Diagnostic Systems Laboratories, Webster, TX), suitable for measuring the concentration of free IGF-1 and readily dissociable IGF-1 in blood plasma. This kit has also been used for quantifying free IGF-1 in human vitreous (Simo et al., 2003) and saliva (Antonetti et al., 2007). Microtiter wells coated with a monoclonal free IGF-1 antibody were loaded with 20 μ L of buffer and 50 μ L of free IGF-1 standards (0, 0.05, 1.6, 3, and 9 ng/mL), two control serum samples, and neat, undiluted vitreous and plasma samples. Wells were incubated for 1 hour at room temperature on a shaker (350 RPM). The wells were then washed manually with a vacuum aspirator (5x). 100 μ L of a solution of IGF-1 antibody conjugated to horseradish peroxidase was added to each well, followed by a 30 minute incubation at room temperature on a shaker (350 RPM). Following washing of the wells (5x), 100 μ L of TMB substrate was added and allowed to incubate for 10 minutes at room temperature in the dark and on a shaker (350 RPM). The reaction was stopped with 0.2 M sulfuric acid (100 μ L) added to each well, and the colour reaction was measured spectrophotometrically (Multiskan Ascent, Thermo Electron Corporation, Vantaa, Finland) at a wavelength of 450 nm with a reference wavelength of 620 nm. The kit reports no cross-reactivity with free IGF-II, insulin, or IGFBP-1 and -3. The measured sensitivity of the kit was 44.4 pg/mL, obtained by calculating the mean plus 2 standard deviations of the zero standard, loaded 8 times in replicate. Interassay coefficients of variance were 12% at 3.5 ng/mL over 3 assays and 19.7% at 0.3 ng/mL over 3 assays. The intra-assay coefficient of variance was 7.6% at 3.5 ng/mL from 6 replicates.

H. Statistical analysis

Groups were compared using a Kruskal-Wallis non-parametric test, as the levels of uncorrected vitreous and plasma GH/IGF-1 and protein-corrected vitreous GH/IGF-1 were not normally distributed. *Post hoc* analysis was performed using Dunn's multiple comparison test. Statistical significance was set at $p < 0.05$. All results were reported as mean values \pm the standard error of the mean (SEM).

Correlations were examined using Spearman's rank correlation test. Data were not logarithmically transformed prior to analysis. All statistical analyses were performed using Prism and InStat (Graphpad, San Diego, CA).

Tables

Table 1 – Sample information for diabetic patients with ocular disease, sorted by age.

Sample	Type	Age	Gender	Diagnosis	Vit [protein] (µg/uL)**	Vit [GH] (pg/mL)	Vit [GH] / Vit [protein]** (pg/mg)	Plasma [GH] (ng/mL)	Vit [free IGF-1] (ng/mL)	Vit [free IGF-1] / Vit [protein]** (pg/mg)	Plasma [free IGF-1] (ng/mL)
N53	IDDM	27	M	PDR, Vit hemorrhage	0.62	12.3	20.0	0.99	0.10	155.61	0.57
N69	IDDM	32	M	PDR	1.76	21.4	12.2	N/A	N/D	N/D	N/A
N18	IDDM	34	M	PDR, Vit hemorrhage	5.88	40.0	6.8	N/A	N/D	N/D	N/A
N27	IDDM	34	F	PDR, Vit hemorrhage	2.42	155.0	64.0	5.10	N/D	N/D	N/D
N38	IDDM	34	F	PDR, Vit hemorrhage	2.09	6.4	3.1	0.05	0.12	55.36	0.07
N72	NIDDM	35	M	PDR, Vit hemorrhage	11.65	17.8	1.5	0.01	N/D	N/D	N/D
(48.1)*	IDDM	40	F	PDR, Vit hemorrhage	N/A	N/A	N/A	1.92	N/A	N/A	0.19
N44	NIDDM	48	M	PDR, Vit hemorrhage	3.25	6.4	2.0	0.01	N/D	N/D	N/D
N54	IDDM	48	F	PDR, Vit hemorrhage	3.14	6.4	2.1	0.06	0.14	43.16	0.72
N65	IDDM	54	M	PDR, Vit hemorrhage	1.23	6.4	5.2	N/A	N/D	N/D	N/A
N8	NIDDM	55	M	PDR, Vit hemorrhage	1.95	6.4	3.3	N/A	N/D	N/D	N/A
N39	IDDM	55	F	PDR, Vit hemorrhage	5.17	6.4	1.2	0.05	0.28	54.63	1.02
N37	NIDDM	60	F	PDR, Vit hemorrhage	1.65	6.4	3.9	0.40	0.93	564.98	0.79
N66	NIDDM	60	F	PDR, Vit hemorrhage	2.16	11.3	5.2	0.05	N/D	N/D	N/D
N49	IDDM	63	F	Epiretinal membrane w/ macular edema	0.88	6.4	7.3	0.08	0.16	176.70	1.50
N45	NIDDM	67	F	Epiretinal membrane	3.44	6.4	1.9	0.03	0.16	46.13	1.85
N28	IDDM	68	F	RD	0.55	6.4	11.7	0.20	0.04	80.38	0.55
N16	NIDDM	70	M	PDR, Vit hemorrhage	1.26	61.0	48.3	1.16	N/A	N/A	N/A
N68	NIDDM	70	F	Epiretinal membrane	0.04	11.3	282.2	0.12	N/D	N/D	N/D
(35.1)*	NIDDM	71	M	PDR, Vit hemorrhage	N/A	N/A	N/A	0.06	N/A	N/A	1.07
N70	NIDDM	71	M	PDR, Vit hemorrhage	2.26	21.1	9.3	0.67	N/D	N/D	N/D
N43	NIDDM	72	F	Vit Hemorrhage	2.64	6.4	2.4	0.04	0.16	59.98	0.08
N25	IDDM	74	M	PDR, Vit Hemorrhage	1.74	6.4	3.7	0.05	0.17	94.72	0.41
N34	NIDDM	77	M	Epiretinal membrane	0.96	6.4	6.7	0.11	0.15	156.49	0.28
N71	NIDDM	78	M	Wound	0.84	6.4	7.7	0.03	N/D	N/D	N/D
N59	NIDDM	79	M	Subretinal hemorrhage	1.39	6.4	4.6	0.11	0.15	104.44	0.68

* Plasma samples only

** After correcting for vitreous hemoglobin

PDR = Proliferative diabetic retinopathy, RD = Retinal detachment, N/A = Not applicable, N/D = Not determined

Table 2 – Sample information for non-diabetic patients with various ocular disorders, sorted by age.

Sample	Age	Gender	Diagnosis	Vit [protein] (µg/uL)*	Vit [GH] (pg/mL)	Vit [GH] / Vit [protein]* (pg/mg)	Plasma [GH] (ng/mL)	Vit [free IGF-1] (ng/mL)	Vit [free IGF-1] / Vit [protein]* (pg/mg)	Plasma [free IGF-1] (ng/mL)
N60	21	M	Subretinal hemorrhage	1.61	6.4	4.0	0.20	0.18	109.1	4.31
N31	37	F	Vitreous debris	0.22	6.4	29.8	1.60	0.13	581.5	1.09
N24	38	M	Recurrent RD	0.93	495.4	532.2	0.02	N/D	N/D	3.09
N46	39	M	RD	0.52	6.4	12.3	0.14	0.13	240.8	3.48
N73	45	M	RD	1.23	6.4	5.2	0.02	N/D	N/D	N/D
N50	46	M	CRVO	2.14	6.4	3.0	0.01	3.32	1398.0	0.90
N47	47	M	MH	0.23	6.4	27.4	0.03	0.11	451.2	1.23
N57	47	M	Vit hemorrhage	0.19	6.4	33.6	0.11	0.04	232.0	1.68
N74	47	M	ERM (aqueous from anterior chamber)	5.03	6.4	1.3	0.01	N/D	N/D	N/D
N12	49	M	Full thickness MH	0.24	6.4	26.4	N/A	0.04	182.3	N/A
N64	49	M	RD + Full thickness MH	10.68	7.5	0.7	0.11	N/D	N/D	N/D
N67	50	M	RD + optic nerve pit (congenital)	0.20	6.4	32.8	0.02	N/D	N/D	N/D
N35	51	M	RD	0.90	23.4	26.0	0.33	N/D	N/D	N/D
N56	53	M	RD	0.72	6.4	8.9	0.69	0.04	61.5	3.28
N51	55	M	RD	0.72	6.4	8.9	0.42	0.04	61.5	0.97
N58	55	F	Full thickness MH	0.90	6.4	7.2	0.14	0.06	70.7	2.98
N21	58	F	Full thickness MH	0.30	6.4	21.7	0.37	0.10	323.4	1.49
N11	61	M	Dislocated crystalline lens	0.66	52.5	79.5	N/A	N/D	N/D	N/A
N33	63	M	RD	1.15	6.4	5.6	0.02	0.21	179.0	1.16
N42	63	M	RD	0.18	6.4	36.5	0.31	0.09	527.9	1.88
N20	64	F	MH	0.21	6.4	31.2	0.04	N/D	N/D	N/D
N15	65	F	MH	0.38	76.0	201.1	N/A	0.04	117.4	N/A
N29	66	F	Vit hemorrhage (vein occlusion)	0.67	6.4	9.6	0.60	0.07	89.4	0.91
N40	66	M	ERM w/ pseudo MH	0.12	7.4	62.9	0.02	N/D	N/D	N/D
N2	67	M	ERM	2.80	577.5	206.3	N/A	N/D	N/D	N/A
N26	67	F	ERM	0.44	6.4	14.5	0.05	0.08	172.3	1.28
N36	67	F	Vit Hemorrhage	2.70	6.4	2.4	0.66	0.24	90.5	N/D
N61	67	M	RD	1.19	15.2	12.8	0.04	0.23	193.1	2.08

(Continued on next page)

(Continued from previous page)

N32	69	M	ERM	0.68	6.4	9.5	0.81	0.29	429.4	1.82
N62	70	M	Vitr opacity	2.04	6.4	3.1	0.31	0.22	105.5	N/D
N10	71	M	ERM	3.25	587.5	180.8	N/A	0.26	78.5	N/A
N19	71	F	MH	0.48	6.4	13.5	N/A	0.05	102.0	N/A
N30	71	F	ERM	0.69	6.4	9.3	0.11	0.17	253.8	1.56
N13	72	F	ERM	0.84	8.0	9.6	N/A	0.04	53.1	N/A
N14	73	M	ERM	0.68	124.0	182.9	N/A	0.08	115.3	N/A
N23	73	M	ERM w/ pseudo MH	1.87	6.4	3.4	0.15	0.12	61.9	1.45
N22	74	F	RD	1.55	6.4	4.2	0.09	0.10	62.0	0.40
N41	74	F	Full thickness MH	0.04	6.4	314.3	0.06	0.12	115.7	3.00
N55	74	M	Dislocated crystalline lens	3.42	6.4	1.9	0.23	0.12	35.3	2.26
N9	78	M	MH	0.60	6.4	10.7	N/A	0.04	110.9	N/A
N63	79	F	Subretinal hemorrhage	1.13	6.4	5.7	0.01	N/D	N/D	N/D
N52	82	F	ERM	0.59	6.4	10.9	0.07	0.62	1048.0	3.32
N48	87	M	Full thickness MH	0.60	6.4	10.7	0.72	0.21	357.2	1.85
N6	91	F	Full thickness MH	0.95	6.4	6.8	N/A	0.04	46.6	N/A

38

* After correcting for vitreous hemoglobin

RD = Retinal detachment, ERM = Epiretinal membrane, MH = Macular hole, CRVO = Central retinal vein occlusion, N/A = Not applicable, N/D = Not determined

Table 3 – Sample information for samples of control vitreous from cadavers with no known history of ocular disease, sorted by age.

Sample	Age	Gender	Vit [protein] (µg/uL)	Vit [GH] (pg/mL)	Vit [GH] / Vit [protein] (pg/mg)	Vit [free IGF-1] (ng/mL)	Vit [free IGF-1] / Vit [protein] (pg/mg)
D	39	M	0.28	25.8	90.9	N/D	N/D
M	39	M	0.77	56.3	72.9	N/D	N/D
N	44	M	0.31	53.6	171.0	N/D	N/D
O	44	M	1.31	77.2	58.8	N/D	N/D
A	50	F	0.37	27.2	73.1	0.10	272.7
G	50	F	0.77	59.1	76.5	0.18	235.9
K	56	F	0.11	6.4	59.8	0.13	1172.4
E	57	M	0.29	33.8	115.0	0.04	151.1
H	57	F	0.70	117.8	167.1	0.04	63.0
F	67	M	0.46	28.2	61.3	0.08	165.1
C	67	M	1.06	17.8	16.7	N/A	N/A
L	70	F	1.14	79.2	69.8	0.35	307.9
B	70	F	1.65	50.1	30.2	N/A	N/A
I	?	F	0.61	90.4	148.9	0.32	527.2
J	?	F	0.43	76.8	178.4	0.20	460.0

N/A = Not applicable, N/D = Not determined

Table 4 – Sample information for samples of control plasma from volunteers with no known history of ocular disease or DM, sorted by age.

Sample	Age	Gender	Plasma GH (ng/mL)
C25.1	50	M	0.03
C4.1	52	M	0.05
C23.1	52	F	0.03
C12.1	55	M	0.07
C6.1	57	M	0.01
C26.1	58	F	0.03
C21.1	60	M	0.03
C11.1	61	F	0.12

III. RESULTS

A. Western Immunoblots

Growth hormone (GH) immunoreactivity in adult human vitreous and retina was characterized by Western immunoblotting (Figures 1-3). As expected, GH immunoreactivity in a 10 ng sample of the human GH (hGH) standard was associated with protein bands at 22 kDa and 45 kDa, corresponding to monomer and dimer GH, respectively (Figure 1A). In a sample of vitreous collected from a male cadaver aged 67 with no known history of ocular disease, GH immunoreactivity was associated with several protein bands, including those at 22 kDa and 45-48 kDa (Figure 1A). Definitive measurement of band size larger than 50 kDa was extremely difficult due to the polyacrylamide gel concentration used (8%). This concentration gave the best results for characterizing both lower molecular weight (22 kDa) and mid-range molecular weight (45-48 kDa) bands. These immunoreactive protein bands disappeared following pre-absorption of the primary antibody with recombinant human GH (hGH), in an antigen:antibody ratio of 150:1 (Figure 1B). In human retina from a male cadaver aged 57 with no known history of ocular disease, GH immunoreactive bands of approximate size 22 kDa and 45 kDa were also characterized (Figure 2). GH immunoreactive bands at approximately 22 kDa and 45 kDa were also characterized in vitreous collected from an 80 year old female patient with diabetes (Figure 3, lane 1) and an 81 year old male non-diabetic patient with epiretinal membrane (Figure 3, lane 2). Incubation of the membrane with secondary antibody only did not reveal immunoreactive bands (data not shown). All figures were representative of at least three immunoblots of the same sample. Figures 2 and 3 courtesy of Dr. Esmond Sanders and Ewa Parker, University of Alberta.

B. ELISAs

Following analysis of ELISA data using the Kruskal-Wallis nonparametric test and *post hoc* comparison of groups using Dunn's multiple comparison test, statistically significant results are summarized in Tables 5 and 6. All analyses involved age and gender-matched groups and were presented as means \pm standard error of the mean (SEM). Control subjects had a mean uncorrected vitreous GH level of 48.6 ± 8.4 pg of GH/mL of vitreous and a mean protein-corrected vitreous GH level of 0.08 ± 0.01 ng of GH/mg of vitreous protein corrected for hemoglobin. Non-diabetics with ocular disease had a mean uncorrected vitreous GH level of 58.1 ± 27.1 pg/mL and a mean protein-corrected vitreous GH level of 0.05 ± 0.02 ng/mg. Diabetics with ocular disease had a mean uncorrected vitreous GH level of 16.7 ± 4.9 pg/mL and a mean protein-corrected vitreous GH level of 0.02 ± 0.01 ng/mg. Patients with diabetes had higher levels of hemoglobin-corrected vitreal protein than both controls (2.5 ± 0.5 ng/mL versus 0.7 ± 0.1 ng/mL, $p < 0.05$) and non-diabetics with ocular disease (2.5 ± 0.5 ng/mL versus 1.3 ± 0.3 ng/mL, $p < 0.05$; Figure 4). However, controls had higher levels of uncorrected and protein-corrected vitreous GH than diabetics (48.6 ± 8.4 pg/mL versus 16.7 ± 4.9 pg/mL, $p < 0.01$ and 0.08 ± 0.01 ng/mg versus 0.02 ± 0.01 , $p < 0.001$; Figures 5 and 6). Patients with IDDM had lower levels of protein-corrected vitreous GH than controls (0.01 ± 0.005 versus 0.08 ± 0.01 , $p < 0.01$; Figure 6) and patients with NIDDM had lower levels of both uncorrected and protein-corrected vitreous GH than controls (11.8 ± 6.4 pg/mL versus 48.6 ± 8.4 pg/mL and 0.02 ± 0.01 versus 0.08 ± 0.01 , both at $p < 0.01$; Figures 5 and 6). Non-diabetic patients with ocular disease had higher levels of uncorrected vitreous GH than

controls (58.1 ± 27.1 pg/mL versus 48.6 ± 8.4 pg/mL, $p < 0.001$; Figure 5) but controls had higher levels of protein-corrected GH than non-diabetics (0.08 ± 0.01 versus 0.05 ± 0.02 , $p < 0.05$; Figure 6). Within the group of non-diabetics with ocular disease, patients with macular holes had lower levels of uncorrected vitreous GH than controls (15.1 ± 8.7 pg/mL versus 48.6 ± 8.4 pg/mL, $p < 0.05$; Figure 5). Diabetics with proliferative DR (PDR) had no statistically significant differences in uncorrected and protein-corrected vitreous GH compared to diabetics with no PDR (Figure 7).

Despite differences in vitreous GH concentrations, there were no statistically significant differences in plasma GH levels among all groups tested (Figure 8). Control subjects had a mean plasma GH level of 45.1 ± 13.2 pg/mL and diabetics had a mean plasma GH level of 0.5 ± 0.2 ng/mL. Diabetics with IDDM had a mean plasma GH level of 0.9 ± 0.6 ng/mL, and diabetics with NIDDM had a mean plasma GH level of 0.2 ± 0.09 ng/mL.

Controls had a mean uncorrected vitreous free IGF-1 level of 0.1 ± 0.04 ng/mL and a mean protein-corrected vitreous free IGF-1 level of 0.3 ± 0.1 ng/mg. Non-diabetics with ocular disease had a mean uncorrected vitreous free IGF-1 level of 0.3 ± 0.1 ng/mL, a mean protein-corrected vitreous free IGF-1 level of 0.3 ± 0.06 , and a mean plasma free IGF-1 level of 2.0 ± 0.2 ng/mL. Diabetics with ocular disease had a mean uncorrected vitreous free IGF-1 level of 0.2 ± 0.07 ng/mL, a mean protein-corrected vitreous free IGF-1 level of 0.1 ± 0.04 , and a mean plasma free IGF-1 level of 0.7 ± 0.1 ng/mL. There were no statistically significant differences in uncorrected and protein-corrected vitreous free IGF-1 levels among the groups tested (Figures 9 and 10). However, non-diabetics

with ocular disease (mean of 2.0 ± 0.2 ng/mL) and specifically those with retinal detachment (mean of 2.3 ± 0.4 ng/mL) had higher levels of plasma free IGF-1 than both diabetics (mean of 0.7 ± 0.1 ng/mL, $p < 0.01$; Figure 11) and those specifically with IDDM (mean of 0.6 ± 0.2 ng/mL, $p < 0.05$; Figure 11).

Statistically significant correlations obtained via the Spearman non-parametric correlation are summarized in Table 6. A positive linear correlation was observed between uncorrected vitreous GH and plasma GH levels ($r = 0.5199$, $p < 0.05$, $n = 20$; Figure 14) and between protein-corrected vitreous GH and plasma GH levels ($r = 0.7910$, $p < 0.0001$, $n = 20$) in patients with diabetes. In non-diabetic patients with ocular disease, however, there were no correlations between plasma GH levels and uncorrected vitreous GH ($r = -0.1798$) or protein-corrected vitreous GH ($r = -0.0410$) levels. There was no correlation between total uncorrected vitreous protein and uncorrected vitreous GH in controls ($r = 0.4665$), non-diabetics with ocular disease ($r = 0.2076$; Figure 12), or diabetics ($r = -0.0614$; Figure 13). There was likewise no correlation between uncorrected vitreous GH and uncorrected vitreous free IGF-1 in controls ($r = 0.2594$), non-diabetics with ocular disease ($r = -0.0251$), or diabetics ($r = -0.3930$). There was a positive linear correlation between protein-corrected vitreous free IGF-1 and protein-corrected vitreous GH levels in non-diabetics with ocular disease ($r = 0.4073$, $p < 0.05$, $n = 33$) and in diabetics ($r = 0.7483$, $p < 0.01$, $n = 12$), although no such correlation was present in controls ($r = -0.2167$). In plasma, there was no correlation between GH and free IGF-1 levels in non-diabetics with ocular disease ($r = 0.0904$) or in diabetics ($r = 0.0165$).

Table 5 – Statistically significant differences in total corrected vitreous protein (corrected for hemoglobin), uncorrected vitreous GH, protein-corrected vitreous GH and plasma free IGF-1 grouped by ocular conditions.

Comparison	Total corrected vitreous protein		Uncorrected vitreous GH		Protein-corrected vitreous GH		Plasma free IGF-1	
	p value	Summary	p value	Summary	p value	Summary	p value	Summary
C vs DM	p < 0.05	* (DM > C)	p < 0.01	** (C > DM)	p < 0.001	*** (C > DM)	p > 0.05	ns
C vs IDDM	p > 0.05	ns	p > 0.05	ns	p < 0.01	** (C > IDDM)	p > 0.05	ns
C vs NIDDM	p > 0.05	ns	p < 0.01	** (C > NIDDM)	p < 0.01	** (C > NIDDM)	p > 0.05	ns
C vs ND	p > 0.05	ns	p < 0.001	*** (ND > C)	p < 0.05	* (C > ND)	p > 0.05	ns
C vs MH	p > 0.05	ns	p < 0.05	* (C > MH)	p > 0.05	ns	p > 0.05	ns
DM vs ND	p < 0.05	* (DM > ND)	p > 0.05	ns	p > 0.05	ns	p < 0.01	** (ND > DM)
DM vs RD	p > 0.05	ns	p > 0.05	ns	p > 0.05	ns	p < 0.01	** (RD > DM)
IDDM vs ND	p > 0.05	ns	p > 0.05	ns	p > 0.05	ns	p < 0.05	* (ND > IDDM)
IDDM vs RD	p > 0.05	ns	p > 0.05	ns	p > 0.05	ns	p < 0.05	* (RD > IDDM)

C = Controls, ND = Non-diabetic with ocular disorders, DM = Diabetes mellitus, IDDM = Insulin-dependent diabetes mellitus, NIDDM = Non-insulin-dependent diabetes mellitus, MH = Macular hole, ns = Not significant

* = p < 0.05, ** p < 0.01, *** = p < 0.001

Table 6 – Statistically significant correlations between vitreous and plasma GH and free IGF-1.

Correlation	C		ND		DM	
	r value	p value and correlation	r value	p value and correlation	r value	p value and correlation
Uncorrected vitreous GH vs Plasma GH	N/A	N/A	-0.1798	ns	0.5199	p < 0.05, positive
Protein-corrected vitreous GH vs Plasma GH	N/A	N/A	-0.0410	ns	0.7910	p < 0.0001, positive
Protein-corrected vitreous free IGF-1 vs protein-corrected vitreous GH	-0.2617	ns	0.4073	p < 0.05, positive	0.7483	p < 0.01, positive

C = Controls, ND = Non-diabetics with ocular disorders, DM = Diabetes mellitus, ns = Not significant.
 N/A = Not applicable

Figures

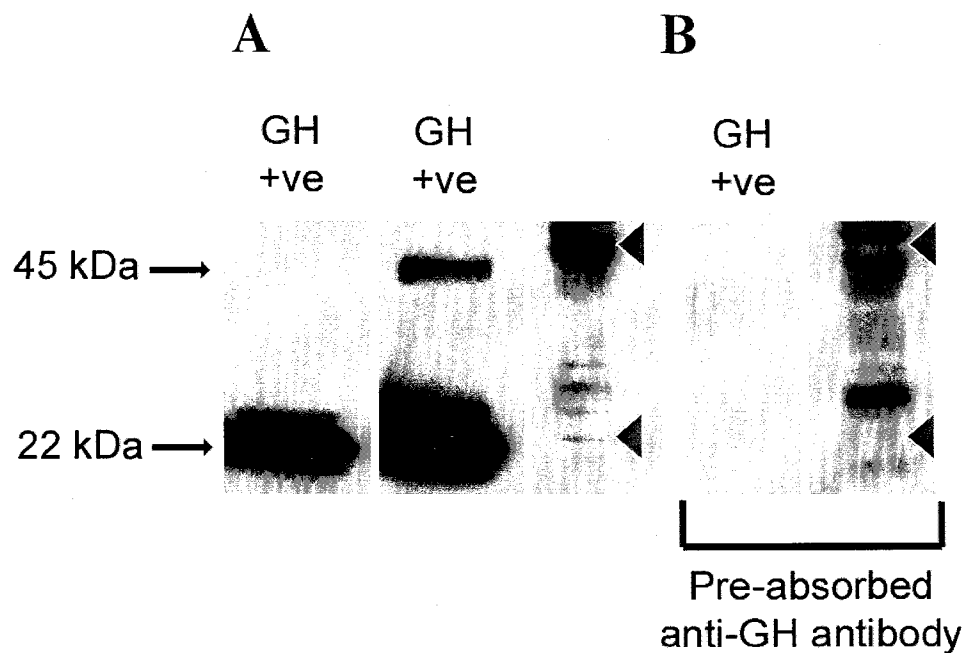
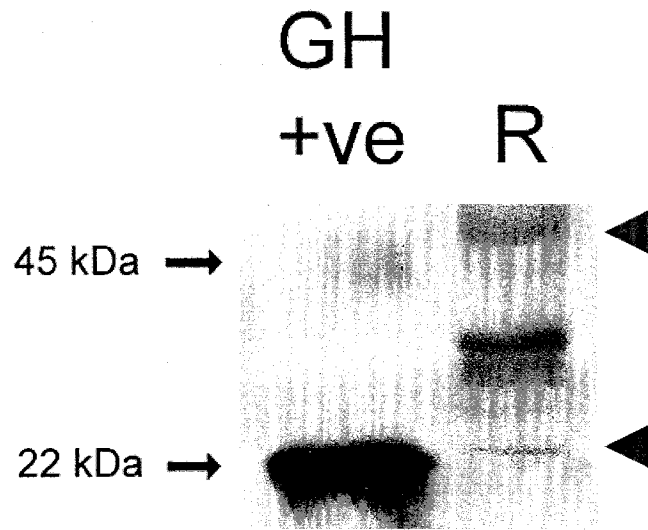


Figure 1 - Western immunoblot of GH-immunoreactive proteins in adult human vitreous from a male cadaver, age 67, with no known history of ocular disease. Acrylamide concentration is 8%. Sample lanes were loaded with 84 μ g of protein. Data are representative of at least three Western immunoblots. (A) Arrow heads (\blacktriangleleft) show protein bands that are quenched following treatment of the membrane with anti-GH antibody pre-absorbed with recombinant hGH (antigen:antibody ratio of 150:1). These bands are specific for GH-immunoreactive proteins. Positive control of 10 ng recombinant hGH was loaded twice, showing 22 kDa and 45 kDa protein bands. (B) Same immunoblot and sample showing immunoreactive bands following treatment with pre-absorbed anti-GH antibody. Positive control is 10 ng recombinant hGH.



49

Figure 2 – Western immunoblot of GH-immunoreactive proteins in adult human retina (lane R) from a 57 year old male with no known history of ocular disease. Loaded 20 μ g of protein. Positive control was 33 ng of recombinant hGH. Protein bands corresponding to putative monomer and dimer GH are indicated by arrow heads (\blacktriangleleft). Data are representative of at least three Western immunoblots. Immunoblot courtesy of Dr. Esmond Sanders and Ewa Parker, University of Alberta.

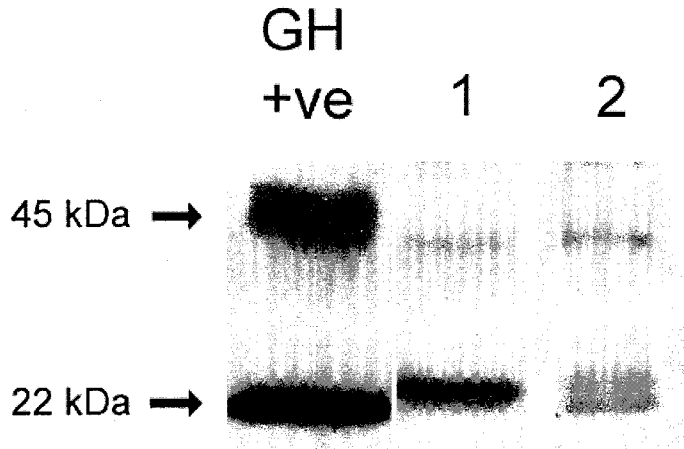


Figure 3 – Western immunoblot of GH-immunoreactive proteins in adult human vitreous from patients with ocular disease. Positive control was 33 ng of recombinant hGH. (1) Vitreous from an 80 year old female with diabetes mellitus. Loaded 24 μ g of protein. (2) Vitreous from an 81 year old male with epiretinal membrane. Loaded 20 μ g protein. Data are representative of at least three Western immunoblots. Immunoblot courtesy of Dr. Esmond Sanders and Ewa Parker, University of Alberta.

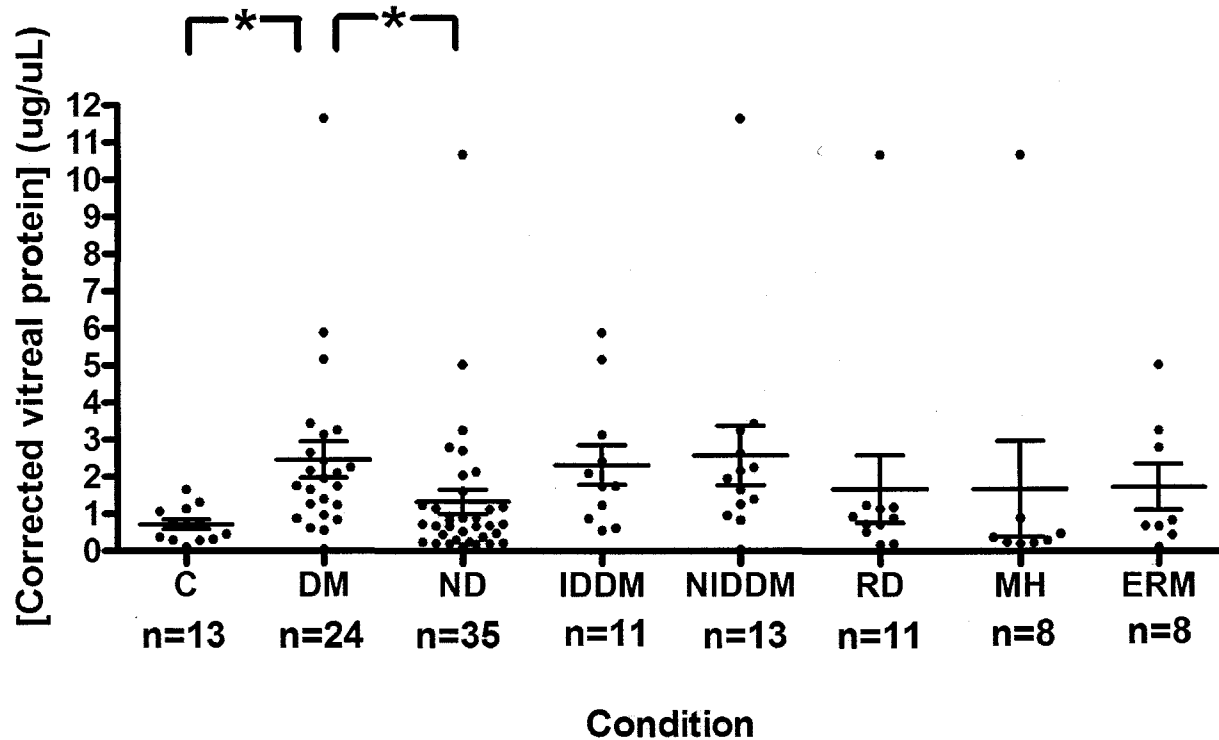


Figure 4 – **Total protein corrected for hemoglobin in adult vitreous.** Levels are higher in those with DM than in ND ($p < 0.05$) and C ($p < 0.05$). All groups are age and gender matched. Groups were compared using a Kruskal-Wallis non-parametric test. *Post hoc* analysis was performed using Dunn's multiple comparison test. Values shown \pm SEM. C = Controls with no history of ocular disease, DM = Diabetes mellitus with ocular disease, ND = Non-diabetic with other ocular conditions (RD, MH, ERM, vitreous hemorrhage, subretinal hemorrhage, vitreous debris, central retinal vein occlusion), IDDM = Insulin-dependent diabetes mellitus with ocular disease, NIDDM = Non-insulin-dependent diabetes mellitus with ocular disease, RD = Retinal detachment (part of ND pool), MH = Macular Hole (part of ND pool), ERM = Epiretinal membrane (part of ND pool).

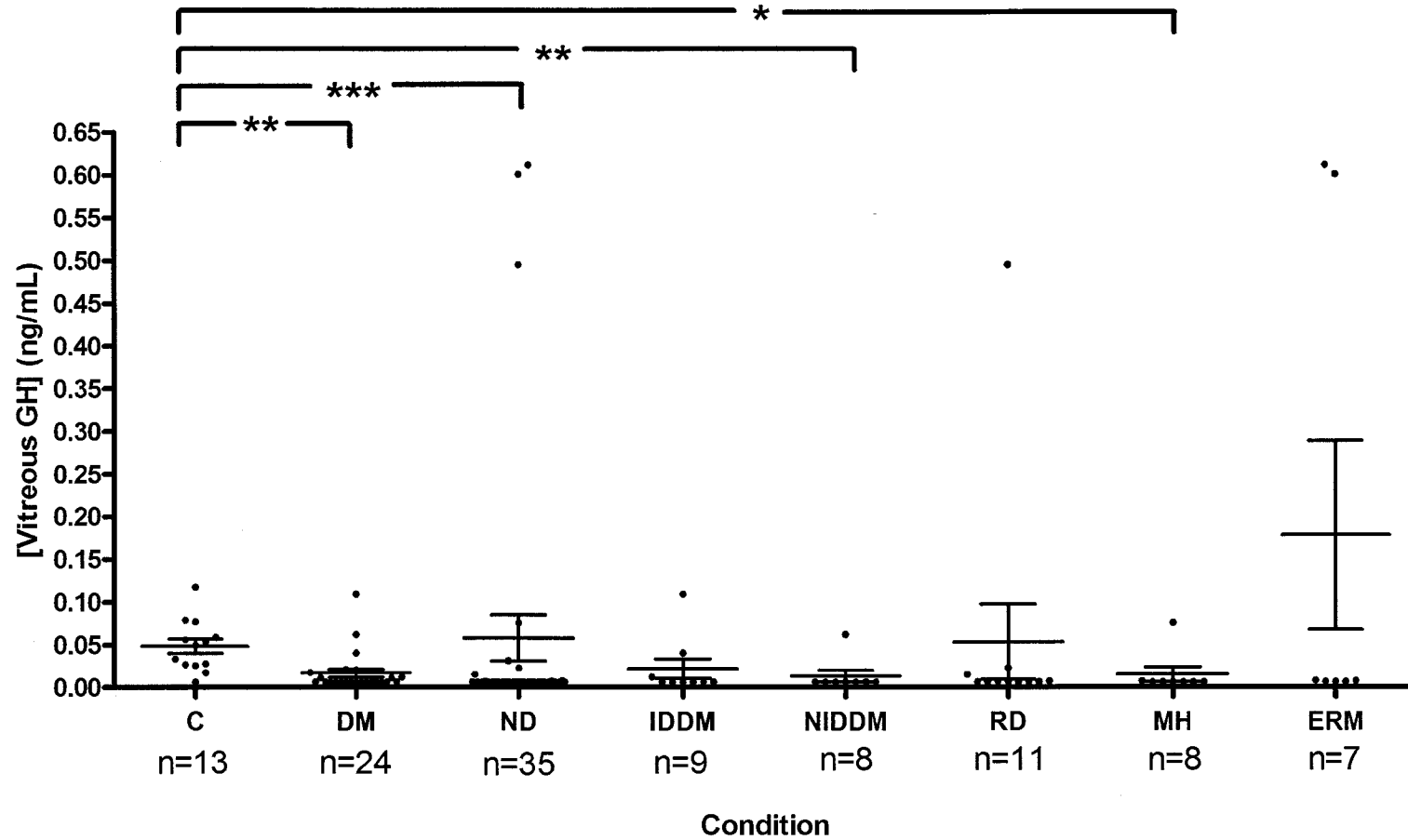


Figure 5 - Levels of uncorrected vitreous GH in adult patients. Levels are higher in C than in those with DM ($p < 0.01$), NIDDM ($p < 0.01$) and MH ($p < 0.05$) while levels are higher in ND than in C ($p < 0.001$). All groups are age and gender matched. Groups were compared using a Kruskal-Wallis non-parametric test. *Post hoc* analysis was performed using Dunn's multiple comparison test. Values shown \pm SEM.

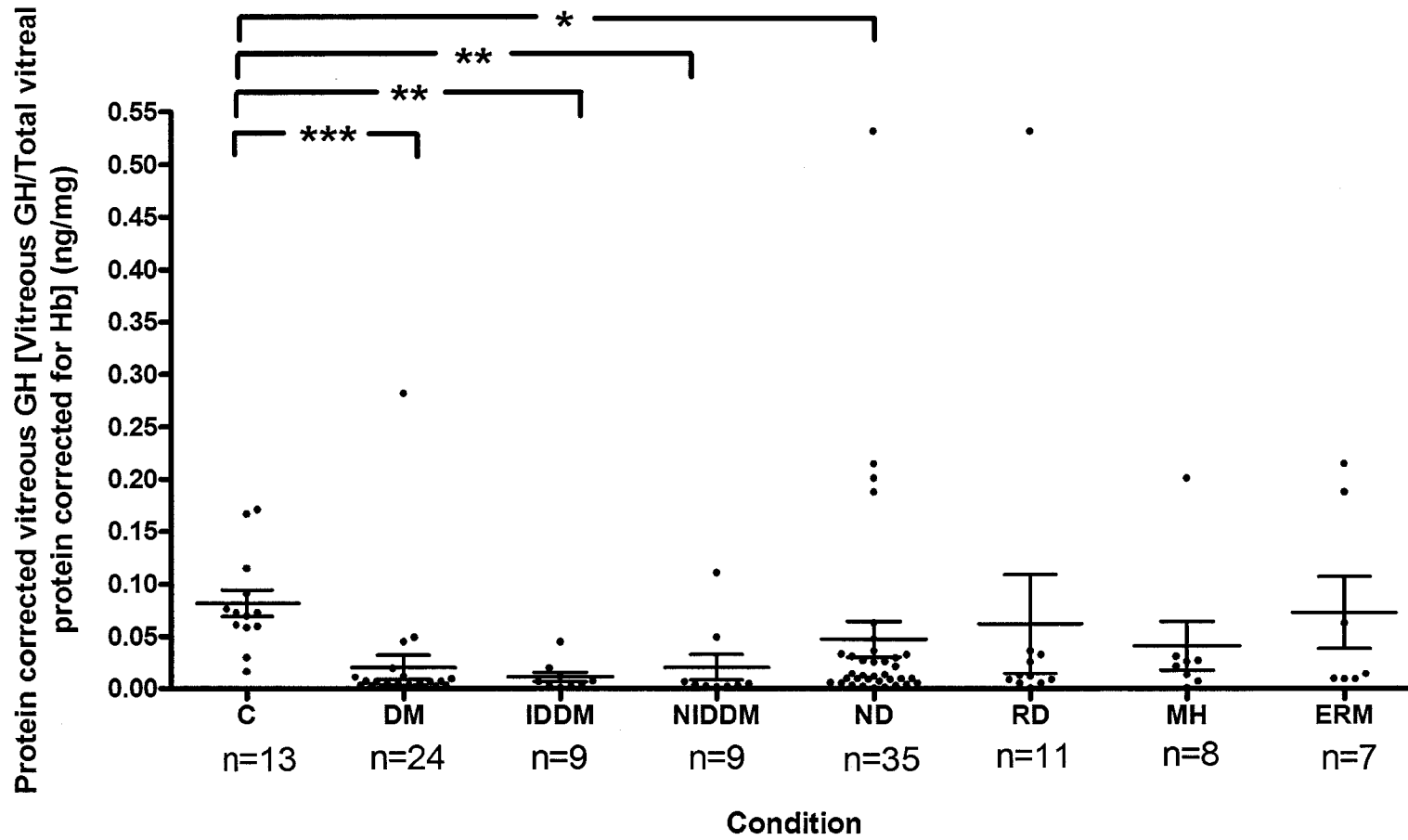


Figure 6 – Levels of GH corrected for total vitreal protein in the vitreous of adult humans. Levels are higher in C than in those with DM ($p < 0.001$), IDDM ($p < 0.01$), NIDDM ($p < 0.01$) and ND ($p < 0.05$). All groups are age and gender matched. Groups were compared using a Kruskal-Wallis non-parametric test. *Post hoc* analysis was performed using Dunn’s multiple comparison test. Values shown \pm SEM. Total vitreal protein was corrected for hemoglobin (Hb).

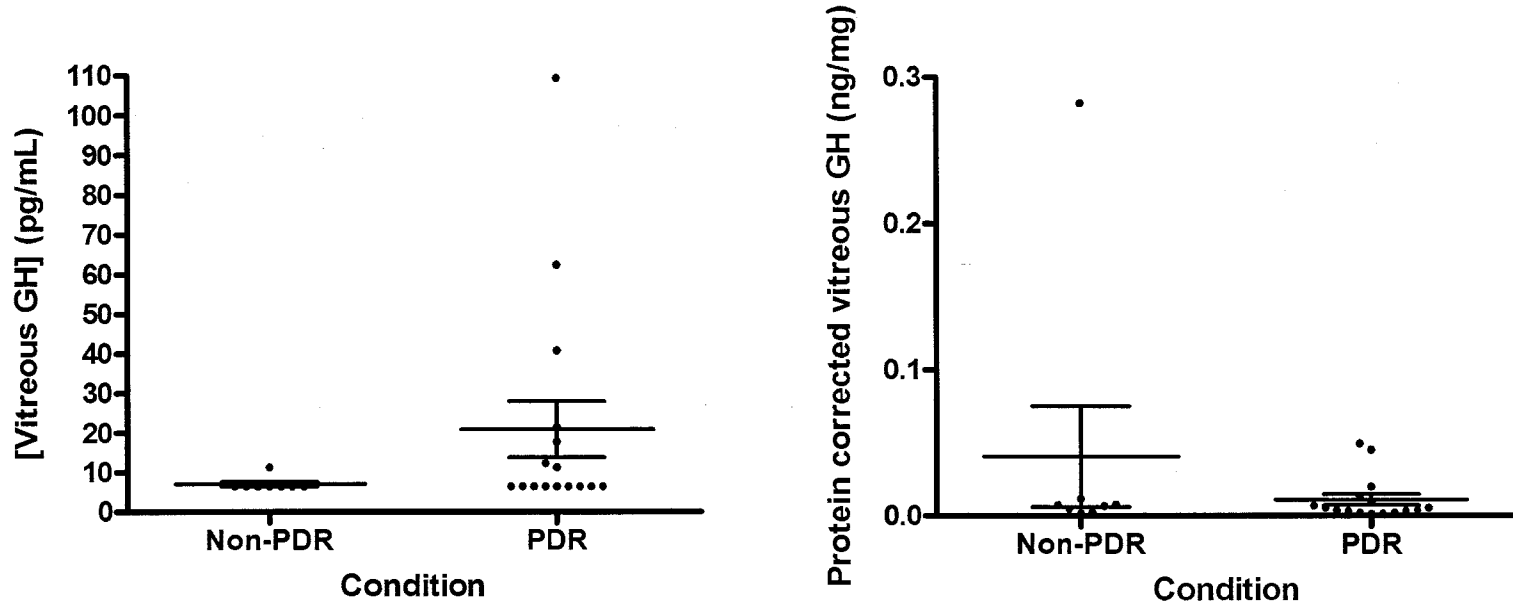


Figure 7 – Uncorrected and protein-corrected vitreous GH levels in diabetics without PDR and diabetics with PDR. No statistically significant differences between groups. Groups were compared using a Mann-Whitney U test. Values shown \pm SEM.

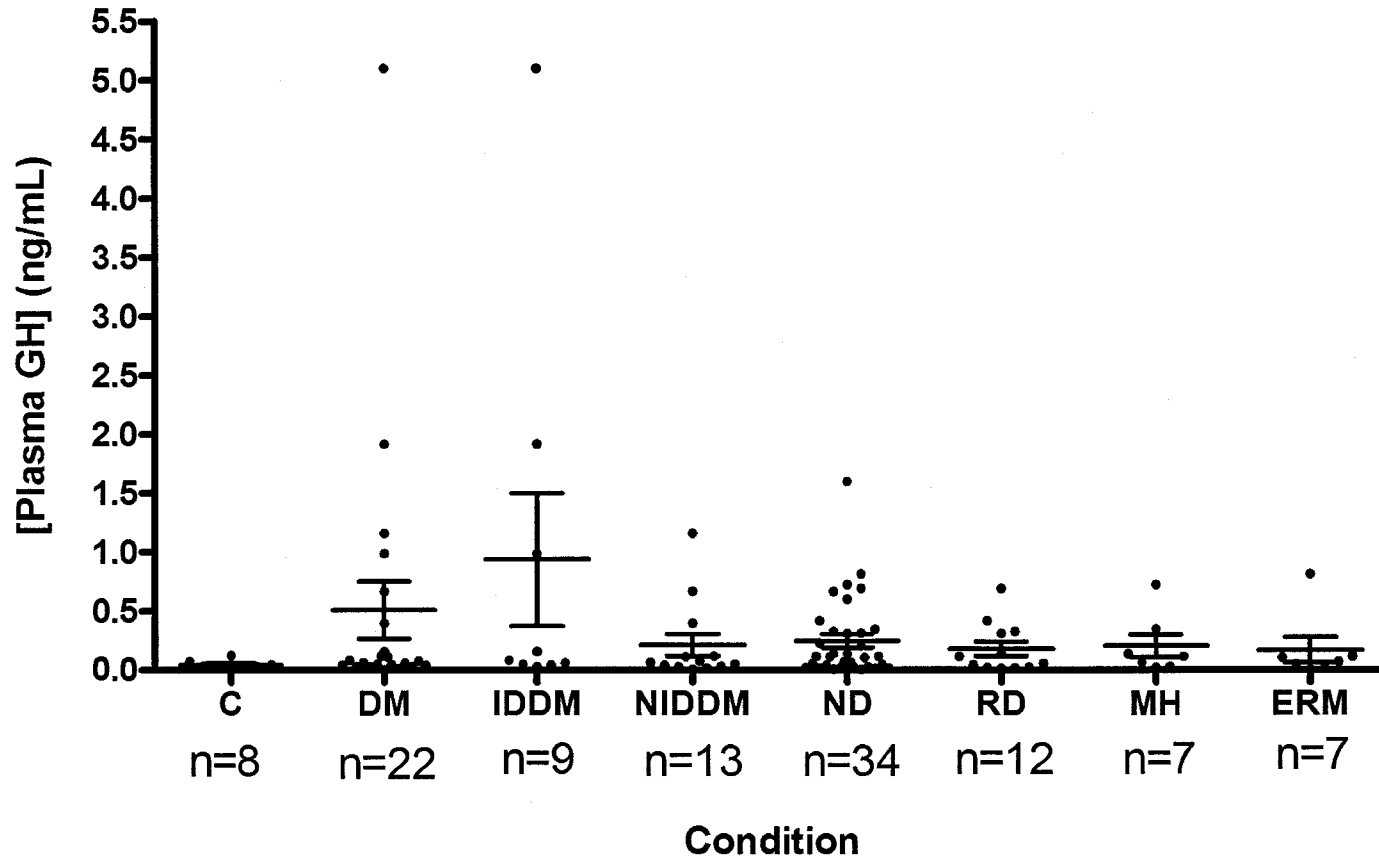


Figure 8 – **Plasma GH levels in adults.** No statistically significant differences among groups. All groups are age and gender matched. Groups were compared using a Kruskal-Wallis non-parametric test. *Post hoc* analysis was performed using Dunn’s multiple comparison test. Values shown \pm SEM.

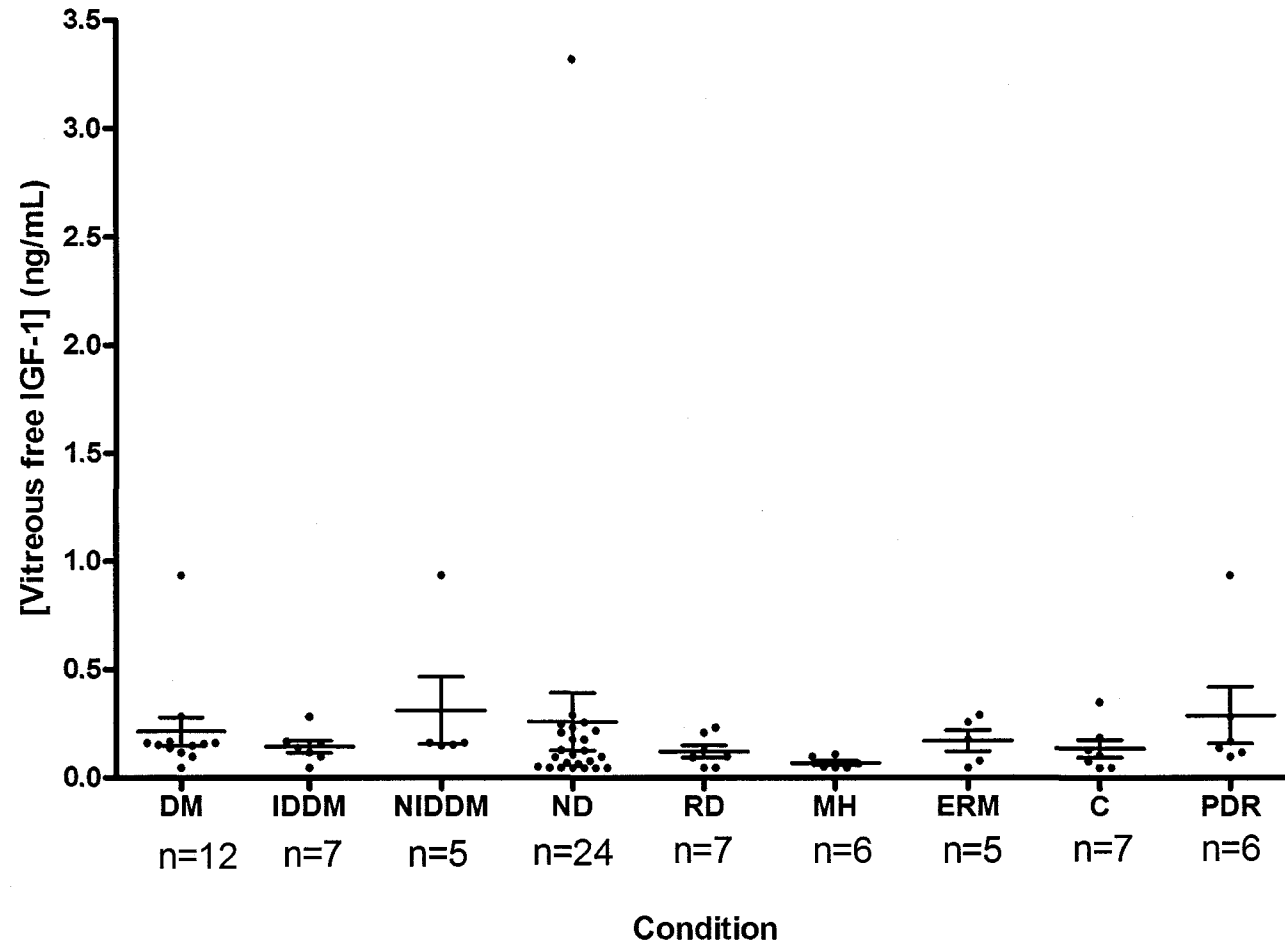


Figure 9 – **Uncorrected vitreous free IGF-1 in adults.** No statistically significant differences among groups. All groups are age and gender matched. Groups were compared using a Kruskal-Wallis non-parametric test. *Post hoc* analysis was performed using Dunn's multiple comparison test. Values shown \pm SEM.

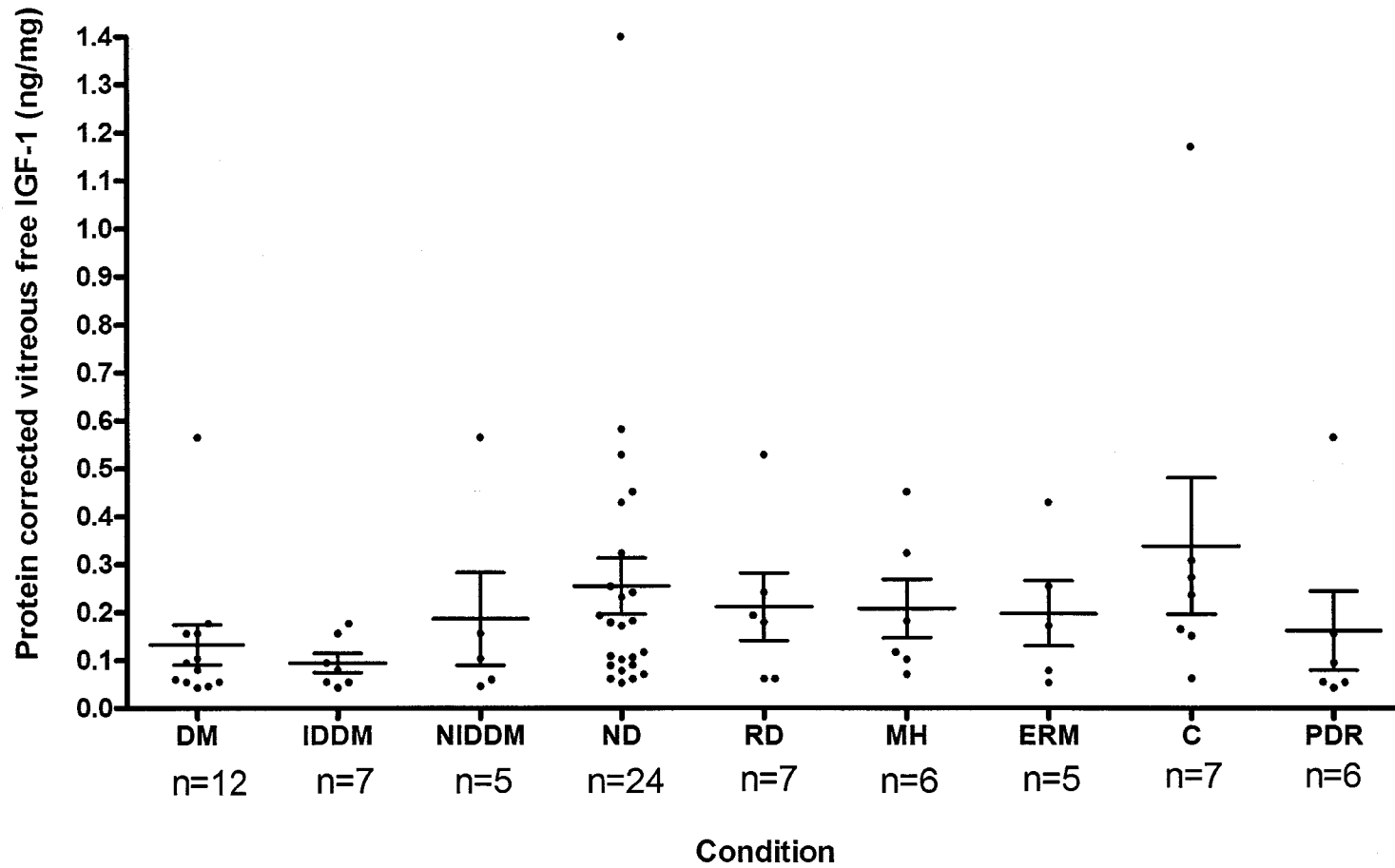


Figure 10 – Levels of free IGF-1 corrected for total vitreal protein in the vitreous of adult humans. No statistically significant differences among groups. All groups are age and gender matched. Groups were compared using a Kruskal-Wallis non-parametric test. *Post hoc* analysis was performed using Dunn’s multiple comparison test. Values shown \pm SEM. Total vitreal protein corrected for hemoglobin (Hb).

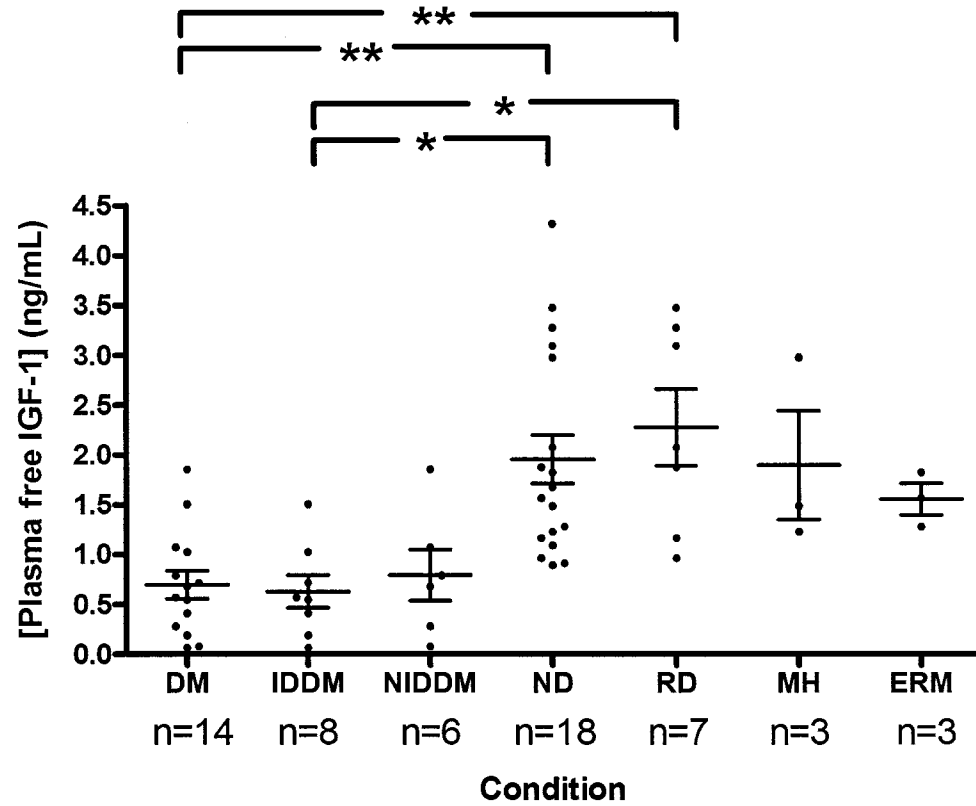


Figure 11 – **Plasma free IGF-1 levels in adults.** Levels are higher in ND than in those with DM ($p < 0.01$) and IDDM ($p < 0.05$). Levels are higher in those with RD than in those with DM ($p < 0.01$) and IDDM ($p < 0.05$). All groups are age and gender matched. Groups were compared using a Kruskal-Wallis non-parametric test. *Post hoc* analysis was performed using Dunn’s multiple comparison test. Values shown \pm SEM.

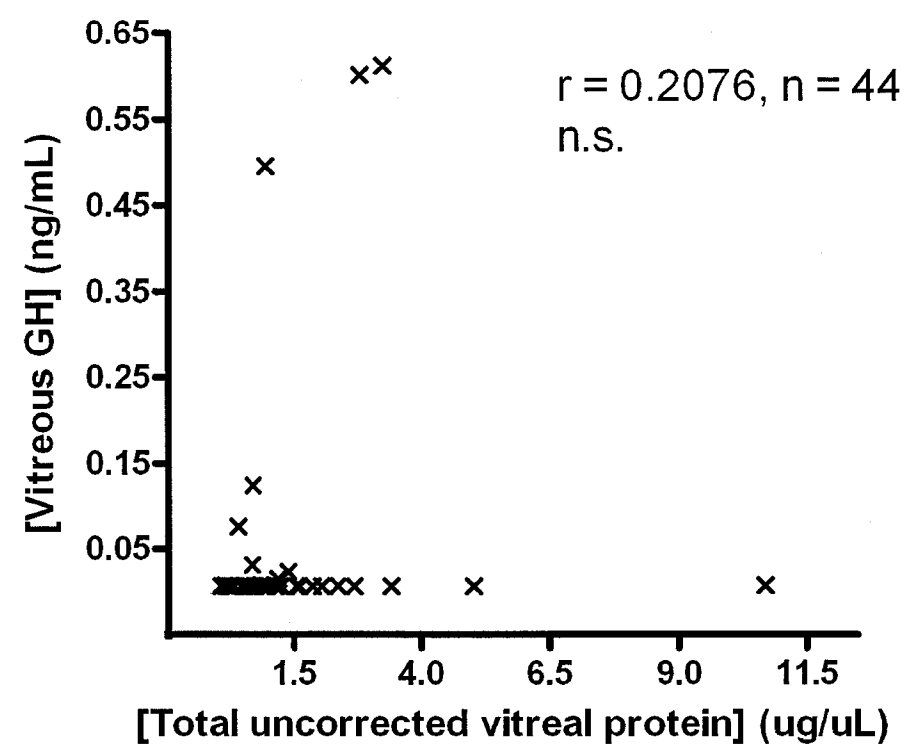


Figure 12 - Total uncorrected vitreal protein versus uncorrected vitreous GH in non-diabetics with ocular disease. No significant correlation. Spearman non-parametric correlation used.

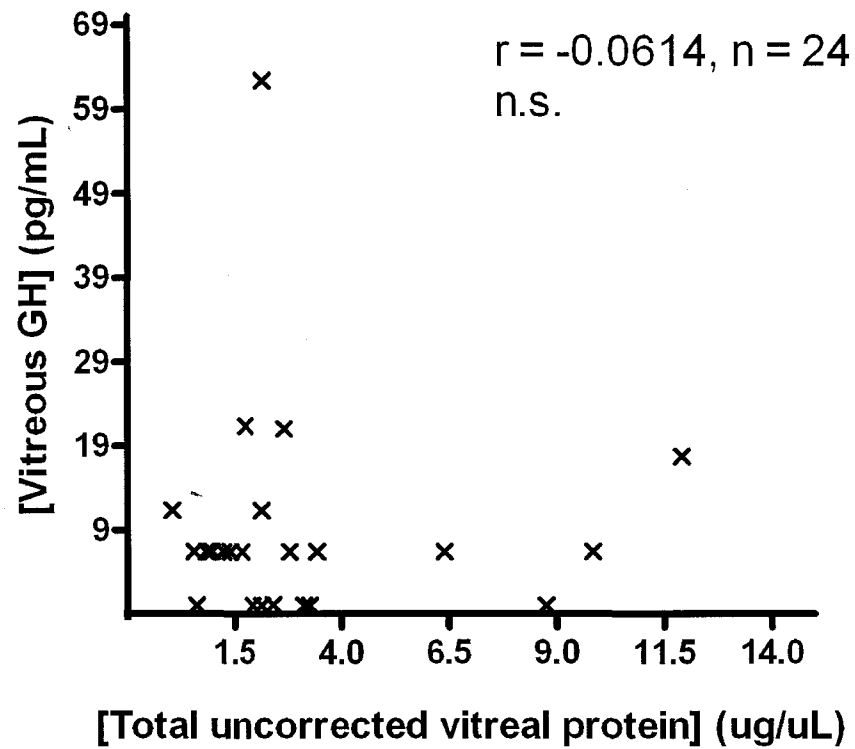


Figure 13 - Total uncorrected vitreal protein versus uncorrected vitreous GH in diabetics with ocular disease. No significant correlation. Spearman non-parametric correlation used.

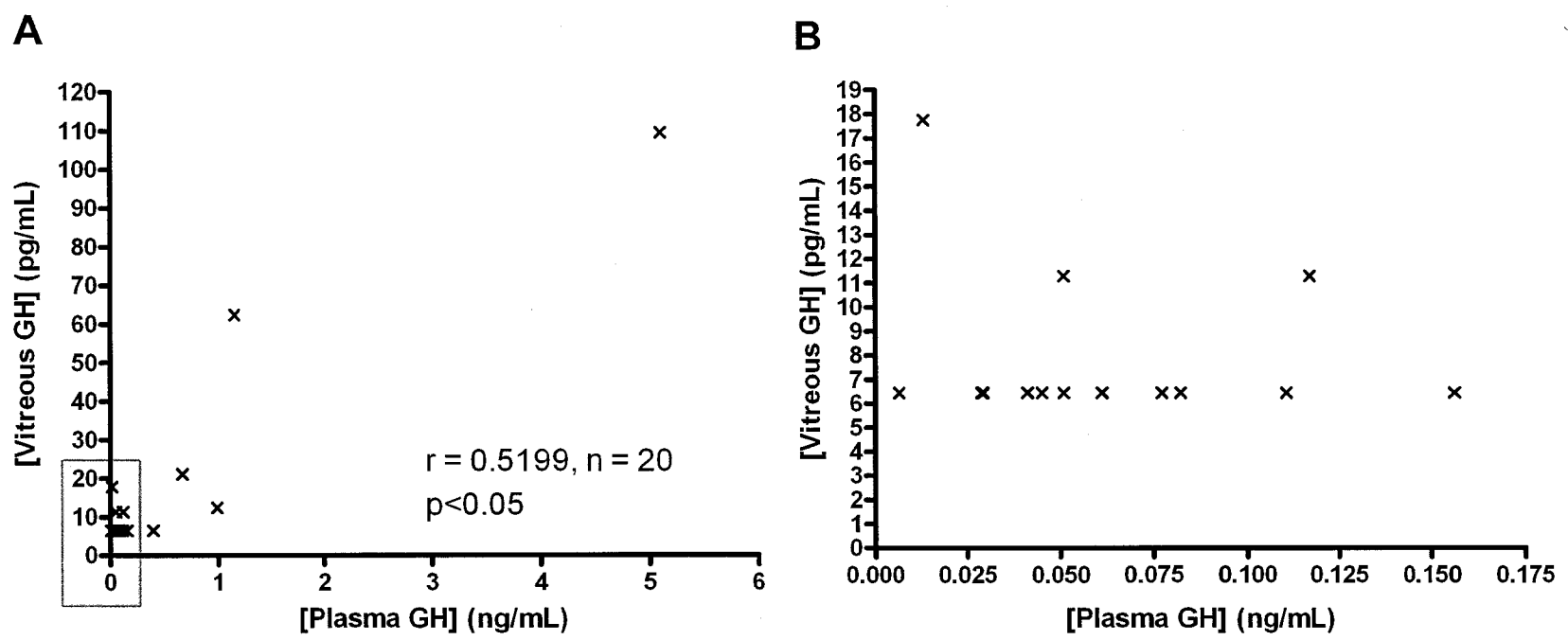


Figure 14 – Uncorrected vitreous GH versus plasma GH in diabetics with ocular disease. Box in (A) is expanded in (B). Spearman non-parametric correlation used.

IV. DISCUSSION

These results demonstrate, for the first time, that immunoreactive GH-like proteins are present in the vitreous and retina of adult humans, both in those with no history of ocular disease and in those with diabetic/non-diabetic ocular disease. The present study also shows that vitreous GH levels, both corrected and uncorrected for total vitreal protein, are lower in diabetics with ocular disease than in controls with no history of ocular disease. Vitreous GH can thus be added to the growing list of peptide markers of diabetic ocular disease, including VEGF (Funatsu et al., 2002b), fibronectin (Probst et al., 2004), TGF- β and IGF-1 (Boulton et al., 1997). In addition, patients with macular holes have a 3-fold significant decrease in uncorrected vitreous GH compared to controls, implicating vitreous GH as a marker of macular hole formation. A positive linear correlation was observed between protein-corrected vitreous levels of free IGF-1 and GH in non-diabetics and diabetics – both with ocular disease – suggesting that local GH action in the retina may be IGF-1 dependent in these patients.

A. Characterization of GH in vitreous and retina

The present study presents the first evidence of GH immunoreactivity in the human vitreous humour and retina, although a previous study measured vitreal GH in the neonatal rat (Modanlou et al., 2006) and previous studies in this laboratory have demonstrated GH gene and protein expression in the retina of embryonic chicks (Baudet et al., 2003) and in the retina and whole eye of perinatal and adult rats (Harvey et al., 2006).

The predominant GH-immunoreactive protein moieties in the embryonic chick retina were of sizes 15 kDa, 16 kDa, and 25 kDa while in rat retinae immunoreactive protein of size 22 kDa predominated (Harvey et al., 2006). In human vitreous from cadavers with no known history of ocular disease, there were several immunoreactive protein bands, including bands of 22 kDa and 45-48 kDa. In a patient with epiretinal membrane and one with diabetes, the vitreous profile of GH immunoreactivity was different, with the putative monomer band running slightly higher than the 22 kDa positive control and the putative dimer band running slightly lower than the 45 kDa positive control. These differences may be due to the running conditions of the Western immunoblot as described above (non-uniform gel concentration and current), binding of GH to vitreal factors and/or post-translational modification of the GH protein within the vitreous. In particular, the putative dimer band running between 45-48 kDa in size may be a dimeric form of GH comprised of 22 kDa and 24 kDa moieties (Brostedt and Roos, 1989). Western immunoblotting did not reveal any noticeable differences in protein bands between controls and subjects with ocular disease. As many samples of vitreous were not concentrated enough to show reproducible GH protein bands, further concentrating and Western immunoblot analysis is required to determine if the vitreous GH profile differs with ocular disease. A knowledge of how the GH profile differs is important, as different isohormones of GH can interact differently with the GH receptor and can exhibit different bioactivities. For instance, the 20 kDa GH isohormone has substantially reduced affinity for the GH receptor (Baumann, 1991), and in rats has less bioactivity in stimulating bone growth, body weight gain, and elevation of plasma IGF-1 levels than 22 kDa monomer GH (Kostyo et al., 1987). Similarly, variants of plasma GH have been

shown to have different bioactivities (De Palo et al., 2006b; Sami, 2007), with some cleaved forms showing enhanced bioactivity and dimeric/oligomeric forms showing decreased bioactivity (reviewed by Baumann, 1991).

In those individuals with an uncompromised BRB, transport of systemic GH across the barrier is unlikely (James and Cotlier, 1983) suggesting that at least some of the immunoreactive GH in the vitreous of control patients is derived from a local ocular source. In the present study, and for the first time, GH immunoreactivity was detected in a sample of whole retina from an adult human with no known history of ocular disease. The retina, then, given its proximity to vitreous and its repository of cells such as retinal ganglion cells (RGCs), is a likely source of local GH. Retinal immunoreactive GH protein was also detected in the RGCs and RPE of embryonic chicks (Baudet et al., 2003) and in the retinal ganglion cells of perinatal and adult rats (Harvey et al., 2006), both of which have been shown to express locally-derived GH.

B. Quantification of GH and IGF-1 immunoreactivity by ELISA

1. TOTAL VITREAL PROTEIN AND GH LEVELS

Serum GH has been implicated in the progression of ocular disorders, in particular neovascular diseases such as DR. Ocular GH, as distinct from serum GH, may also be implicated in ocular disease progression. In those with breakdown of the BRB secondary to vitreoretinal disease, GH immunoreactivity in the vitreous may be indicative of both ocular (local) and serum contribution of GH. It is for this reason that levels of GH corrected for total vitreal protein were measured, in addition to uncorrected, absolute

vitreal GH concentrations. Strikingly, levels of vitreal GH did not increase in diabetics and non-diabetics following increased infiltration of proteins from serum into the vitreal (see Figures 12 and 13). This suggests that the effect of serum GH leakage into the vitreal was at most minimal, despite the observed increase in total vitreal proteins in diabetics compared to controls and non-diabetics with ocular disease. Alternatively, increased infiltration of hemoglobin from plasma into the vitreal may have masked a significant increase in vitreal GH levels. The low levels of serum GH in diabetics and non-diabetics with ocular disease likely implies a low probability of serum GH leakage into the vitreal. In addition, GH may be excluded based on its size; GH dimers/oligomers and/or bound GH may have greater difficulty crossing the compromised BRB than monomer GH. Given that the BRB and the BBB are similar in function and microanatomy and share a similar developmental origin (Lightman et al., 1987; Manfre et al., 1997), they may have similar transport mechanisms. While human GH does not bind specifically to receptors in retinal capillaries in the bovine eye (James and Cotlier, 1983), GH receptors are present at the choroid plexus and a specific transport mechanism for GH at the blood-CSF barrier has been suggested (Lai et al., 1991; Pan et al., 2005), although a process involving simple diffusion cannot be dismissed (Coculescu, 1999; Pan et al., 2005). Alternatively, the lipid solubility and charge state of the GH molecule may affect its infiltration from blood into vitreal. Highly negatively charged fluorescent dyes such as calcein and hydrophilic dyes such as carboxyfluorescein are better able to cross the BRB following laser coagulation therapy than less negatively charged and more lipid soluble dyes such as sodium fluorescein (Mori et al., 1997). Midvitreal levels of calcein 4 hours after systemic injection were higher than levels of

sodium fluorescein (Golshani et al., 1993). As plasma GH is a hydrophilic protein (Harvey et al., 1995), and biologically active deamidated charge isomers of plasma GH have been characterized (Skottner et al., 1988), alternative mechanisms of GH entry into vitreous in compromised and uncompromised retinal vasculature based on lipid solubility and charge are possible.

2. UNCORRECTED VITREOUS GH

In diabetics and specifically in non-insulin-dependent diabetics, mean vitreous levels of GH uncorrected for vitreous protein were lower than in controls. This novel finding was unexpected for two reasons. Firstly, the present study showed that plasma GH levels in diabetics correlate with GH levels in vitreous, supporting the notion of BRB leakage in the diabetic retina (Cunha-Vaz, 2004). Secondly, in the present study those with IDDM and NIDDM had plasma GH levels comparable with controls. Together, these two points suggest that uncorrected vitreous GH should be comparable among diabetics and controls, rather than lower among diabetics. Movement of GH from the vitreous to plasma, possibly through a specific transport mechanism (Coculescu, 1999), may be partly responsible for the observed decrease in vitreous GH. Other explanations for the decrease in vitreous GH are given below, in relation to protein-corrected vitreous GH. Non-diabetics with ocular disease had higher levels of vitreous GH than controls, while a subgroup of patients with macular hole had lower levels of vitreous GH than controls. This is of interest, as a previous study showed lower systemic levels of GH in postmenopausal women with idiopathic macular holes compared to age-matched controls (Kmera-Muszynska and Zgliczynski, 2000). The effect of decreased GH on retinal

vasculature may affect the incidence of macular holes, as changes in retinal vasculature are known to increase risk for macular hole formation (Ho et al., 1998). When those with either epiretinal membrane or retinal detachment were compared to controls in the present study, however, no significant difference in vitreous GH levels was observed (see Figure 6). In the vitreous of non-diabetics with ocular disease, GH may be playing the role of a growth factor involved in angiogenesis of the retina. As monomer and dimer GH have been characterized in the vitreous of non-diabetic patients, and as GH can bind to at least one vitreous proteoglycan (opticin; Sanders et al., 2003) it is possible that alternative binding and/or expression of various GH moieties may result in or be associated with changes in vitreous integrity which can lead to ocular disorders such as epiretinal membrane, macular hole, and retinal detachment.

In the present study mean uncorrected vitreous GH levels for the control individuals were 48.6 pg/mL while mean values for uncorrected vitreous GH of rats at postnatal age 21 days were reported to be 4.9 ng/mL (Modanlou et al., 2006). GH levels in the human central nervous system (CNS) may therefore be much lower than those in the rat CNS. This possibility is supported by Costa et al. (1993) who detected very low GH immunoreactivity and by Nyberg (2000), who failed to find GH expression in the human CNS. In contrast, GH and GH mRNA are readily detected in the rat brain (Hojvat et al., 1982; Harvey and Hull, 2003). This difference may be species or age-related, especially as GH secretion is distinctly inversely age-related (Sherlock and Toogood, 2007) and the patients in the present study were all elderly, whereas the rats used by Modanlou et al. (2006) were neonatal. The difference in GH levels could also reflect methodological

differences, since different immunological techniques were used for measurement and different assays have been shown to give dissimilar results (Ebdrup et al., 1999; Bidlingmaier and Strasburger, 2007).

3. PROTEIN-CORRECTED VITREOUS GH

The observed decrease in protein-corrected vitreous GH in diabetic patients – the majority of whom had DR – is also a novel finding and correlates with the decrease in protein-corrected vitreous free IGF-1 observed in patients with PDR (Simo et al., 2003). In the present study, there was no decrease in protein-corrected vitreous free IGF-1 levels in patients with PDR. While the same ELISA kit was used in the study by Simo et al. (2003) and the present study, the patient cohort was slightly younger and the number of samples of controls and diabetics with PDR was higher in the study by Simo et al. (2003). Reduced local production of retinal GH in diabetics is a possible explanation for the observed decrease in protein-corrected vitreous GH, since GH is known to induce IGF-1 expression in the retina of embryonic chicks (Baudet et al., 2003) and goldfish (Otteson et al., 2002). While elevated serum GH has been implicated in the progression of DR (Kohner and Oakley, 1975; Parentin et al., 2004), it is possible that the decrease in protein-corrected vitreous GH observed in this study leads to a decrease of proteolytically cleaved GH fragments known as vasoinhibins (Clapp et al., 2006). These GH fragments exert anti-angiogenic properties in a variety of ways, such as via interference with the activity of growth factors and via the stimulation of apoptosis in endothelial cells (Clapp et al., 2006). Thus, a reduction of vasoinhibin activity might lead to diabetic eye disease involving neovascularization of the retina and hemorrhaging. Another possibility is that

diabetes causes a decrease in GH secretion in the retina due to apoptotic death of RGCs, caused by pressure from macular edema secondary to DR (Felinski and Antonetti, 2005). The human diabetic retina is known to express several proapoptotic molecules, including Bad, in response to neuronal injury (Abu El-Asrar et al., 2007), likely through glial cell-induced apoptosis in RGCs (Abu-El-Asrar et al., 2004). RGCs are known sites of local GH production in the embryonic chick and perinatal and adult rat (Baudet et al., 2003; Harvey et al., 2006), thus death of RGCs could lead to diminished levels of vitreoretinal GH.

4. PLASMA GH

In the present study, plasma levels of GH were comparable across diabetics, non-diabetics, and controls. Previous studies have shown increases in plasma GH levels in both insulin-dependent (Johansen and Hansen, 1971) and non-insulin-dependent diabetics compared to controls (Kjeldsen et al., 1975). Tran et al. (2002) suggest that GH may play a role in the development of DR while hyperglycemia accelerates the course of the disease. In the present study, the mean plasma GH level in controls was 45.1 ± 13.2 pg/mL. This value is approximately 40-50 times lower than mean 24-hour plasma GH levels reported in a previous study (Kjeldsen et al., 1975). In the present study, the mean age of controls was 55.6 ± 1.4 years while in the study by Kjeldsen et al. (1975), the mean age of controls was 55-57 years. Obesity and the degree of diabetic control (see below) are likely confounding factors in the present study and can potentially affect the levels of plasma GH obtained. Patients in the present study were not separated based on their level of obesity as measured by body mass index, a measure of body height to mass.

However, in non-obese diabetics with NIDDM there are higher levels of plasma GH than in non-obese controls (Hansen, 1973), while plasma GH levels are decreased in obese diabetics with NIDDM compared to obese controls (Kjeldsen et al., 1975). This difference highlights the importance of controlling for obesity in study subjects. The time of day in which plasma samples were taken is another variable to consider. Plasma GH levels vary throughout the day in non-diabetic and especially in diabetic patients, where the effect is more pronounced (Johansen and Hansen, 1971). In the present study, plasma samples were taken between the hours of 8 am and 2 pm, during which there may have been fluctuations in plasma GH level. Mean 24-hour plasma GH levels measured by Kjeldsen et al. (1975), therefore, cannot be directly compared to the GH levels measured in the present study. The ELISA kit used to detect vitreous and plasma GH uses polyclonal antibodies; thus, any immunoreactive GH isohormone or variant – whether monomer, dimer, or oligomer – will be measured. There is a possibility that levels of (a) specific GH moiety(ies) could potentially increase or decrease, and the ELISA kit used in the present study might not be able to measure this change. GH exists in many molecular isoforms and approximately half of the circulating GH is bound by a high-affinity binding protein (Baumann, 2001). Binding of GH to its binding protein may interfere with its quantification (Ebdrup et al., 1999; Popii and Baumann, 2004). In previous studies measuring plasma GH levels in diabetics versus controls, radioimmunoassay was typically the method of choice; thus, direct comparison of results between the present study and previous studies is impossible, although the ELISA kit used in the present study was calibrated to international reference preparations of GH. Finally, there is potentially great variability in GH assay results among different laboratories; in the UK,

different laboratories assaying identical samples of GH reported values which differed two to three-fold (Ebdrup et al., 1999).

As plasma GH levels are known to decline with age (Zadik et al., 1985), it is not surprising that plasma GH levels in the present study are much lower than those reported in a previous study in which mean patient ages were 25-28 (Johansen and Hansen, 1971). Plasma GH levels in elderly controls are indistinguishable from plasma GH levels in those with GH deficiency (Ho and Hoffman, 1993), particularly by the age of 60 (Savine and Sonksen, 2000). In the present study, the mean plasma GH level of those with IDDM was 0.9 ± 0.6 ng/mL with a mean age of 49 ± 5.6 years. This value was, as expected, lower than the value reported by Johansen et al. (1971) in patients with a mean age of 19.9 years. Similarly, in the present study the mean plasma GH level of those with NIDDM was 0.2 ± 0.1 ng/mL with a mean age of 66 ± 3.5 years, lower than the value reported by Kjeldsen et al. (1975) in patients with a mean age of 55-58 years. Additionally, plasma GH levels in rats of postnatal age 21 days was reported to be 87.3 ng/mL (Modanlou et al., 2006). Of note, GH may be compartmentalized in extracellular fluids such as the vitreous, as GH levels in vitreous change despite a lack of difference in serum GH levels across groups in the present study. This compartmentalization may be supported by active transport mechanisms to transport GH into the retina (Coculescu, 1999).

5. UNCORRECTED AND PROTEIN-CORRECTED VITREOUS GH CORRELATES WITH PLASMA GH

As expected by the compromised BRB, uncorrected vitreous GH levels correlated with levels of plasma GH. Strikingly, however, protein-corrected vitreous GH levels strongly and positively correlated with plasma GH levels. This correlation was much higher ($p < 0.0001$) than the correlation between uncorrected vitreous GH and plasma GH ($p < 0.05$). This finding raises the possibility of a positive feedback mechanism or a reduction in the negative feedback mechanism of GH secretion, whereby increased plasma GH raises the level of local GH in the eye. Alternatively, an intermediary signaling molecule that can raise protein-corrected vitreous GH levels and cross the BRB may be involved. GH typically acts to decrease GH secretion in a classical negative feedback scenario (Goldenberg and Barkan, 2007). One source of error is the leaky BRB; protein-corrected vitreous GH is calculated by correcting vitreous GH for total vitreous protein, yet there is increased and unpredictable infiltration of plasma proteins into vitreous in the diabetic retina.

6. UNCORRECTED AND PROTEIN-CORRECTED VITREOUS FREE IGF-1

In the present study, uncorrected and protein-corrected vitreous free IGF-1 levels were comparable among all the groups. This was an unexpected finding, as a previous study had reported increased free IGF-1 levels in the vitreous of patients with PDR along with decreased intraocular production of free IGF-1 (Simo et al., 2003). That study had a greater number of non-diabetics and diabetics enrolled, and, contrary to the present study, those enrolled by Simo et al. (2003) were matched according to serum free IGF-1. In

addition, increased total IGF-1 has been reported in the vitreous of patients with PDR (Burgos et al., 2000) and high levels of IGF-1 were reported in the subretinal fluid of a diabetic patient with acromegaly (van Setten et al., 2002).

7. PLASMA FREE IGF-1

Among diabetics and in particular those with IDDM, plasma free IGF-1 levels were lower than in non-diabetics with ocular disease and in a subset of patients with retinal detachment. Other studies have similarly reported decreases in serum free IGF-1 in diabetics (Feldmann et al., 2000; Frystyk, 2004) and particularly in insulin-dependent diabetics (Orskov, 1996; Frystyk et al., 2003), although decreased levels of serum free IGF-1 likely do not correlate with incidence of PDR in patients with IDDM (Frystyk et al., 2003). Notably, eight diabetic patients in the present study were not diagnosed with PDR. This fact is important as diabetics with IDDM and DR had comparable levels of serum free IGF-1 levels than diabetics without DR (Frystyk, 2004). Earlier studies had paradoxically shown that levels of plasma free IGF-1 in diabetics with IDDM and DR were either higher (Janssen et al., 1997) or lower (Feldmann et al., 2000) than in diabetics with IDDM without DR. These differences are likely due to the lack of appropriately matched groups [in the case of the study by Janssen et al. (1997)] or to the use of non-fasting plasma samples collected after breakfast and insulin administration [in the case of the study by Feldmann et al. (2000)], where insulin can have effects on the level of plasma free IGF-1 in those with IDDM (Attia et al., 1999). Due to differences in total IGF-1 assays and patient groups used, there has been controversy over levels of total IGF-1 in plasma. It is generally agreed that in those with DR a transient increase in

plasma total IGF-1 levels does occur in the early stage of retinal neovascularization (Merimee et al., 1983; Hyer et al., 1989a). Some studies report decreased levels of total IGF-1 in diabetics (Yde, 1969; Frystyk et al., 2003). Others, however, have shown no significant association between total IGF-1 levels and DR (Dills et al., 1990; Wang et al., 1995). Another confounding factor is the level of circulating insulin, as total IGF-1 levels are, like free IGF-1, significantly influenced by insulin (Attia et al., 1999; Feldmann et al., 2000) and insulin can affect levels of IGFBP-1, another modulator of IGF-1 levels (Rajaram et al., 1997).

8. IGF-1 DEPENDENCE OF GH ACTION

In the present study, there was a positive linear correlation between protein-corrected vitreous free IGF-1 and protein-corrected vitreous GH levels in the vitreous of non-diabetics with ocular disease and in diabetics. This suggests that local GH action in the retina may be IGF-1 dependent in these patients. The present study is the first known to suggest IGF-1 dependence of GH action in the eyes of non-diabetics with ocular disease and diabetics with ocular disease. Levels of retinal IGF-1 in the embryonic chick retina have been shown to be GH dependant (Baudet et al., 2003) while studies of control (non-diabetic with no ocular disease) rat retinal tissue have shown retinal IGF-1 expression is independent of GH (Gerhardinger et al., 2001), as is observed in the rat brain (D'Ercole et al., 1984). In the present study, GH levels may be IGF-1 independent in the vitreous of controls. As the vitreous is morphologically adjacent to the retina and can store growth factors such as GH and IGF-1, vitreous GH and IGF-1 levels are good indicators of retinal GH and IGF-1 levels. Ideally, GH and free/total IGF-1 would be quantified in

adult human retinal tissues from controls, non-diabetics, and diabetics. In the plasma, GH and free IGF-1 levels did not correlate in non-diabetics or diabetics. While levels of free IGF-1 are thought to determine feedback on growth hormone release in normal subjects (Chen et al., 2005), patients with ocular disease and diabetics may have alterations in free IGF-1 and GH levels which compromise normal feedback regulation mechanisms.

C. Other variables

1. METABOLIC FACTORS

There are a number of factors that may affect plasma and vitreous levels of GH and IGF-1. In this study, there was no information on duration or control of diabetes in the diabetics. In a case study of three women with insulin-controlled IDDM from childhood, two women showed regression of retinopathy after some 3 or 4 decades (Bliddal et al., 1983), highlighting the effect of diabetes duration on prevalence of retinopathy. In addition, poorly-controlled diabetics with IDDM have elevated serum GH levels compared to well-controlled diabetics (Lundbaek et al., 1970; Wurzbürger and Sonksen, 1996), and poor glycemic control can lead to insulin resistance leading in turn to acceleration of the rate of retinopathy (Alzaid et al., 1994). Finally, most patients were on oral hypoglycemics and many were being treated with insulin, a known regulator of hepatic IGF-1 production (Frystyk, 2007). Thus, the hypoglycemic medication and insulin treatment may affect serum IGF-1 levels and thus indirectly affect plasma GH levels as plasma free IGF-1 down-regulates GH secretion (Chapman et al., 1998; Butler and Le Roith, 2001).

2. GENDER

Gender differences in plasma GH levels have been previously characterized (Ho et al., 1987). However, in this study all groups were gender matched to ensure that differences observed were not due to gender. As well, the difference in levels of GH and IGF-I between men and women is lost after menopause (Ho et al., 1987), and the mean age of all participants in the present study was 59, past the age of onset for menopause. Another factor that may affect levels of IGF-1 and GH is ethnicity. African American girls and adult men had lower circulating IGF-1 levels than Caucasian counterparts (Platz et al., 1999; Wong et al., 1999). The patients enrolled in this study represented several backgrounds, including (but not limited to) Caucasian, Aboriginal, and East Indian. As circulating IGF-1 levels may be variable among different races, this may also affect their circulating (and thus protein-corrected) GH levels.

3. FREE VERSUS TOTAL IGF-1

In this study, free and readily dissociable IGF-1 was measured in vitreous samples. In serum, free IGF-1 is believed to be the biologically active factor in growth and metabolism (Juul et al., 1997; Chen et al., 2005). A recent review by Frystyk (2007) has suggested that for certain endocrine disorders such as GH deficiency, measurement of serum free IGF-1 may be as diagnostically relevant as total serum IGF-1 (free and bound to binding proteins). Indeed, Chapman et al. (1998) have confirmed the role of serum free IGF-1 rather than total IGF-1 in suppressing GH secretion. And, Hasegawa et al. (1996) showed that levels of serum total IGF-1 correlate with those of free IGF-1 in GH deficient patients. Thus, measurement of free IGF-1 in this study is a useful indicator of

the dependence/independence of GH on IGF-1 in serum and vitreous. Notably, bound forms of IGF-1 are likely in the vitreous, as IGFBPs have been characterized in the vitreous and levels of IGFBP-3 are elevated in PDR (Simo et al., 2003). The majority of IGF-1 in circulation exists in a complex with IGFBP-3 and ALS in a 150 kDa complex, and under conditions of a non-compromised BRB, this complex cannot easily leave the vascular compartment (Jones and Clemmons, 1995). Thus, association of free IGF-1 with its binding proteins may occur in the vitreous following entry into the vitreous of free IGF-1 in those with non-proliferative ocular conditions or those without ocular disease.

D. Reduced vitreous GH – beneficial or insidious?

In the present study, reduced levels of uncorrected and protein-corrected vitreous GH were associated with diabetes. This paradoxical finding is contradicted by studies which, for decades, have pointed to a link between elevated plasma GH levels and the progression of DR. Poulsen (1953) noted the recovery from DR in a patient with a damaged pituitary gland, leading to hypophysectomy as an established treatment for DR before the advent of laser photocoagulation therapy and strict metabolic control (Boehm, 2007). Among diabetics with IDDM, those with DR had higher plasma GH levels than those without DR (Powell et al., 1966). And finally, a study using computer analysis of ocular results following growth hormone blockade in diabetics with varying degrees of DR revealed that suppression of GH improves the prognosis of DR (Schaub et al., 1984). Certainly, further work is needed to confirm the findings in the present study (see below), yet the present findings can be explained and/or reconciled with those in the literature.

Firstly, GH has been shown to be compartmentalized in the vitreous, comprising a separate pool from plasma GH (Modanlou et al., 2006). Thus, while breakdown of the blood-retinal barrier (BRB) is a hallmark of DR (Cunha-Vaz, 2004), local GH levels may also play a role in the disease. Secondly, diabetics with IDDM show three distinct phases each with its own profile of plasma GH concentration (Wurzburger and Sonksen, 1996). In the first and third phases, plasma GH levels are high, while in the second phase, plasma GH levels are near normal (Wurzburger and Sonksen, 1996). Without adequate clinical information, it is impossible to know the phase of IDDM in which study subjects were found. Thirdly, as mentioned above, vitreous and plasma levels of GH were measured using an ELISA kit made with polyclonal anti-GH antibodies. While inter-assay and intra-assay variations in vitreous and plasma GH measurement were acceptable, complete validation of the kit for measurement of vitreous GH remains to be done. Regardless, while absolute levels of vitreous and plasma GH may be different from those obtained in previous studies, increase or decrease in GH levels can be reliably detected with this kit. In previous studies, the method of choice for measurement of plasma GH levels was radioimmunoassay. Finally, there is already controversy in the literature surrounding the role of plasma GH in the progression of DR. While some studies have implicated GH replacement therapy in the progression of DR-like symptoms in non-diabetics (Koller et al., 1998; Paterson et al., 2007), others have rejected this link (Blank et al., 2000; Urban et al., 2005). Additionally, following the observed DR in a patient with GH gene deletion, Laron and Weinburger (2005) have proposed a U-shaped effect whereby both GH/IGF-1 excess and GH/IGF-1 deficiency may lead to diabetic ocular complications.

E. Future work

In the present study, sequencing of GH-immunoreactive bands obtained via polyacrylamide gel electrophoresis (PAGE) would enable definitive characterization of those bands. Expanded clinical information on the severity of the observed ocular disorders [i.e. the stage of DR (Chiarelli et al., 2005)] would have allowed for a comparison between plasma and vitreous GH levels and severity of ocular disease. Information related to the duration of diabetes in the diabetics would also be useful, as the duration of diabetes is a factor in the progression of DR (Bliddal et al., 1983). In the present study, infiltration of serum proteins into the vitreous was expected in those with proliferative ocular disorders. As albumin has been used as a permeability marker of blood vessels (Spranger et al., 2001), levels of albumin in the vitreous could be a more accurate measure of protein infiltration into vitreous as compared to measurement of total vitreous protein performed in the present study. The GH ELISA kit used in the present study had not, to our knowledge, been previously used to quantify GH levels in vitreous fluid. While the kit's intra- and inter-assay variations and sensitivity for measuring GH in vitreous were measured and found to be acceptable, further validation is worthwhile. Specifically, reliably determining the concentration of vitreous samples spiked with known concentrations of control serum would indicate the accuracy of the ELISA kit. Given the results of plasma GH levels in the present study, further validation of the ELISA kit for detecting plasma GH is suggested. Measurement and comparison of samples containing known concentrations of bound GH, unbound, and isohormone/variant GH in both plasma and vitreous would aid in determining the

specificity of the ELISA kit. Performing radioimmunoassays on vitreous and plasma samples would serve to confirm or reject the results in the present study, and would allow for direct comparison to values and trends in previous studies.

V. REFERENCES

- Abu El-Asrar AM, Dralands L, Missotten L, Geboes K (2007) Expression of antiapoptotic and proapoptotic molecules in diabetic retinas. *Eye* **21**:238-245.
- Abu-El-Asrar AM, Dralands L, Missotten L, Al-Jadaan IA, Geboes K (2004) Expression of apoptosis markers in the retinas of human subjects with diabetes. *Invest Ophthalmol Vis Sci* **45**:2760-2766.
- Adamis AP, Miller JW, Bernal MT, D'Amico DJ, Folkman J, Yeo TK, Yeo KT (1994) Increased vascular endothelial growth factor levels in the vitreous of eyes with proliferative diabetic retinopathy. *Am J Ophthalmol* **118**:445-450.
- Alzaid AA, Dinneen SF, Melton LJ,3rd, Rizza RA (1994) The role of growth hormone in the development of diabetic retinopathy. *Diabetes Care* **17**:531-534.
- Antonetti DA, Barber AJ, Khin S, Lieth E, Tarbell JM, Gardner TW (1998) Vascular permeability in experimental diabetes is associated with reduced endothelial occludin content: Vascular endothelial growth factor decreases occludin in retinal endothelial cells. penn state retina research group. *Diabetes* **47**:1953-1959.
- Armstrong CS, Wuarin L, Ishii DN (2000) Uptake of circulating insulin-like growth factor-I into the cerebrospinal fluid of normal and diabetic rats and normalization of IGF-II mRNA content in diabetic rat brain. *J Neurosci Res* **59**:649-660.
- Asaria RH, Charteris DG (2006) Proliferative vitreoretinopathy: Developments in pathogenesis and treatment. *Compr Ophthalmol Update* **7**:179-185.
- Attia N, Caprio S, Jones TW, Heptulla R, Holcombe J, Silver D, Sherwin RS, Tamborlane WV (1999) Changes in free insulin-like growth factor-1 and leptin concentrations during acute metabolic decompensation in insulin withdrawn patients with type 1 diabetes. *J Clin Endocrinol Metab* **84**:2324-2328.
- Bahr M (2000) Live or let die - retinal ganglion cell death and survival during development and in the lesioned adult CNS. *Trends Neurosci* **23**:483-490.
- Ballantine EJ, Foxman S, Gorden P, Roth J (1981) Rarity of diabetic retinopathy in patients with acromegaly. *Arch Intern Med* **141**:1625-1627.
- Baudet ML, Sanders EJ, Harvey S (2003) Retinal growth hormone in the chick embryo. *Endocrinology* **144**:5459-5468.
- Baumann G (2002) Growth hormone binding protein. the soluble growth hormone receptor. *Minerva Endocrinol* **27**:265-276.
- Baumann G (2001) Growth hormone binding protein 2001. *J Pediatr Endocrinol Metab* **14**:355-375.

- Baumann G (1991) Growth hormone heterogeneity: Genes, isohormones, variants, and binding proteins. *Endocr Rev* **12**:424-449.
- Baumann G, Amburn KD, Buchanan TA (1987) The effect of circulating growth hormone-binding protein on metabolic clearance, distribution, and degradation of human growth hormone. *J Clin Endocrinol Metab* **64**:657-660.
- Baumann G, Stolar MW, Amburn K (1985) Molecular forms of circulating growth hormone during spontaneous secretory episodes and in the basal state. *J Clin Endocrinol Metab* **60**:1216-1220.
- Beck RW, Frank RN, Kraker RT, et al. (2001). The effect of growth hormone receptor antagonist drug on proliferative diabetic retinopathy. Growth Hormone Antagonist for Proliferative Diabetic Retinopathy Study Group. *Ophthalmology*, **108**:2266-2272.
- Biasotti A, Houssay BA (1932) Phlorrhizin diabetes in fasting or fed hypophysectomized dogs. *J Physiol* **77**:81-91.
- Bidlingmaier M, Strasburger CJ (2007) Growth hormone assays: Current methodologies and their limitations. *Pituitary* **10**:115-119.
- Bienvenu G, Seurin D, Grellier P, Froment P, Baudrimont M, Monget P, Le Bouc Y, Babajko S (2004) Insulin-like growth factor binding protein-6 transgenic mice: Postnatal growth, brain development, and reproduction abnormalities. *Endocrinology* **145**:2412-2420.
- Billestrup N, Nielsen JH (1991) The stimulatory effect of growth hormone, prolactin, and placental lactogen on beta-cell proliferation is not mediated by insulin-like growth factor-I. *Endocrinology* **129**:883-888.
- Bishop PN (2000) Structural macromolecules and supramolecular organisation of the vitreous gel. *Prog Retin Eye Res* **19**:323-344.
- Blank D, Riedl M, Reitner A, Schnack C, Scherthaner G, Clodi M, Frisch H, Luger A (2000) Growth hormone replacement therapy is not associated with retinal changes. *J Clin Endocrinol Metab* **85**:634-636.
- Bliddal H, Thorsteinsson B, Munkgaard S (1983) Long-term insulin-dependent diabetes mellitus with secondary pituitary insufficiency and regression of retinopathy. *Acta Med Scand* **214**:225-229.
- Boehm BO (2007) Use of long-acting somatostatin analogue treatment in diabetic retinopathy. *Dev Ophthalmol* **39**:111-121.
- Boulton M, Gregor Z, McLeod D, Charteris D, Jarvis-Evans J, Moriarty P, Khaliq A, Foreman D, Allamby D, Bardsley B (1997) Intravitreal growth factors in proliferative diabetic retinopathy: Correlation with neovascular activity and glycaemic management. *Br J Ophthalmol* **81**:228-233.

- Bourla DH, Laron Z, Snir M, Lilos P, Weinberger D, Axer-Siegel R (2006) Insulinlike growth factor I affects ocular development: A study of untreated and treated patients with laron syndrome. *Ophthalmology* **113**:1197.e1-1197.e5.
- Bresgen M, Heimann K (1995) Idiopathic macular foramen: New aspects of staging and possible therapeutic concepts. *Klin Monatsbl Augenheilkd* **206**:2-12.
- Brostedt P, Roos P (1989) Isolation of dimeric forms of human pituitary growth hormone. *Prep Biochem* **19**:217-229.
- Brucker AJ, Hopkins TB (2006) Retinal detachment surgery: The latest in current management. *Retina* **26**:S28-33.
- Burgos R, Mateo C, Canton A, Hernandez C, Mesa J, Simo R (2000) Vitreous levels of IGF-I, IGF binding protein 1, and IGF binding protein 3 in proliferative diabetic retinopathy: A case-control study. *Diabetes Care* **23**:80-83.
- Butler AA, Le Roith D (2001) Control of growth by the somatropic axis: Growth hormone and the insulin-like growth factors have related and independent roles. *Annu Rev Physiol* **63**:141-164.
- Carro E, Torres-Aleman I (2006) Serum insulin-like growth factor I in brain function. *Keio J Med* **55**:59-63.
- Cavallerano AA, Woodcome HT (1994) Idiopathic macular hole: A clinical review and current concepts in the diagnosis and management. *J Am Optom Assoc* **65**:845-854.
- Chanson P, Salenave S (2004) Diagnosis and treatment of pituitary adenomas. *Minerva Endocrinol* **29**:241-275.
- Chapman IM, Hartman ML, Pieper KS, Skiles EH, Pezzoli SS, Hintz RL, Thorner MO (1998) Recovery of growth hormone release from suppression by exogenous insulin-like growth factor I (IGF-I): Evidence for a suppressive action of free rather than bound IGF-I. *J Clin Endocrinol Metab* **83**:2836-2842.
- Chen JW, Hojlund K, Beck-Nielsen H, Sandahl Christiansen J, Orskov H, Frystyk J (2005) Free rather than total circulating insulin-like growth factor-I determines the feedback on growth hormone release in normal subjects. *J Clin Endocrinol Metab* **90**:366-371.
- Chiarelli F, Giannini C, Di Marzio D, Mohn A (2005) Treating diabetic retinopathy by tackling growth factor pathways. *Curr Opin Investig Drugs* **6**:395-409.
- Choh V, Sivak JG (2005) Lenticular accommodation in relation to ametropia: The chick model. *J Vis* **5**:165-176.

- Clapp C, Aranda J, Gonzalez C, Jeziorski MC, Martinez de la Escalera, G. (2006) Vasoinhibins: Endogenous regulators of angiogenesis and vascular function. *Trends Endocrinol Metab* **17**:301-307.
- Coculescu M (1999) Blood-brain barrier for human growth hormone and insulin-like growth factor-I. *J Pediatr Endocrinol Metab* **12**:113-124.
- Cohen A (1992). The retina. In: Adler's Physiology of the Eye, pp. 579-615. St. Louis, MI: Mosby-Year.
- Cooke RM, Harvey TS, Campbell ID (1991) Solution structure of human insulin-like growth factor 1: A nuclear magnetic resonance and restrained molecular dynamics study. *Biochemistry* **30**:5484-5491.
- Corbacho AM, Martinez De La Escalera, G., Clapp C (2002) Roles of prolactin and related members of the prolactin/growth hormone/placental lactogen family in angiogenesis. *J Endocrinol* **173**:219-238.
- Corcuff JB, Ogor C, Kerlan V, Rougier MB, Bercovich M, Roger P (1997) Ocular naevus and melanoma in acromegaly. *Clin Endocrinol (Oxf)* **47**:119-121.
- Costa A, Zoppetti G, Benedetto C, Bertino E, Marozio L, Fabris C, Arisio R, Giraudi GF, Testori O, Ariano M (1993) Immunolike growth hormone substance in tissues from human embryos/fetuses and adults. *J Endocrinol Invest* **16**:625-633.
- Cotes PM, Crichton JA (1949) Galactopoietic activity of purified anterior pituitary growth hormone. *Nature* **164**:992.
- Cunha-Vaz JG (2004) The blood-retinal barriers system. basic concepts and clinical evaluation. *Exp Eye Res* **78**:715-721.
- Cunha-Vaz JG (1997) The blood-ocular barriers: Past, present, and future. *Doc Ophthalmol* **93**:149-157.
- Cunha-Vaz JG (1976) The blood-retinal barriers. *Doc Ophthalmol* **41**:287-327.
- Das A, McGuire PG (2003) Retinal and choroidal angiogenesis: Pathophysiology and strategies for inhibition. *Prog Retin Eye Res* **22**:721-748.
- Daughaday WH, Hall K, Raben MS, Salmon WD, Jr, van den Brande JL, van Wyk JJ (1972) Somatomedin: Proposed designation for sulphation factor. *Nature* **235**:107.
- de la Rosa EJ, de Pablo F (2000) Cell death in early neural development: Beyond the neurotrophic theory. *Trends Neurosci* **23**:454-458.
- De Palo EF, De Filippis V, Gatti R, Spinella P (2006a) Growth hormone isoforms and segments/fragments: Molecular structure and laboratory measurement. *Clin Chim Acta* **364**:67-76.

- De Palo EF, Gatti R, Antonelli G, Spinella P (2006b) Growth hormone isoforms, segments/fragments: Does a link exist with multifunctionality? *Clin Chim Acta* **364**:77-81.
- DeNoto FM, Moore DD, Goodman HM (1981) Human growth hormone DNA sequence and mRNA structure: Possible alternative splicing. *Nucleic Acids Res* **9**:3719-3730.
- Di Rocco M, Picco P, Arslanian A, Restagno G, Perfumo F, Buoncompagni A, Gattorno M, Borrone C (1997) Retinitis pigmentosa, hypopituitarism, nephronophthisis, and mild skeletal dysplasia (RHYNS): A new syndrome? *Am J Med Genet* **73**:1-4.
- Diaz-Casares A, Leon Y, de la Rosa EJ, Varela-Nieto I (2005) Regulation of vertebrate sensory organ development: A scenario for growth hormone and insulin-like growth factors action. *Adv Exp Med Biol* **567**:221-242.
- Dills DG, Moss SE, Klein R, Klein BE, Davis M (1990) Is insulinlike growth factor I associated with diabetic retinopathy? *Diabetes* **39**:191-195.
- Drake AJ, Lowis SP, Bouffet E, Crowne EC (2000) Growth hormone hypersecretion in a girl with neurofibromatosis type 1 and an optic nerve glioma: Resolution following chemotherapy. *Horm Res* **53**:305-308.
- Ebdrup L, Fisker S, Sorensen HH, Ranke MB, Orskov H (1999) Variety in growth hormone determinations due to use of different immunoassays and to the interference of growth hormone-binding protein. *Horm Res* **51 Suppl 1**:20-26.
- Feldmann B, Jehle PM, Mohan S, Lang GE, Lang GK, Brueckel J, Boehm BO (2000) Diabetic retinopathy is associated with decreased serum levels of free IGF-I and changes of IGF-binding proteins. *Growth Horm IGF Res* **10**:53-59.
- Felinski EA, Antonetti DA (2005) Glucocorticoid regulation of endothelial cell tight junction gene expression: Novel treatments for diabetic retinopathy. *Curr Eye Res* **30**:949-957.
- Forrester JV (2004) Shedding light on a new eye protein. *Br J Ophthalmol* **88**:602-603.
- Frank RN (2004) Diabetic retinopathy. *N Engl J Med* **350**:48-58.
- Frystyk J (2007) Utility of free igf-I measurements. *Pituitary* **10**:181-187.
- Frystyk J (2005) The growth hormone hypothesis - 2005 revision. *Horm Metab Res* **37 Suppl 1**:44-48.
- Frystyk J (2004) Free insulin-like growth factors -- measurements and relationships to growth hormone secretion and glucose homeostasis. *Growth Horm IGF Res* **14**:337-375.

- Frystyk J, Bek T, Flyvbjerg A, Skjaerbaek C, Orskov H (2003) The relationship between the circulating IGF system and the presence of retinopathy in type 1 diabetic patients. *Diabet Med* **20**:269-276.
- Fukata J, Diamond DJ, Martin JB (1985) Effects of rat growth hormone (rGH)-releasing factor and somatostatin on the release and synthesis of rGH in dispersed pituitary cells. *Endocrinology* **117**:457-467.
- Funatsu H, Yamashita T, Yamashita H (2006) Vitreous fluid biomarkers. *Adv Clin Chem* **42**:111-166.
- Funatsu H, Yamashita H, Noma H, Mimura T, Nakamura S, Sakata K, Hori S (2005a) Aqueous humor levels of cytokines are related to vitreous levels and progression of diabetic retinopathy in diabetic patients. *Graefes Arch Clin Exp Ophthalmol* **243**:3-8.
- Funatsu H, Yamashita H, Sakata K, Noma H, Mimura T, Suzuki M, Eguchi S, Hori S (2005b) Vitreous levels of vascular endothelial growth factor and intercellular adhesion molecule 1 are related to diabetic macular edema. *Ophthalmology* **112**:806-816.
- Funatsu H, Yamashita H, Ikeda T, Nakanishi Y, Kitano S, Hori S (2002a) Angiotensin II and vascular endothelial growth factor in the vitreous fluid of patients with diabetic macular edema and other retinal disorders. *Am J Ophthalmol* **133**:537-543.
- Funatsu H, Yamashita H, Nakanishi Y, Hori S (2002b) Angiotensin II and vascular endothelial growth factor in the vitreous fluid of patients with proliferative diabetic retinopathy. *Br J Ophthalmol* **86**:311-315.
- Geerts L, Pertile G, van de Sompel W, Moreels T, Claes C (2004) Vitrectomy for epiretinal membranes: Visual outcome and prognostic criteria. *Bull Soc Belge Ophtalmol* (293):7-15.
- Gerhardinger C, McClure KD, Romeo G, Podesta F, Lorenzi M (2001) IGF-I mRNA and signaling in the diabetic retina. *Diabetes* **50**:175-183.
- Gick GG, Zeytin FN, Brazeau P, Ling NC, Esch FS, Bancroft C (1984) Growth hormone-releasing factor regulates growth hormone mRNA in primary cultures of rat pituitary cells. *Proc Natl Acad Sci U S A* **81**:1553-1555.
- Glaser BM, Michels RG, Kuppermann BD, Sjaarda RN, Pena RA (1992) Transforming growth factor-beta 2 for the treatment of full-thickness macular holes. A prospective randomized study. *Ophthalmology* **99**:1162-72; discussion 1173.
- Goldenberg N, Barkan A (2007) Factors regulating growth hormone secretion in humans. *Endocrinol Metab Clin North Am* **36**:37-55.
- Golshani MR, Khoobehi B, Peyman GA (1993) Calcein: A new dye for evaluation of the blood-retinal barrier by fluorophotometry. *Int Ophthalmol* **17**:349-353.

- Grabner G, Boltz G, Forster O (1980) Macrophage-like properties of human hyalocytes. *Invest Ophthalmol Vis Sci* **19**:333-340.
- Grant MB, Mames RN, Fitzgerald C, Hazariwala KM, Cooper-DeHoff R, Caballero S, Estes KS (2000) The efficacy of octreotide in the therapy of severe nonproliferative and early proliferative diabetic retinopathy: A randomized controlled study. *Diabetes Care* **23**:504-509.
- Greco AV, Ricci B, Altomonte L, Rebutzi AG, Manna R, Ghirlanda G (1979) GH secretion in open-angle glaucoma. *Ophthalmologica* **179**:168-172.
- Grigorian AL, Bustamante JJ, Hernandez P, Martinez AO, Haro LS (2005) Extraordinarily stable disulfide-linked homodimer of human growth hormone. *Protein Sci* **14**:902-913.
- Growth Hormone Antagonist for Proliferative Diabetic Retinopathy Study Group (2001) The effect of a growth hormone receptor antagonist drug on proliferative diabetic retinopathy. *Ophthalmology* **108**:2266-2272.
- Hansen AP (1973) Abnormal serum growth hormone response to exercise in maturity-onset diabetics. *Diabetes* **22**:619-628.
- Hansen R, Koller EA, Malozowski S (2000) Full remission of growth hormone (GH)-induced retinopathy after GH treatment discontinuation: Long-term follow-up. *J Clin Endocrinol Metab* **85**:2627.
- Hardouin S, Gournelen M, Noguez P, Seurin D, Roghani M, Le Bouc Y, Pova G, Merimee TJ, Hossenlopp P, Binoux M (1989) Molecular forms of serum insulin-like growth factor (IGF)-binding proteins in man: Relationships with growth hormone and IGFs and physiological significance. *J Clin Endocrinol Metab* **69**:1291-1301.
- Haro LS, Lewis UJ, Garcia M, Bustamante J, Martinez AO, Ling NC (1996) Glycosylated human growth hormone (hGH): A novel 24 kDa hGH-N variant. *Biochem Biophys Res Commun* **228**:549-556.
- Harvey S, Baudet ML, Sanders EJ (2007). Growth hormone and developmental ocular function: Clinical and basic studies. *Pediatr Endocrinol Rev*. In press.
- Harvey S, Baudet ML, Sanders EJ (2006) Retinal growth hormone in perinatal and adult rats. *J Mol Neurosci* **28**:257-264.
- Harvey S, Kakebeeke M, Sanders EJ (2004) Growth hormone localization in the neural retina and retinal pigmented epithelium of embryonic chicks. *J Mol Neurosci* **22**:139-145.
- Harvey S, Kakebeeke M, Murphy AE, Sanders EJ (2003) Growth hormone in the nervous system: Autocrine or paracrine roles in retinal function? *Can J Physiol Pharmacol* **81**:371-384.

- Harvey S, Hull K (2003) Neural growth hormone: An update. *J Mol Neurosci* **20**:1-14.
- Harvey S, Johnson CD, Sanders EJ (2001) Growth hormone in neural tissues of the chick embryo. *J Endocrinol* **169**:487-498.
- Harvey S, Johnson CD, Sharma P, Sanders EJ, Hull KL (1998) Growth hormone: A paracrine growth factor in embryonic development? *Comp Biochem Physiol C Pharmacol Toxicol Endocrinol* **119**:305-315.
- Harvey S, Hull KL (1997) Growth hormone. A paracrine growth factor? *Endocrine* **7**:267-279.
- Harvey S, Scanes CG, Daughaday WH (1995) Growth hormone. Boca Baton: CRC Press.
- Harvey S, Davison TF, Chadwick A (1979) Ontogeny of growth hormone and prolactin secretion in the domestic fowl (*Gallus domesticus*). *Gen Comp Endocrinol* **39**:270-273.
- Hattori M, Fukuchi S (1974) Studies on ERG of KK mice especially on oscillatory potentials. 3. influence of ovine growth hormone (author's transl). *Nippon Ganka Gakkai Zasshi* **78**:705-714.
- Hedera P, Gorski JL (2001) Retinitis pigmentosa, growth hormone deficiency, and acromelic skeletal dysplasia in two brothers: Possible familial RHYNS syndrome. *Am J Med Genet* **101**:142-145.
- Hellstrom A, Svensson E, Carlsson B, Niklasson A, Albertsson-Wikland K (1999) Reduced retinal vascularization in children with growth hormone deficiency. *J Clin Endocrinol Metab* **84**:795-798.
- Hernandez-Sanchez C, Lopez-Carranza A, Alarcon C, de La Rosa EJ, de Pablo F (1995) Autocrine/paracrine role of insulin-related growth factors in neurogenesis: Local expression and effects on cell proliferation and differentiation in retina. *Proc Natl Acad Sci U S A* **92**:9834-9838.
- Hikino S, Ihara K, Yamamoto J, Takahata Y, Nakayama H, Kinukawa N, Narazaki Y, Hara T (2001) Physical growth and retinopathy in preterm infants: Involvement of IGF-I and GH. *Pediatr Res* **50**:732-736.
- Ho AC, Guyer DR, Fine SL (1998) Macular hole. *Surv Ophthalmol* **42**:393-416.
- Ho KK, Hoffman DM (1993) Aging and growth hormone. *Horm Res* **40**:80-86.
- Ho KY, Evans WS, Blizzard RM, Veldhuis JD, Merriam GR, Samojlik E, Furlanetto R, Rogol AD, Kaiser DL, Thorner MO (1987) Effects of sex and age on the 24-hour profile of growth hormone secretion in man: Importance of endogenous estradiol concentrations. *J Clin Endocrinol Metab* **64**:51-58.

- Hojvat S, Baker G, Kirsteins L, Lawrence AM (1982) Growth hormone (GH) immunoreactivity in the rodent and primate CNS: distribution, characterization and presence posthypophysectomy. *Brain Res.* **239**:543-557.
- Holt RI, Simpson HL, Sonksen PH (2003) The role of the growth hormone-insulin-like growth factor axis in glucose homeostasis. *Diabet Med* **20**:3-15.
- Hoyt WF, Kaplan SL, Grumbach MM, Glaser JS (1970) Septo-optic dysplasia and pituitary dwarfism. *Lancet* **1**:893-894.
- Hyer SL, Sharp PS, Brooks RA, Burrin JM, Kohner EM (1989a) A two-year follow-up study of serum insulinlike growth factor-I in diabetics with retinopathy. *Metabolism* **38**:586-589.
- Hyer SL, Sharp PS, Sleightholm M, Burrin JM, Kohner EM (1989b) Progression of diabetic retinopathy and changes in serum insulin-like growth factor I (IGF I) during continuous subcutaneous insulin infusion (CSII). *Horm Metab Res* **21**:18-22.
- Isaksson OG, Jansson JO, Gause IA (1982) Growth hormone stimulates longitudinal bone growth directly. *Science* **216**:1237-1239.
- James CR, Cotlier E (1983) Fate of insulin in the retina: An autoradiographic study. *Br J Ophthalmol* **67**:80-88.
- Jansen M, van Schaik FM, Ricker AT, Bullock B, Woods DE, Gabbay KH, Nussbaum AL, Sussenbach JS, Van den Brande JL (1983) Sequence of cDNA encoding human insulin-like growth factor I precursor. *Nature* **306**:609-611.
- Janssen JA, Jacobs ML, Derkx FH, Weber RF, van der Lely AJ, Lamberts SW (1997) Free and total insulin-like growth factor I (IGF-I), IGF-binding protein-1 (IGFBP-1), and IGFBP-3 and their relationships to the presence of diabetic retinopathy and glomerular hyperfiltration in insulin-dependent diabetes mellitus. *J Clin Endocrinol Metab* **82**:2809-2815.
- Johansen K, Hansen AP (1971) Diurnal serum growth hormone levels in poorly and well-controlled juvenile diabetics. *Diabetes* **20**:239-245.
- Johansen K, Hansen AP (1969) High 24-hour level of serum growth hormone in juvenile diabetics. *Br Med J* **2**:356-357.
- Jones JJ, Clemmons DR (1995) Insulin-like growth factors and their binding proteins: Biological actions. *Endocr Rev* **16**:3-34.
- Jorgensen JO, Moller L, Krag M, Billestrup N, Christiansen JS (2007) Effects of growth hormone on glucose and fat metabolism in human subjects. *Endocrinol Metab Clin North Am* **36**:75-87.

- Juul A (2003) Serum levels of insulin-like growth factor I and its binding proteins in health and disease. *Growth Horm IGF Res* **13**:113-170.
- Juul A, Holm K, Kastrup KW, Pedersen SA, Michaelsen KF, Scheike T, Rasmussen S, Muller J, Skakkebaek NE (1997) Free insulin-like growth factor I serum levels in 1430 healthy children and adults, and its diagnostic value in patients suspected of growth hormone deficiency. *J Clin Endocrinol Metab* **82**:2497-2502.
- Kaneko K, Komine S, Maeda T, Ohta M, Tsushima T, Shizume K (1985) Growth hormone responses to growth-hormone-releasing hormone and thyrotropin-releasing hormone in diabetic patients with and without retinopathy. *Diabetes* **34**:710-713.
- Kjeldsen H, Hansen AP, Lundbaek K (1975) Twenty-four-hour serum growth hormone levels in maturity-onset diabetics. *Diabetes* **24**:977-982.
- Klein R, Klein BE, Moss SE (1992) Epidemiology of proliferative diabetic retinopathy. *Diabetes Care* **15**:1875-1891.
- Kmera-Muszynska M, Zgliczynski W (2000) Does macular hole formation have a hormonal cause? *Klin Oczna* **102**:191-193.
- Kohner EM, Oakley NW (1975) Diabetic retinopathy. *Metabolism* **24**:1085-1102.
- Koller EA, Green L, Gertner JM, Bost M, Malozowski SN (1998) Retinal changes mimicking diabetic retinopathy in two nondiabetic, growth hormone-treated patients. *J Clin Endocrinol Metab* **83**:2380-2383.
- Kon CH, Occleston NL, Aylward GW, Khaw PT (1999) Expression of vitreous cytokines in proliferative vitreoretinopathy: A prospective study. *Invest Ophthalmol Vis Sci* **40**:705-712.
- Kostyo JL, Skottner A, Brostedt P, Roos P, Cameron CM, Forsman A, Fryklund L, Adamafio NA, Skoog B (1987) Biological characterization of purified native 20-kDa human growth hormone. *Biochim Biophys Acta* **925**:314-324.
- Kostyo JL (1968) Rapid effects of growth hormone on amino acid transport and protein synthesis. *Ann N Y Acad Sci* **148**:389-407.
- Kowluru RA, Tang J, Kern TS (2001) Abnormalities of retinal metabolism in diabetes and experimental galactosemia. VII. effect of long-term administration of antioxidants on the development of retinopathy. *Diabetes* **50**:1938-1942.
- Koyama R, Nakanishi T, Ikeda T, Shimizu A (2003) Catalogue of soluble proteins in human vitreous humor by one-dimensional sodium dodecyl sulfate-polyacrylamide gel electrophoresis and electrospray ionization mass spectrometry including seven angiogenesis-regulating factors. *J Chromatogr B Analyt Technol Biomed Life Sci* **792**:5-21.

- Kurmasheva RT, Houghton PJ (2006) IGF-I mediated survival pathways in normal and malignant cells. *Biochim Biophys Acta* **1766**:1-22.
- Kyle CV, Evans MC, Odell WD (1981). Growth hormone-like material in normal human tissues. *J Clin Endocrinol Metab* **53**:1138-1144.
- La Cour M, Friis J (2002) Macular holes: Classification, epidemiology, natural history and treatment. *Acta Ophthalmol Scand* **80**:579-587.
- Lai ZN, Emtner M, Roos P, Nyberg F (1991) Characterization of putative growth hormone receptors in human choroid plexus. *Brain Res* **546**:222-226.
- Lang GE (2004) Pharmacological treatment of diabetic retinopathy. *Ophthalmology* **101**:1165-1170.
- Laron Z, Weinburger D (2005). Diabetic retinopathy, nephropathy and cardiovascular disease in a patient with GH gene deletion. *Clin Endocrinology*. **63**:699-700.
- Lawrence MS, Azar DT (2002) Myopia and models and mechanisms of refractive error control. *Ophthalmol Clin North Am* **15**:127-133.
- Le Roith D, Bondy C, Yakar S, Liu JL, Butler A (2001) The somatomedin hypothesis: 2001. *Endocr Rev* **22**:53-74.
- Lecomte CM, Renard A, Martial JA (1987) A new natural hGH variant--17.5 kd-- produced by alternative splicing. an additional consensus sequence which might play a role in branchpoint selection. *Nucleic Acids Res* **15**:6331-6348.
- Lengyel AM (2006) Novel mechanisms of growth hormone regulation: Growth hormone-releasing peptides and ghrelin. *Braz J Med Biol Res* **39**:1003-1011.
- Leung KC, Johannsson G, Leong GM, Ho KK (2004) Estrogen regulation of growth hormone action. *Endocr Rev* **25**:693-721.
- Lewis UJ, Sinha YN, Lewis GP (2000) Structure and properties of members of the hGH family: A review. *Endocr J* **47 Suppl**:S1-8.
- Lewis UJ, Singh RN, Bonewald LF, Seavey BK (1981) Altered proteolytic cleavage of human growth hormone as a result of deamidation. *J Biol Chem* **256**:11645-11650.
- Lewis UJ, Bonewald LF, Lewis LJ (1980) The 20,000-dalton variant of human growth hormone: Location of the amino acid deletions. *Biochem Biophys Res Commun* **92**:511-516.
- Lewis UJ, Singh RN, Bonewald LF, Lewis LJ, Vanderlaan WP (1979) Human growth hormone: Additional members of the complex. *Endocrinology* **104**:1256-1265.

- Liberti JP, Joshi GS (1986) Synthesis and secretion of phosphorylated growth hormone by rat pituitary glands in vitro. *Biochem Biophys Res Commun* **137**:806-812.
- Lightman SL, Palestine AG, Rapoport SI, Rechthand E (1987) Quantitative assessment of the permeability of the rat blood-retinal barrier to small water-soluble non-electrolytes. *J Physiol* **389**:483-490.
- Lundbaek K, Christensen NJ, Jensen VA, Johansen K, Olsen TS, Hansen AP, Orskov H, Osterby R (1971) The pathogenesis of diabetic angiopathy and growth hormone. *Dan Med Bull* **18**:1-7.
- Lundbaek K, Christensen NJ, Jensen VA, Johansen K, Olsen TS, Hansen AP, Orskov H, Osterby R (1970) Diabetes, diabetic angiopathy, and growth hormone. *Lancet* **2**:131-133.
- Maberley D, Cui JZ, Matsubara JA (2006) Vitreous leptin levels in retinal disease. *Eye* **20**:801-804.
- Maciag T, Forand R, Ilsley S, Cerundolo J, Greenlee R, Kelley PR, Canalis E (1980) The generation of sulfation factor activity by proteolytic modification of growth hormone. *J Biol Chem* **255**:6064-6070.
- Mandelcorn E, Khan Y, Javorska L, Cohen J, Howarth D, Mandelcorn M (2003) Idiopathic epiretinal membranes: Cell type, growth factor expression, and fluorescein angiographic and retinal photographic correlations. *Can J Ophthalmol* **38**:457-463.
- Manfre L, Midiri M, Giuffre G, Mangiameli A, Cardella G, Ponte F, De Maria M, Lagalla R (1997) Blood-ocular barrier damage: Use of contrast-enhanced MRI. *Eur Radiol* **7**:110-114.
- Matsuo T, Okada Y, Shiraga F, Yanagawa T (1998) TIMP-1 and TIMP-2 levels in vitreous and subretinal fluid. *Jpn J Ophthalmol* **42**:377-380.
- McCombe M, Lightman S, Eckland DJ, Hamilton AM, Lightman SL (1991) Effect of a long-acting somatostatin analogue (BIM23014) on proliferative diabetic retinopathy: A pilot study. *Eye* **5 (Pt 5)**:569-575.
- Merimee TJ, Zapf J, Froesch ER (1983) Insulin-like growth factors. studies in diabetics with and without retinopathy. *N Engl J Med* **309**:527-530.
- Merimee TJ (1978) A follow-up study of vascular disease in growth-hormone-deficient dwarfs with diabetes. *N Engl J Med* **298**:1217-1222.
- Meyer-Schwickerath R, Pfeiffer A, Blum WF, Freyberger H, Klein M, Losche C, Rollmann R, Schatz H (1993) Vitreous levels of the insulin-like growth factors I and II, and the insulin-like growth factor binding proteins 2 and 3, increase in neovascular eye disease. studies in nondiabetic and diabetic subjects. *J Clin Invest* **92**:2620-2625.

- Miller RF (1989). The physiology and morphology of the vertebrate retina. In: Retina, volume 1, pp. 83-106. St Louis, MI: C.V. Mosby.
- Mitchell P, Smith W, Chey T, Wang JJ, Chang A (1997) Prevalence and associations of epiretinal membranes. the blue mountains eye study, australia. *Ophthalmology* **104**:1033-1040.
- Modanlou HD, Gharraee Z, Hasan J, Waltzman J, Nageotte S, Beharry KD (2006) Ontogeny of VEGF, IGF-I, and GH in neonatal rat serum, vitreous fluid, and retina from birth to weaning. *Invest Ophthalmol Vis Sci* **47**:738-744.
- Moller N, Copeland KC, Nair KS (2007) Growth hormone effects on protein metabolism. *Endocrinol Metab Clin North Am* **36**:89-100.
- Mori K, Yoneya S, Hayashi N, Abe T, Isono H, Nishiyama Y (1997) Angiography by scanning laser ophthalmoscope with fluorescein compounds of different physicochemical properties. *Nippon Ganka Gakkai Zasshi* **101**:318-326.
- Mutz I, Millner M, Borckenstein M (1984) Optic nerve hypoplasia and growth hormone deficiency: De morsier's syndrome. *Wien Klin Wochenschr* **96**:432-435.
- Noma H, Funatsu H, Yamasaki M, Tsukamoto H, Mimura T, Sone T, Jian K, Sakamoto I, Nakano K, Yamashita H, Minamoto A, Mishima HK (2005) Pathogenesis of macular edema with branch retinal vein occlusion and intraocular levels of vascular endothelial growth factor and interleukin-6. *Am J Ophthalmol* **140**:256-261.
- Nyberg F (2000) Growth hormone in the brain: Characteristics of specific brain targets for the hormone and their functional significance. *Front Neuroendocrinol* **21**:330-348.
- Orskov H (1996) Somatostatin, growth hormone, insulin-like growth factor-1, and diabetes: Friends or foes? *Metabolism* **45**:91-95.
- Otteson DC, Cirenza PF, Hitchcock PF (2002) Persistent neurogenesis in the teleost retina: Evidence for regulation by the growth-hormone/insulin-like growth factor-I axis. *Mech Dev* **117**:137-149.
- Pan W, Yu Y, Cain CM, Nyberg F, Couraud PO, Kastin AJ (2005) Permeation of growth hormone across the blood-brain barrier. *Endocrinology* **146**:4898-4904.
- Pardridge WM (1986) Receptor-mediated peptide transport through the blood-brain barrier. *Endocr Rev* **7**:314-330.
- Pardridge WM, Eisenberg J, Cefalu WT (1985) Absence of albumin receptor on brain capillaries in vivo or in vitro. *Am J Physiol* **249**:E264-7.
- Parentin F, Perissutti P (2005) Congenital growth hormone deficiency and eye refraction: A longitudinal study. *Ophthalmologica* **219**:226-231.

- Parentin F, Tonini G, Perissutti P (2004) Refractive evaluation in children with growth defect. *Curr Eye Res* **28**:11-15.
- Park SK, Chang SH, Cho SB, Baek HS, Lee DY (1994) Cockayne syndrome: A case with hyperinsulinemia and growth hormone deficiency. *J Korean Med Sci* **9**:74-77.
- Paterson WF, Kelly B, Newman W, Savage MO, Camacho-Hubner C, Dutton GN, Tolmie J, Donaldson MD (2007) Deterioration of visual acuity associated with growth hormone therapy in a child with extreme short stature and high hypermetropia. *Horm Res* **67**:67-72.
- Pfeiffer A, Spranger J, Meyer-Schwickerath R, Schatz H (1997) Growth factor alterations in advanced diabetic retinopathy: A possible role of blood retina barrier breakdown. *Diabetes* **46 Suppl 2**:S26-30.
- Pivnick EK, Velagaleti GV, Wilroy RS, Smith ME, Rose SR, Tipton RE, Tharapel AT (1996) Jacobsen syndrome: Report of a patient with severe eye anomalies, growth hormone deficiency, and hypothyroidism associated with deletion 11 (q23q25) and review of 52 cases. *J Med Genet* **33**:772-778.
- Platz EA, Pollak MN, Rimm EB, Majeed N, Tao Y, Willett WC, Giovannucci E (1999) Racial variation in insulin-like growth factor-1 and binding protein-3 concentrations in middle-aged men. *Cancer Epidemiol Biomarkers Prev* **8**:1107-1110.
- Popii V, Baumann G (2004) Laboratory measurement of growth hormone. *Clin Chim Acta* **350**:1-16.
- Poulsen JE (1953). Recovery from retinopathy in a case of diabetes with Simmonds' disease. *Diabetes*. **2**:7-12.
- Powell ED, Frantz AG, Rabkin MT, Field RA (1966) Growth hormone in relation to diabetic retinopathy. *N Engl J Med* **275**:922-925.
- Probst K, Fijnheer R, Schellekens P, Rothova A (2004) Intraocular and plasma levels of cellular fibronectin in patients with uveitis and diabetes mellitus. *Br J Ophthalmol* **88**:667-672.
- Pulford BE, Ishii DN (2001) Uptake of circulating insulin-like growth factors (IGFs) into cerebrospinal fluid appears to be independent of the IGF receptors as well as IGF-binding proteins. *Endocrinology* **142**:213-220.
- Qaum T, Xu Q, Jousseaume AM, Clemens MW, Qin W, Miyamoto K, Hassessian H, Wiegand SJ, Rudge J, Yancopoulos GD, Adamis AP (2001) VEGF-initiated blood-retinal barrier breakdown in early diabetes. *Invest Ophthalmol Vis Sci* **42**:2408-2413.
- Rajaram S, Baylink DJ, Mohan S (1997) Insulin-like growth factor-binding proteins in serum and other biological fluids: Regulation and functions. *Endocr Rev* **18**:801-831.

- Reinhardt RR, Bondy CA (1994) Insulin-like growth factors cross the blood-brain barrier. *Endocrinology* **135**:1753-1761.
- Ridderstrale M (2005) Signaling mechanism for the insulin-like effects of growth hormone--another example of a classical hormonal negative feedback loop. *Curr Drug Targets Immune Endocr Metabol Disord* **5**:79-92.
- Rymaszewski Z, Cohen RM, Chomczynski P (1991) Human growth hormone stimulates proliferation of human retinal microvascular endothelial cells in vitro. *Proc Natl Acad Sci USA* **88**:617-621.
- Sami AJ (2007) Structure-function relation of somatotropin with reference to molecular modeling. *Curr Protein Pept Sci* **8**:283-292.
- Sanders EJ, Parker E, Aramburo C, Harvey S (2005) Retinal growth hormone is an anti-apoptotic factor in embryonic retinal ganglion cell differentiation. *Exp Eye Res* **81**:551-560.
- Sanders EJ, Walter MA, Parker E, Aramburo C, Harvey S (2003) Opticin binds retinal growth hormone in the embryonic vitreous. *Invest Ophthalmol Vis Sci* **44**:5404-5409.
- Savine R, Sonksen P (2000) Growth hormone - hormone replacement for the somatopause? *Horm Res* **53 Suppl 3**:37-41.
- Scacchi M, Pincelli AI, Cavagnini F (1999) Growth hormone in obesity. *Int J Obes Relat Metab Disord* **23**:260-271.
- Schaub C, Boujard O, Brouard N, Drouin P, Le Devehat C, Lemoine A, Mejean L, Mounier F, Regnault F, Saudax A (1984) Computer analysis of ocular results following selective blockade of growth-hormone in diabetic retinopathy. A collaborative study. *Metab Ophthalmol* **8**:35-42.
- Schepper JM, Hughes EF, Postel-Vinay MC, Hughes JP (1984) Cleavage of growth hormone by rabbit liver plasmalemma enhances binding. *J Biol Chem* **259**:12945-12948.
- Seigel GM, Lupien SB, Campbell LM, Ishii DN (2006) Systemic IGF-I treatment inhibits cell death in diabetic rat retina. *J Diabetes Complications* **20**:196-204.
- Sherlock M, Toogood AA (2007) Aging and the growth hormone/insulin like growth factor-I axis. *Pituitary* **10**:189-203.
- Shurka E, Laron Z (1975) Adjustment and rehabilitation problems of children and adolescents with growth retardation. I. familial dwarfism with high plasma immunoreactive human growth hormone. *Isr J Med Sci* **11**:352-357.
- Simo R, Hernandez C, Segura RM, Garcia-Arumi J, Sararols L, Burgos R, Canton A, Mesa J (2003) Free insulin-like growth factor 1 in the vitreous fluid of diabetic patients

with proliferative diabetic retinopathy: A case-control study. *Clin Sci (Lond)* **104**:223-230.

Simo R, Lecube A, Sararols L, Garcia-Arumi J, Segura RM, Casamitjana R, Hernandez C (2002) Deficit of somatostatin-like immunoreactivity in the vitreous fluid of diabetic patients: Possible role in the development of proliferative diabetic retinopathy. *Diabetes Care* **25**:2282-2286.

Sinha YN, Jacobsen BP (1994) Human growth hormone (hGH)-(44-191), a reportedly diabetogenic fragment of hGH, circulates in human blood: Measurement by radioimmunoassay. *J Clin Endocrinol Metab* **78**:1411-1418.

Skottner A, Forsman A, Skoog B, Kostyo JL, Cameron CM, Adamafo NA, Thorngren KG, Hagerman M (1988) Biological characterization of charge isomers of human growth hormone. *Acta Endocrinol (Copenh)* **118**:14-21.

Smiddy WE, Glaser BM, Thompson JT, Sjaarda RN, Flynn HW, Jr, Hanham A, Murphy RP (1993) Transforming growth factor-beta 2 significantly enhances the ability to flatten the rim of subretinal fluid surrounding macular holes. preliminary anatomic results of a multicenter prospective randomized study. *Retina* **13**:296-301.

Smith LE, Kopchick JJ, Chen W, Knapp J, Kinose F, Daley D, Foley E, Smith RG, Schaeffer JM (1997) Essential role of growth hormone in ischemia-induced retinal neovascularization. *Science* **276**:1706-1709.

Sonksen PH, Russell-Jones D, Jones RH (1993) Growth hormone and diabetes mellitus. A review of sixty-three years of medical research and a glimpse into the future? *Horm Res* **40**:68-79.

Sotiropoulos A, Ohanna M, Kedzia C, Menon RK, Kopchick JJ, Kelly PA, Pende M (2006) Growth hormone promotes skeletal muscle cell fusion independent of insulin-like growth factor 1 up-regulation. *Proc Natl Acad Sci U S A* **103**:7315-7320.

Spoerri PE, Ellis EA, Tarnuzzer RW, Grant MB (1998) Insulin-like growth factor: Receptor and binding proteins in human retinal endothelial cell cultures of diabetic and non-diabetic origin. *Growth Horm IGF Res* **8**:125-132.

Spranger J, Mohlig M, Osterhoff M, Buhnen J, Blum WF, Pfeiffer AF (2001) Retinal photocoagulation does not influence intraocular levels of IGF-I, IGF-II and IGF-BP3 in proliferative diabetic retinopathy-evidence for combined treatment of PDR with somatostatin analogues and retinal photocoagulation? *Horm Metab Res* **33**:312-316.

Stolar MW, Amburn K, Baumann G (1984a) Plasma "big" and "big-big" growth hormone (GH) in man: An oligomeric series composed of structurally diverse GH monomers. *J Clin Endocrinol Metab* **59**:212-218.

- Stolar MW, Baumann G, Vance ML, Thorner MO (1984b) Circulating growth hormone forms after stimulation of pituitary secretion with growth hormone-releasing factor in man. *J Clin Endocrinol Metab* **59**:235-239.
- Svensson J, Diez M, Engel J, Wass C, Tivesten A, Jansson JO, Isaksson O, Archer T, Hokfelt T, Ohlsson C (2006) Endocrine, liver-derived IGF-I is of importance for spatial learning and memory in old mice. *J Endocrinol* **189**:617-627.
- Takahashi S, Satozawa N (2002) The 20-kD human growth hormone reduces body fat by increasing lipolysis and decreasing lipoprotein lipase activity. *Horm Res* **58**:157-164.
- Ting FS, Kwok AK (2005) Treatment of epiretinal membrane: An update. *Hong Kong Med J* **11**:496-502.
- Tran HA, Petrovsky N, Field AJ (2002) Severe diabetic retinopathy: a rare complication of acromegaly. *Int Med J.* **32**:52-54.
- Ulbig MW, Wolfensberger TJ, Hiscott P, Ationu A, Carter ND, Gregor ZJ (1995) Insulin-like growth factor I (IGF-I) receptor/binding protein in human diabetic epiretinal membranes. *Ger J Ophthalmol* **4**:264-268.
- Urban B, Gardziejczyk M, Urban M, Bakunowicz-Lazarczyk A (2005) Effect of human growth hormone treatment on the eyes of patients with somatotrophic pituitary insufficiency and in girls with turner's syndrome. *Endokrynol Diabetol Chor Przemiany Materii Wieku Rozw* **11**:9-12.
- Uy HS, Foster CS (1999) Diagnostic vitrectomy and uveitis. *Int Ophthalmol Clin* **39**:223-235.
- van Setten G, Brismar K, Algvere P (2002) Elevated intraocular levels of insulin-like growth factor I in a diabetic patient with acromegaly. *Orbit* **21**:161-167.
- Wang J, Zhou J, Bondy CA (1999) Igf1 promotes longitudinal bone growth by insulin-like actions augmenting chondrocyte hypertrophy. *FASEB J* **13**:1985-1990.
- Wang Q, Dills DG, Klein R, Klein BE, Moss SE (1995) Does insulin-like growth factor I predict incidence and progression of diabetic retinopathy? *Diabetes* **44**:161-164.
- Willnow S, Kiess W, Butenandt O, Dorr HG, Enders A, Strasser-Vogel B, Egger J, Schwarz HP (1996) Endocrine disorders in septo-optic dysplasia (de morskier syndrome)--evaluation and follow up of 18 patients. *Eur J Pediatr* **155**:179-184.
- Winegrad AI, Greene DA (1978) The complications of diabetes mellitus. *N Engl J Med* **298**:1250-1252.
- Wong WW, Copeland KC, Hergenroeder AC, Hill RB, Stuff JE, Ellis KJ (1999) Serum concentrations of insulin, insulin-like growth factor-I and insulin-like growth factor

binding proteins are different between white and african american girls. *J Pediatr* **135**:296-300.

Wurzbarger MI, Sonksen PH (1996) Natural course of growth hormone hypersecretion in insulin-dependent diabetes mellitus. *Med Hypotheses* **46**:145-149.

Yde H (1969) The growth hormone dependent sulfation factor in serum from patients with various types of diabetes. *Acta Med Scand* **186**:293-297.

Yu XB, Sun XH, Dahan E, Guo WY, Qian SH, Meng FR, Song YL, Simon GJ (2007) Increased levels of transforming growth factor-beta1 and -beta2 in the aqueous humor of patients with neovascular glaucoma. *Ophthalmic Surg Lasers Imaging* **38**:6-14.

Zadik Z, Chalew SA, McCarter RJ, Jr, Meistas M, Kowarski AA (1985) The influence of age on the 24-hour integrated concentration of growth hormone in normal individuals. *J Clin Endocrinol Metab* **60**:513-516.

Zapf J, Schmid C, Froesch ER (1984) Biological and immunological properties of insulin-like growth factors (IGF) I and II. *Clin Endocrinol Metab* **13**:3-30.

Zimmerman BR, Molnar GD (1977) Prolonged follow-up in diabetic retinopathy treated by sectioning the pituitary stalk. *Mayo Clin Proc* **52**:233-237.