

26758



National Library of Canada

Bibliothèque nationale du Canada

CANADIAN THESES ON MICROFICHE

THÈSES CANADIENNES SUR MICROFICHE

NAME OF AUTHOR/NOM DE L'AUTEUR ALBERT JOHN GEERAERT

TITLE OF THESIS/TITRE DE LA THÈSE SMALL CALIBRE ARTERIAL GRAFTS

UNIVERSITY/UNIVERSITÉ U OF ALBERTA

DEGREE FOR WHICH THESIS WAS PRESENTED/
GRADE POUR LEQUEL CETTE THÈSE A ÉTÉ PRÉSENTÉE M. SC.

YEAR THIS DEGREE CONFERRED/ANNÉE D'OBTENTION DE CE GRADE FALL - 1975

NAME OF SUPERVISOR/NOM DU DIRECTEUR DE THÈSE DR. J. C. CALLAGHAN

Permission is hereby granted to the NATIONAL LIBRARY OF CANADA to microfilm this thesis and to lend or sell copies of the film.

L'autorisation est, par la présente, accordée à la BIBLIOTHÈQUE NATIONALE DU CANADA de microfilmer cette thèse et de prêter ou de vendre des exemplaires du film.

The author reserves other publication rights, and neither the thesis nor extensive extracts from it may be printed or otherwise reproduced without the author's written permission.

L'auteur se réserve les autres droits de publication; ni la thèse ni de longs extraits de celle-ci ne doivent être imprimés ou autrement reproduits sans l'autorisation écrite de l'auteur.

DATED/DATE 6/10/75 SIGNED/SIGNÉ [Signature]

PERMANENT ADDRESS/RÉSIDENCE FIXE 11214 - 71 AVE
Edmonton, Alberta

THE UNIVERSITY OF ALBERTA
SMALL CALIBRE ARTERIAL GRAFTS

by

ALBERT JOHN GEERAERT



A THESIS
SUBMITTED TO THE FACULTY OF GRADUATE STUDIES AND RESEARCH
IN PARTIAL FULFILMENT OF THE REQUIREMENTS FOR THE DEGREE
OF MASTER OF SCIENCE

in


EXPERIMENTAL SURGERY
DEPARTMENT OF SURGERY



EDMONTON, ALBERTA

FALL, 1975

THE UNIVERSITY OF ALBERTA
FACULTY OF GRADUATE STUDIES AND RESEARCH

The undersigned certify that they have read, and recommend to the Faculty of Graduate Studies and Research, for acceptance, a thesis entitled SMALL CALIBRE ARTERIAL GRAFTS submitted by ALBERT JOHN GEERAERT in partial fulfilment of the requirements for the degree of Master of Science.


.....
Supervisor


.....
Thesis by

.....

Date Oct 2 1975

To my wife, Karen, who supported me
in so many ways through this venture,
and also

To my parents and highschool teachers
at St. Jerome's who gave me an appreciation
of academic study and started me on the way.

ABSTRACT

With technical sophistication of peripheral vascular surgery and the advent of aorto-coronary bypass surgery, an increasing demand has arisen for small calibre arterial grafts. At present most small calibre grafting is done utilizing segments of autogenous veins to interpose into the arterial system. The healing characteristics of these are not clearly understood, and also detract from their function in many cases. Thus the need for a more ideal and also readily available alternative has prompted our study of various other small calibre conduits.

We decided to study the function and healing characteristics of four separate types of grafts: (a) autogenous arterial segments, (b) autogenous venous segments, (c) 4 mm dacron conduits, and (d) 3 mm polyurethane foam conduits. A group of each of these separate types of grafts were implanted into a dog's femoral artery site and left to mature for a one hundred day period or until occlusion, determined by intermittent angiography. They were then removed and subjected to histological and electron microscopic examination to delineate the structural and cellular changes occurring.

The autogenous segments performed extremely well and were studied as above. However, the two types of fabric grafts proved unsuitable by demonstrating early occlusion due to thrombosis and were not further studied. Histologic and ultrastructural examination of the autogenous segments demonstrated that the venous segments underwent changes of intimal thickening and medial fibrosis, while the arterial segments remained essentially unchanged.

ACKNOWLEDGMENTS

I wish to express my thanks and gratitude to the following people who have assisted me throughout the past year.

Dr. J.C. Callaghan, who made this thesis and my experience in the laboratory possible.

Mrs. Janet Ebert, for her frequent encouragement and without whom this thesis would never have been completed.

Mr. John Henriksen and Dr. August Kolodej, for their expert technical assistance.

Mr. Ken Lazenby, for his prompt work on the histological specimens.

All the other staff of SMRI, who made my time spent there pleasantly remembered.

Dr. T.K. Shnitka, for his generous work on the electron-microscopic specimens.

Edmonton Civic Employees Association, who supported me financially during my research year.

Department of Surgery for funds to carry out this research work.

TABLE OF CONTENTS

CHAPTER		PAGE
I.	INTRODUCTION	1
II	METHODS AND MATERIALS.	32
	Experimental Operation Technique.	35
III	RESULTS.	45
	Histologic and Electron Microscopic Results	51
IV	DISCUSSION	87
	Autogenous Grafts	87
	Fabric Grafts	95
	CONCLUSIONS	97
	REFERENCES.	98

LIST OF TABLES

TABLE		PAGE
I	Flow measurements - Group I	47
II	Flow measurements - Group II	49
III	Flow measurements - Group III	50
IV	Polyurethane foam grafts	52
V	Flow measurements and function duration - Group IV	54

LIST OF FIGURES

FIGURE		PAGE
1	Diagrammatic representation of zeta potential.	8
2	Normal canine carotid artery.	29
3	Normal canine saphenous vein.	30
4	Initial stage of implantation of autogenous venous segment.	39
5	Completed graft; animal still heparinized.	40
6	Diagrammatic representation of hemodynamic situation of grafts.	41
7	Sauvage external velour 4 mm dacron graft.	43
8	Uniform diameter 3 mm polyurethane foam graft.	44
9	Tapered 3 mm polyurethane foam graft.	53
10	Cross-section graft B-412: right.	56
11	Cross-section B-461: right.	57
12	Electron microscopy of intima B-461: right.	58
13	Cross-section B-427: left.	60
14	Cross-section B-528: left.	61
15	Cross-section B-434: right.	62
16	Cross-section anastomotic region B-412.	63
17	Electron microscopy B-410: left.	64
18	Electron microscopy B-410 right. Section extending into media.	66
19	Electron microscopy B-410 right.	68

FIGURE		PAGE
20	Electron microscopy. Lumena] aspect B-461: left.	70
21	Cross-section B-469: right.	73
22	Cross-section B-469: right.	74
23	Cross-section B-489: left.	75
24	Electron microscopy. Intima and inner media. B-489 right.	76
25	Cross-section B-522 right.	78
26	Cross section B-471 right	79
27	Cross-section B-547 left. Anastomotic site.	80
28	Electron microscopy. B-466 right. Media.	81
29	Electron microscopy. B-466 left. Media.	83
30	Electron microscopy. B-466 left. Adventitia.	85

CHAPTER I

INTRODUCTION

The vascular surgeon is confronted daily with the problem of replacing an arterial segment, which has been damaged traumatically or pathologically, with an adequate substitute. In order to satisfy the requirements for a satisfactory arterial substitute, a conduit must fulfill several criteria. Ideally, the calibre of the conduit should correspond to the size of the vessel being substituted for or grafted to. Attaining this, the conduit must also fulfill several more challenging requirements. It must be of durability sufficient to allow it to withstand the physical stresses imposed upon it by the fluid flow it now carries. Next, the conduit must be of such composition that it can withstand the chemical stresses inherent in such a biological environment and yet not produce alterations in the surrounding structures. Finally, an ideal replacement must be capable of acting specifically as a vascular segment conducting a flow of blood for the survival period of the individual.

The size compatibility problem was solved almost immediately as the surgical repair of the vessel became a possibility. The obvious solution was to use another vessel of similar size and anatomical structure from the host. Historically this is precisely what was realized in the early work consisting of the replacement of an arterial defect with a fresh, autogenous arterial segment. Such work was carried out by Carrel and Guthrie in the early 1900's (1)

and reviewed by Schloss and Shumacker (2). This simple solution also met the other requirements of a vascular conduit and proved quite successful, at least for short and medium term time intervals.

In practice however, an expendable arterial replacement is seldom available from the host and therefore other vessels had to be tried as replacements. Autogenous venous segments which are anatomically more accessible were tried as arterial replacements. Early successful results of their usage appear in the literature in the work of Carrel and Guthrie (3), Goodman (4) and Schloss and Shumacker (2). These venous segments demonstrated an ability to function well when interposed in the arterial system and persist as viable structures. However, histological examinations revealed that definite early and progressive structural changes occur in the various layers of the venous wall. These have proved to be somewhat detrimental to the function of the grafted segment (2-4). These changes, labelled arterialization, are characterized by marked thickening of the venous wall, consisting of various degrees of intimal hyperplasia, medial and adventitial hypertrophy and fibrosis. These changes were attributed initially to the effect of the arterial pressure upon the wall of the vein graft. Thus, although a venous graft can in many instances act as an adequate functional replacement of an arterial segment, it is not an ideal or, in many cases, a practical alternative.

Attempts to find alternative, easily accessible arterial grafts resulted experimentally in the use of both arterial and venous homografts or heterografts. Early experimental work on these types of grafts demonstrated that they could indeed remain intact and functional at

least for some time, but histological follow-up demonstrated complete fibrosis and hyalinization (5,6). Arterial homografts were used clinically in 1948 (7) and then in some succeeding cases (8,9) both as fresh and variously preserved specimens. Despite undergoing complete fibrosis replacement, some have functioned for extended lengths of time. However, although easily accessible, these types of grafts are far from being ideal; there is a risk of early dissolution of the graft and subsequent rupture as well as all of the late complications of late degenerative fibrosis such as stricture, obstruction, aneurysmal dilatation and also atherosclerotic change.

The result of the problems involved in the procurement and use of biological alternatives for arterial segments was that synthetic prosthetic replacement would be attempted. Immediately upon attempting to interpose a prosthesis in the vascular system, the fundamental problems of vascular grafting which arterial and venous segments had inherently fulfilled, presented themselves. Merely finding a prosthetic replacement that could act as a blood conduit and withstand the physical stresses imposed upon it by the arterial hemodynamic situation was quite simple. Joseph Lister solved this by using a rubber tube as a replacement for a sheep's aorta over 100 years ago (10). To date several thousand various types of prostheses have been evaluated experimentally and clinically from materials as seemingly inappropriate as an artist's lead paint container (11) to the present-day knitted dacron prosthesis.

The critical parameter determining success or failure of any vascular prosthesis relates to a blood-foreign surface interface

compatibility. Ideally, the inner surface of a vascular prosthesis should be capable of simulating the function of the vascular endothelium and providing a stable flow surface for the blood. It should be neither injurious to any blood component nor stimulate the blood coagulation components into activity. Despite the multitude of available synthetics which are physically and chemically capable of acting as blood conduits, this last factor remains an unresolved problem.

When it became apparent that blood-foreign surface interface reaction was the critical problem, experimentors began the study of factors operative at this interface. It was noticed that coating of glass with paraffin could markedly increase the clotting time (12). Thus it was hypothesized that non-wettability of a surface would be advantageous to blood non-reactivity. Lampert formulated the hypothesis that the coagulation time was inversely proportional to the wettability of an artificial surface (13,14). Many hydrophilic surfaces however show the same delayed clotting times as surfaces made specifically non-wettable (12). In some cases it was found that specifically increasing the hydrophilia of a compound (example, elvax, hydroxyethyl methacrylate and ethyl methacrylate) would increase its blood compatibility (13). Moreover, vascular endothelium seems to be a wettable surface.

More recent work has suggested that coagulation factors XII, X, IX, and prothrombin are hydrophylic and not readily absorbed onto a non-wettable surface. This may, in part, explain Lampert's observation (15). On the other hand, factors XI, VIII, V, thrombin and fibrinogen are hydrophobic. Surface wettability therefore is not the only determining factor in blood-foreign surface reactivity.

Another factor which was evaluated in earlier work was surface smoothness. It was found that by polishing glass, isotropic carbon and other foreign surfaces, coagulation could be retarded compared to unpolished or rough surfaces of the same constituents (16). There have been several explanations offered for this observation. Roughness of a surface may increase the relative surface area of that foreign material to such an extent that this alone may account for the rapid coagulation (12). This is not valid except in extreme instances, however, as any smooth surface is only nominally so, and represents in itself a large true surface area to the blood.

Rough surfaces may mechanically damage blood elements and thus induce coagulation. This factor is difficult to experimentally analyze but it would not appear to be operative except in cases of extremely irregular surfaces. One of the more likely explanations is that roughness of a surface induces areas of microturbulence in the flow. This would stimulate coagulation inherently by increasing the exposure time of various blood coagulation proteins and blood platelets to the foreign surface. This explanation has a sound hemodynamic basis in that irregularities of surface conformation induce concomitant areas of vortex formation and stagnation and is in agreement with many experimentally observed events of thrombosis. Increased thrombosis has been observed in the regions trailing even minute flow irregularities (17-19). Anatomically the vascular endothelium presents a relatively smooth surface to blood flow. Smoothness therefore can be correlated to blood foreign surface compatibility but within very narrow limits. Smoothness alone cannot markedly alter inherent thrombo-

genicity of any surface and cannot really be considered a major factor in blood compatibility.

As knowledge of the vascular wall and endothelium became more sophisticated it was found that the vascular intima has an electro-negative potential in the range of minus one to minus five millivolts relative to the adventitia (20). This, coupled with the negative electrical potential found on circulating blood components, characterized the blood endothelium interface as "a suspension of electronegatively charged cellular elements in a colloidal solution of hydrophillic electronegatively charged protein flowing past an electronegative solid layer" (21). Such observations led to the impression that electrical factors were perhaps the major factor in control of blood foreign surface reaction.

Much work has been done in an attempt to determine the optimum charge that should be induced upon a foreign surface to prevent thrombosis. Early work done by Sawyer demonstrated quite clearly that a very small positive charge will induce thrombosis, while a small negative charge will tend to prevent this (20,22). With an even minor injury to the intima, an immediate reversal of the normal polarity conducive to thrombosis will occur. It soon became clear that the static charge alone imposed upon a prosthesis would not always prevent thrombosis (23). A highly negative surface is indeed quite thrombogenic.

Considering the dynamic conditions present at the blood vascular interface, it would seem a bit simplistic to consider only the static electrical phenomena. Investigation therefore turned toward dynamic electrical phenomena at the interface. Investigators began trying to

relate the parameters of streaming potentials and zeta potentials to blood-foreign surface reactions. For clarity of terms, a brief discussion of these phenomena, as related to the vascular interface, will be given.

Zeta potential is defined as the potential drop across the mobile phase of the electrical boundary layer at an electrolyte-solid interface. This is schematically shown in Figure 1 (24). This concept encompasses several separate phenomena related to the vascular interface. In the case of the vascular endothelium the solid layer is represented by a membrane matrix of fixed negative charges consisting of anionic groups such as the carboxyl groups of the proteins or the phosphate groups of lipids. To maintain electro-neutrality these fixed anions will accumulate a number of salt cations from the surrounding region and repel anions giving rise to the membrane Donnan potential. This then establishes the boundary potential. When an electrolyte solution flows past a fixed boundary, a thin nominally immobile electrolyte layer and a mobile electrolyte layer will be established. These two layers are separated by a slippage plane that is influenced by such factors as ionic strength, viscosity and surface roughness (25). The location of this slippage plane relative to the solid boundary will determine the magnitude of the measured zeta potential. Thus this measurement is inherently arbitrary.

Electro-osmosis is the electrical phenomena exhibited by the flow of ions across a membrane having fixed pores when a potential difference is applied across this same membrane. Streaming potential is the inverse of this process. The streaming potential may be

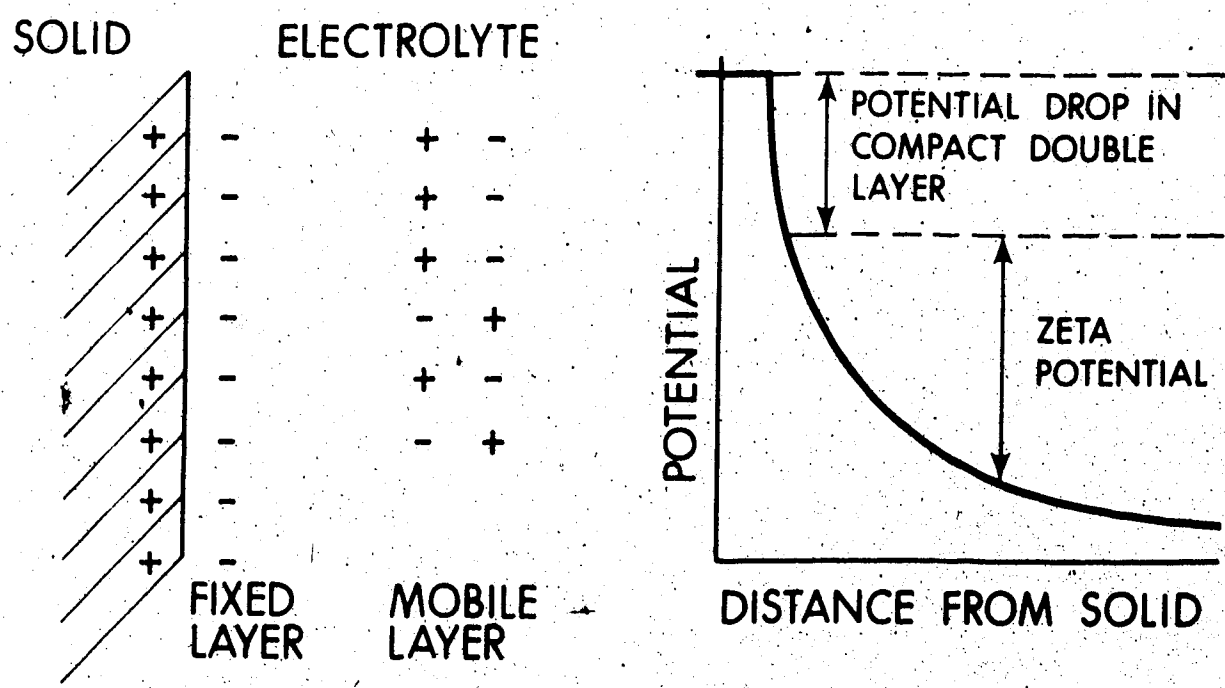


Figure 1 Diagrammatic representation of zeta potential.

measured by the potential difference between two electrodes inserted into a capillary tube or vessel through which an electrolyte solution is flowing. The zeta potential can be deduced from the measured streaming potential by the following formula (12).

$$Z = \frac{SRDP}{4 \pi \eta}$$

where Z = zeta potential in millivolts

S = streaming potential, millivolts

η = viscosity of fluid, poise

R = resistivity of fluid, esu

D = dielectric constant of fluid

P = pressure drop across capillary, dynes cm^{-2}

When investigators began measuring the electrical characteristics of various prostheses, several interesting observations were made. Any surface, when exposed to a flow of electrolytes, will demonstrate a characteristic zeta potential (12,20,26). Several studies suggested that a negative zeta potential, relative to physiological saline, was necessary for blood-foreign surface non-reactivity (20,26,27). However, exposure of any foreign surface to blood results in rapid adsorption of blood proteins onto the surface and causes the zeta potential to approach zero, despite its previously measured value (12,15,28). This critical blood-foreign surface reaction negated any significant correlation between the above measured electrical phenomena and blood reactivity.

Several experiments demonstrated that an electroconductive lining is advantageous for blood compatibility (16,27,29). Again, however, adsorption of proteins tends to change the conduction of the

surface facing the blood. Indeed, the protein adsorbate itself is somewhat conductive and thus will determine the amount of electroconductivity facing blood flow (12).

None of the above electrical properties then are of critical importance. They may affect, but do not primarily determine, the ultimate fate of a vascular prosthesis. Electrical phenomena however are certainly important in the processes of intravascular thrombosis. Sawyer has stated that "intravascular thrombosis is an electrochemical interfacial phenomenon and predominately dependent upon interfacial potential differences" (30).

Another interesting property of foreign surfaces which has been investigated and correlated to blood reactivity is surface free energy. It was hypothesized that the free energy of a surface would be operative in providing the interaction energy necessary to induce coagulation (31). The point in the coagulation series where this energy would be utilized would be determined by the nature of the surface influencing the substances adsorbed from the blood. Theoretically the surface with the lowest possible surface energy would be the most compatible, because a surface with a lower surface energy will not modify the conformation of the adsorbed protein layer as markedly (32). This hypothesis does hold true within limits. Most biologically inert surfaces tend to demonstrate lower surface free energy. This, however, merely reflects the chemical nature of the surface which has been acknowledged as operative in blood-foreign surface reactivity.

It should be emphasized that there is no completely athrombogenic surface known. Furthermore, there is no single property known primarily

responsible for the thrombogenicity of the surface. Any foreign surface implanted into the vascular system will initiate a reaction by the soluble and formed elements of the blood, the nature and extent of which will be determined by the chemical nature of the implanted prosthesis. Study of this reaction, however, does bring to light some interesting observations.

The initial reaction of any foreign surface with blood appears to be the immediate adsorption of various plasma proteins (13,15,33,34). These proteins consist usually of albumin, gammaglobulin, fibrinogen and also factor XII (35). Different surfaces vary in the types and amounts of the various proteins adsorbed (36,37). If the outermost adsorbed layer of protein demonstrates little structural modification regardless of whether it is adsorbed directly onto the surface or onto a secondary or tertiary layer of protein, it may act as a passive barrier towards activation of other approaching protein species (32).

Adsorption of factor XII to a foreign surface activates the intrinsic coagulation system with the resulting deposition of fibrin and possible thrombosis formation. The next important reaction of blood with foreign surfaces is the reaction of platelets with this surface. It would appear that the blood platelets adhere to the adsorbed protein layer (13,17,38,39). These platelets may adhere, singly or in aggregates. Depending upon the degree of activation, the platelets demonstrate changes leading to thrombosis formation such as pseudopodal formation, degranulation and, later, disintegration. The stimulation for platelet adherence appears to be mainly contact time with the surface (18). Leucocytes and erythrocytes may also adhere to this adsorbed protein layer. The end result of this entire

process is thrombus formation. In the case of a vascular conduit, thrombus may either embolize or occlude the conduit, depending upon attachment to the surface, size of the conduit and flow characteristics.

Failing to achieve an ideal blood-foreign surface interface, and confronted with the inevitability of reaction against a prosthesis by the blood, a compromise would be to minimize the reaction stimulated and, hopefully, obtain a stable flow surface. A flow surface of unstable nature is inherently detrimental because it would progress to one of several outcomes. If the surface continues to evolve structurally, never attaining an equilibrium state with flow, thrombotic occlusion of the prosthesis develops.

Another possible outcome of an unstable flow surface is thrombotic material continuing to embolize and the flow-surface reforming. Assuming that the thrombotic material embolizes and does not only partially separate or lodge distally in the prosthesis, this second alternative may provide a functional blood conduit. However, the pathological results of this embolic process on the host would render it unacceptable.

A third and final possible type of unstable flow surface would be one which underwent the process of dissolution and replacement at a sub-microscopic level. Such a process would involve the continual removal and replacement of individual protein moieties biochemically or physically. This may indeed represent the normal process which occurs at a nominally stable flow surface. The stability of the flow surface, therefore, is of critical importance if a prosthetic graft is to have a functional life of useful duration. Stabilization of the flow surface, resulting from the vascular homeostatic mechanism oper-

ative at a foreign synthetic interface, introduces a central concept in modern synthetic grafting, that of porosity.

In the early 1950's, Vorrhees, Jaretzki and Blakemore (40) did experimental work implanting Vinyon N cloth prostheses into the aorta of dogs. They postulated that it would be advantageous to have a porous type graft such that fibrin plugs could arrest hemorrhage yet fibroblast ingrowths through the mesh would later occur. Theoretically the ingrowth would serve as a stimulus for endothelial proliferations or possibly provide a functional intima in itself. Wesolowski (41) and others proved the validity of this concept. Synthetic fabric grafts for large calibre arteries function satisfactorily for prolonged periods. Experimental studies in dogs, pigs and calves have confirmed that complete healing, including endothelialization, does occur in porous synthetic grafts in these animals.

Early experimental work proceeded to differentiate the healing characteristics of various plastics such as orlon, nylon, teflon, dacron and many others. Wesolowski postulated that porosity itself was the critical determinant of the ultimate fate of synthetic grafts and not the basic tissue reactivity of the material implanted (41).

Clinical use of these porous fabric grafts was pioneered in the mid to late fifties by DeBakey, Wesolowski and others, using grafts constructed of knitted dacron.

Morphologic studies on specimens removed at autopsy or graft replacement have elucidated the healing characteristics of fabric grafts in humans. It has been found that humans can only incompletely heal a synthetic vascular prostheses (42). The healing process of these fabric grafts primarily determines their ultimate fate and thus the

incomplete healing seen in humans has several important implications. These can be best anticipated by an understanding of the complete healing process itself.

Implantation of the graft is performed by anastomosing suture techniques as this has proven most atraumatic and effective. Immediately following transplantation, blood proteins deposit upon the luminal aspect of the synthetic fibres in a manner characteristic of any blood-foreign surface interface (43). The interstices then become plugged by blood clots consisting mainly of fibrin and erythrocytes (11), which form in zones of stasis deep within the fabric material. This same process may occur as a result of preclotting of the graft. On the flow surface fibrin and platelets deposit in layers under the influence of hemodynamic factors and the thrombotic process resulting in formation of a fibrin membrane over a period of minutes (43). This results in the development of a neo-intima or pseudointima of thickened fibrin layers which may be virtually complete within a period as short as 20 minutes (44).

Following this initial hemostatic process, the gradual organization of the clot and neo-intima begins and results in the formation of three rather distinct zones in the wall which are somewhat analogous to the three layers in the normal vascular wall (45). This process of organization is similar to the normal process of thrombus organization, although the neo-intima layer is modified by hemodynamic factors of the flow surface. Granulation tissue with inflammatory cells and macrophages quickly form, surrounding the graft (45). Within a week the capillary buds and fibroblasts can be seen invading the

interstices of the fabric from this granulation tissue around the external surface. Concomitant with this process, leukocytes deposited on the inner surface migrate through the platelet-fibrin neo-intima lysing thrombus as they proceed. In some animals these macrophages can differentiate into fibroblasts and contribute to organization of the thrombus (46). Although this may take place in humans, such has not been proven.

With maturation of the organization process, fibroblastic foci coalesce throughout the fabric interstices, often completely encasing fibres of the graft material. These advancing fibroblasts eventually reach and contribute to the organization of the neo-intima. In some animals fibroblasts may participate in, or actually form, a complete pseudo-endothelium of flattened cells in contact with the blood. This layer of cells may also be contributed to by seeding of macrophages from the blood stream which can ultimately differentiate into cells indistinguishable from normal endothelium. The origin of these cells from the blood stream has been demonstrated by experiments with implanted isolated dacron hubs (47). The process of organization of the neo-intima is markedly restricted and delayed in humans, confined merely by attachment to the basal layers under even the most optimal conditions (42,43,45).

With proceeding maturation of the granulation tissue and increasing amounts of collagenous replacement, separation of the wall into layers becomes more evident. The outer capsule surrounding the graft consists of a fibrous connective tissue, this outer capsule has been further subdivided by Wesolowski into three sublayers (11). The outer of these consists of a looser fibrous connective tissue which

contains a vascular plexus, the new vasa vasorum for the prostheses. The middle layer of the outer capsule consists of a dense collagenous scar tissue, while the inner layer of the outer capsule remains as a layer of granulation tissue adjacent to the fabric elements of the graft. The middle layer of the three major layers, consists of the fabric matrix of the graft, with granulation tissue bridging the interstices from the outer to the inner capsules. The inner capsule can be subdivided into two regions (45). The layer immediately adjacent to the fabric again consists of granulation tissue, continuous with that extending through the interstices. The flow surface layer consists mainly of compacted fibrin in humans, although in many animal species it is completed with an over-lying endothelial layer.

The foregoing describes the graft several weeks to months after implantation. During the latter stages of this time period however, with continuing maturation of the granulation tissue around the fabric elements and through the interstices, contracture develops and capillary elements become strangulated at the weakest points, particularly those bridging the interstices. This produces a potentially critical situation in the normal healing process of a graft. With this contracture of the fibrous elements, vascular supply to the inner capsule is lost. The inner capsule is probably completely dependent upon this blood supply to maintain its integrity (11). With loss of its blood supply, the inner capsule undergoes degeneration with several possible consequences depending on the surface area of degeneration and the degree of porosity of the graft. Small areas of degeneration result only in a further layering of fibrin on the inner surface while larger areas may embolize. Contracture may also produce physical rhexus of the

bridging elements in the fabric matrix, eventuating in the formation of intracapsular hematomas.

The degree of porosity appears to determine the ultimate fate of the graft at this stage. Wesolowski believes that if a graft is sufficiently porous, any degeneration of the inner capsule will stimulate a second wave of ingrowth of granulation tissue of sufficient magnitude to reorganize the structures and prevent progressive degeneration or the other complications. In a graft of sufficient porosity, however, these complications may be averted merely by the size and physical tenacity of the bridging fibrous elements. In a graft of low porosity these bridging structures will be more tenuous and subject to rhexus than in a graft that allowed more substantial ingrowth originally. There is little change in the morphology of the normal implanted fabric graft structures after a period of several months except for perhaps increased density of collagenization. This is evident from clinical grafts which have been studied for periods up to eleven years (42,45).

At the anastomotic sites, a different healing response, termed pannus ingrowth, occurs. This special reaction represents a hyperplastic response from the ends of the host arteries (42), and consists of tissue outgrowth from the wall and the luminal surface of the host artery around and over the implanted ends of the graft structures. At these points of pannus ingrowth, healing is always complete with endothelialization, which may even extend out over the graft surface beyond the pannus for short distances. This type of healing is very limited to the anastomotic site and extends only one to two centimeters

with time.

The incompleteness of the healing process in humans compared to experimental animals is reflected by two major differences. First, it is of delayed nature and, secondly, there is an inability to endothelialize flow surfaces. Extensive clinical and experimental work by Sauvage and Berger (48) led them to correlate the speed of healing with the final quality of healing. Delayed transinterstitial ingrowth of fibrous tissue will delay organization of the inner capsule.

This predisposes human grafts to several problems which may prove detrimental. With delayed organization, the inner capsule tends to be thicker than when it is rapidly organized and endothelialized. The inner capsule so formed will be less adherent to the underlying structures during the early stages of healing. This predisposes it to sloughing and embolization at critical stages in its development, such as when rhexus of interstitial tufts occur. A delayed healing pattern also seems to predispose thin walled porous grafts to delayed transinterstitial hemorrhage. The reason for this has not been elucidated in the case of man.

Failure of humans to endothelialize the flow surface also has adverse effects on synthetic grafts. This failure may merely be a reflection of the markedly delayed healing process as well. The organization of the compact fibrin neo-intima is so delayed that endothelialization is never achieved due to subsequent changes in the underlying structures and fibrin interface. Regardless of the cause, failure to endothelialize results in a flow surface consisting of compacted fibrin. This surface, although functional, is certainly

more tenuous than an endothelialized surface. Compacted fibrin has a relatively high thrombotic threshold velocity and therefore can only provide a functional surface under conditions where a high flow is assured and maintained. If the flow is compromised, new layering of fibrin can be expected on the inner flow surface. This will eventually result in occlusion (49).

Fabric and suture play a vital role in maintaining the physical integrity of the arterial conduit. Healing is never completed to the extent that the fabric or suture can be dispensed with. This is reflected in cases of delayed anastomotic rupture years after implantation caused by suture failure or delayed graft rupture due to fabric dehiscence. In humans then, a typical healed porous fabric graft, structurally consists of a capsule of relatively acellular scar tissue surrounding, but poorly attached to the underlying fabric matrix, and the inner capsule by prongs of fibrous tissue extending through the interstices. The inner capsule is composed mainly of compacted fibrin of varying age. This has led Wesolowski to predict a 10 to 20 per cent per annum failure rate of femoro-popliteal dacron grafts due to intrinsic graft failure after the first year (49). Patency predictions are somewhat better, however, for larger calibre grafts.

An understanding of the healing process and the critical stages involved, allows us to, hopefully, alter these for functional improvements. This approach has indeed led to several structural innovations which have improved the healing capacity of these porous grafts. From a strictly structural standpoint, it was soon recognized that the graft must be constructed of a fabric which was relatively inert so as not to

stimulate a marked foreign-body response. This is not of major importance however, for Wesolowski suggests that the foreign-body response is stimulated by autolysis of host tissue in the vicinity of the implanted substance (11). Of more importance perhaps, the graft fabric must not be subject to biologic degeneration such as occurred with nylon and polyvinyl alcohol grafts (11). These considerations have resulted in the clinical use of mainly dacron or teflon grafts.

An implanted synthetic prosthesis, with the normal fibrotic process involved in healing, demonstrates loss of elasticity. Nevertheless, it must be able to maintain patency without kinking or obstruction through whatever range of motion is inherent in the anatomical position into which it is implanted. Plain dacron grafts can kink excessively and physically obstruct flow. This problem led to the development of crimped grafts which allows bending through 180 degrees without kinking (50).

Attempts have been made in several ways to increase the porosity of grafts and achieve better healing. There is a limit to the degree of porosity that may be obtained with minimal risk of graft leakage. To circumvent this problem, attempts were made to develop a compound type graft in which elements of the wall would be absorbed to increase "healed porosity" (51). These types of grafts however have not proven clinically useful because the risk of delayed hemorrhage is high. In an attempt to physically increase porosity, Wesolowski suggested the 'gossamer' concept wherein finely fabricated lightweight yarns would produce an increase in the ratio of pore size to yarn diameter (52). Experimentally this concept has proven advantageous,

but it is applicable only to small calibre grafts.

In an attempt to increase the rate of fibroblast migration through the fabric wall and thus facilitate binding to the graft and healing of the neo-intima, several approaches have again been used. It was found that decreasing the wall thickness would facilitate healing and also tended to reduce the thickness of the internal capsule (53). Although this may be a useful technique in small calibre grafts, maintaining the structural integrity of the graft obviates its usefulness in clinically used grafts. Another useful concept is that of the velour surface. The velour surface provides a trellis for the migration of fibroblasts through the interstices of the graft in order to increase the rate of cellular migration. The velour surface consists of fine fibres of the synthetic material protruding as loops or fibres from the main fabric matrix to provide a roughened surface. Experimental and clinical studies with external (54) or internal velour surfaces (55) have been conducted. Current investigation relates to double velour surfaces (55).

The external velour surface provides several functional advantages. It facilitates inner capsular healing by aiding fibroblast migration. It also reduces implant bleeding by providing a more definite matrix for thrombus formation. Furthermore, external velour assists in more rapid binding of the graft to surrounding tissues, thus minimizing peri-graft hematoma and seroma formations; factors which detract markedly from the healing process (54). Sauvage and Berger have documented several cases of complete healing in grafts utilizing external velour dacron knitted conduits (54,55).

Internal velour surfaces differ slightly from the external type in their finer construction. The internal velour surface serves to anchor the thrombotic inner flow surface and speed its organization by providing another trellis for fibroblastic ingrowth. Clinical work by DeBakey supports the value of this (56).

The exact nature of the role which porosity plays in maintaining the integrity of a functional neo-intima remains obscure. It has been suggested that the pores allow a flux of electrons and ions through the graft to establish an electrochemical gradient such as occurs in the normal arterial wall (56). This, however, has not been experimentally verified. Sawyer has suggested that an impermeable synthetic prosthesis may act as an electrical condenser which, in the presence of blood flow, produces a thrombogenic charge; this also remains conjectural. Another interesting concept is that the porosity of grafts allows for the establishment of fibrinolytic activity in the neo-intima. Studies done on dogs have indicated the presence of fibrinolytic activity in the neo-intima within 24 hours of implantation that lasts for several weeks (57). These studies cannot be extrapolated to humans however. One study carried out on dacron grafts recovered from humans has shown the fibrinolytic enzyme plasminogen activator to be present in the neo-intima of patent grafts at sites of capillary penetration (58). Plasminogen is absent in occluded grafts. The fibrinolytic system may function to maintain patency in porous synthetic grafts similar to the role it plays in normal vascular structures.

Grafts permeable to fibroblasts certainly are inherently

permeable to any or all of the above factors. An interplay between these and other, as yet undetermined factors, probably is important to the maintenance of graft patency. Invasion of fibrous tissue/ through the graft functions to stabilize and organize the neo-intima. This invading granulation tissue also appears to nutritionally support the inner capsule with a capillary supply. Disruption of these fibrous supporting elements compromises the graft. Despite the thrombogenic nature of the compacted fibrin neo-intima, in order to maintain patency, this neo-intima must be stabilized by invading fibrous tissue elements. The more rapidly and extensively this can be done, the better the result, or as Wesolowski states, "the degree of physical porosity is the primary factor in synthetic grafting (11).

Various workers have attempted to minimize neo-intimal formation by minimizing blood-foreign surface reaction. Gott has done extensive work toward creation of a heparin-bound surface (59). Originally Gott used graphite-benzalkonium-heparin surfaces, but these proved unstable over long periods because the heparin eluted from the surface in three to four weeks (60). Gott and other workers have since developed more stable heparin bound surfaces (61,62), and also an increasingly sophisticated combination of anticoagulant surfaces such as heparin-urokinase (63) and silver allantoin heparin surfaces (64). All of these surfaces do bind plasma proteins and attract platelets but only to a limited extent. None have as yet proven clinically useful except for short term periods.

Many other types of highly sophisticated surfaces have been developed, such as polyelectrolyte hydrogels (65), electrochemical (66),

and autobiological synthetic surfaces (67-69). None have been as useful however as the porous synthetic surface for vascular grafting.

With this background understanding of the principles, our synthetic grafting of small calibre grafts, in particular, will be considered. Most previous studies of prosthetic vascular grafts have related to grafts with internal diameters in the range of 10 to 15 millimeters. There was little problem in applying techniques and materials developed in large calibre grafts to grafts with internal diameters in the range of six to eight millimeters. With the advent of aorto-coronary surgery however, and increasing demands for small arterial replacement, the need for grafts with internal diameters of four millimeters or less arose. Special problems were encountered with grafts of this calibre.

From a technical point of view, small calibre grafting posed special problems related to materials and surgical technique. A smooth anastomosis with minimal compromise became a necessity for graft success. This required fabric materials that would be readily conformable to the arterial anastomosis, readily pliable to prevent kinking, fabricated to prevent even minor fraying defects, and easily suturable to accommodate the light sutures and fine techniques required in the anastomotic procedures. These requirements can be met quite well by various types of finely fabricated synthetics such as dacron or polyurethane. Small calibre grafts can indeed be constructed of finer, lighter and thinner fabrication than is necessary for grafts of larger calibres, as can be appreciated by consideration of the law of Laplace which states simply:

$$P = \frac{T}{R}$$

where P = pressure tending to distend the vessel

T = tension experienced circumferentially in the vessel wall

R = radius of the vessel

For simple cylindrical vessels, the tension that will be experienced by the wall of a small calibre graft will be much less than that experienced by the wall of a large calibre conduit.

As well as being a technically favorable characteristic, the thin walled construction allows more rapid and complete healing of the graft and thus tends to minimize neo-intimal thickness. The critical factor in small calibre grafts is thickness of neo-intimal formation which will be determined primarily by fabric reactivity, rapidity of healing and velocity of blood flow. A dynamic and complex interplay occurs between graft flow velocity and neo-intimal thickness. Velocity of blood flow will affect the intimal formation by determining the time of contact at the blood interface of protein and cellular elements and by determining the sheer stress tending to remove thrombotic elements at this interface. From the law of Poiseuille which states that the flow through a cylindrical tube is:

$$F = \frac{\Delta P}{R}$$

where F = flow

ΔP = pressure differential between the ends of the conduit

R = resistance factor

which is calculated from the following equation:

$$R = \left(\frac{8}{\pi}\right) \times (\eta) \times \left(\frac{l}{r^4}\right)$$

where η = fluid viscosity

l = length of vessel

r = radius of the vessel

It can be appreciated that the factor most affecting flow is the radius of the vessel. Velocity of flow cannot be equated directly to flow volume, but referring to the equation of flow continuity, may be related by

$$F = V \times A$$

where F = flow volume

V = flow velocity

A = cross-sectional area ($A = \pi r^2$)

A simple reduction of equations yields

$$V = P \times \frac{r^2}{8\eta l}$$

where V = velocity of flow.

Thus it may be appreciated that the dominant factor in determining velocity will be the radius of the graft. This means that an increasing thickness of neo-intima, decreasing the internal diameter of the graft, will decrease the flow velocity which will tend to propagate production of neo-intima. Because of this, it has been found that neo-intima formation in excess of 500 microns will result in occlusion of 4 millimeter grafts (70). Neo-intimal thickness for medium and large calibre grafts is usually in the range of 1200 microns.

The flow velocity through small calibre arteries will be slower

than that through larger calibre arteries as can be appreciated from the simple equation of continuity of flow stating that the product of the total cross sectional area and the mean velocity must remain constant throughout the vascular bed. Thus, for example, the mean flow velocity through a two centimeter diameter aorta will be 28 centimeters per second, while that through distal arteries of four millimeter diameter will be approximately 12 centimeters per second under normal physiologic conditions (71). This lower flow velocity will contribute to thrombosis of small calibre grafts.

From these considerations, it can be appreciated that factors exist both favorable and detrimental to maintaining functions in small calibre arterial grafts. With a neo-intima composed of fibrin with a relatively high thrombotic threshold velocity, the hemodynamic situation in small calibre grafts is at best a tenuous one. Any factor adversely affecting the hemodynamics or thrombotic process in these grafts will result in immediate occlusion. At present the most effective way to improve the situation is to have a fabric surface of lowest possible blood reactivity and speed the healing process, hopefully to complete endothelialization with the consequent marked drop in thrombogenicity. With rapid complete healing, the inner capsule may be restricted to 100 to 200 microns (56) and this, coupled with a normal endothelized surface would assure patency.

In conclusion, a brief consideration should be given to normal structural characteristics of small calibre sized vessels. Beginning with arteries, vessels of the three and four millimeter size are classed as muscular distributing arteries and include such branches as the main stem coronaries, the internal mammaries, the radial and

popliteal arteries and numerous other distal distributing branches.

The walls of these muscular arteries lend themselves well to division into three distinct classical layers, that is, intima, media and adventitia (Fig. 2). The intima of muscular arteries consists of an overlying endothelial layer of cells, an underlying basement membrane, a subendothelial space composed of delicate elastic and collagenous fibres as well as the occasional cell, and the limiting internal elastic lamina. The media of muscular arteries is the main wall component and comprises multiple layers of circularly disposed smooth muscle cells with interspersed connective tissue elements of elastic, collagenous and glycoprotein composition. The adventitia is composed of loose connective tissue, mainly of collagenous nature, orientated mainly longitudinally as well as occasional neurogenic structures and vasa vasorum. The inner layer of adventitia is often condensed into an external elastic lamina in muscular arteries.

Veins of similar calibre to the muscular arteries show analogous but less well defined morphologic structure (Fig. 3). The intima consists of endothelial cells with a usually inconspicuous subendothelial space of fine connective tissue. The internal elastic membrane is absent or rudimentary, consisting only of fine elastic matrix. The media is again composed of circularly orientated smooth muscle cells interspersed with connective tissue matrix, but is much thinner and less well developed than in the case of the arteries. An important exception to this is the media of the saphenous vein which is composed of an inner longitudinal and an outer circularly arranged, well demarcated bundles of smooth muscle. The adventitia of veins is well



Fig. 1 canine carotid artery;

1) outer limit intima,

2) outer limit media,

3) outer limit adventitia.

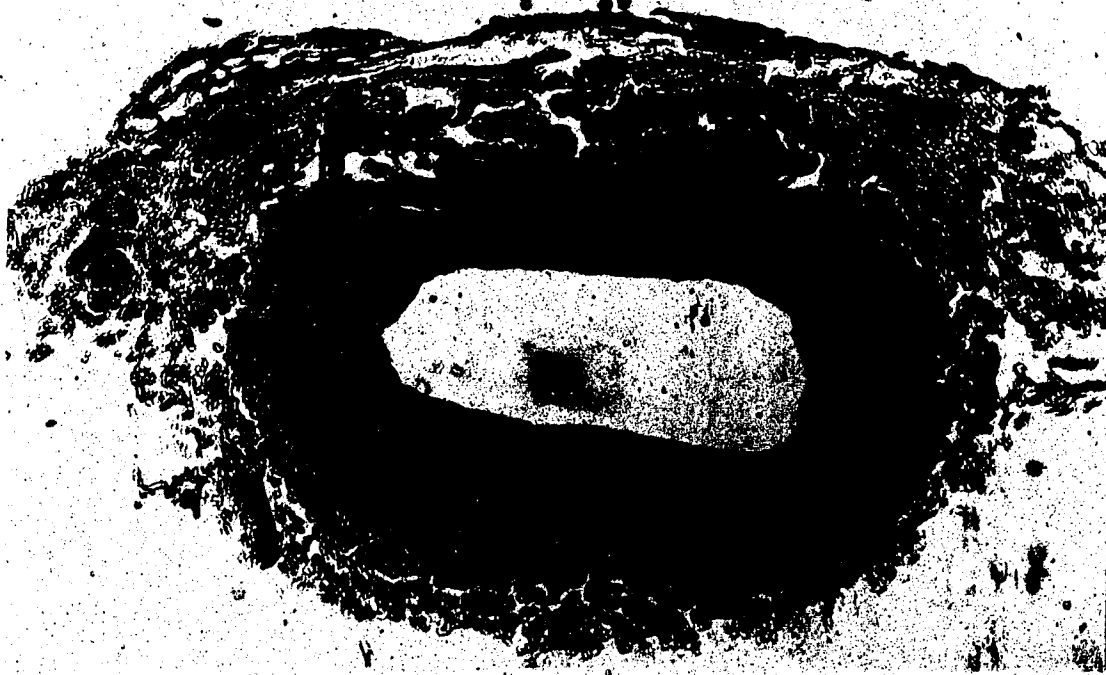


Figure 3. Normal canine saphenous vein;

- (1) outer limit intima,
- (2) outer limit media,
- (3) adventitia.

developed and comprises a major component of the venous wall.

Structurally it is similar to that of the arteries.

CHAPTER II

METHODS AND MATERIALS

It is our intention to study the healing characteristics, histologically and submicroscopically of autogenous vascular grafts of small calibre size and also assess the functionality and, where possible, the healing characteristics of selected three and four millimeter synthetic grafts. These studies are pertinent to aorta-coronary and distal artery bypass surgery which presents an increasing demand for suitable synthetic prostheses of this calibre and also elucidation of the healing characteristics ultimately affecting the fate of autogenous grafts presently being used for these procedures. We have chosen dogs for our experimental animal because of availability and their suitably sized arteries, which most closely approximate the healing response of vascular tissues as seen in man (48).

Our experimental model will consist of bypass segments anastomosed onto a readily accessible distal artery of proper calibre, using an end-side anastomosis which has been shown superior by Linton (72). The suture technique will be a continuous suture beginning with an everting mattress at the receding end of the implanted segment and proceeding around with a continuous over and over suture to finally place the tie on the lateral aspect of the graft where distending pressure will maintain maximum diameter. The suture utilized will be 7-0 prolene double armed which provides a fine slippery monofilament type suture, and is similar to 6-0 prolene presently being utilized clinically at this center.

Our experimental series will be divided into four groups:

Group I: will consist of a series of ten dogs with bilateral autogenous saphenous vein grafts onto a distal artery.

Group II: will consist of a series of ten dogs with bilateral autogenous arterial grafts onto a distal artery.

Group III: will consist of a series of ten dogs with four millimeter dacron grafts onto a distal artery.

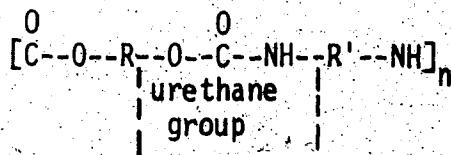
Group IV: will consist of a series of ten dogs with three millimeter polyurethane grafts onto a distal artery.

At operation, flow measurements will be taken on the grafts, then patency will be assessed every three weeks angiographically. We will leave these grafts for one hundred days then remove them at sacrifice for histological and electron microscopic examinations. A 100-day period will allow a significant time interval to assess cellular changes occurring in autogenous grafts and will allow for complete healing of the synthetic grafts which is approximately eight to 12 weeks in dogs.

As we are interested in the healing processes involved in these grafts, our model is constructed to insure optimum patency rate. We will graft short straight segments onto a healthy artery. This model will provide optimal distal runoff, allowing unimpeded flow, and our short segments will insure relatively high flow rates. To further increase the flow in some of our segments, we will ligate the arterial segment underlying the bypass segment. In the case of our synthetic grafts, increasing the flow rate thus will hemodynamically optimize patency rate. In the case of the autogenous grafts where high patency

rate is anticipated, ligating the underlying arterial segment will more closely approximate the true arterial hemodynamic situation. At present, as will be later discussed, the importance of various factors inherent in the arterial environment relative to the changes seen in autogenous venous and also arterial grafts is still obscure and controversial. Therefore morphological examination following sacrifice may demonstrate structural and cellular differences between autogenous segments introduced into the arterial system as simple bypasses and those as bypasses with imposed flow.

The autogenous vein, artery and also four millimeter dacron grafts have been and are being used clinically and thus the need for complete understanding of their healing characteristics is obvious. In the case of our polyurethane grafts, these are in the experimental stage of development. Various recent experimental studies suggest polyurethane may provide an acceptable and, in fact, superior synthetic for vascular grafting. Polyurethane basically is a polymer of the urethane group and may be represented as



Polymerization may be catalyzed by various processes and represents a condensation reaction. Some polyurethanes have been shown to degrade very rapidly due to linkage-cleavage when subjected to the biological environment (73). However, by various changes in the catalytic process, biologically stable polyurethane can be polymerized. Polyurethane foams, prepared by the reaction of diisocyanate and difunctional alcohol

leading to polymerization with expansion by evolution of carbon dioxide gas, represents a biologically stable form (74). Recent experiments have demonstrated that a polyurethane lattice showed a more rapid healing response and better pseudointimal incorporation than dacron velours in large calibre prostheses (75). Also recent work by Sharp has demonstrated long-term patency of three and four millimeter grafts of electroloom; a dacron velour lined with a polyurethane coating with a static bio-potential imposed by addition of carbon black (25,26,70). Polyurethane demonstrates the additional desirable characteristic of increased elasticity compared to dacron. Polyurethane foam can be readily constituted with varying pore structures and presents exciting possibilities as a synthetic for vascular grafts. As such we have obtained various machined and wrapped three millimeter polyurethane foam grafts from Bentley Laboratories for assessment of function and, achieving this, healing characteristics.

Experimental Operation Technique:

The femoral artery site was chosen, in lieu of the carotid, for our graft site for reason of accessibility for percutaneous angiographic follow-up studies. The dogs were anesthetized with intravenous Nembutal using an initial dosage of 0.5 cc/kg body weight. The dogs were then intubated using an oral endotracheal airway. An intravenous line was established in the dog's fore limb, using an initial slow infusion of 2/3-1/3 solution for maintenance during anesthesia.

Following this the groin site was prepared bilaterally by shaving, washing and sterilization with Ioprep solution.

The dog was surgically draped and longitudinal skin incisions

were made over the femoral arteries, using arterial pulsation as reference for line of incision. The subcutaneous tissue and sartorius muscle layer were divided, hemostasis being obtained with electrocautery. The femoral sheath was then identified in the femoral triangle and incised. The femoral artery was now dissected free, assuring a sufficient length for grafting. Minor branches of the femoral artery in the femoral triangle were ligated and divided for ease of grafting.

Following bilateral exposure of the femoral arteries, graft segments were obtained. In the case of autogenous vein series, segments were taken from the lateral saphenous vein which is the major superficial vein in the hind limb of the dog. This was obtained with a longitudinal skin incision over the vein, and dissecting through the subcutaneous fascia. The saphenous vein was then dissected free as atraumatically as possible, taking care not to inadvertently incise or damage the vessel with forceps. All branches were ligated with 3-0 silk and divided, taking care that the ligature was placed so as to neither compromise the vessel lumen when distended nor allow any extraneous length of branch for thrombosis to occur. Having freed a sufficient length of vein to supply two graft segments, allowing blood flow to continue until final removal; the vein was ligated proximally and distally and removed. The graft segment was then immediately immersed in 2/3-1/3 solution cooled in ice slush.

Segments of autogenous artery were obtained from a carotid artery. The carotid artery was approached through a midline incision, dissecting between the superficial and deep cervical muscles to reach

the carotid sheath. Having reached the carotid sheath, the artery was carefully dissected free of the sheath, usually obtaining a sufficient branch-free length below the inferior thyroid branch for two grafts. In two cases this was not possible and the other carotid was easily dissected free using the same midline incision. The dogs suffered no ill effects with bilateral carotid removal, having a very well developed vertebral system to ensure adequate central nervous system perfusion. The carotid artery was doubly ligated proximally and distally to the segment to be removed with 2-0 silk ligatures and then the graft segment was excised. Again, immediately upon excision, the graft segment was immersed in cold 2/3-1/3 solution. In the case of synthetic grafts, no further surgical procedures were necessary following exposure of the femoral artery sites.

At this point, having procured the graft segments, the surgical wounds were closed by surgically approximating the various layers divided, and finally performing the skin closure with subcutaneous continuous 2-0 chromic gut suture. Now the femoral artery graft site, having been protected with saline soaked lap pads in the interval, was again exposed, adventitia was removed from the anastomotic site, taking care however now to indiscriminantly strip away excessive areas of adventitia. The graft segments were tailed to approximate length of the recipient site, and the ends of the graft segments were tailored for the anastomosis by spading, as demonstrated by Dr. Callaghan.

The dog was now heparinized utilizing a dosage of 0.3 milliliters of 1000 unit per milliliter swine mucosa heparin per kilogram body weight of the dog. DeBakey angled peripheral vascular clamps were now

applied proximally and distally to the graft site on the femoral artery and a longitudinal arteriotomy was made in the femoral artery for the proximal anastomosis. The first graft segment was now taken out of the cold saline solution and the anastomosis was performed as described (Figure 4). The proximal vascular clamp was now momentarily released to assess adequacy of the anastomosis while holding gentle digital pressure on the free end of the graft segment. The distal anastomosis was completed in a similar manner as the proximal and the vascular clamps were removed, distal first. The anastomoses were again examined and any excessive bleeding points were oversewn with a figure of eight suture taking care to include only adventitial fibres and not re-enter the lumen. Papaverine was now sprayed onto the external surface of the autogenous grafts with a fine syringe to reverse any vascular spasm induced by the manipulative procedures which, in some cases, was quite obvious and significant. The second graft was now performed on the contralateral femoral artery similarly (Fig. 5).

Following completion of both grafts, the femoral arterial segment underlying the graft on the right hand side was ligated, taking care not to physically embarrass either anastomosis (Figure 6).

Flow measurements were now taken on the grafts using an SE Medic flowmeter and an external electromagnetic flow probe. To reverse anticoagulation, protamine sulphate was now given in a dose of approximately half that required to equilibrate with the total heparin dosage, as the time elapsed since heparinization at this point was usually one half to one hour. After assuring all blood oozing was arrested, the femoral sites were closed, leaving the grafts in a


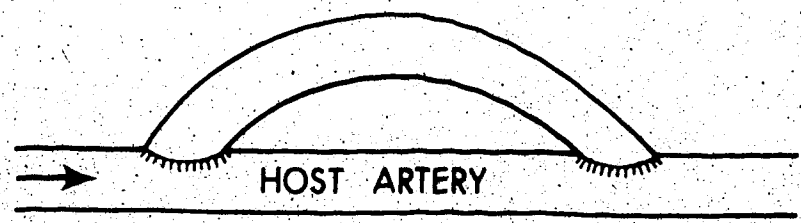


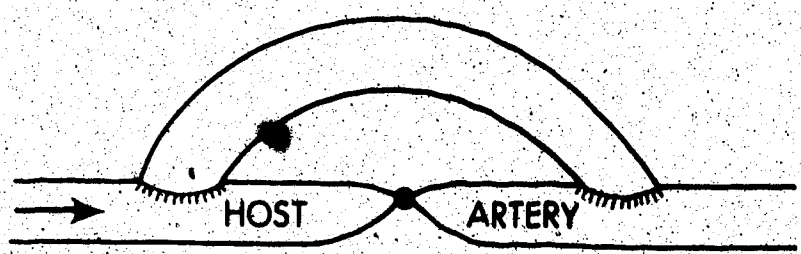
Figure 4 Initial stage of implantation of autogenous venous segment.



Figure 5 Completed graft; animal still heparinized.



1. GRAFT AS SIMPLE BYPASS WITH COMPETITIVE FLOW (PARALLEL)



2. GRAFT AS SIMPLE BYPASS WITH HOST ARTERY LIGATED (SERIES)

Figure 6 Diagrammatic representation of hemodynamic situation of grafts.

subcutaneous position for easy palpable assessment of patency. Care was taken during closure to ensure no tissue planes exerted pressure upon the grafted segments. Final skin closure was again performed with a continuous 2-0 chromic gut subcutaneous suture. Following operation, an intramuscular injection of Durapen penicillin was administered prophylactically and the dog was returned to the vivarium.

The grafts were now assessed for patency every three to four weeks by percutaneous angiography. In our experimental series, a total of twelve dogs were done using each type of autogenous graft. The extra two dogs in each group were kept as a precaution against unusual infection or other serious complication. A series of ten dogs were done utilizing four millimeter dacron grafts. For our experimental series we chose Sauvage TM external velour, four millimeter internal diameter, crimped dacron grafts (Figure 7). We received a total of 32 various wrapped and machined polyurethane grafts from Bentley Laboratories, and thus this series included a total of sixteen animals (Figure 8). The only difference in techniques for implanting the synthetic grafts as opposed to the procedures used for the autogenous grafts as described, is that blood was drawn from the animal prior to heparinization and the grafts were preclotted. Also, in the case of the polyurethane grafts, the underlying arterial segments were all ligated to increase flow and optimize conditions for patency. The ends of half of the synthetic grafts of both types were prepared by simple bevelling as opposed to spading which was done on the other half. This variation was utilized merely for ease of anastomosis.

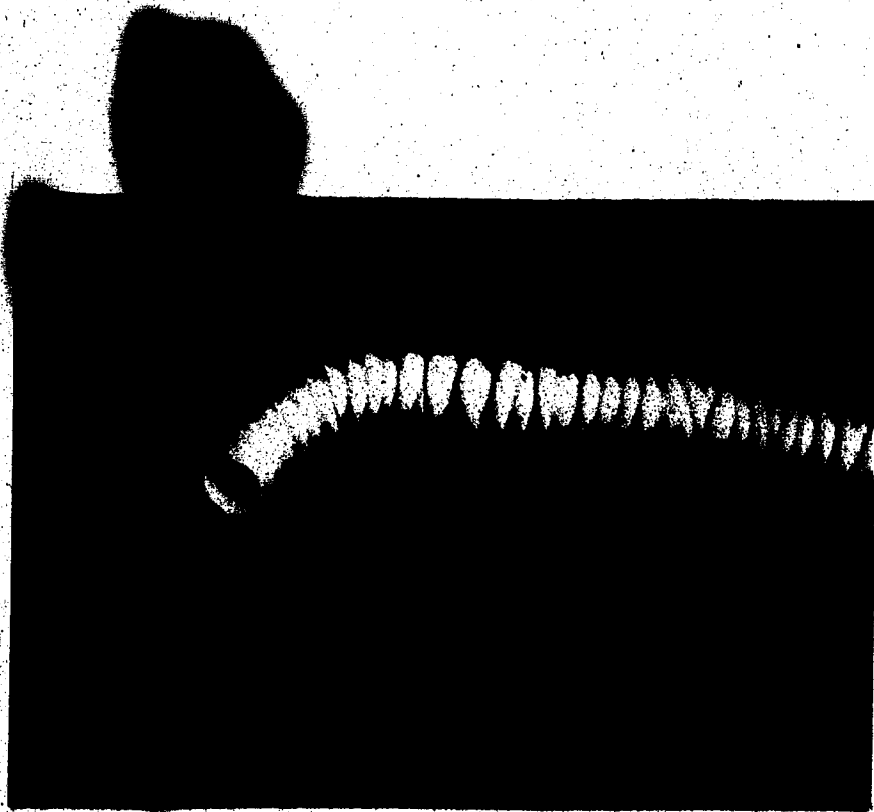


Figure 7 Shows the external velour 4 mm dacron graft.



Figure 8 Uniform diameter 3 mm polyurethane foam graft.

CHAPTER III

RESULTS

Various types of grafts were implanted in our series of dogs over a time period of four months. Our dogs, obtained from the Health Sciences Animal Center of the University of Alberta, were a random selection of various mongrel types, ranging in size from 13 to 32 kilograms body weight, with the average body weight being approximately 20 kilograms. In all cases, the surgical procedures employed were as described previously. The only significant surgical complication encountered was that of bleeding. In most cases, intraoperative bleeding was minimal, being estimated at 100 to 200 milliliters and accounted for by bleeding during implantation at release of clamps, and also anastomotic bleeding prior to reversal of anticoagulation. In some cases bleeding occurred in moderate amounts, being estimated at 400 to 500 milliliters. This was usually accounted for by longer operation time or excessive bleeding from anastomotic sites requiring additional sutures. In these cases, 500 to 1000 milliliters of Ringer's lactate solution was administered intravenously as replacement fluid. In no case did mortality result from intraoperative bleeding and lack of whole blood replacement. One dog in the series expired intraoperatively as a result of anesthetic overdose. No other intraoperative complications were encountered.

Several postoperative complications occurred in our experimental series. The most usual was breakdown of suture lines due to the dogs

chewing at the sutures. This resulted in infection, and required surgical debridement and repair. This complication was encountered in several dogs in the series. No other types of wound infections occurred. Two dogs in our series of dacron grafts died one and two days postoperatively as a result of subsequent bleeding from the graft site. In both of these cases, examination revealed intact suture lines and no overt cause for the bleeding. One dog died suddenly two days postoperatively and no apparent cause of death could be discerned, this was, however, an acute dog, inadvertently supplied to us for a chronic experiment.

Group I: A series of twelve dogs was included in this group utilizing autogenous vein grafts. All the dogs survived and did well postoperatively. Intraoperative flow measurements taken in the grafts demonstrated that, generally, in the parallel bypass situation, approximately one third to one half of the total arterial flow would be carried by the graft. In the case where flow was entirely through the graft segment, graft flows would approximate flows normally occurring in the femoral artery. Flow measurements are given in Table I. Blood pressure measurements taken using an arterial catheter connected to a pressure transducer demonstrated normal intraoperative blood pressures in the femoral artery to be 120-130 systolic and 70-80 diastolic. Pressure recordings were made early in several dogs and then was assumed similar for the rest of the series.

Angiograms were done every three to four weeks from operation to sacrifice. Angiography was performed by percutaneous puncture of the femoral artery using 16 and 18 gauge arterial catheters and injection

TABLE I

FLOW MEASUREMENTS - GROUP I

<i>Dog No.</i>	<i>Weight Kg.</i>	<i>Operation Date</i>	<i>Normal Artery Flow</i>	<i>Graft Flow</i>	<i>Sacrifice Date</i>
B-315	26.0	15/10/74	L 38 R 35	15 (P) 16 (P)	14/2/75
B-141	14.2	19/10/74	L 30 R 30	10 (P) 30 (S)	14/2/75
B-416	20.4	23/10/74	L 35 R 35	15 (P) 30 (S)	18/2/75
B-323	16.0	21/10/74	L 30 R 32	12 (P) 30 (S)	18/2/75
B-461	20.2	25/10/74	L 38 R 40	20 (P) 35 (S)	18/2/75
B-410	29.6	22/10/74	L 45 R 48	20 (P) 40 (S)	18/2/75
B-427	21.4	24/10/74	L 35 R 35	12 (P) 32 (S)	19/2/75
B-182	15.0	28/10/74	L 32 R 30	28 (S) 12 (P)	19/2/75
B-434	31.5	29/10/74	L 50 R 48	28 (P) 45 (S)	19/2/75
B-425	26.0	31/10/74	L 38 R 40	35 (S) 40 (S)	19/2/75
B-412	28.4	5/11/74	L 35 R 35	13 (P) 30 (S)	19/2/75
B-528	28.0	2/12/74	L 35 R 40	10 (P) 35 (S)	19/2/75

L - left

R - right

P - graft in parallel with artery

S - graft in series; artery ligated under graft

of several milliliters of Vascoray.

Of the 24 saphenous vein segments implanted, one occluded prior to the initial angiography, otherwise all remained patent until sacrifice. Sacrifice was carried out between 100 and 120 days postoperative.

Group II: Again twelve dogs were included in this group with two grafts implanted into each, for a total of 24 grafts. Flow measurements in this group were consistent with those of the preceding group and are given in Table II. Postoperatively, angiography was done as in Group I. All grafts in this series remained patent to sacrifice, performed between 90 and 100 days postoperatively.

Group III: This group consisted of a series of ten dogs into which knitted dacron fabric tubes (Figure 7.) of lengths varying from 4 to 6 centimeters were implanted as the arterial conduit (Table III). Angiograms were done on this group beginning one week postoperatively, then every three to four weeks thereafter until sacrifice. This group was sacrificed after a time interval of 14 to 70 days. Unfortunately, due to physical circumstances, we were unable to leave these dogs for the total anticipated 100-day period, thus accounting for the great variability in sacrifice intervals. Of this group one dog died intraoperatively of an anesthetic overdose given intraoperatively as a maintenance dose. Two other dogs died, one and two-days postoperatively, as previously mentioned. These three dogs were necessarily excluded from the group.

Group IV: This group consisted of sixteen dogs into which two polyurethane foam conduits were implanted. These grafts

TABLE II

FLOW MEASUREMENTS - GROUP II

Dog No.	Weight Kg.	Operation Date	Normal Artery Flow	Graft Flow	Sacrifice Date
B-466	15.0	19/11/74	L 30 R 30	28 (S) 12 (P)	21/2/75
B-525	19.2	20/11/74	L 35 R 35	30 (S) 18 (P)	21/2/75
B-522	21/4	22/11/74	L 35 R 38	35 (S) 20 (P)	24/2/75
B-547	21.0	26/11/74	L 35 R 35	32 (S) 16 (P)	24/2/75
B-529	30.0	27/11/74	L 40 R 42	38 (S) 25 (P)	24/2/75
B-489	23.5	29/11/74	L 35 R 35	30 (S) 15 (P)	24/2/75
B-454	30.5	6/11/74	L 42 R 40	40 (S) 22 (P)	24/2/75
B-238	14.2	8/11/74	L 28 R 30	25 (S) 15 (P)	25/2/75
B-453	25.2	12/11/74	L 35 R 35	35 (S) 14 (P)	25/2/75
B-469	22.5	13/11/74	L 35 R 35	30 (S) 12 (P)	25/2/75
B-467	24.7	14/11/74	L 35 R 36	35 (S) 16 (P)	25/2/75
B-471	22.0	15/11/74	L 35 R 35	30 (S) 15 (P)	25/2/75

TABLE III
FLOW MEASUREMENTS - GROUP III

Dog No.	Weight Kg	Operation Date	Normal Artery Flow	Graft Flow	Sacrifice Date
B-536	28.0	13/12/74	L 50 R 48	50 (S) 35 (S)	25/2/75 LO*
B-530	27.0	16/12/74	L 45 R 45	45 (S) 40 (S)	2/1/75 BO†
B-598	25.5	20/12/74	L 40 R 40	40 (S) 40 (S)	26/2/75
B-608	20.2	23/12/74	L 30 R 40	30 (S) 35 (S)	26/2/75
B-482	17.0	31/12/74	L 40 R 35	35 (S) 35 (S)	10/3/75
B-636	35.7	2/1/75	L 65 R 65	40 (S) 65 (S)	10/3/75
B-572	17.2	3/1/75	L 35 R 35	25 (S) 25 (S)	10/3/75 LO*
B-622	17.4	6/1/75	L 35 R 35	35 (S) 15 (S)	21/11/75 RO‡
B-758	30.2	8/1/75	L 50 R 48	45 (S) 45 (S)	10/3/75
B-739	29.0	9/1/75	L 45 R 45	35 (S) 40 (S)	10/3/75 RO‡

* Left occluded

† Bilateral occlusion

‡ Right occluded

were specially constructed by three separate techniques as listed in Table IV. This group was implanted in three separate sets. In the first set, all were implanted as simple bypass conduits and the underlying artery was left patent. These dogs were left to heal for one week, similar to the preceding dacron group, before angiography. Initial angiography after this interval disclosed occlusion in all cases and these dogs were sacrificed at this point.

In the second set, the underlying artery was ligated to increase flow and optimize patency. Also, angiograms were done at six-hour intervals until 24 hours, then at 24-hour intervals until occlusion to follow the course more closely. The intraoperative flow studies and times of occlusion of this set are listed in Table V. The final set of grafts were implanted and followed similarly to the second set with results as indicated in Table V.

Histologic and Electron Microscopic Results

All autogenous grafts were subjected to routine histological and electron microscopic analysis in an attempt to delineate their structural and cellular characteristics. Sections were taken throughout the length of the grafts, including anastomotic areas. From every graft several sections were stained with hematoxylin and eosin stain for routine structural study. Several sections from every graft were also subjected to one of several connective tissue stains selected to more clearly demonstrate the various structural changes occurring.

Group I: All sections of autogenous saphenous vein grafts showed various degrees of alteration from normal venous structure. The most common change was seen to occur in the intimal layer, and consisted of varying degrees of intimal thickening. The amount of

TABLE IV
POLYURETHANE FOAM GRAFTS

<i>Machined</i> [†]	<i>Wrapped</i>	<i>Tapered</i> [‡]
7001-142	7001X-154	7001-T-003
7001-131	7001X-155	7001-T-002
7001-136	7001X-153	
7001-132	7001X-151	
7001-140	7001X-157	
7001-133	7001X-152	
7001-135	7001X-156	
7001-139	7001X-147	
7001-128	7001X-145	
7001-138	7001X-146	
7001-130	7001X-150	
7001-137	7001X-144	
7001-129	7001X-149	
7001-141	7001X-148	
7001-134	7001X-143	

Grafts are listed in order of decreasing permeability.

[†] See Figure 8

[‡] See Figure 9




Figure 9 Tapered 3 mm polyurethane foam graft.

TABLE V

FLOW MEASUREMENTS AND FUNCTION DURATION - GROUP IV

Dog No.	Weight Kg.	Graft	Normal Flow	Graft Flow	Occlusion Hours
<u>Set 1</u>					
B-594	17.5	7001-142	R 35	22.5	
		7001-141	L 35	15	
B-632	23.4	7001-139	R 38	15	
			L Artery vestigial		
B-631	19.2	7001-136	R 38	20	
		7001-140	L 40	15	
B-623	17.2	7001-129	R 35	22	
		7001-138	L 30	15	
B-656	18.2	7001-133	R 36	15	
		7001-135	L 35	15	

<u>Set 2</u>					
B-675	16.0	7001X-148	R 32	30	6
		7001X-146	L 30	30	6
B-667	21.7	7001X-151	R 35	25	72
		7001X-130	L 38	28	24
B-666	25.6	7001-131	R 40	25	24
		7001-132	L 40	28	24
B-678	28.0	7001X-155	R 38	27	18
		7001X-137	L 40	30	18

<u>Set 3</u>					
B-690	28.0	7001X-154	45	22.5	6
		7001-T-002	48	37.5	48
B-686	24.0	7001X-143	38	32	72
		7001X-153	38	25	72
B-689	26.6	7001X-144	40	30	7
		7001X-152	40	27	7
B-739	34.0	7001-T-003	60	55	120
		7001-145	60	32	12
B-730	24.0	7001X-149	35	30	48
		7001X-157	35	24	6

Set 1 - Polyurethane foam conduits implanted as simple bypass conduits with the underlying artery left patent.

Set 2 - Underlying artery ligated to increase flow and optimize patency.

Set 3 - Underlying artery ligated to increase flow and optimize patency.

intimal thickening which occurred varied greatly between grafts and also throughout the same graft. In some sections it was seen to be quite extensive, encroaching well into the lumen, while in other areas it was minimal. No section was seen, however, to be completely free from intimal change. Despite the very rudimentary internal elastic membrane present in the canine saphenous vein, it is possible to delineate the limits of the intimal thickening by using connective tissue stains and also distinguish it from the more regular smooth muscle layers of the media. The intimal thickening was seen to be composed of various amounts of connective tissue elements and smooth muscle cells. In some areas it gave the appearance of organized thrombotic material. From the electron micrographs, the intima could be seen to be composed of a continuous endothelium. Many of the endothelial cells appeared thickened in places, almost cuboidal, suggestive of injury. Underlying this could be seen smooth muscle cells and fibrous elements of connective tissue, mainly collagen. The smooth muscle cells demonstrated a normal appearance with some showing increased density suggestive of aging.

The media of the vein grafts showed increased collagenization and many areas of decreased density of smooth muscle cells. In some sections the media appeared to be relatively normal. The adventitial layer showed increased collagenization.

At the anastomotic sites, the grafts showed increased amounts of intimal thickening of the same nature as elsewhere. The other changes were similar to those seen elsewhere in the grafts. These various changes are demonstrated in figures 10 to 20 taken as

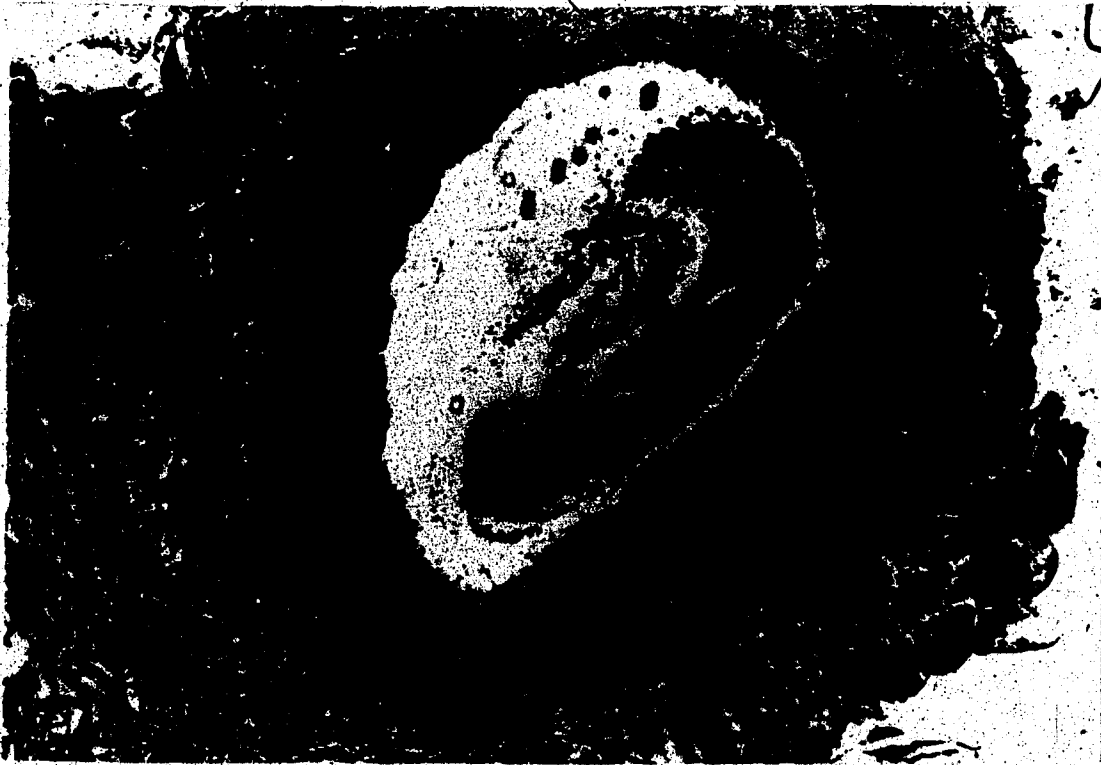

Figure 10 Cross-section graft B-412 right; arrows demarcating extent of intimal hyperplasia.




Figure 11 Cross-section B-461 right; arrows demarcating extent of intimal hyperplasia. Note varying thickness. Also note paucity of smooth muscle cells in media.

Figure 12 Electron microscopy of same graft as Fig. 11.
Section through intima.

- (1) endothelial cell, somewhat thickened
- (2) smooth muscle cells
- (3) probable dense smooth muscle cell;
questionable fibrin
- (4) typical appearance of collagen





Figure 13. Cross-section B-427 left. Again note varying thickness of intimal hyperplasia.

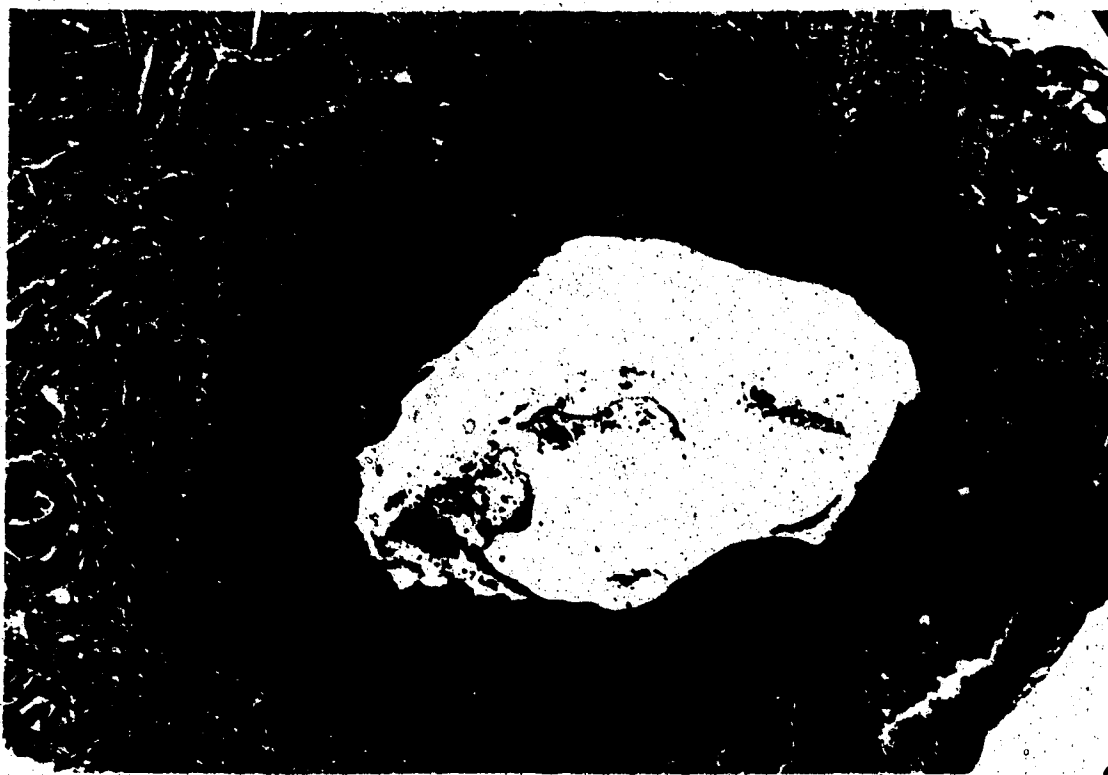

Figure 14 Cross-section B-528 left. Note again intimal thickening (1). Also separation of smooth muscle cells of media due to collagenization (2).

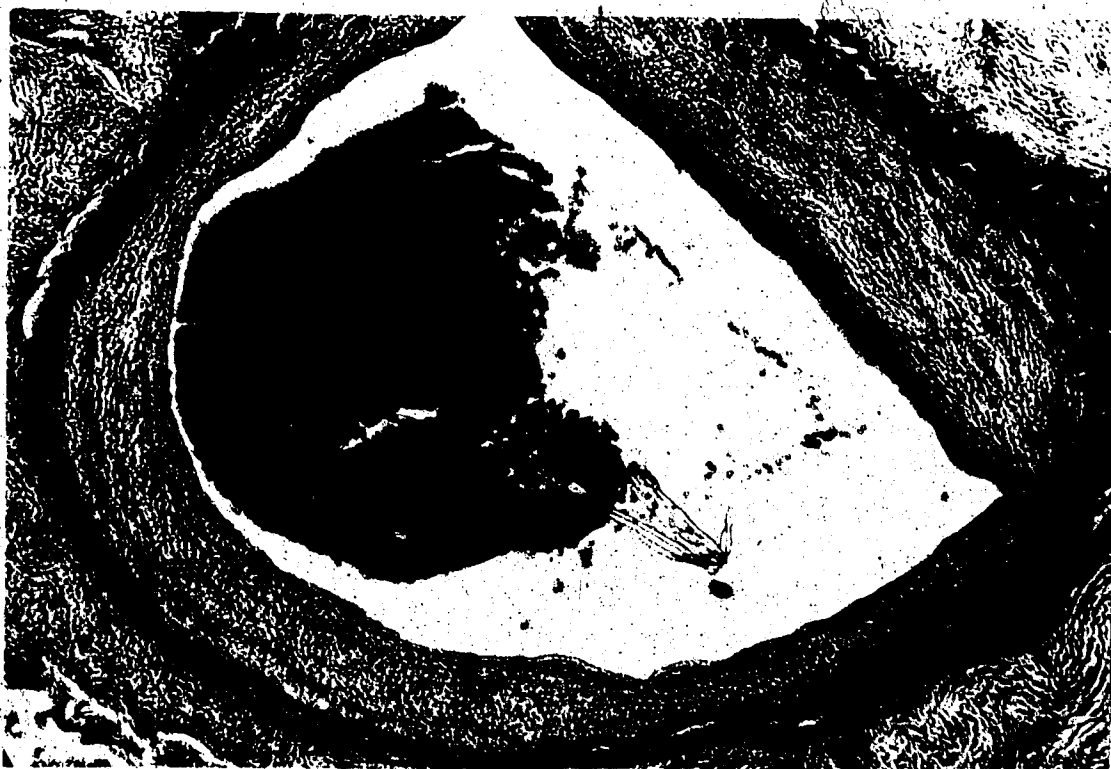

Figure 15 Cross-section B-434. Relatively thin layer of intimal hyperplasia. Area giving appearance of organized thrombotic material (1).

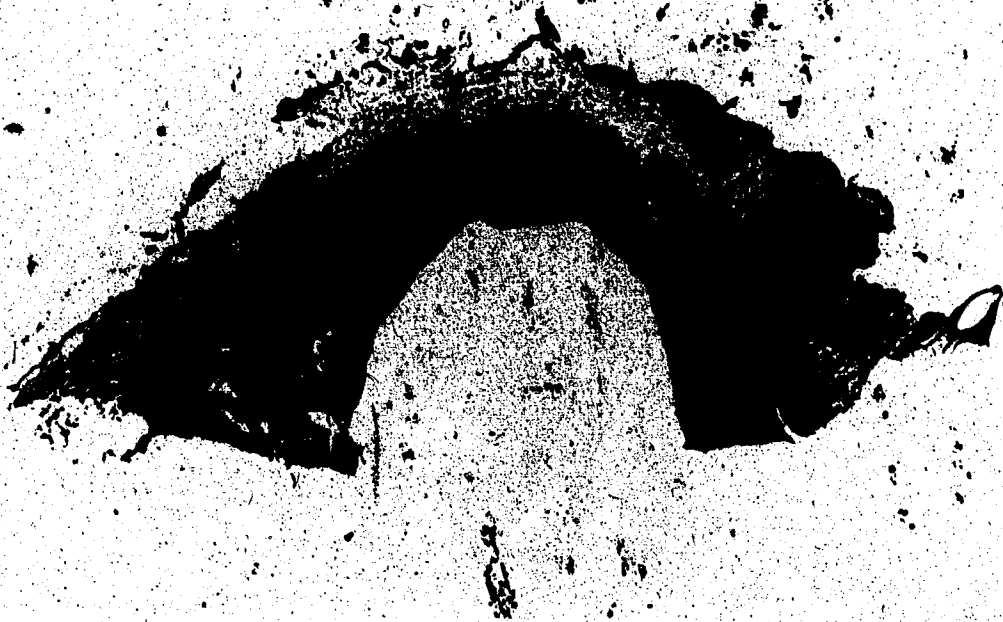

Figure 16 Cross-section anastomotic region B-412. Arrows demarcating intimal layer.

Figure 17 Electron microscopy B-410 left.

- (1) lumen
- (2) endothelial cell - normal appearance
- (3) polymorph in intima
- (4) smooth muscle cells
- (5) collagen fibres in close association with smooth muscle cells

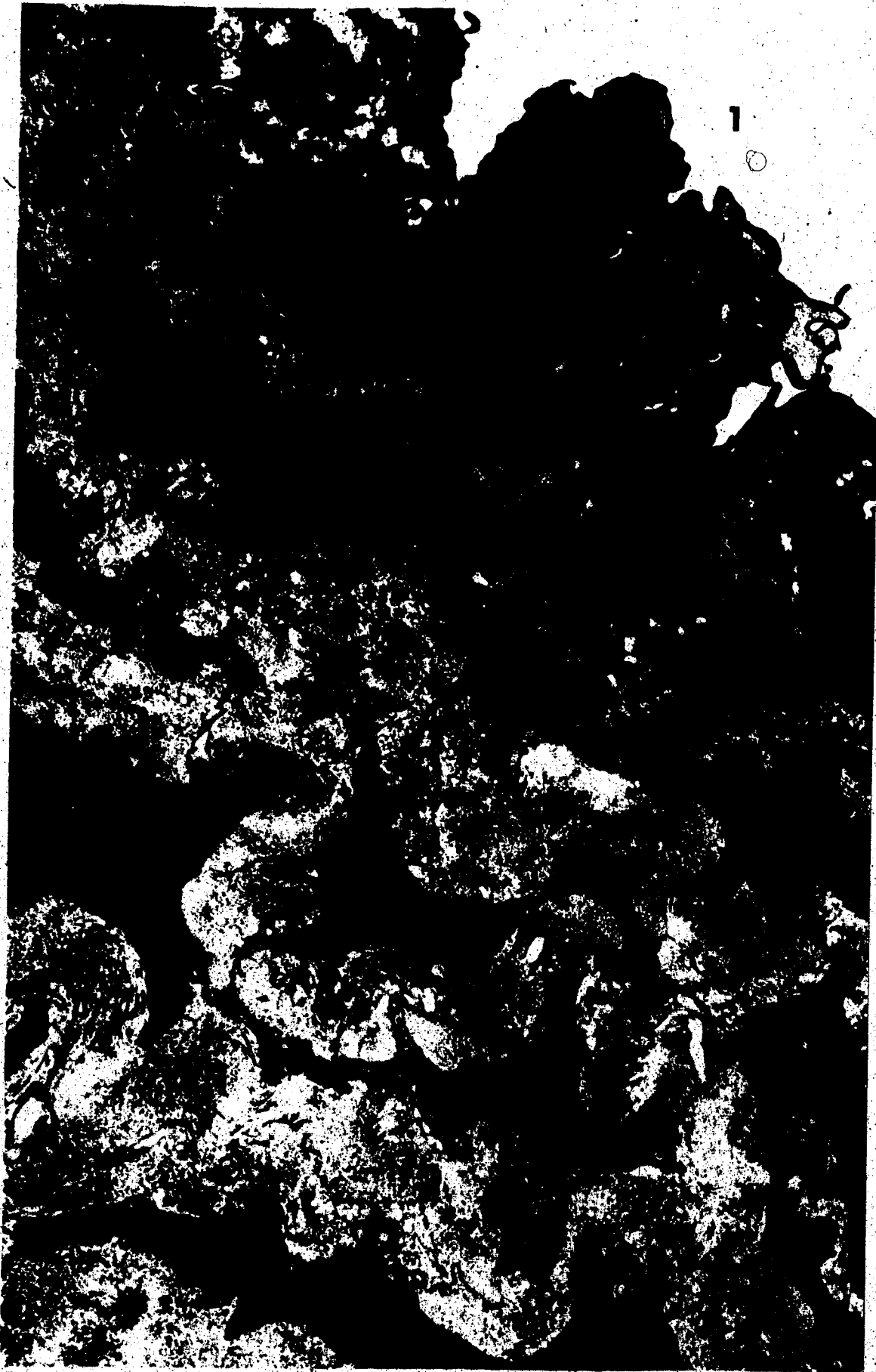

Figure 18 Electron microscopy B-410 right. Section extending into media.

- (1) lumen
- (2) endothelium
- (3) smooth muscle cells.

Note increasing amounts of collagenization toward media.




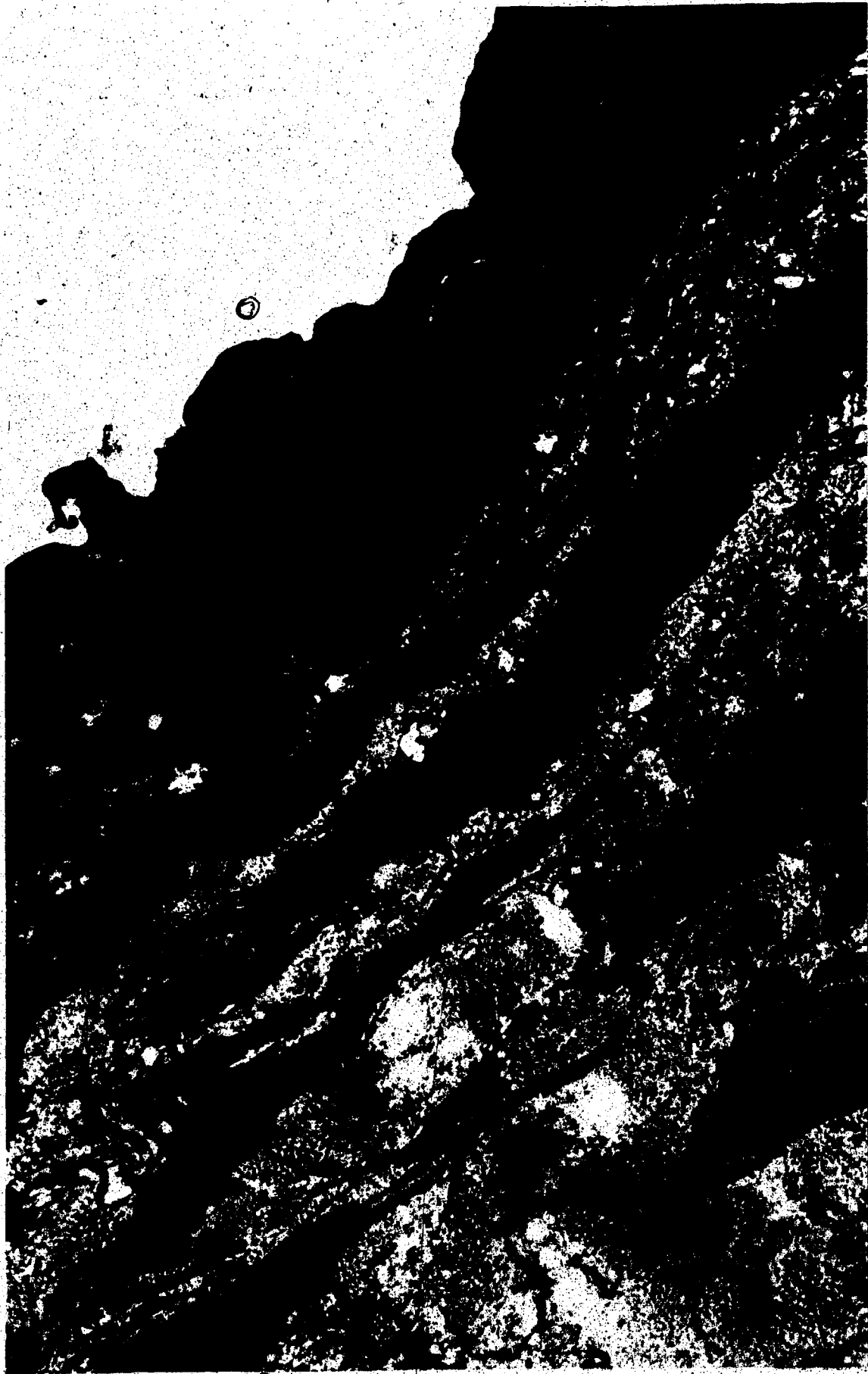

Figure 19 Electron microscopy of intimal layer B-410 right.
Endothelial cells showing almost cuboidal
appearance.




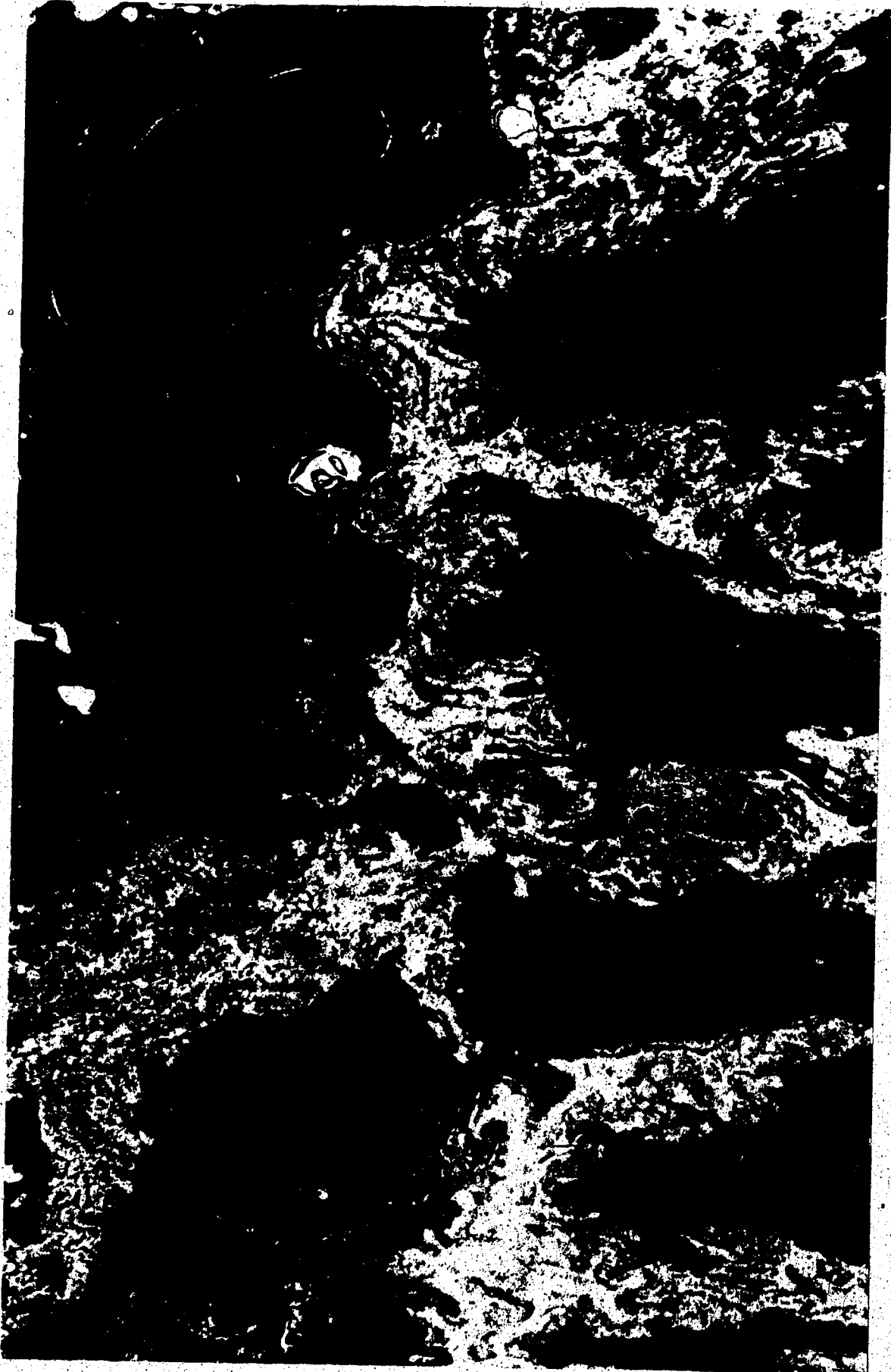The image is a high-magnification electron micrograph showing a complex, granular surface. The texture is highly irregular and porous, with numerous small, dark, rounded features scattered across a lighter, textured background. The overall appearance is that of a highly detailed, three-dimensional surface structure, likely biological or synthetic in origin. The image is somewhat grainy and has a high level of contrast, typical of electron microscopy.

Figure 20 Electron microscopy of luminal aspect B-461
left. Again note polymorph in intima.



characteristic of the autogenous vein group.

Group II: Most sections of autogenous arterial grafts showed an appearance approximating normal arterial structure very closely. On cross-section, they showed a complete endothelium, with the endothelial cells demonstrating normal flattened appearance. Underlying this was a very narrow subendothelial space, then a normal internal elastic membrane.

The media was seen to be composed of layers of smooth muscle cells and elastic lamina with some collagen fibers. Some areas showed increased collagenization and separation of the muscle cells. The smooth muscle cells themselves appeared to be quite normal in structure. Finally, surrounding this, the adventitia showed heavy collagenization with occasional vasa vasorum.

Some areas showed slight intimal thickening with the appearance of collagen and cellular elements in the subendothelial space. The cells were seen to be polymorphs, smooth muscle cells and, in some cases, perhaps fibroblasts. These areas of thickening were never seen to be very extensive or encroaching upon the lumen as in the case of autogenous veins. This same intimal appearance occurred, also quite uniformly, at the anastomotic sites.

Figures 21 to 30 are sections taken as representative of Group

II.

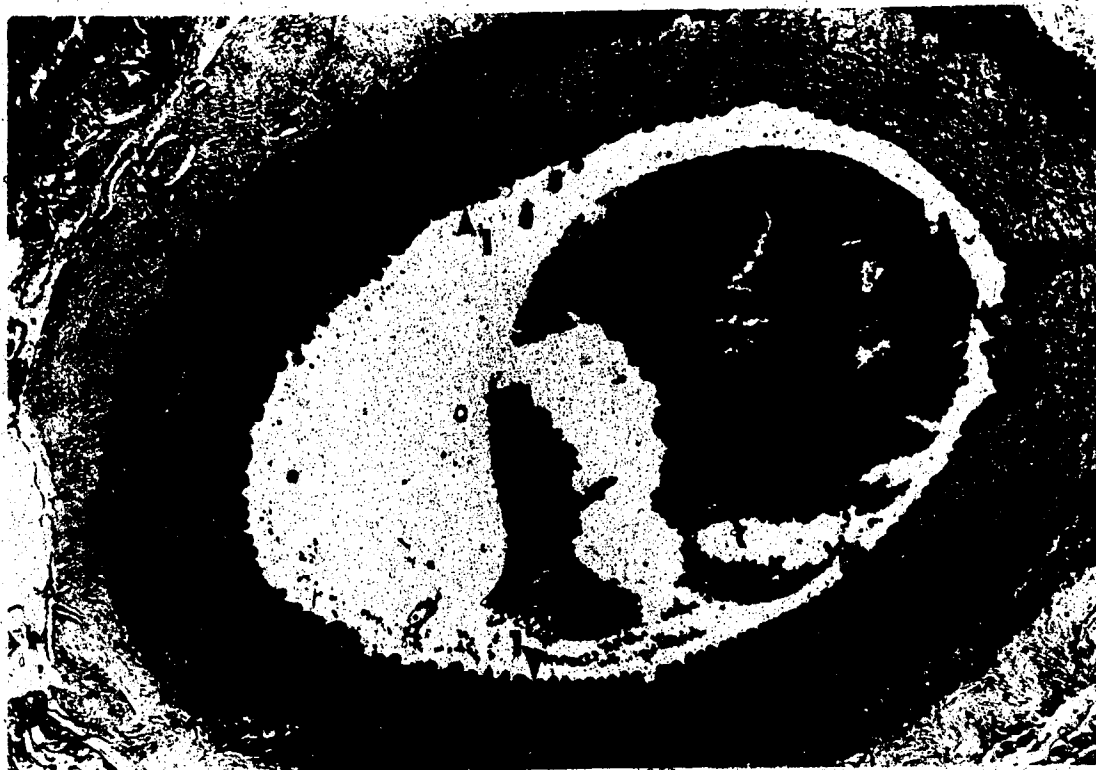

Figure 21 Cross-section B-469 left. Note normal intima bounded by internal elastic membrane (1). Media showing increased collagenization (2). Adventitia (3).

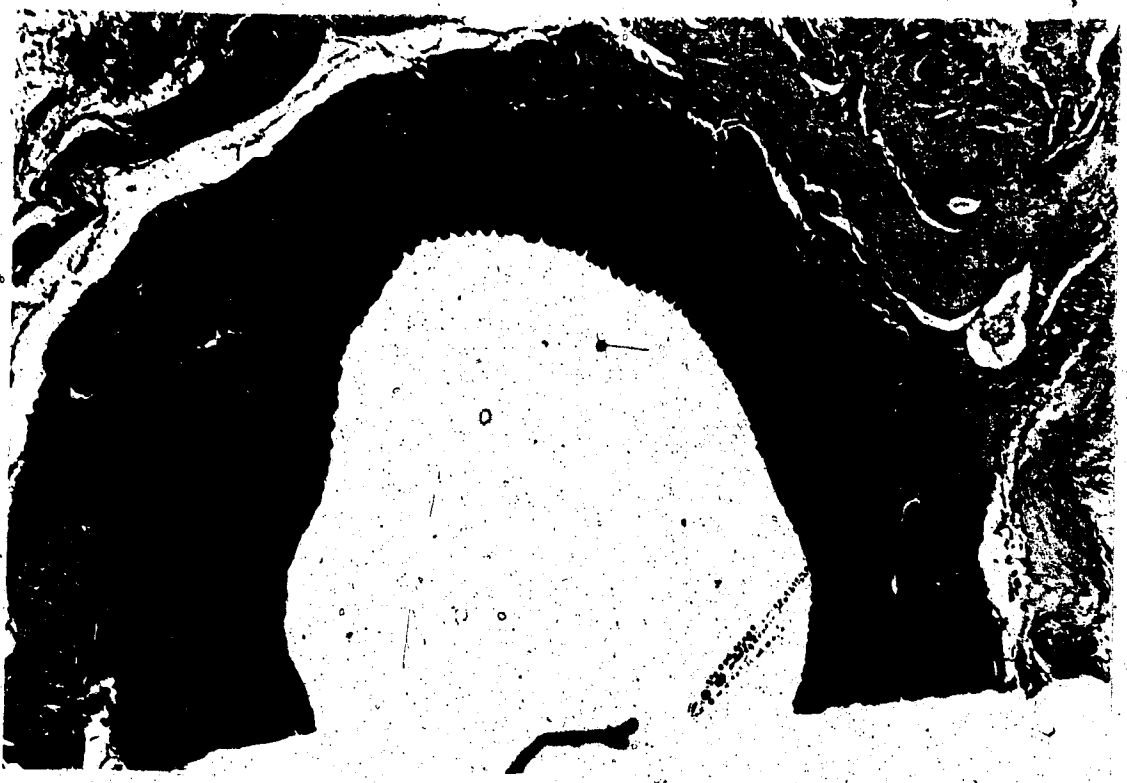

Figure 22 Cross-section B-469 right. Again note normal intima. Media with increased collagenization.

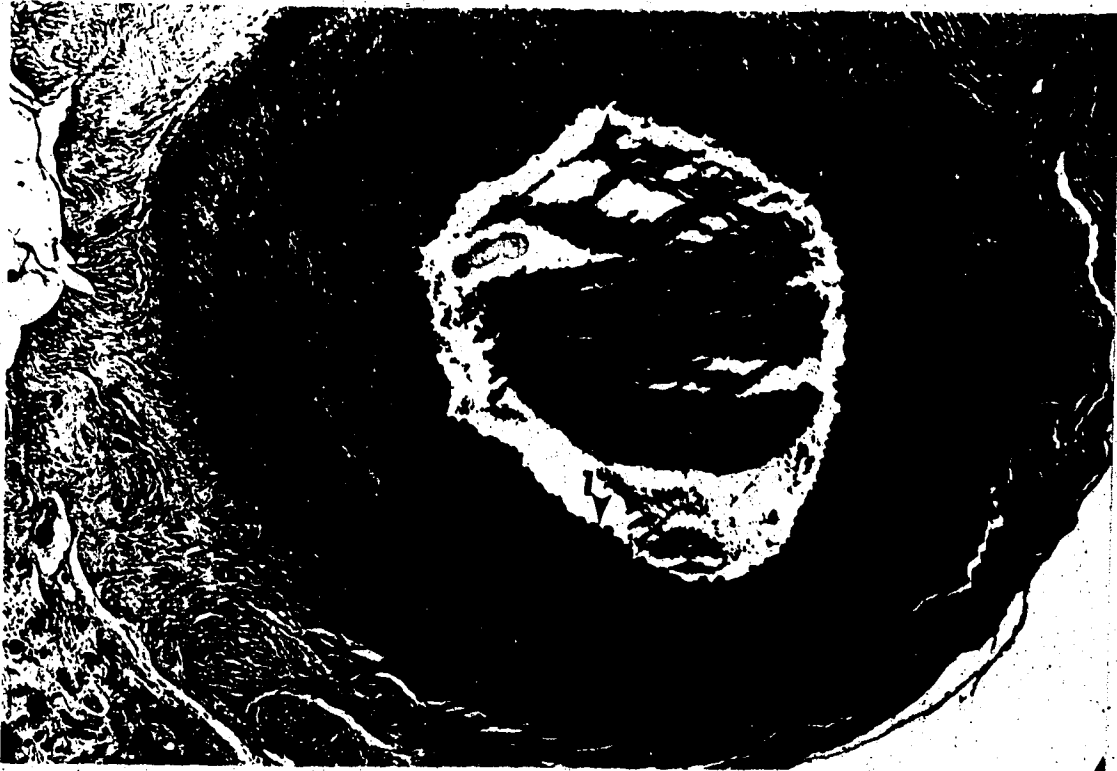


Figure 23 Cross-section B-489 left. Note normal appearing intima (1), media (2), and adventitia (3).



Figure 24 Electron microscopy of intima and inner media
B-489 right.

- (1) lumen
- (2) endothelium
- (3) internal elastic membrane
- (4) smooth muscle cells
- (5) collagen fibres

Note normal intimal structure.





Figure 25 - Cross-section B-522 right. Note areas demonstrating mild degree of intimal thickening (arrows). This section is one of only a few which demonstrate this appearance.

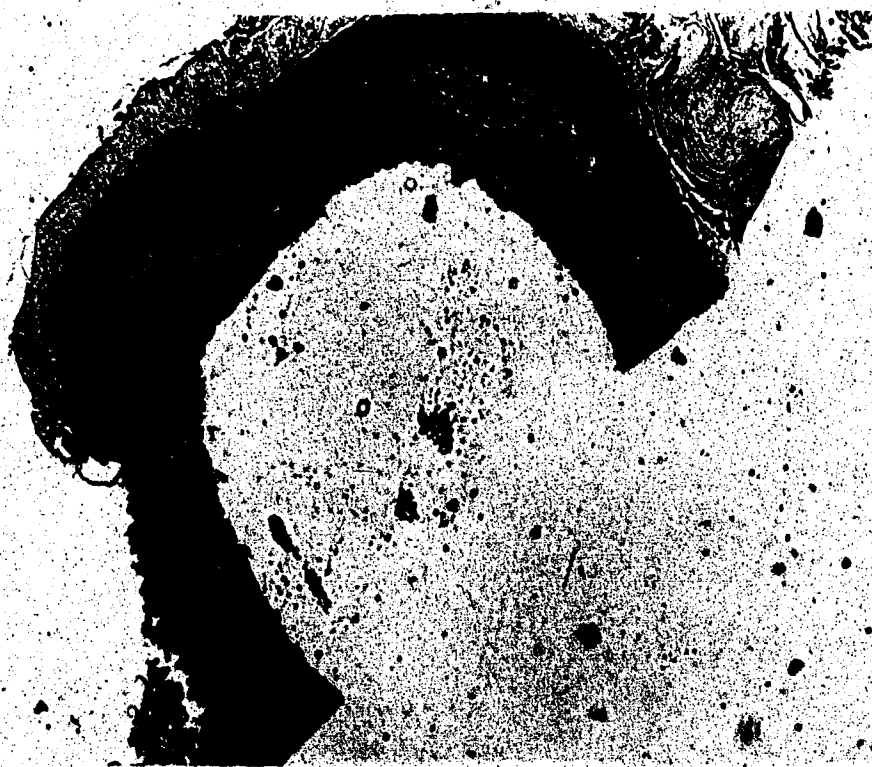

Figure 26 Cross-section B-471 right. Again showing
normal intima with some collagenization
of media.

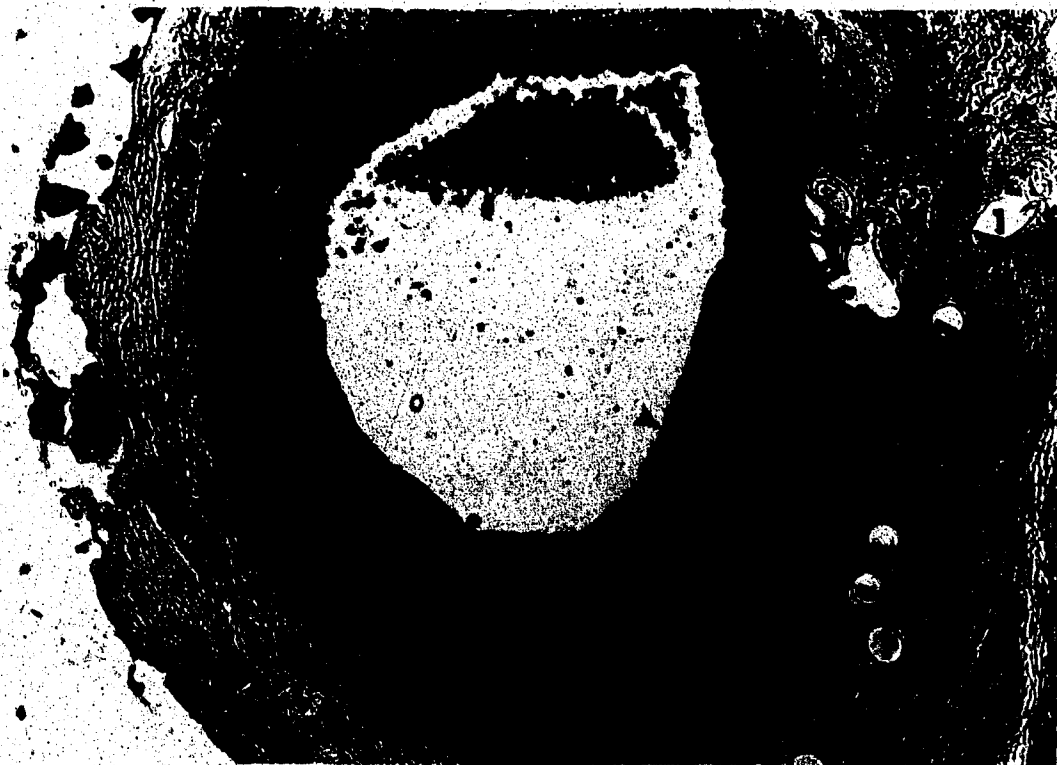
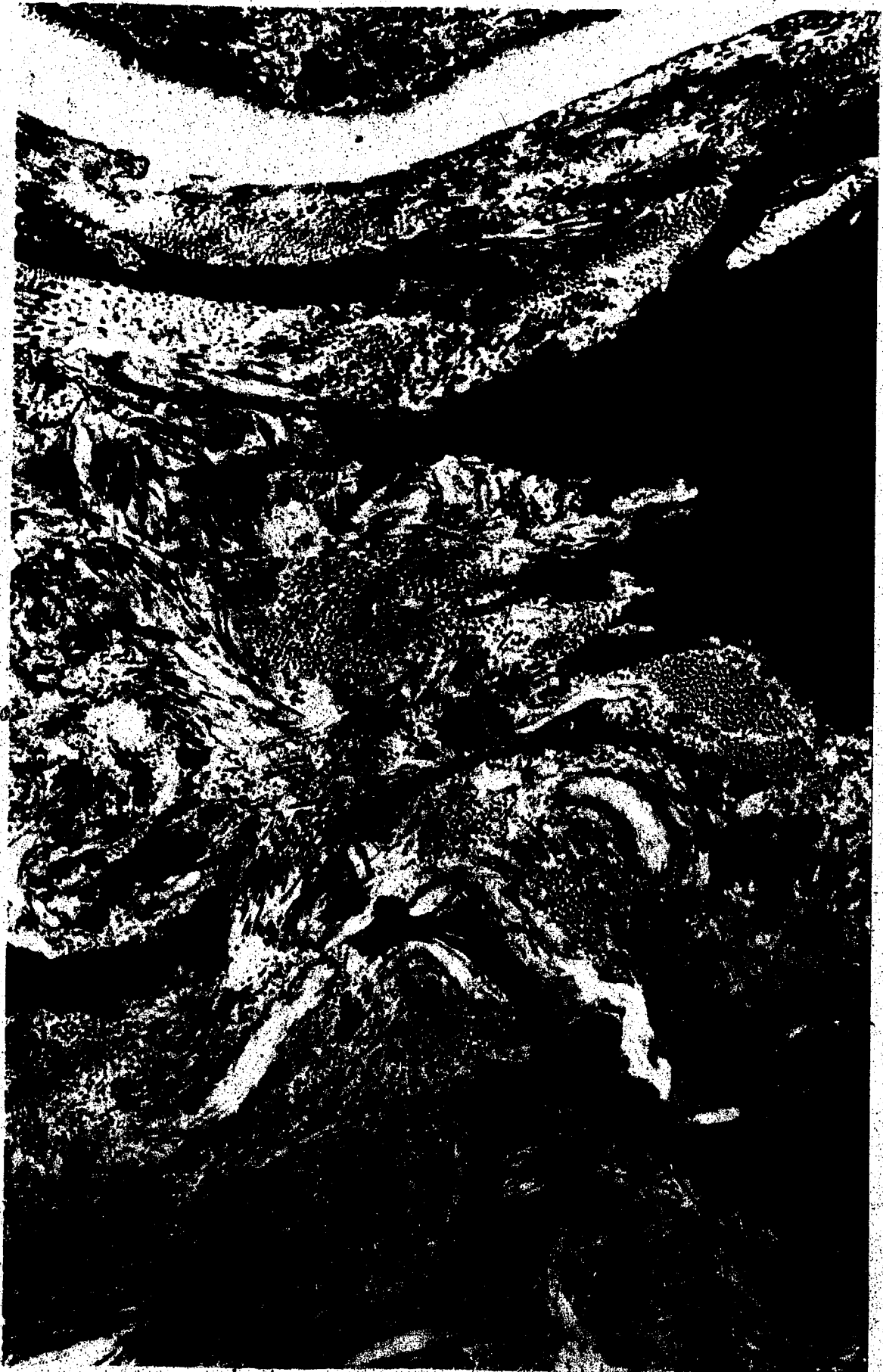
Figure 27 Cross-section B-547 left anastomotic site.
Note intimal hyperplastic reaction (arrows),
and also suture sites (1).

Figure 28 Electron microscopy B-466 right. Media.
Note increased collagen.






Figure 29 Electron microscopy B-466 left. Media. Demonstrating relatively normal structure with smooth muscle cells (1), elastic fibres (2) and collagen (3).

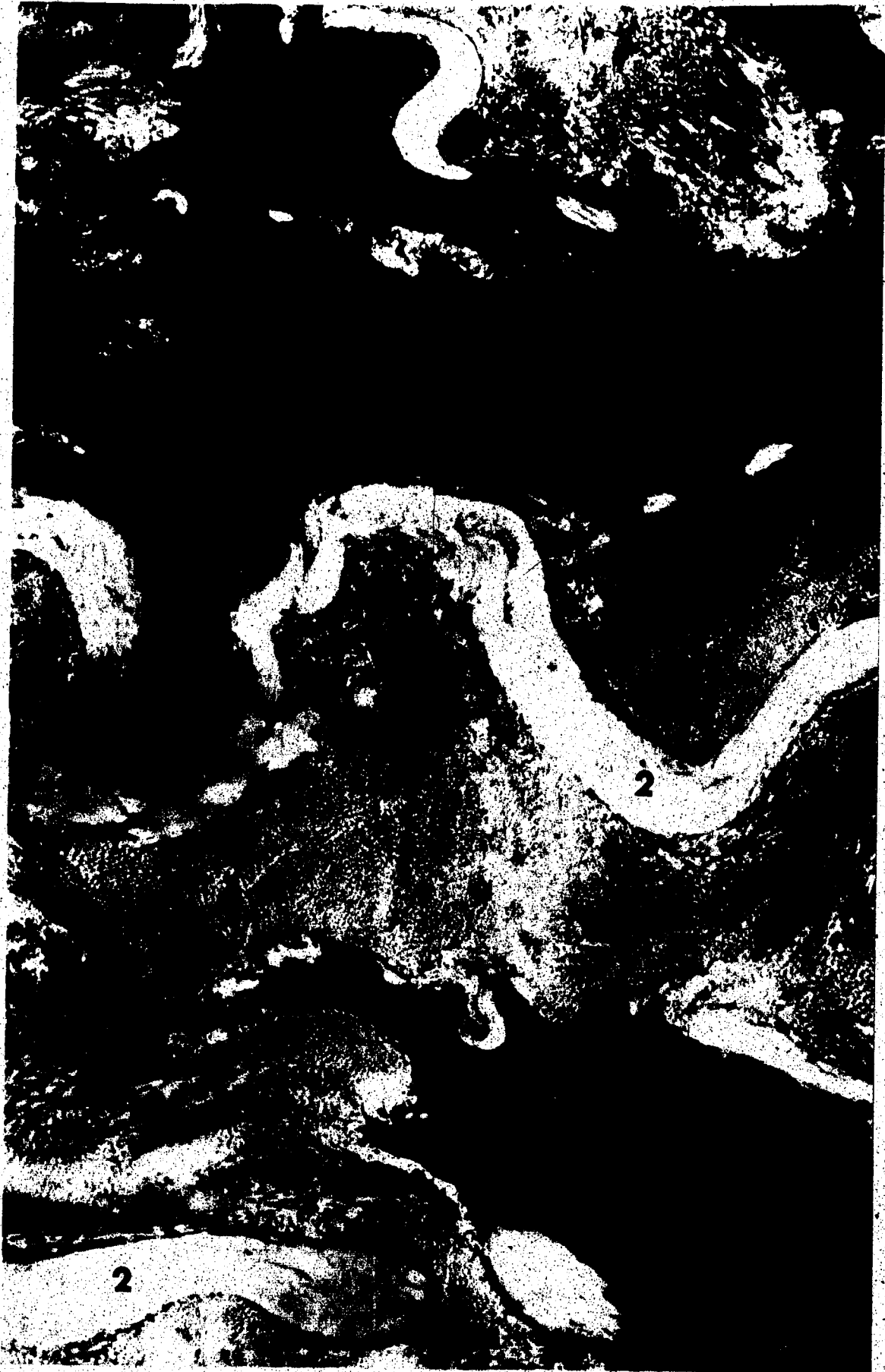
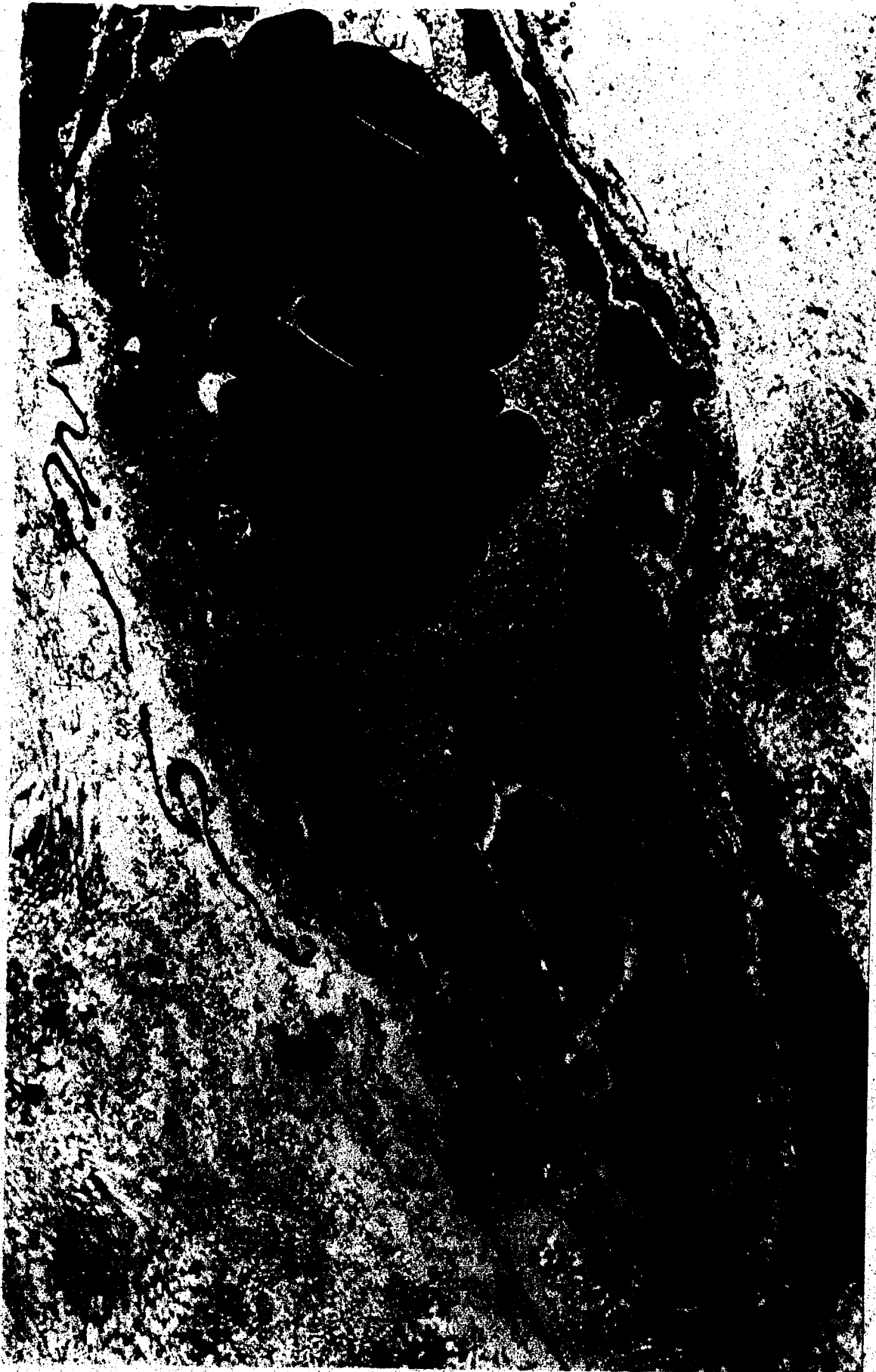



Figure 30 Electron microscopy B-466 left. Adventitia.
Note vasa vasorum and heavy collagenization.



CHAPTER IV

DISCUSSION

Autogenous Grafts

The histological changes occurring in autogenous venous segments interposed into the arterial system have been examined by various investigators since the extensive work by Carrel and Guthrie. They first described the changes as consisting of intimal thickening and fibrosis of the media and adventitia (1,3). This same pattern of change has been repeatedly reaffirmed in various other studies to the present time. Areas of contention between investigators have concerned the cause, nature and degree of these structural changes. Early studies concluded generally that the cellular elements involved were of connective tissue origin and the changes were in response to the higher pressure imposed by the arterial environment.

Recently with the extensive usage of saphenous vein segments in clinical aorto-coronary bypass surgery, renewed interest has increased efforts to clearly delineate the nature of the structural changes occurring in these grafts. Despite the structural difference between human saphenous vein segments and veins of experimental animals, good correlation exists between clinical and experimental studies.

Recent studies, both of experimental and clinically obtained specimens, have clearly defined many aspects of the nature of the structural changes, although controversy still remains the causative factors involved.

Cellular and structural changes have been demonstrated to

progressively occur in these grafts from the immediate post-implantation period to many months. The first noticeable change has been described as endothelial damage and desquamation occurring immediately post-implantation (76). Wyatt observed up to 70% endothelial desquamation at 48 hours (77). Subsequent and consequent to this endothelial disruption, mural platelet and fibrin deposition occurs. Regeneration of the endothelium occurs to completion in approximately 12 weeks. During the first week, medial edema with inflammatory infiltrates has been described (76). Also during this same period, Marti (78) has described a transient hypertrophy of the medial muscle cells. Within approximately two weeks of implantation, there is a beginning progressive necrosis of the medial myocytes and increasing medial fibrosis (79). This process continues to complete medial fibrosis by approximately twelve months. Within a period of four to eight weeks all grafts show increasing intimal thickening. This intimal hyperplasia is also progressive, gradually narrowing the lumen and thus ultimately determining the long term fate of the graft. This intimal hyperplasia consists of increasing cellular and fibrous invasion of the subendothelial space. The cellular elements in this process, originally thought to be fibroblasts due to their association with the other fibrous tissue elements present, have recently been identified as modified smooth muscle cells by electron microscopic examination (79-81). These modified smooth muscle cells proliferate and produce ground substance, collagen and other fibrous elements present in the earlier stages of intimal thickening, but later mature to typical smooth muscle cells. The origin of these cells in the sub-endothelial space, where they are not usually present, is thought to be

either from migration of smooth muscle cells from the media or differentiation from deposited fibroblasts. The temporal or physical extent to which this intimal hyperplastic process proceeds is variable and obscure. In some grafts it will proceed to complete occlusion of the lumen over a period of several months while in others, a static state appears to be reached maintaining luminal patency for years. The salient factors operative in determining the extent of this process are unknown.

The stimulus for the structural changes described are still conjectural. As mentioned, empirically it was thought these changes were an attempt of the venous wall to simulate arterial structure in direct response to the imposed arterial pressure. This 'arterialization' concept however leads to several observed discrepancies. The 'arterialized' vein in no way resembles normal arterial morphology. It is difficult to hypothesize the medial changes as being other than degenerative. Also, if the intimal changes are considered as being adaptive to pressure, then what stimulates the progression to occlusion seen in many cases? Confronted with these discrepancies, investigators have hypothesized other parameters as causative in the changes seen. Brody (79) experimentally demonstrated ischemia as causing the medial changes, subsequent to interruption of the vasa vasorum during removal. He hypothesized the intimal proliferation resulted from pressure and demonstrated an inverse relationship between the two processes. The causative role of ischemia in the medial changes is supported by other observations. Szilagyi (82) observed that the deterioration of the smooth muscle cells was maximal in the central regions of the media, with

persistence of cells in the immediate subendothelial and outer medial areas where nutrition could be maintained by diffusion. Concurrent with the role of ischemia, observations on experimental arteriovenous fistulas demonstrate that the major change occurring in the venous walls is limited to intimal proliferative response until marked physical disruption leads to fibrotic changes (83). Storm et al. (84) demonstrated that adventitial stripping of in situ veins results in no apparent histologic change, suggesting that perhaps warm ischemia time after removal is more important than merely devitalization from loss of vasa vasorum. Wyatt (77) demonstrated that neovascularization of the adventitia begins almost immediately at implantation with complete vasa structures within days. Other observations as well have specifically implicated warm ischemia time as being detrimental to venous segments (82,85). Szilagyi (86) has indeed suggested that optimal protection can only be provided by immediate immersion of the graft segment in heparinized whole blood at 4°C as even cold balanced salt solutions fail to prevent ultrastructural deterioration.

Recently, many researchers have been implicating endothelial damage as being related to the subsequent proliferative changes occurring in the graft segments. Endothelial integrity is critical in maintaining functional integrity of the vascular wall both by being selectively permeable to plasma constituents and also preventing platelet adherence or fibrin deposition to the highly thrombogenic subendothelial elements. Thus damage to, or desquamation of endothelial cells, leads to fibrin layering and also abnormal insudation of plasma and formed cells into the vessel wall. Small thrombotic deposits may be removed by

fibrinolytic activity, but larger deposits must be organized resulting in intimal thickening. Such thickening may inherently contribute to the observed intimal proliferation; it also has been demonstrated to be detrimental to underlying intimal and medial components by partially blocking diffusion (87). Abnormal insudation of plasma constituents into the intima and media may stimulate smooth muscle cell proliferation (81) leading eventually to the intimal hyperplastic changes.

Endothelial damage, speculatively, may be caused by several factors. Endothelial cells are specialized and highly reactive to various types of injury. Anoxia causes almost immediate opening of interendothelial junctions (88) and necrosis (89). Thus any warm ischemia time could potentially cause the marked endothelial sloughing observed by various experimentors. Endothelial cells are highly reactive to mechanical or hemodynamic stresses as well. The acute yield stress of the endothelial cells is relatively high (90) but even minimal turbulence can cause increased permeability, cytological changes and increased rate of mitosis (91). Physical handling of the grafts during implantation or any unusual hemodynamic situations after implantation may thus contribute to endothelial damage.

If desquamation occurs then direct insudation of blood components into the vessel wall can occur. However, cytological changes from cellular injury short of complete desquamation, also can allow abnormal insudation of plasma components. Unusual stretching of the endothelial cells caused by direct pressure may also result in permeability changes, even through a relatively intact endothelial layer. Speculatively, such unusual stretching could occur as a result of overstretching of the

venous wall by the improved arterial pressure. This unusual stretching may hemodynamically damage the endothelial cells resulting in observed permeability changes or the increased tension exerted upon the cells by stretching will increase the energy density of the blood vascular interface which can also be related to permeability changes (90). With endothelial changes altering the normal permeability barrier, and assuming a causative relationship between abnormal insudation of plasma and smooth muscle cell proliferation, theoretically at least the evolution of observed intimal hyperplastic changes can be anticipated.

In our group of autogenous vein segments, the changes which we observed were similar to those observed both clinically and from other experimental series. Various degrees of intimal hyperplastic changes were present in all grafts. There was no significant structural difference noticeable between the grafts left as simply bypasses and those in which the underlying arterial segment was ligated. The hemodynamic situation in these two cases will differ by the kinetic energy component.

The total fluid energy at any point in the circulation may be expressed by the equation:

$$E = P + pgh + 1/2 pv^2$$

where,

- E - total fluid energy
- P - pressure
- p - density
- g - acceleration due to gravity
- h - height above arbitrary point
- v - velocity of flow

In our experimental model, the second term (ρgh) may be neglected because of similar implantation site on both sides. The pressure term (P) will also be similar in the two cases. However, the last term will differ because of a differing blood velocity. With ligating the underlying artery, the flow through the graft segment will increase by increasing the velocity of flow, assuming relatively constant diameter. Szilagyi (82) has implicated intimal fibrin layering as a factor in determining the degree of intimal changes seen. The amount of fibrin layering which may occur is related to the velocity of blood flow, and thus it could be anticipated that, if indeed this process occurred in our grafts; some difference in the amount of intimal change may be noticeable. As this was not the case, we may say that in our experimental model, velocity changes within a physiological range maintaining laminar flow, do not appear to affect the degree of intimal hyperplasia. This conclusion may not apply where flow becomes turbulent or velocity is reduced to very low levels by restricted outflow tracts.

From our experimental group of autogenous vein segments, we have demonstrated that after a medium term interval the cellular changes occurring will consist of:

Intimal thickening:

The degree of which will vary both between grafts and within the same graft. The greatest degree appears to occur at the anastomotic sites, with lesser but varying amounts occurring elsewhere in the graft. This intimal thickening is composed of smooth muscle cells and fibrous elements of connective tissue.

Fibrosis of the media and adventitia:

Our group of autogenous arterial grafts demonstrated essentially no structural changes after the same medium term interval. This result is concurrent with observations of other experimental series where autogenous arterial grafts remained unchanged when implanted into another arterial site (92,93). Histologic studies of autogenous arterial patch grafts also demonstrated maintenance of essentially normal structure except for some medial fibrosis (94,95). Our results on these autogenous arterial segments would tend to contradict theories relating endothelial damage directly to the intimal hyperplastic phenomena as it appears only plausible to assume the same endothelial damage would occur in the arterial segments as in the venous. This would seem to imply that the intimal thickening seen in veins is indeed at least partially an adaptive reaction to the arterial environment.

These results differ from some clinical specimens obtained at this center and elsewhere, where histologic studies on autogenous arteries have demonstrated intimal hyperplastic changes. Correlation between our experimental results and those of clinical arterial specimens must be speculative. Various authors have implicated vasospasm as a factor causing failure of autogenous arterial grafts (96,97). In our series, the grafts were sprayed with papaverine solution to reduce vasospasm. It is possible that structural differences between the canine carotid artery and human radial artery may determine a different cellular response. Another consideration could be that with implantation of the radial artery to the aorto-coronary position, the

adequacy of the outflow tract may determine the ultimate response seen. With inadequate graft flow, fibrin layering may occur, eventuating in intimal hyperplasia.

Fabric Grafts

The group of dacron grafts showed an occlusion rate of 30% in our series. These graft failures occurred in the early postoperative period, before endothelialization could occur. The immediate cause of graft failure was luminal thrombosis in all cases, as seen at sacrifice. All grafts in this group were implanted similarly, with similar lengths. Flow measurements demonstrated no significant differences between the grafts remaining patent and the ones occluding, except in one case, B-622, where flow was markedly decreased. Thus the primary cause of the luminal thrombosis cannot be ascertained from this series. Speculatively, it would result from successive neo-intimal fibrin layering over the critical thickness of 500 μ , however, the factors operative in producing this in one graft and not another are obscure.

A patency rate of 70% proves to be unacceptable contemplating clinical usage. This patency rate could be anticipated to be even lower in clinical cases where longer segments would be used and perhaps lower flow rates maintained because of competitive flow.

Our group of polyurethane foam grafts demonstrated a 100% short term occlusion rate. The mean time of occlusion is approximately 18 hours, occlusion again resulting from luminal thrombosis. These results, although demonstrating a completely unacceptable function of these grafts are, however, significant. The three millimeter internal diameter dimension presents a very stringent test for any fabric material. At

this calibre, any physical aberration will result in immediate thrombosis. The critical thickness of neo-intima formation is determined to be even less than 500 μ tolerated at 4 millimeters. Experimentally, the only long-term patency achieved with conduits of this calibre has been when an optimal bio-potential has been maintained either by incorporating a stainless steel wire carrying a current within the small wall or specifically inducing a static potential. In the first instance, the current itself will eventually prove destructive, while the second type of conduit does prove to be functional. However, long-term patency at this calibre is defined as exceeding 21 days (26), which is still clinically unacceptable.

The function of 3 millimeter diameter grafts constructed of common fabric materials can be measured in minutes rather than hours or days, and thus our polyurethane foam conduits did function within expected experimental limits.

The concept of a tapered graft also is quite valid and lends itself extremely well to the aorto-coronary position. Flow through a tapered graft can be anticipated to exceed that through a similar length of uniform diameter conduit, as the tapered graft effectively removes the length resistance factor from the equation of flow. The smaller distal diameter also facilitates anastomosis to a smaller calibre artery such as the coronaries.

Generally, however, from our experimental series it may be concluded that fabric grafts of the three or four millimeter internal diameter calibre are not acceptable replacements for small calibre arteries.

CONCLUSIONS

1. The most ideal replacement for a small calibre artery segment is a similar sized autogenous arterial conduit.
2. Autogenous venous segments, although functional replacements for small calibre arteries, undergo structural changes which may prove detrimental to function.
3. At this stage in their development, fabric grafts cannot be considered as adequate replacements for small calibre arteries.

REFERENCES

1. CARREL, A. and GUTHRIE, C.C.: Uniterminal and biterminal venous transplantation. *Surg. Gynec. Obstet.* 2: 266, 1906.
2. SCHLOSS, G. and SHUMACKER, H.: Studies in vascular repair. *Yale J. Biol. Med.* 22: 273, 1950.
3. CARREL, A. and GUTHRIE, C.: Results of the biterminal transplantation of veins. *Amer. J. Med. Sci.* 132: 415, 1906.
4. GOODMAN, C.: A histological study of the circular suture of the blood vessels. *Ann. Surg.* 65: 693, 1917.
5. CREECH, O., DeBAKEY, M.E., SELFT, M. and HALPERT, B.: The fate of heterologous arterial grafts: an experimental study. *Surgery* 36: 431, 1954.
6. FOSTER, J.H., EKSMANN, C.A. and SCOTT, H.W.: Late behavior of vascular substitutes: three to five-year follow-up of arterial and synthetic prostheses in experimental animals. *Ann. Surg.* 151: 867, 1960.
7. GROSS, R.E.: Preliminary observation on the use of human arterial grafts in the treatment of certain cardiovascular defects. *New Eng. J. Med.* 239: 578, 1949.
8. CREECH, O., DeBAKEY, M., COLEY, D. and SELFT, M.: Preparation and use of freeze-dried arterial homografts. *Ann. Surg.* 140: 35, 1954.
9. HALPERT, B., DeBAKEY, M., JORDAN, G. and HENLY, W.: The fate of homografts and prostheses of the human aorta. *Surg. Gynec. Obstet.* 111: 659, 1960.
10. COPLEY: Discussion: Some desirable physical characteristics of prosthetic vascular grafts. In: *Biophysical Mechanisms in Vascular Homeostasis and Intravascular Thrombosis*. Edited by P.N. Sawyer, Appleton Century Crofts, New York, 1965. p. 335.
11. WESOLOWSKI, S., FRIES, C. and SAWYER, P.: Some desirable characteristics of prosthetic vascular grafts. In: *Biophysical Mechanisms in Vascular Homeostasis and Intravascular Thrombosis*. Edited by P.N. Sawyer, Appleton Century Crofts, New York, 1965, pp. 322.

12. LEININGER, R.: Surface effects in blood plastic compatibility. In: Biophysical Mechanisms in Vascular Homeostasis and Intravascular Thrombosis. Edited by P.N. Sawyer, Appleton Century Crofts, New York, 1965, pp. 288.
13. MASON, R.G.: The interaction of blood hemostatic elements with artificial surfaces. In: Progress in Hemostasis and Thrombosis. Edited by T. Spaet, Grune & Stratton, 1972. pp. 141.
14. LYMAN, D.: Biomedical polymers. Review of Macromolecular Chemistry 1: 355, 1966.
15. GOTT, V.: Causes and prevention of thrombosis on prosthetic materials. J. Surg. Res. 6: 274, 1966.
16. BRUCK, S.: Interactions of Materials with Blood. In: Blood Compatible Synthetic Polymers. Charles C. Thomas, Springfield, 1974. pp. 73.
17. MADRAO, P., MORTON, W. and RETSCHEK, H.: Dynamics of thrombus formation. Fed. Proc. 30: 1665, 1971.
18. FRIEDMAN, L., LIEM, H., GRABOWSKI, E., LEONARD, E. and McCORD, C.: Inconsequentiality of surface properties for initial platelet adhesion. Trans. Amer. Soc. Art. Int. Organs 16: 63, 1970.
19. GLAGOV, S.: Hemodynamic risk factors. In: Pathogenesis of Atherosclerosis. Edited by R.W. Wissler and J.C. Greer, Williams and Wilkins, 1972. pp. 164.
20. SAWYER, P.N. and PATE, J.: Electrical potential differences across the normal aorta and aortic grafts of dogs. Amer. J. Physiol. 175: 113, 1953.
21. GOLDSMITH, H.: Flow of model particles and blood cells and its relation to thrombogenesis. In: Progress in Hemostasis and Thrombosis. Edited by T. Spaet, Greene & Stratton, 1972. pp. 97.
22. SAWYER, P. and PATE, J.: Bioelectric phenomena as an etiologic factor in intravascular thrombosis. Amer. J. Physiol. 175: 103, 1953.
23. MIRKOVITCH, V.: Bioelectric phenomena, thrombosis and plastics: A review of current knowledge. Cleveland Clinic Quarterly 30: 241, 1963.
24. BRUCK, S.D.: Macromolecules. In: Blood Compatible Synthetic Polymers. Charles C. Thomas, Springfield, 1974. pp. 3.

25. TEORELL, T.: The role of electrical forces at cell boundaries. In: *Biophysical Mechanisms in Vascular Homeostasis and Intra-vascular Thrombosis*. Edited by P.N. Sawyer, Appleton Century Crofts, New York, 1965. pp. 19.
26. SHARP, W.V.: Electrolour: A new vascular interface. *Trans. Amer. Soc. Artif. Int. Organs* 14: 73, 1968.
27. TAYLOR, B., SHARP, W., WRIGHT, J.I., EWING, K.L. and WILSON, C.L.: The importance of zeta potential, ultra-structure and electrical conductivity to the *in vivo* performance of polyurethane-carbon black vascular prostheses. *Trans. Soc. Artif. Int. Organs* 17: 22, 1971.
28. EDMUIK, K., DAVIS, J. and MILLIGAN, H.: Streaming potential. An analysis of the Lest techniques and its application to the study of thrombosis on implant materials. *Thrombosis et Diathesis Haemorrhagica* 24: 286, 1970.
29. SHARP, W.: Latex vascular prostheses. *Circulation* 29 (Supl.): 16S, 1964.
30. SAWYER, P. and SCINIVASAN, D.: Studies on the biophysics of intra-vascular thrombosis. *Amer. J. Surg.* 114: 42, 1967.
31. LYMAN, D., MUIR, W. and LEE, S.: The effect of chemical structure and surface properties on the coagulation of blood: Surface free energy effects. *Trans. Amer. Soc. Artif. Int. Organs* 11: 301, 1965.
32. BAIER, R., LOEB, G. and WALLACE, G.: Role of an artificial boundary in modifying blood proteins. *Fed. Proc.* 30: 1523, 1971.
33. RODMAN, N.F. and MASON, R.: Blood-foreign surface interface. *Thrombosis et Diathesis Haemorrhagica* 42 (Supl.): 61, 1970.
34. LYMAN, D., KLEIN, K., BRASH, J. and FRITZINGER, B.: The interaction of platelets with polymer surfaces. *Thrombosis et Diathesis Haemorrhagica* 23: 120, 1970.
35. VROMAN, L. and ADAMS, A.: Identification of rapid changes at plasma-solid interfaces. *J. Biomed. Materials Res.* 3: 43, 1969.
36. BRASH, J. and LYMAN, D.: Adsorption of plasma proteins in solution to uncharged, hydrophobic polymer surfaces. *J. Biomed. Materials Res.* 3: 175, 1969.
37. VROMAN, L., ADAMS, A. and KLINGS, M.: Interactions among human blood proteins at interfaces. *Fed. Soc.* 30: 1494, 1971.

38. SALZMAN, E.: Role of platelets in blood-surface interactions. Fed. Proc. 30: 1503, 1971.
39. SCARBOROUGH, D., MASON, R., DALLDORF, F. and BRINKHOUS, K.: Morphologic manifestations of blood-solid interfacial reactions. Lab. Invest. 20: 164, 1969.
40. VOORHEES, A., JARETZKI, A. and BLAKEMORE, A.: The use of tubes constructed from 'Vinyon-N' cloth in bridging arterial defects. Ann. Surg. 135: 332, 1952.
41. WESOLOWSKI, S.: Porosity: Primary determinant of ultimate fate of synthetic vascular grafts. Surgery 50: 91, 1961.
42. BERGER, K., SAUVAGE, L., RAO, A. and WOOD, S.: Healing of arterial prostheses in man: Its incompleteness. Ann. Surg. 175: 118, 1972.
43. BRAIS, M. and BRAUNWALD, N.: Tissue acceptance of materials implanted within the circulatory system. Arch. Surg. 109: 351, 1974.
44. TAKEBAYASKI, J., KAMATONI, M., NAMBA, G., KATAYAMI, Y., and HAYASKI, K.: Early reparative process of implanted arterial prosthesis: A morphological and hematological study. J. Surg. Res. 17: 102, 1974.
45. DeBAKEY, M., JORDAN, G., ABBOT, J., HALPERT, B., and O'NEAL, R.: The fate of dacron vascular grafts. Arch. Surg. 89: 757, 1964.
46. GILLMAN, T. and WRIGHT, L.: Autoradiographic evidence suggesting *in vivo* transformation of some blood mononuclears in repair and fibrosis. Nature 209: 1086, 1966.
47. O'NEAL, R., GEORGE, J., RABIN, E., DeBAKEY, M. and HALPERT, B.: Cells grown on isolated intravascular dacron hubs: An electron microscopic study. Exper. Molec. Path. 3: 403, 1964.
48. SAUVAGE, S., BERGER, K., WOOD, S., YATES, S., SMITH, J. and MANSFIELD, P.: Interspecies healing of porous arterial prostheses. Arch. Surg. 109: 697, 1974.
49. WESOLOWSKI, S., FRIES, C., HENNIGAR, G., FOX, L., SAWYER, R. and SAUVAGE, L.: Factors contributing to long-term failures in human vascular prosthetic grafts. J. Cardiovasc. Surg. 5: 544, 1964.
50. EDWARDS, W.: Progress in synthetic graft development: An improved crimped graft of Teflon. Surgery 45: 298, 1959.