

**University of Alberta**

**Pain and MRI findings in the thoracic region and their association**

by

*Eija Riikka Niemeläinen* ©

A thesis submitted to the Faculty of Graduate Studies and Research

in partial fulfillment of the requirements for the degree of

Doctor of Philosophy

in

Rehabilitation Science

Faculty of Rehabilitation Medicine

Edmonton, Alberta

Fall 2008



Library and  
Archives Canada

Published Heritage  
Branch

395 Wellington Street  
Ottawa ON K1A 0N4  
Canada

Bibliothèque et  
Archives Canada

Direction du  
Patrimoine de l'édition

395, rue Wellington  
Ottawa ON K1A 0N4  
Canada

*Your file    Votre référence*  
*ISBN: 978-0-494-46398-7*  
*Our file    Notre référence*  
*ISBN: 978-0-494-46398-7*

**NOTICE:**

The author has granted a non-exclusive license allowing Library and Archives Canada to reproduce, publish, archive, preserve, conserve, communicate to the public by telecommunication or on the Internet, loan, distribute and sell theses worldwide, for commercial or non-commercial purposes, in microform, paper, electronic and/or any other formats.

The author retains copyright ownership and moral rights in this thesis. Neither the thesis nor substantial extracts from it may be printed or otherwise reproduced without the author's permission.

**AVIS:**

L'auteur a accordé une licence non exclusive permettant à la Bibliothèque et Archives Canada de reproduire, publier, archiver, sauvegarder, conserver, transmettre au public par télécommunication ou par l'Internet, prêter, distribuer et vendre des thèses partout dans le monde, à des fins commerciales ou autres, sur support microforme, papier, électronique et/ou autres formats.

L'auteur conserve la propriété du droit d'auteur et des droits moraux qui protègent cette thèse. Ni la thèse ni des extraits substantiels de celle-ci ne doivent être imprimés ou autrement reproduits sans son autorisation.

---

In compliance with the Canadian Privacy Act some supporting forms may have been removed from this thesis.

Conformément à la loi canadienne sur la protection de la vie privée, quelques formulaires secondaires ont été enlevés de cette thèse.

While these forms may be included in the document page count, their removal does not represent any loss of content from the thesis.

Bien que ces formulaires aient inclus dans la pagination, il n'y aura aucun contenu manquant.

■ ■ ■  
**Canada**

## **DEDICATION**

This work is dedicated to my family who has always provided me with love and support during my undergraduate and graduate studies.

## ABSTRACT

Research on imaging findings and pain has focused on cervical and lumbar regions, while relatively little is known of the thoracic region. The goal of this thesis was to examine the prevalence of upper or mid-back pain and MRI findings of the thoracic region and their association to one another in a large population-based sample. Such knowledge is of value as a reference for clinical observations, as well as for gaining insights into the pathogenesis of disc degeneration.

Structured, in-depth interview data on upper or mid-back pain reporting and qualitative MRI assessments of disc degeneration (T6-T12) were already available for 600 Finnish men from a pre-existing dataset. Added to these were quantitative MRI measurements of disc degeneration using manual tissue segmentation and custom-made image analysis software. The MRI findings investigated included disc height narrowing, signal and bulging, osteophytes, endplate irregularities, Scheuermann's disease, and vertebral deformities and hemangiomas. Also, a new method was developed and used to perform quantitative measurements of thoracic disc signal, reflecting disc dehydration.

During the prior year, upper or mid-back pain, which rarely occurred in individuals without reports of neck and low-back pain, was reported by 17% of subjects with a mean intensity score of 38/100. Of these subjects, 23.1% reported associated difficulties in performing normal activities. Thoracic MRI 'degenerative' findings were assessed to be mostly mild when present; only disc height narrowing and endplate irregularities were ever rated as severe. Bulging and osteophytes occurred more often anteriorly than posteriorly and the prevalence of most findings varied by level, being more common in the lowest thoracic levels. The greatest association with age existed for disc signal. Several MRI

findings were associated with a history of severe upper or mid-back pain in crude analyses after controlling for age, but only quantitatively-measured posterior osteophytes entered the multivariable model. Only anterior bulging was associated with pain frequency.

In summary, upper or mid-back pain is common in men, with severe pain modestly associated with thoracic MRI findings, including posterior osteophytes in particular.

## ACKNOWLEDGEMENTS

“Excellence is not a singular act, but a habit. You are what you repeatedly do.” With these words from Shaquille O’Neill I would like to express my sincere gratitude towards my advisors, Dr. Tapio Videman and Dr. Michele C. Battiè, who taught me to strive for the best. Their endless guidance and support were keys to the completion of this work. I can only wish to reach the same passion they have for their work. This PhD work would not have been possible without access to the Twin Spine Study data which they provided me and for which I am highly grateful. Participation in the Alberta CIHR Provincial Training Program in Bone and Joint Health offered me a valuable addition to the PhD program through exposure to other trainees and their work and the possibility to attend international conferences to present my work.

I would also like to thank Dr. Kevin Gill for his help with the MR images, Dr. Laura Gibbons for her patience with my statistical questions and Brad Sinclair with the programming of SpEx<sup>®</sup>. The members of my supervisory committee, Dr. Douglas Gross, Dr. Sukhvinder Dhillon and Dr. Keith Bagnall, provided me with constructive comments and advice throughout the program and were highly appreciated.

I’m extremely grateful for the financial support of the Helsingin Sanomat Centennial Foundation, the Alberta CIHR Provincial Training Program in Bone and Joint Health, the European Union (Eurodisc), the Faculty of Rehabilitation Medicine and the Finnish Konkordia Fund. This financial support allowed me to devote my full attention to my doctoral studies.

Lastly I’d like to express my sincere gratitude to many dear friends who were always there for me and made this path even more worth taking.

## TABLE OF CONTENTS

<b>CHAPTER 1 INTRODUCTION AND OBJECTIVES</b>	<b>1</b>
REFERENCES	4
<b>CHAPTER 2 REVIEW OF LITERATURE</b>	<b>7</b>
<b>THE THORACIC REGION OF THE SPINE</b>	<b>7</b>
Overview of development and anatomy of the thoracic region	7
Embryology and development	7
Anatomy	8
Bony structures	8
Intervertebral disc	12
<b>IMAGING OF THE SPINE</b>	<b>16</b>
MRI –the method of choice for soft tissue imaging	17
An overview of the principles of MRI	17
Strengths and limitations	18
<b>IMAGING FINDINGS OF THE THORACIC REGION</b>	<b>21</b>
The prevalence of imaging findings	21
Association of degenerative findings with age	34
Association of degenerative findings with one another	35
<b>UPPER OR MID-BACK PAIN</b>	<b>36</b>
The epidemiology of upper or mid-back pain	36
The sensation of pain	39
Pain receptors in spinal tissues	40
Different pain types	41
Primary pain	41
Immunological irritation	41
Inflammatory irritation	41
Chemical irritation	41
Secondary pain	42
Mechanical irritation	42
Reflex pain	42
Referred pain	42
Biological factors and pain	43
Psychosocial factors and pain	44
<b>ASSOCIATION BETWEEN IMAGING FINDINGS AND BACK PAIN</b>	<b>45</b>
<b>CONCLUSION</b>	<b>48</b>
<b>REFERENCES</b>	<b>50</b>

<b>CHAPTER 3 STUDY SUBJECTS AND THORACIC MRI VARIABLES</b>	<b>68</b>
SUBJECT CHARACTERISTICS AND REPRESENTATIVENESS	68
DATA ACQUISITION FROM THE MR IMAGES	69
The reliability of the quantitative measurements and qualitative assessments	74
REFERENCES	76
<b>CHAPTER 4 PREVALENCE AND CHARACTERISTICS OF UPPER OR MID-BACK PAIN IN FINNISH MEN</b>	<b>78</b>
INTRODUCTION	78
METHODS	79
RESULTS	81
DISCUSSION	83
REFERENCES	86
<b>CHAPTER 5 QUANTITATIVE MEASUREMENT OF INTERVERTEBRAL DISC SIGNAL USING MRI</b>	<b>88</b>
INTRODUCTION	88
METHODS	89
RESULTS	91
DISCUSSION	92
REFERENCES	95
<b>CHAPTER 6 THE PREVALENCE AND CHARACTERISTICS OF THORACIC MRI FINDINGS IN MEN</b>	<b>96</b>
INTRODUCTION	96
METHODS	97
RESULTS	102
DISCUSSION	106
REFERENCES	111
<b>CHAPTER 7 ASSOCIATION BETWEEN THORACIC MRI FINDINGS AND SYMPTOMS IN MEN</b>	<b>114</b>
INTRODUCTION	114
METHODS	115
RESULTS	118
DISCUSSION	121
REFERENCES	124



<b>CHAPTER 8 GENERAL DISCUSSION AND CONCLUSIONS</b>	<b>127</b>
OVERVIEW	127
UPPER OR MID-BACK PAIN	127
Key findings	127
Discussion	128
MRI FINDINGS OF THE THORACIC REGION	129
Key findings	129
Discussion	130
ASSOCIATIONS OF MRI FINDINGS OF THE THORACIC REGION AND UP- PER OR MID- BACK PAIN	136
Key findings	136
Discussion	136
METHODOLOGICAL CONSIDERATIONS	139
Study design	139
Validity issues	139
CONCLUSIONS	141
DIRECTIONS FOR FUTURE RESEARCH	142
Methodological implications for related research	142
Other implications for future research	144
REFERENCES	146
<b>APPENDIX A: MRI FINDINGS AND THEIR DEFINITIONS ACCORDING TO THE NOMENCLATURE AND CLASSIFICATION OF DISC PATHOLOGY</b>	<b>156</b>
<b>APPENDIX B: EMBRYOLOGY AND DEVELOPMENT OF THE SPINE</b>	<b>158</b>
<b>APPENDIX C: THE ONE-YEAR PREVALENCE OF BACK AND NECK PAIN IN OCCUPATIONAL GROUPS</b>	<b>161</b>
<b>APPENDIX D: INNERVATION AND NEURAL ANATOMY OF THE THO- RACIC REGION</b>	<b>165</b>
<b>APPENDIX E: DICTIONARY</b>	<b>168</b>

## LIST OF TABLES

<b>Table 2-1</b>	The prevalence of thoracic disc degeneration in the literature.	22
<b>Table 2-2</b>	The one-year prevalence of back pain in general population and general workforce samples.	37
<b>Table 2-3</b>	The characteristics of back and neck pain in occupational groups.	38
<b>Table 2-4</b>	The association between MRI findings and 12-month LBP.	47
<b>Table 3-1</b>	Grading scale for qualitative assessments of the thoracic MRI findings.	74
<b>Table 3-2</b>	Reliability of the measurements.	74
<b>Table 4-1</b>	A comparison of pain characteristics for subjects' neck, upper or mid-back and low-back pain.	82
<b>Table 4-2</b>	Methodologically similar studies to the current study reporting the one-year prevalence of self-reported back pain in the general population.	84
<b>Table 5-1</b>	Correlations between signal intensities of the clear cerebrospinal fluid (CSF) samples and spinal cord.	92
<b>Table 5-2</b>	Correlations between disc signal intensity and age without adjustment and with adjustment using cerebrospinal fluid (CSF) and spinal cord.	92
<b>Table 6-1</b>	Grading scale for qualitative assessments of thoracic disc degeneration with intraobserver reliability from a sample of twenty subjects.	99
<b>Table 6-2</b>	The prevalence of MRI findings based on qualitative assessments.	104
<b>Table 6-3</b>	Correlations of different MRI findings for T7-T8 and T11-T12, adjusted for age.	110
<b>Table 7-1</b>	The prevalence of upper or mid-back pain in frequency categorization.	118
<b>Table 7-2</b>	Subject characteristics and possible confounding factors.	119
<b>Table 7-3</b>	The means and standard deviations (SD) for the MRI findings using the mean score and the highest score to denote the level of degeneration.	120

## LIST OF FIGURES

<b>Figure 2-1</b> Different views on the thoracic vertebrae highlighting the segmental changes from T1 to T12 in size and structure.	10
<b>Figure 2-2</b> The regions of the thoracic spine with their characteristic features and biomechanical implications.	12
<b>Figure 2-3</b> Determinants of pain.	45
<b>Figure 3-1</b> The manual segmentation process.	71
<b>Figure 3-2</b> The acquisition of mean disc height, osteophyte and disc bulging measurements.	72
<b>Figure 3-3</b> Semiquantitative visual grading of vertebral deformities.	73
<b>Figure 4-1</b> Frequency and severity of upper or mid-back pain over the previous 12 months (n=102).	81
<b>Figure 5-1</b> Cord and CSF reference samples were acquired at the adjacent levels to the disc.	90
<b>Figure 6-1</b> Example segmentation and disc height, osteophyte and bulging measurements.	100
<b>Figure 6-2</b> Quantitative mean disc height by level (n=403-524).	103
<b>Figure 6-3</b> The prevalence of anterior and posterior quantitative disc bulging by level with the mean bulging distance (n=409-524).	105
<b>Figure A-1</b> Cross-section of the thorax with a distribution of a nerve at one level after exiting the spinal cord.	165

## ACRONYMS AND ABBREVIATIONS

**Annulus** =Annulus fibrosus

**Cohort** =Finnish Twin Cohort

**CSF** =Cerebrospinal fluid

**CT** =Computed tomography

**Disc** =Intervertebral disc

**DZ** =Dizygotic

**LBP** =Low-back pain

**MRI** =Magnetic resonance imaging

**MZ** =Monozygotic

**Nucleus** =Nucleus pulposus

**PD** =proton-density

**SE** =Spin echo

**TE** =Time to echo

**TR** =Time to repetition

**TSS** =Twin Spine Study

## CHAPTER 1: INTRODUCTION AND OBJECTIVES

Back and neck pain are common problems affecting almost everyone sometime in life. They cause disability, affect the quality of life<sup>1</sup> and have substantial economic consequences.<sup>2,3</sup> Epidemiological studies on back and neck pain and related imaging findings have focused on the lumbar and cervical regions because upper or mid-back pain is less common. Nevertheless, the occurrence of upper or mid-back pain is substantial<sup>4</sup> and deserves further examination.

The structures in the thoracic region differ significantly from the adjacent regions and require separate analysis rather than simple extrapolation of results and conclusions from other regions. For example, facet joint alignment, vertebral anthropometrics and the presence of the ribs may all have implications on the frequency and characteristics of pain and degenerative findings. To date, population-based studies of degenerative findings of the thoracic region are scarce and the studies available differ enormously in sample selection (patients,<sup>5-10</sup> asymptomatic subjects,<sup>11-13</sup> convenience samples of patients,<sup>14-17</sup> workers<sup>18-20</sup> and cadavers<sup>21-29</sup>), in imaging methods (plain radiographs,<sup>18-21,23,25,26,29</sup> magnetic resonance imaging,<sup>5,12,14,16,17,30-33</sup> computed tomography,<sup>6,10</sup> discography<sup>13,21</sup> and anatomical investigations<sup>21,22,24,25</sup>) and in outcome definitions used making comparisons between studies very difficult.

Magnetic resonance imaging (MRI) has become the method of choice for spine imaging because of its superior soft tissue contrast<sup>34-39</sup> and ability to evaluate the intervertebral disc both structurally and biochemically.<sup>40-43</sup> Data on the variations of thoracic MRI findings in the general population would be of value for comparative purposes in clinical practice. Additionally, knowledge of the association between pain and imaging findings would provide the background necessary to evaluate the clinical importance of MRI findings.<sup>44</sup> The association between MRI findings and pain in the thoracic region has previously been investigated in patients.<sup>38</sup> However, there were several methodological shortcomings of the study, such as a small sample size and whether or not the assessor was blinded to the pain status of the subjects, which may have affected the assessments.

To enhance research and interventions related to thoracic problems it is essential to know which thoracic MRI findings, if any, are associated with pain.

The paucity of knowledge of MRI findings of the thoracic region, upper or mid-back pain and their association in the general population led to commencing this investigation. In contrast to the previous studies, this study used a large and representative population-based sample of men with data on pain history and suspected risk factors through interviews and thoracic MR images.

### **THESIS OBJECTIVES**

- The overall purpose of this thesis was to describe the prevalence and characteristics of upper or mid-back pain and MRI findings of the thoracic region, and to examine their association to one another in a general population of men. The following chapters will address these topics and introduce a new method to measure thoracic disc signal quantitatively. First, the topic of this thesis will be introduced by critically reviewing the related literature (Chapter 2), and describing the subject acquisition, representativeness of the sample and the data collection procedures (Chapter 3). Then, the primary objectives of the research will be addressed, including:

- To examine the one-year prevalence, severity and frequency of upper or mid-back pain and to compare them with neck and low-back pain. Specific objectives were: 1) determine the one-year prevalence and characteristics of upper or mid-back pain in Finnish men, 2) compare the one-year prevalence and characteristics of upper or mid-back pain with neck and low-back pain within the same sample, and 3) determine the association between upper or mid-back pain and neck and low-back pain. (Chapter 4.)

- To investigate the methodological challenges of quantitatively measuring thoracic disc signal by examining the reliability and validity of using the spinal cord as an alternative intra-body reference. The reliability was investigated through repeated measurements of spinal cord signal with the expectation of excellent agreement. The validity of using the spinal cord as an alternative reference was believed to be supported if: 1) the spinal cord signal correlated highly with the signal from clear CSF samples (the criterion reference), and 2) the spinal cord-adjusted disc signal correlated with age, at least as highly as

CSF-adjusted disc signal, while the correlation of non-adjusted disc signal with age was lower. (Chapter 5.)

- To examine the prevalence and characteristics of MRI findings of the thoracic region. The specific objectives were to: 1) describe the prevalence of selected types of thoracic MRI findings by spinal level, including T6 through T12, and 2) determine the association of these findings with age and one another. The purpose of this investigation was to expand on the sample size from a previous investigation of a sub-sample of subjects from this thesis<sup>33</sup> and the types of findings assessed both qualitatively and quantitatively. (Chapter 6.)

- To examine the association between upper or mid-back pain and MRI findings while controlling for possible behavioural and environmental confounding factors. It was theorized that the highest score for degeneration present would be associated with a greater likelihood of severe pain, whereas the mean score for degeneration would be associated with the frequency of pain. It was also expected that disc height narrowing would be associated with upper or mid-back pain based on its association with low-back pain. (Chapter 7.)

- The thesis will conclude with a summary and discussion of the main findings and recommendations for future investigations. (Chapter 8.)

## REFERENCES

1. Crook J, Rideout E, Browne G. The prevalence of pain complaints in a general population. *Pain*. 1984;18(3):299-314.
2. van Tulder MW, Koes BW, Bouter LM. A cost-of-illness study of back pain in the Netherlands. *Pain*. 1995;62(2):233-240.
3. Ekman M, Johnell O, Lidgren L. The economic cost of low back pain in Sweden in 2001. *Acta Orthop*. 2005;76(2):275-284.
4. Cromie JE, Robertson VJ, Best MO. Work-related musculoskeletal disorders and the culture of physical therapy. *Phys Ther*. 2002;82(5):459-472.
5. Girard CJ, Schweitzer ME, Morrison WB, Parellada JA, Carrino JA. Thoracic spine disc-related abnormalities: Longitudinal MR imaging assessment. *Skeletal Radiol*. 2004;33(4):216-222.
6. Awwad EE, Martin DS, Smith KR, Jr, Baker BK. Asymptomatic versus symptomatic herniated thoracic discs: Their frequency and characteristics as detected by computed tomography after myelography. *Neurosurgery*. 1991;28(2):180-186.
7. Mann T, Oviatt SK, Wilson D, Nelson D, Orwoll ES. Vertebral deformity in men. *J Bone Miner Res*. 1992;7(11):1259-1265.
8. O'Neill TW, McCloskey EV, Kanis JA, et al. The distribution, determinants, and clinical correlates of vertebral osteophytosis: A population based survey. *J Rheumatol*. 1999;26(4):842-848.
9. Lauridsen KN, De Carvalho A, Andersen AH. Degree of vertebral wedging of the dorso-lumbar spine. *Acta Radiol Diagn (Stockh)*. 1984;25(1):29-32.
10. Ryan RW, Lally JF, Kozic Z. Asymptomatic calcified herniated thoracic disks: CT recognition. *AJNR Am J Neuroradiol*. 1988;9(2):363-366.
11. Wood KB, Blair JM, Aepple DM, et al. The natural history of asymptomatic thoracic disc herniations. *Spine*. 1997;22(5):525-529.
12. Wood KB, Garvey TA, Gundry C, Heithoff KB. Magnetic resonance imaging of the thoracic spine. Evaluation of asymptomatic individuals. *J Bone Joint Surg Am*. 1995;77-A(11):1631-1638.
13. Wood KB, Schellhas KP, Garvey TA, Aeppli D. Thoracic discography in healthy individuals. A controlled prospective study of magnetic resonance imaging and discography in asymptomatic and symptomatic individuals. *Spine*. 1999;24(15):1548-1555.
14. Goh S, Tan C, Price RI, et al. Influence of age and gender on thoracic vertebral body shape and disc degeneration: An MR investigation of 169 cases. *J Anat*. 2000;197(4):647-657.
15. Tan CIC, Song S, Edmondston SJ, Singer KP. Patterns of thoracic disc degeneration from MRI: Age, gender and spinal level influences. *JMR*. 2001;5(4):269-278.
16. Goh S, Price RI, Song S, Davis S, Singer KP. Magnetic resonance-based vertebral morphometry of the thoracic spine: Age, gender and level-specific influences. *Clin Biomech (Bristol, Avon)*. 2000;15(6):417-425.



17. Williams MP, Cherryman GR, Husband JE. Significance of thoracic disc herniation demonstrated by MR imaging. *J Comput Assist Tomogr.* 1989;13(2):211-214.
18. Hult L. Cervical, dorsal and lumbar spinal syndromes; a field investigation of a non-selected material of 1200 workers in different occupations with special reference to disc degeneration and so-called muscular rheumatism. *Acta Orthop Scand Suppl.* 1954;17:1-102.
19. Hult L. The Munkfors investigation; a study of the frequency and causes of the stiff neck-brachialgia and lumbago-sciatica syndromes, as well as observations on certain signs and symptoms from the dorsal spine and the joints of the extremities in industrial and forest workers. *Acta Orthop Scand Suppl.* 1954;16:1-76.
20. Lawrence JS, Molyneux MK, Dingwall-Fordyce I. Rheumatism in foundry workers. *Br J Ind Med.* 1966;23(1):42-52.
21. Malmivaara A. *Thoracolumbar Junctional Region of the Spine. An Anatomical and Radiological Study.* [PhD]. Medical Faculty of the University of Helsinki; 1987.
22. Hilton RC, Ball J, Benn RT. Annular tears in the dorsolumbar spine. *Ann Rheum Dis.* 1980;39( 6):533-538.
23. Hilton RC, Ball J, Benn RT. Vertebral end-plate lesions (Schmorl's nodes) in the dorsolumbar spine. *Ann Rheum Dis.* 1976;35( 2):127-132.
24. Saluja G, Fitzpatrick K, Bruce M, Cross J. Schmorl's nodes (intravertebral herniations of intervertebral disc tissue) in two historic British populations. *J Anat.* 1986;145:87-96.
25. Silberstein M, Opeskin K, Fahey V. Spinal Schmorl's nodes: Sagittal sectional imaging and pathological examination. *Australas Radiol.* 1999;43(1):27-30.
26. Pfirrmann CW, Resnick D. Schmorl nodes of the thoracic and lumbar spine: Radiographic-pathologic study of prevalence, characterization, and correlation with degenerative changes of 1,650 spinal levels in 100 cadavers. *Radiology.* 2001;219(2):368-374.
27. Nathan H. Osteophytes of the vertebral column. An anatomical study of their development according to age, race, and sex with consideration as to their etiology and significance. *J Bone Joint Surg Am.* 1962;44-A:243-268.
28. Shore LR. On osteo-arthritis in the dorsal intervertebral joints. A study in morbid anatomy. *Br J Surg.* 1935;22(88):833-849.
29. Chanchairujira K, Chung CB, Kim JY, et al. Intervertebral disk calcification of the spine in an elderly population: Radiographic prevalence, location, and distribution and correlation with spinal degeneration. *Radiology.* 2004;230(2):499-503.
30. Arana E, Marti-Bonmati L, Dosda R, Molla E. Concomitant lower thoracic spine disc disease in lumbar spine MR imaging studies. *Eur Radiol.* 2002;12(11):2794-2798.
31. Arana E, Marti-Bonmati L, Molla E, Costa S. Upper thoracic-spine disc degeneration in patients with cervical pain. *Skeletal Radiol.* 2004;33(1):29-33.
32. Baranto A, Hellstrom M, Nyman R, Lundin O, Sward L. Back pain and degenerative abnormalities in the spine of young elite divers: A 5-year follow-up magnetic resonance imaging study. *Knee Surg Sports Traumatol Arthrosc.* 2006;14(9):907-914.

33. Videman T, Battie MC, Gill K, Manninen H, Gibbons LE, Fisher LD. Magnetic resonance imaging findings and their relationships in the thoracic and lumbar spine. Insights into the etiopathogenesis of spinal degeneration. *Spine*. 1995;20(8):928-935.
34. Malfair D, Beall DP. Imaging the degenerative diseases of the lumbar spine. *Magn Reson Imaging Clin N Am*. 2007;15(2):221-238.
35. Ross JS, Perez-Reyes N, Masaryk TJ, Bohlman H, Modic MT. Thoracic disk herniation: MR imaging. *Radiology*. 1987;165(2):511-515.
36. Berns DH, Blaser SI, Modic MT. Magnetic resonance imaging of the spine. *Clin Orthop Relat Res*. 1989;244:78-100.
37. Saal JS. General principles of diagnostic testing as related to painful lumbar spine disorders: A critical appraisal of current diagnostic techniques. *Spine*. 2002;27(22):2538-2545.
38. Bruckner FE, Greco A, Leung AW. 'Benign thoracic pain' syndrome: Role of magnetic resonance imaging in the detection and localization of thoracic disc disease. *J R Soc Med*. 1989;82(2):81-83.
39. Jarvik JG, Deyo RA. Diagnostic evaluation of low back pain with emphasis on imaging. *Ann Intern Med*. 2002;137(7):586-597.
40. Herzog RJ. The role of magnetic resonance imaging in the assessment of disk degeneration and diskogenic pain. In: Weinstein JN, Gordon SL, eds. *Low Back Pain. A Scientific and Clinical Overview*. 1st ed. Rosemont, Illinois: American Academy of Orthopaedic Surgeons; 1996:385-405.
41. Terti M, Paajanen H, Laato M, Aho H, Komu M, Kormanen M. Disc degeneration in magnetic resonance imaging. A comparative biochemical, histologic, and radiologic study in cadaver spines. *Spine*. 1991;16(6):629-634.
42. Benneker LM, Heini PF, Anderson SE, Alini M, Ito K. Correlation of radiographic and MRI parameters to morphological and biochemical assessment of intervertebral disc degeneration. *Eur Spine J*. 2005;14(1):27-35.
43. Weidenbaum M, Foster RJ, Best BA, et al. Correlating magnetic resonance imaging with the biochemical content of the normal human intervertebral disc. *J Orthop Res*. 1992;10(4):552-561.
44. Borenstein DG, O'Mara JW Jr, Boden SD, et al. The value of magnetic resonance imaging of the lumbar spine to predict low-back pain in asymptomatic subjects: A seven-year follow-up study. *J Bone Joint Surg Am*. 2001;83-A(9):1306-1311.

## **CHAPTER 2 REVIEW OF LITERATURE**

This purpose of this chapter is to provide background for subsequent discussion of degenerative findings<sup>a</sup> of the thoracic region and upper or mid-back pain. Firstly, the anatomy and development of the thoracic region will be described. Secondly, imaging of the spine will be reviewed with an emphasis on MRI. Thirdly, the current state of knowledge with regard to degenerative findings of the thoracic region will be reviewed, followed by a description of upper or mid-back pain and possible mechanisms. Lastly, the associations between imaging findings and pain will be reviewed.

### **THE THORACIC REGION OF THE SPINE**

This section will offer an overview of the development and anatomy of the thoracic region, which is the longest region of the spine with anatomical and biomechanical features that make it substantially different from cervical and lumbar regions. Due to the focus of this work, only intervertebral discs and vertebrae including their connections with the ribs and facet joints are included. The review of the structure and function is directed toward the differences, if any, by level and by region.

#### **Overview of development and anatomy of the thoracic region**

##### *Embryology and development*

Most of the vertebral column (vertebrae, endplates and annulus fibrosus) develops from mesoderm, but the nucleus pulposus, which is a remnant of notochord, derives from endoderm.<sup>1</sup> The development of the vertebral column starts around the 4<sup>th</sup> week of development when somites start to appear in the region of the head.<sup>2</sup> The medial parts of the somites further become differentiated into sclerotomes, which are the precursors of the vertebra.<sup>1</sup> The development of the vertebra continues with the chondrification, which starts in the 5<sup>th</sup> week followed by the ossification in the 8<sup>th</sup> week of development. The ossification does not follow the craniocaudal trend as does the formation of somites but

---

<sup>a</sup> The term disc degeneration will be used to describe the intervertebral disc with structural variations (Appendix A).

varies depending on the ossification centre. Vertebral centra ossifies first in the lowest thoracic and upper lumbar levels and then progressively at adjacent caudal and cranial levels.<sup>3,4</sup> Neural arches, on the other hand, show no exact pattern but ossify first in the cervicothoracic levels followed by upper cervical, mid-thoracic and thoracolumbar levels from where the ossification extends cranially and caudally.<sup>4</sup> The longitudinal growth of the vertebral body occurs at the thick cartilage on the cranial and caudal surface of the vertebral body and periosteal ossification is responsible for the horizontal growth.<sup>2</sup> The development of intervertebral disc is closely associated to that of vertebral bodies and takes place by notochordal enlargement (nucleus pulposus) and cellular arrangement that eventually leads to the formation of collagen fibres (annulus fibrosus).<sup>2,5</sup> (Appendix B.)

### *Anatomy*

In fetus, the vertebral column has only one continuous anterior concavity but the secondary curvatures (lordosis) develop as a result of the stresses of sitting and standing.<sup>6,7</sup> Hence, the upright spine is characterized by four curvatures; lordotic or convex anteriorly in cervical and lumbar regions, and kyphotic or concave anteriorly in thoracic and sacro-coccygeal regions. The curvature of the thoracic region (kyphosis) causes the line of gravity to pass ventral to the vertebral bodies during standing.<sup>8</sup> A kyphosis ranging between 20° and 40° is considered normal but the values depend on age and gender; older age and female gender are associated with more pronounced kyphosis.<sup>9</sup> The wedging of both vertebral bodies and intervertebral discs contribute to the kyphosis<sup>10-12</sup> but the relative contributions remain unclear. The progression of thoracic kyphosis with aging occurs in two ways; senile kyphosis, which is mainly due to degeneration of the intervertebral discs, and osteoporotic kyphosis, which is caused by the collapse of the thoracic vertebral body resulting in wedging.<sup>13</sup>

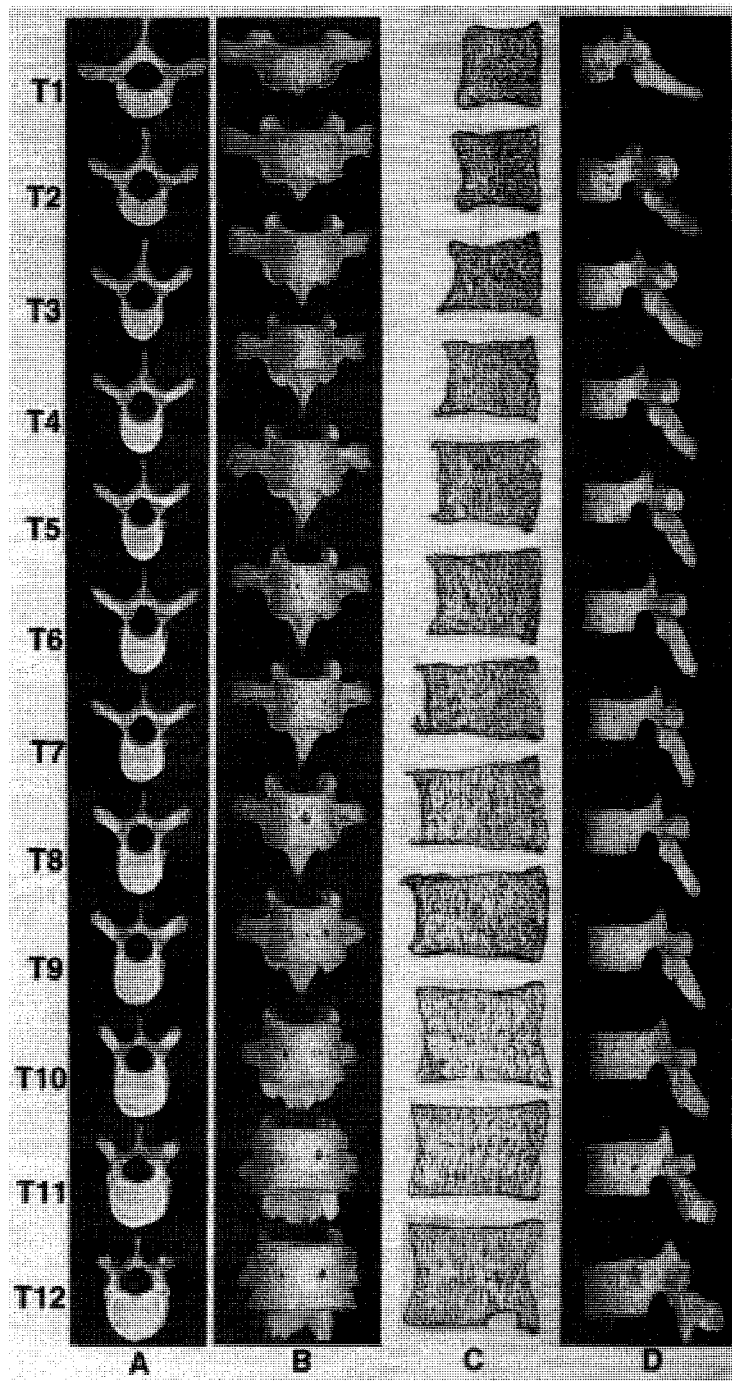
### Bony structures.

The twelve *thoracic vertebrae*, made of a trabecular bone surrounded by a shell of cortical bone,<sup>2</sup> consist of the body ventrally and the arch dorsally.<sup>7</sup> The primary function of the vertebrae is to withstand and distribute the forces encountered during everyday routine activities while protecting the spinal cord and roots of the spinal nerves.<sup>8,14</sup> The axial loads due to body weight in the thoracic region have been estimated to increase from ap-

proximately 9% of the body weight at T1 to 47% at T12.<sup>15</sup> The majority of this weight is transmitted by the vertebral bodies (anterior part of the vertebral column) and as an adaptation, the size, height and bone mass of the vertebral bodies, as well as the endplate cross-sectional area, increase caudally.<sup>7,14,16</sup> (Figure 2-1.)

Based on the anatomy of the thoracic vertebrae *three distinct regions* can be identified; upper (T1-T4), middle (T5-T9) and lower (T10-T12).<sup>16</sup> The upper region, the transition zone between the cervical and thoracic region, is characterized by narrowing of the endplates and spinal canal lateral width while the anterior-posterior depth remains relatively unchanged.<sup>16</sup> In the middle region, which is also called the “critical vascular zone” for the spinal cord<sup>17</sup> because it has the least profuse blood supply,<sup>16</sup> the spinal canal is at its narrowest while the dimensions of the endplates show a slight linear increase from the upper region. In the lower region (thoracolumbar junction) the area of the endplates continues to increase and the spinal canal begins to enlarge again.<sup>16</sup> (Figure 2-2.)

One of the *characteristic features of thoracic vertebrae* is the facets for articulation with the head and tubercles of the first to tenth ribs.<sup>18</sup> All the thoracic vertebrae, except the last three, articulate with two ribs. The costovertebral articulation joins the bodies of two neighbouring vertebrae with the disc via a ligament (one articulation is present at the 1<sup>st</sup>, 11<sup>th</sup> and 12<sup>th</sup> rib), and the costotransverse articulation unites the transverse processes with the rib tubercles (except the 11<sup>th</sup> and 12<sup>th</sup> ribs). Anteriorly the ribs articulate with the sternum; the upper seven are true ribs because of their direct articulation to the sternum and the lower five are false ribs, indirectly joining the sternum (8<sup>th</sup>-10<sup>th</sup> rib) or not at all (11<sup>th</sup>-12<sup>th</sup> rib).<sup>7</sup>



**Figure 2-1.** Different views on the thoracic vertebrae highlighting the segmental changes from T1 to T12 in size and structure.<sup>14</sup> (Reprinted with permission from Elsevier Ltd.)

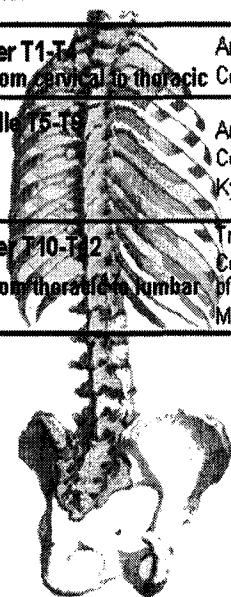
The orientation of the *facet joints*, which are formed by the articulation of the articular processes of two vertebrae,<sup>2</sup> changes caudally from coronal to sagittal.<sup>7,14</sup> The cor-

onal orientation of the thoracic facet joints offers substantial resistance to anterior translation while the sagittal orientation of the lumbar region limits more rotation and has almost no effect on anterior translation.<sup>19</sup> The change in orientation can happen either suddenly at one joint or gradually over more than one joint<sup>20-22</sup> but most commonly it occurs at the T11 and T12 vertebrae.<sup>20,22,23</sup> A second characteristic feature of the lower thoracic region is the presence of a (carpenter's) 'mortice joint', which is formed by the projection of the mamillary process behind the inferior articular process. The presence of mortice joints may mark the junction of two functionally different regions<sup>24</sup> since they are most commonly seen at T11-12<sup>23,24</sup> where the orientation of the facet joints usually changes.

*These regional differences*, particularly in the facet joint geometry, have implications on the regional range of motion. For example, axial rotation is greatest in the middle thoracic levels<sup>25,26</sup> where the facet joints project posteriorly and do not provide resistance to axial rotation. Also, the presence of the ribcage (ribs and their joints)<sup>18,19,27</sup> and the attachments of the ribs to the vertebral bodies and discs by the ligaments<sup>28</sup> contribute to the resistance of the movements in the thoracic region. Hence, the range of motion in the sagittal and coronal planes (flexion-extension and lateral flexion) increases caudally.<sup>25</sup> (Figure 2-3.)

With advancing age the human skeleton develops both "*atrophic and hypertrophic changes*".<sup>29</sup> Atrophic changes include bone atrophy (loss), which predisposes the vertebrae to fractures.<sup>29</sup> The peak bone density is achieved early in life and diminishes with age.<sup>30</sup> The detection of bone loss from the vertebral bodies may be masked by the concomitant hypertrophic changes.<sup>31</sup> Bone loss may lead to osteoporosis characterized by reduced bone mineral mass and defined as a bone mineral density of more than 2.5 standard deviations below that of young adults,<sup>32</sup> and to vertebral deformities. At a tissue level, bone undergoes constant remodeling and a negative balance between resorption and formation is the basic mechanism for bone loss.<sup>33</sup>

Region	Characteristic features	Biomechanical factors
Upper T1-T4 Transition zone from cervical to thoracic	Articulation of ribs to sternum Coronal orientation of facet joints	Decreased flexion-extension and rotation
Middle T5-T9	Articulation of ribs to sternum Coronal orientation of facet joints Kyphosis	Greater compressive forces anteriorly Increased axial rotation in locomotion Decreased flexion-extension
Lower T10-T12 Transition zone from thoracic to lumbar	True and floating ribs Coronal and sagittal orientation of facet joints Mortice joints	Increased flexion-extension Increased lateral flexion Decreased axial rotation



**Figure 2-2.** The regions of the thoracic spine with their characteristic features and biomechanical implications.

Hypertrophic changes, on the other hand, consist of osteophyte formation. The development of osteophytes can be seen as an adaptation to physical activity<sup>34</sup> or as an attempt to restrict the instability caused by “temporary dysfunction”, such as degeneration of the intervertebral disc.<sup>35</sup> However, the exact cause of osteophytes still remains unknown.<sup>36</sup> Osteophytes also occur in the joints between the vertebral bodies and the ribs, and at the facet joints<sup>23,37,38</sup> where they may be of clinical importance due to the possibility of narrowing the intervertebral foramen where the spinal nerves exit the spinal cord.

#### Intervertebral disc.

The intervertebral disc (simply referred to as disc from here on) is a fibrocartilaginous structure forming an articulation between two vertebrae. A young, healthy disc consists of two macroscopically-distinct regions; the nucleus pulposus (nucleus), a semigelatinous fibrocartilaginous structure, and the annulus fibrosus (annulus), which consists of a series of concentric collagenous and fibrocartilaginous lamellae surrounding the nucleus<sup>7,39</sup> and attaches to the outer edges of the adjacent vertebral bodies by its outer fibres.<sup>40,41</sup> Lastly,



the two endplates, which are the interface between disc and vertebra, are comprised of cartilage.<sup>2,39,42</sup> While some consider endplates to be part of the same functional unit with the disc,<sup>43</sup> others debate whether endplates are a part of the disc or the respective vertebral bodies.<sup>2</sup> In this work endplates will be discussed with the disc due to their importance for the function and nutrition of the disc.

The morphology and function of the disc greatly depend on the organization and properties of *extracellular matrix*. Extracellular matrix is responsible for the biomechanical properties of the disc and regulates the composition of the extracellular fluid and the rate of nutrient and metabolite exchange between the disc cells and the rest of the body.<sup>39,44</sup> The matrix consists of a complex and highly-hydrated network of macromolecules<sup>45</sup> whose composition varies in different regions of the disc<sup>39,44,46</sup> and is briefly outlined below.

The *nucleus* consists mainly of water, which may make up to 90% of the content of a nucleus in an infant, but also of macromolecules, such as collagen and aggrecan.<sup>47</sup> Aggrecan is the major proteoglycan of the disc<sup>44,47</sup> and responsible for maintaining the hydration of the disc.<sup>44</sup> The main collagen type in the nucleus is type II,<sup>48,49</sup> also seen in the inner annulus,<sup>49</sup> and several other collagens, such as types III, VI and IX.<sup>49,50</sup> The fibrillar collagen network and aggregating proteoglycans form a mesh suited for containing the water molecules and are all important for the nucleus's function to resist compressive forces.<sup>47</sup> In addition, nucleus also contains some highly-organized elastic fibres made of elastin, which may contribute to maintaining its structure,<sup>48</sup> and small quantities of other non-collagenous proteins whose functional role is not yet clear.<sup>44,51</sup>

The *annulus*, on the other hand, consists of a series of 15-25 concentric layers, or lamellae,<sup>41</sup> of collagen fibres (mostly type I, but also types II, III, V, VI and IX).<sup>49,50</sup> Proteoglycan gel and elastin bind the collagen fibres and the lamellae together contributing to the strength of the structures and recovery after deformation.<sup>48-50</sup> The orientation of the fibres gives the annulus great strength and ability to withstand forces applied to it from any direction.<sup>52</sup> Having both types of collagen (I and II) present allows the annulus to withstand tension- and pressure-related processes as compared to nucleus.<sup>53</sup> The differences between the annulus and nucleus exist in the higher relative concentrations of water and proteoglycans in the nucleus<sup>51</sup>, the type of collagen which predominates in each

structure,<sup>49,50</sup> and in the higher total collagen content and the quantity of elastic fibres in annulus than in nucleus.<sup>46,47</sup>

Similar to the annulus and nucleus, the third region of the disc, the *endplates*, consist of proteoglycans, collagens and water, but also a layer of cartilage (hyaline cartilage and fibrocartilage).<sup>40,52,54</sup> The main collagen types in the endplates; types II and IX (important for normal skeletal development and longevity of adult cartilage<sup>55</sup>) decrease with advancing degeneration.<sup>49,50</sup> The thinnest region, with more proteoglycans and water, is centrally over nucleus to allow the diffusion of nutrients.<sup>54,56,57</sup>

The disc is surrounded anteriorly and posteriorly by longitudinal ligaments, which are made of a mixture of collagen types I, III, V and VI.<sup>49,50</sup> The anterior longitudinal ligament is narrower and thicker in the thoracic region than in the adjacent cervical and lumbar regions and does not directly attach to the discs but only to the vertebral bodies. Conversely, the posterior longitudinal ligament is wider over discs than over vertebral bodies and is attached to the discs.<sup>2,42,58</sup>

The *main function* of the disc is to allow movement between vertebral bodies, to transmit loads from one vertebral body to another<sup>2,42,44,52</sup> and to act as a shock absorber.<sup>39,40,52</sup> Endplates function to resist the pressure due to compression and transmit loads from one vertebra to another.<sup>2</sup> Endplates also act as a growth zone for immature vertebral bodies.<sup>43</sup> The disc structures are interdependent<sup>52</sup> and any disturbance of the integrity and interplay of one of these structures can result in compromised function of the disc.<sup>59</sup>

The *regional differences in the discs* include a change both in the shape and size from cervical to lumbar region, almost in a linear fashion following the increase in the body weight acting on the discs and the increase in the vertebral body size.<sup>60</sup> The caudal increase in the width of annulus is likely due to an increase in the number of distinct layers of laminae rather than an increase in the thickness of individual layer.<sup>41</sup> Further, the annulus is of equal thickness in the discs of the thoracic region as compared to the discs of the lumbar region where it is thicker anteriorly than posteriorly<sup>58</sup> with no difference in the fibre orientation.<sup>60</sup> The circular cross-sectional area of the annulus of the thoracic discs enables its function to resist compression and torsion by distributing the stresses evenly around the annulus.<sup>61</sup> The differences in the composition of the discs between cer-

vical, thoracic and lumbar regions of the spine have been accounted to the differences in the function of discs in those regions. It is unclear whether a difference in the collagen content (% of the dry weight) of annulus exists between the thoracic and lumbar discs since both a caudal increase from T12-L1 to L5-S1<sup>53</sup> and no difference<sup>62</sup> between thoracic and lumbar discs have been reported, with the smallest collagen content in the cervical discs.<sup>62</sup> Similarly, the observed caudal increase in the water and proteoglycan contents seems compatible with the increase in the compressive forces acting on the discs.<sup>62</sup>

Similar to vertebral bodies, discs also undergo changes with advancing age. *Disc degeneration*, which includes both age-related and pathological alterations of the disc, is poorly understood and therefore hard to define. A recent review on disc degeneration defined it as being “an aberrant, cell-mediated response to progressive structural failure where a degenerate disc would be the one with structural failure combined with accelerated or advanced signs of aging”.<sup>63</sup> The macromolecules of the disc are synthesized and maintained by a small number of cells that make up only approximately 1% of the total volume of the disc<sup>64</sup> being almost three times less than in an articular cartilage of the knee joint.<sup>65</sup> Because of the avascularity of the disc, the cells in the centre of an adult disc can be as far as 6-8 mm from the nearest blood supply and require adequate nutrition supply; glucose to remain viable and also oxygen to function, and efficient removal of metabolism by-products, such as lactate.<sup>66,67</sup> The disturbance of the steady state between the rates of synthesis and degradation of matrix leads to impaired maintenance of the integrity of the disc’s vast extracellular matrix resulting in impaired function.<sup>39,66-68</sup>

Even though the mechanism of disc degeneration is still somewhat unknown, it is known that the first clear signs of degeneration in the lumbar discs are seen in the age group of 11-16 years.<sup>59</sup> From there on, the degeneration progresses as a part of the normal aging process, leading to gradual transformation of the biochemical composition and organization of the disc<sup>69</sup> including the loss of proteoglycans<sup>70</sup> and the change in collagen population, of which the first is more pronounced.<sup>44,49,50</sup> Biologic changes are more pronounced in the nucleus<sup>71-73</sup> and gross structural changes most evident in the annulus and endplates.<sup>72,74,75</sup> By the age of 50 years, autopsies have shown that almost all discs

have some disc degeneration with most of the discs representing at least macroscopic degeneration in the nucleus and annular fissuring.<sup>76</sup>

Of the *temporal course of disc degeneration*, Boos et al.<sup>59</sup> have concluded that endplate alterations precede those of the nucleus and the outer annulus is not profoundly affected until in late adulthood. High variability, however, existed within and across the anatomic regions. Ideally, the temporal course of disc degeneration should be examined longitudinally to eliminate the large variations between subjects by age. However, cross-sectional studies of disc degeneration are commonly used because of the higher cost, methodological and measurement challenges with repeat measurements, and time-consuming nature of follow-up studies.

## **IMAGING OF THE SPINE**

Plain radiography, computed tomography (CT) and MRI are the most commonly used imaging methods in the primary care setting.<sup>77,78</sup>

*Plain radiographs* offer data on bony alignment, deformity and the general state of spine degeneration.<sup>79</sup> The strengths of radiography are low cost and ready availability<sup>77</sup> but the downside is the use of harmful radiation. The standard radiographic investigation consists of lateral and anteroposterior plain films.<sup>77,80</sup> These views can be used to demonstrate alignment, disc and vertebral body height, and to perform a gross assessment of bone density and architecture. Radiographs cannot directly visualize soft tissues, such as discs. Hence, radiographs are insensitive to herniations, can only detect compromise of the vertebral canal by bone and cannot visualize nerve roots.<sup>77</sup> Axial images, as are available with either CT or MRI, also are not possible with plain radiography.<sup>81</sup>

*CT* on the other hand uses x-rays to create cross-sectional images of the spine, but the acquisition of sagittal or coronal plane images requires reformations from the axial or off-axial images.<sup>77</sup> Additionally, CT is routinely performed only on few levels, such as on the three lowest lumbar levels, and therefore, can miss unsuspected pathology in the adjacent levels.<sup>82</sup> The strength of CT is the superior spatial resolution and imaging of osseous and calcified structures<sup>81</sup> and is the preferred method to examine bony abnormalities, such as fractures, and to assess bony central and lateral stenosis.<sup>77,78</sup> Both plain radiogra-

phy<sup>83</sup> and CT<sup>81</sup> are of little value in demonstrating soft tissue abnormalities until late manifestations of disc degeneration are present, however CT technology is developing fast.

The ethically-acceptable method for studies of population samples is *MRI*<sup>84</sup> because of its non-invasiveness and lack of ionizing radiation.<sup>78,85</sup> MRI also offers several additional advantages over CT for imaging disc degeneration/spine and, therefore, is the modality of choice. Firstly, no known biologic risks for the use of MRI currently exists.<sup>73</sup> Secondly, it offers superior soft tissue contrast<sup>77,79,81,86-88</sup> which allows distinguishing parts of the disc from one another (for example, the nucleus and the annulus) and visualization of ligaments, vertebral marrow, and the contents of the spinal canal. Thirdly, it can obtain sagittal and axial images directly without having to rely on reformatted axial images<sup>77</sup> and lastly, it can be used to obtain images of the entire spine as opposed to only few levels in CT.<sup>82</sup> Because of these advantages of MRI over other imaging modalities and because of its ability to evaluate the disc both structurally and biochemically<sup>73,89-91</sup> it has become the method of choice for studying spinal disorders.<sup>92,93</sup> These aspects will be discussed in more detail later.

### **MRI –the method of choice for soft tissue imaging**

#### *An overview of the principles of MRI*

MRI is based principally upon the sensitivity to the presence and properties of water which makes up to 90% of the tissues.<sup>94</sup> The presence of the mobile protons is the basis of MR imaging.<sup>77</sup> Radio-waves (radiofrequency pulse) are used to excite the mobile protons.<sup>77</sup> This phenomenon of protons picking up energy from the radio-waves is called resonance. As a consequence of gaining extra energy, the protons can align themselves opposite to the magnetic field.<sup>95</sup> When the protons relax back to the lower energy state (align themselves parallel to the magnetic field) they release energy which is the signal used to create an image. The amount of energy (i.e., signal) depends on several factors, including relaxation times specific to the tissues (T1 and T2).<sup>77</sup> The signal from each anatomic structure varies as a function of the morphology and the hydration of the tissue and scanner settings<sup>96</sup> and tissues have different signal intensities (brightness) on MRI.<sup>94</sup>

Spin echo is one of the most common sequences used in MRI because it generally produces the best quality images, but the image acquisition time is relatively long.<sup>94</sup> It starts with a 90° pulse from the direction of the main magnetic field which pushes the magnetization to the transverse plane. TR is the repetition time (time between successive 90° pulses) and TE is the time from the 90° pulse to the echo (the signal coming back from the patient). By manipulating the TR and TE times it is possible to produce T1-, T2- or PD- (proton density) weighted images.

T1-weighted imaging usually has an excellent contrast, with fluids being dark and fat-based tissues bright.<sup>94,96</sup> T2-weighted imaging has a lower signal-to-noise ratio than the other two image weightings and provides a high contrast between tissues containing a lot of fluid.<sup>96</sup> PD-weighting is the intermediate weighting, having an excellent signal-to-noise ratio and high clarity<sup>96</sup> and can be taken at the same time as T2-weighted imaging using another echo at shorter TE.<sup>94</sup> However, all sequences provide different information on the spinal structures and the selection of the sequences should be done with this in mind. The most commonly used sequence in MR imaging of disc degeneration is T2-weighted imaging, which will be discussed more in-depth next.

#### *Strengths and limitations*

MRI, which is based on the proton density, water content, and chemical environment of the protons,<sup>97</sup> can detect dehydration, the basic biochemical phenomenon in disc degeneration, as a loss of signal intensity on T2-weighted images. This has been shown in several cadaver studies using both qualitative and quantitative assessments of disc signal from T2-weighted images and biochemical analyses of the discs.<sup>89-91</sup> Due to the importance of disc signal as a degenerative parameter, the value of reliable and valid measurements of disc signal cannot be emphasized enough.

Commonly *disc signal* is assessed together with other findings, such as disc height narrowing, using qualitative assessments. Qualitative assessments require making subjective decisions about the brightness of the disc and the of the assessments is not ideal.<sup>98</sup> Quantitative measurements are preferred because of their better reliability and the ability to detect smaller changes in the signal<sup>99</sup> but the measurements are complicated by the magnetic field inhomogeneity. Because of the magnetic field inhomogeneity, the sig-

nal is not homogeneous from one point in the image to another affecting the signal measurements by introducing measurement error. The effect of magnetic field inhomogeneity, and other factors that possibly affect the signal measurements, can be reduced by using a proximal intra-body reference as a signal reference.<sup>100,101</sup> Prior to this doctoral work no studies with quantitative thoracic disc signal measurements existed. Cerebrospinal fluid (CSF) has been used for this purpose in the lumbar region,<sup>99,101-103</sup> but several factors, such as movement of CSF in the thecal sac and paucity of CSF for reference, may hamper the clinical utility of CSF as an internal reference in the thoracic region.<sup>104,105</sup>

In addition to the biochemical evaluation of the disc, MRI can also perform valid visualizations of the morphological state of the disc. Several commonly assessed degenerative MRI findings, such as *disc signal*, *bulging/herniation* and *osteophytes*, have correlated with the morphological degree of disc degeneration from macroanatomical dissections from cadavers as assessed using commonly accepted qualitative assessments. Similarly, using x-ray, *disc height loss*, *osteophytes* and *intradiscal calcification* have been associated with the morphological degree of disc degeneration, whereas *Schmorl's nodes*, *endplate sclerosis* and *endplate shape* have not. However, neither x-ray nor MRI were able to separate between all morphological degrees<sup>90</sup> but this may be due to the subjective nature of the visual assessments. The actual assessments play a crucial role in the reliability and validity of the data, but this is common to all imaging modalities and not unique to MRI.

*Contraindications* for MRI use include the presence of any mobile ferromagnetic implant in the orbit, skull or spinal canal, and the presence of a cardiac pacemaker, intracranial clips or claustrophobia.<sup>96</sup> A disadvantage of MRI is the lack of direct visualization of cortical bone. Cortical bone does not have mobile protons and in MRI it produces a black "signal void".<sup>77,82</sup> Scoliosis which has been defined as lateral deviation of the normal vertical line of the spine greater than 10 degrees in imaging<sup>106</sup> can make the detection and localization of different findings difficult<sup>107,108</sup> especially in the sagittal images.

A number of *artefacts* can also adversely affect MRI. An artefact is any feature in an image that misrepresents the objects in the field of view. The artefacts can be broadly divided into three groups: motion, inhomogeneity and digital imaging artefacts.<sup>94</sup> In spine

imaging the most troublesome ones result from patient motion; gross movement, swallowing, respirations, cardiac contractions and CSF pulsations.<sup>87</sup> Motion can cause erroneously increased or decreased signal intensity, occurring in the phase-encoding direction and leading to blurring or ghosting of the structures.<sup>109,110</sup>

*Chemical shift*, another common artefact, is a displacement of signal along the frequency-encoding direction. A gradient, a coil of wire, alters the magnetic field strength in a linear fashion and causes a frequency change along the axis which is used to locate each signal.<sup>110</sup> This is the basis for understanding chemical shift. Due to the difference caused by the dissimilar chemical environments of protons for example, in fat and water, the proton in fat resonates at a lower frequency than in water and hence, a frequency shift between fat and water occurs. In other words, where water and fat coexists in the subject, the difference in the frequency between those two molecules causes them to be misplaced in the frequency-encoding direction and appear in different pixels in the image causing a signal void between the two areas.<sup>110</sup> The extent of the chemical shift depends on several factors, but can be reduced by lower magnetic field strength and reduced receiver bandwidth. However, a more recommended option is to use either fat- or water-suppressed imaging.<sup>110</sup>

*Partial volume averaging* can also distort image and occurs when two structures with different signal intensities are included within the same voxel (pixel).<sup>94</sup> This leads to averaging of signal intensity within that particular voxel<sup>111</sup> and results in erroneous voxel values. This may further lead to misinterpretations of the image. Both chemical shift and partial volume averaging can complicate the assessment of MRI. The bigger the voxel size the larger the problem with partial volume averaging. The larger voxel may contain several different structures with different signal intensities and as a result of the averaging of the signal intensities of the structures the borders of the structures may appear unclear.

In addition to CT, *MRI techniques are developing fast* and currently several MR-based techniques are available to provide functional information of the patient's spine. For example, the measurements of the direction and magnitude of water diffusion can be used to examine the structure of the spinal tissues and the rate at which intravenous contrast medium diffuses into the disc can be measured to provide a measure of disc's glyco-



saminoglycan structure. Due to the improvements in MR imaging speed, dynamic imaging of the spine has become available providing information on the structures of the spine when subjected to loading and movements. Dynamic imaging can be used to detect disc herniations that, in theory, would only occur with the patient upright and to measure the changes in the dimensions of neural foramen and spinal canal when under axial load or different movements<sup>112,113</sup> and has recently been used for those purposes in the cervical and lumbar regions.<sup>114,115</sup> The continuous development of MRI allows improved and new tools for the researchers to investigate and could enhance the current understanding of the spine problems.

## **IMAGING FINDINGS OF THE THORACIC REGION**

This section will include a review of the prevalence of imaging findings separately for disc-related findings (disc bulging, disc signal, disc height narrowing, osteophytes, annular tears, disc herniation and Schmorl's nodes including endplate irregularities) and other pathology, such as vertebral deformities, hemangiomas, and Scheuermann's disease. Also, the associations of imaging findings to age and one another will be reviewed.

### **The prevalence of imaging findings**

Knowledge of the prevalence of imaging findings in the general population would be useful in the clinical setting for related observations in patients. Yet, several challenges for determining the prevalence of thoracic imaging findings from related research exist. These involve the use of varying subjects selected with and without knowledge of the presence or absence of pain, different definitions for outcomes, and failing to report prevalence rates by spinal level, which is suggested because of the variation in the prevalence rates among levels.<sup>116</sup> These variations greatly complicate comparisons between studies and contribute to the wide variations in the reported prevalence rates. To understand the prevalence of the distinct findings associated with disc degeneration they should be reported separately. (Table 2-1.)

**Table 2-1.** The prevalence of thoracic disc degeneration in the literature (% of the discs unless otherwise noted).

Authors	N	Sample (♂/♀)	Method	Case definition	Prevalence
<b>DISC HERNIATIONS</b>					
Girard 2004 <sup>117</sup>	40	Patients (12/28)	MRI	Nomenclature definition; <sup>118</sup> "disc-related abnormalities"	10%
Videman 1995 <sup>119</sup>	232	Population-based (men)	MRI	A focal disc protrusion; "findings"	By level (T6-T12): mild in 0%-0.4%
Wood 1995 <sup>120</sup>	90	Asymptomatic (49/41)	MRI	A focal protrusion or extrusion; "abnormal anatomical finding"	6% (♀ 32% / ♂ 41%)
Awwad 1991 <sup>121</sup>	433	Patients	CT	Not provided	9.2% of the subjects
Williams 1989 <sup>85</sup>	48	Oncology patients (19/29)	MRI	Not provided	14.6% of the subjects
Wood 1999 <sup>95</sup>	10	Asymptomatic (4/6)	MRI	Modified Dallas Disc Morphology Scheme; <sup>122</sup> "morphologic abnormalities"	20%
Arana 2002 <sup>123</sup>	150	LBP or radiculopathy (77/73)	MRI	Normal, protrusion (incl. bulge), extrusion; "thoracic spine disc disease"	T11-12 & T12-L1 protrusion / extrusion 21.3% / 2.7% & 12.7% / 0.7%
Arana 2004 <sup>124</sup>	156	Neck pain (77/83)	MRI	Normal, protrusion (incl. bulge), extrusion; "thoracic-spine disc degeneration"	T1-2, T2-3 & T3-4 protrusion / extrusion 9% / 0%, 9.6% / 0.6% and 1.9% / 0%
Ryan 1988 <sup>125</sup>	270	With scans of thorax	CT	A focal disc protrusion	1.5% of the patients
<b>DISC BULGING</b>					
Videman 1995 <sup>119</sup>	232	Population-based (men)	MRI	The extent of bulging; "findings"	By level (T6-T12) mild-to-severe 11.2%-46.1% / 0.2%-19.2% / 0%-1.9%
Wood 1995 <sup>120</sup>	90	Asymptomatic (49/41)	MRI	A diffuse extension of disc material beyond the vertebral confines; "abnormal anatomical finding"	8% (♀ 39% / ♂ 65%)
Baranto 2006 <sup>126</sup>	18	Elite divers 10-21 yrs (6/14)	MRI	Convex extension of the disc beyond the cortex of the vertebrae; "degenerative abnormalities"	From T6 to T12 only at T11-T12: 5.5%

Authors	N	Sample (♂/♀)	Method	Case definition	Prevalence
<b>SPINAL CORD DEFORMATION</b>					
Wood 1995 <sup>120</sup>	90	Asymptomatic (49/41)	MRI	Deformed by impingement of disc material; "abnormal anatomical finding"	5% (♀ 12% / ♂ 43%)
Arana 2004 <sup>124</sup>	156	Neck pain (77/83)	MRI	Compression of neural structures by disc contour changes (T1-T4); "thoracic-spine disc degeneration"	33.3% of the changes
<b>DISC HEIGHT NARROWING</b>					
Videman 1995 <sup>119</sup>	232	Population-based (men)	MRI	Compared to the upper disc; "findings"	By level (T6-T12) mild-to-severe 4.7%-9.1% / 0.2%-6.7% / 0%-0.4%
Baranto 2006 <sup>126</sup>	18	Elite divers 10-21 yrs (6/14)	MRI	Normal; reduction <50% (compared to one above and below); reduction 50%-90%; reduction >90%; "degenerative abnormalities"	By level (T6-T12) mild-to-severe: 0%-16.7%
<b>DISC SIGNAL INTENSITY</b>					
Videman 1995 <sup>119</sup>	232	Population-based (men)	MRI	Nucleus signal near to 1) nerves and spinal cord, 2) vertebral body, 3) not seen in dark disc; "findings"	By level (T6-T12) mild-to-severe 15.3%-56.2% / 31.9%-48.3% / 9.5%-19.4%
Goh 2000 <sup>127</sup>	169	Patients (81/88)	MRI	1) bright; 2) horizontal dark bands across the annulus centrally, signal intensity diminished; 3) proportion of grey, signal reduced, gross loss of disc height; "disc degeneration"	♀ / ♂ Grade 2 & 3# T1-4: 32% / 36% and 1.5% / 2% T5-8: 34% / 39% and 23% / 18% T9-12: 58% / 47% and 15% / 27%
Baranto 2006 <sup>126</sup>	18	Elite divers 10-21 yrs (6/14)	MRI	Nucleus signal near to 1) nerves and spinal cord, 2) vertebral body, 3) not seen in dark disc; "degenerative abnormalities"	By level (T6-T12) mild-to-severe: 5.5%-22.2%
<b>DISC DEGENERATION</b>					
Girard 2004 <sup>117</sup>	40	Patients (12/28)	MRI	Desiccation of nucleus pulposus or disc narrowing with or without marginal osteophytosis; "disc-related abnormalities"	14%
Wood 1995 <sup>120</sup>	90	Asymptomatic (49/41)	MRI	Loss of disc height and signal intensity; "abnormal anatomical finding"	♀ 46% / ♂ 63%

Authors	N	Sample (♂/♀)	Method	Case definition	Prevalence
<b>DISC DEGENERATION continued</b>					
Hult 1954 <sup>28</sup>	1200	Workers	X-ray	Vertebral margin osteophytes with or without disc height narrowing; "disc degeneration"	64.7% of the subjects
Lawrence 1963 <sup>1,29</sup>	444	Random sample of 15-75+ yrs	X-ray	Disc height narrowing, osteophytes, wear of anterior corners of the vertebral bodies and sclerosis of the endplates; "disc degeneration"	♀ / ♂ slight-to-severe 73% / 56%
Lawrence 1966 <sup>1,30</sup>	299	Male workers	X-ray	Grading 0 to 4; "disc degeneration" and "radiological findings"	Grade 2-4: 80% of the subjects
Malmivaara 1987 <sup>23</sup>	37	Male cadavers	X-ray, pathologic	The extent of contrast medium spread into annulus (0=normal, 6=severe); "anatomical and pathological findings"	Moderate-to-severe T10-11, T11-12 & T12-L1: 33%, 35% and 17%
<b>ANNULAR TEARS</b>					
Wood 1995 <sup>120</sup>	90	Asymptomatic (49/41)	MRI	The extent of high-intensity material extending to annulus; "abnormal anatomical finding"	12% (♀ 54% / ♂ 61%)
Wood 1999 <sup>93</sup>	10	Asymptomatic (4/6)	Discography	0) normal, 1) inner one-third fissure, 2) inner and middle one-third tear, 3) full-thickness tear; "morphologic abnormalities"	Grade 1-3: 22.5% / 10% / 22.5%
Malmivaara 1987 <sup>23</sup>	37	Male cadavers	Discography	0) normal, 2) extension into the inner border of annulus, 4) extension into the outer portion of the annulus, 6) extension beyond the confines of the outer annulus, "anatomical and pathological findings"	Partial tears for T10-11, T11-12 & T12-L1 35%, 14% and 6% Full tears 8%, 0% and 0%
Hilton 1980 <sup>131</sup>	117	Cadavers (65/52)	Anatomic	Minor=tears to inner annulus, major=tears to outer annulus and possibly to the common ligament	Tears at T10-L1 in 51.3% of the subjects
Goh 2000 <sup>127</sup>	169	Patients (81/88)	MRI	1) homogeneous, 2) areas of increased signal intensity, indistinguishable from nucleus, 3) bright and dark signals contiguous with nucleus and annulus; "disc degeneration"	♀ / ♂ Grade 2 and 3# T1-4: 8% / 14% and - / 0.5% T5-8: 23% / 29% and 6% / 7% T9-12: 28% / 29% and 5% / 11%

Authors	N	Sample (♂/♀)	Method	Case definition	Prevalence
<b>DISC CALCIFICATION</b>					
Chanchairujira 2004 <sup>132</sup>	223	Cadavers (183/40)	X-ray	Not provided	T1-T5, T5-T9 & T9-L1: 8% / 17% / 60%
<b>SCHMORL'S NODES</b>					
Girard 2004 <sup>117</sup>	40	Patients (12/28)	MRI	A focal indentation of the endplate contiguous with the disc; "disc-related abnormalities"	9.6%
Baranto 2006 <sup>126</sup>	18	Elite divers 10-21 yrs (6/14)	MRI	Intraspongious disc herniation, grade 0 to 3; "degenerative abnormalities"	By level (T6-L1) mild-to-severe: 0%-16.7%
Arana 2002 <sup>123</sup>	150	LBP or radiculopathy (77/73)	MRI	Transphyseal disc extension; "thoracic spine disc disease"	T11-12 & T12-L1: 14.7% & 7.3%
Malmivaara 1987 <sup>23</sup>	37	Male cadavers	Pathologic	Mean area of the nodes $\geq 0.8$ cm <sup>2</sup> ; "anatomical and pathological findings"	T10-11, T11-12 & T12-L1: 25%, 30% and 5%*
Saluja 1986 <sup>133</sup>	77	Historic populations: Aberdeen (18/6) and London (28/25)	Anatomic	Presence or absence	Of the subjects (T8-T12)* A: ♀ 32% / ♂ 45% and L: ♀ 3% / ♂ 25%
Silberstein 1999 <sup>134</sup>	70	Cadavers (52/18)	X-ray, pathologic	Presence	T8-9, T9-10, T10-11 & T11-12 52.9% / 40% / 48.5% / 38.5%
Pfirrmann 2001 <sup>135</sup>	100	Cadavers	X-ray	A focal indentation of the vertebral endplate	T1-5, T6-9 & T10-12: 2%, 18% & 30%*
Hilton 1976 <sup>136</sup>	50	Cadavers (33/17)	X-ray	A discontinuity in the cartilaginous part of the vertebral end-plate with a translucency in the adjacent vertebral body	♀/♂ T10-11: 41% / 65%, T11-12: 53% / 61%, T12-L1: 35% / 48%
<b>ENDPLATE IRREGULARITIES</b>					
Videman 1995 <sup>119</sup>	232	Population-based (men)	MRI	Schmorl's nodes and larger defects; "findings"	By level (T6-T12): upper & lower endplates: mild: 10.6%-38.4% & 3.0%-19.8% moderate: 10.8%-25.9% & 2.4%-6.5% severe: 0.2%-1.1% & 0.2%-0.6% ♀ / ♂ Grade 2 and 3#
Goh 2000 <sup>127</sup>	169	Patients (81/88)	MRI	1) single dark line, 2) increase in central concavity, line less distinct, 3) focal defects in line and areas of thickening; "disc degeneration"	T1-4: - T5-8: 4% / 8 % and 10% / 14% T9-12: 6% / 14% and 15% / 23%

Authors	N	Sample (♂/♀)	Method	Case definition	Prevalence
<b>SCHEUERMANN'S DISEASE</b>					
Wood 1995 <sup>120</sup>	90	Asymptomatic (49/41)	MRI	Endplate changes consistent with Scheuermann dystrophic spondylosis; "abnormal anatomical finding"	♀ 27% / ♂ 47%
Wood 1999 <sup>93</sup>	10	Asymptomatic (4/6)	MRI	Endplate changes or Schmorl's nodes consistent of Scheuermann's pathology; "morphologic abnormalities"	28%
Hult 1954 <sup>137</sup>	274	Male workers	X-ray	Wedging of the vertebrae	30% of the subjects
Dameron 1953 <sup>138</sup>	1000	Male draftees	X-ray	Wedging of the vertebrae ( $\leq 2$ ), increased antero-posterior diameter and endplate irregularity	6.1% of the subjects
Mann 1992 <sup>139</sup>	144	Men from hospitals	X-ray	Irregular vertebral endplate outlines, sclerotic deformities of the endplate and wedging; "vertebral deformity resulting from epiphysitis"	9.7% of the subjects
Scoles 1991 <sup>140</sup>	1384	Cadavers (984/400)	Anatomic	Three or more adjacent vertebrae wedged 5° or more <sup>141</sup>	7.4% of the subjects
Biering-Sorensen 1985 <sup>142</sup>	666	60-year-olds (360/306)	X-ray		9.7% and 3.3% of men and women
<b>MODIC CHANGES</b>					
Girard 2004 <sup>117</sup>	40	Patients (12/28)	MRI	According to Modic <sup>143</sup> ; "disc-related abnormalities"	Only Modic I in 2.3%
<b>OSTEOPHYTES</b>					
Videman 1995 <sup>119</sup>	232	Population-based (men)	MRI	The size of osteophytes; "findings"	By level (T6-T12) moderate/severe 1.3%-19.2% / 0-1.5%
Malmivaara 1987 <sup>23</sup>	37	Male cadavers	X-ray, pathologic	Increase in mean area of the interposing endplates $\geq 15\%$ ; "anatomical and pathological findings"	T10-11, T11-12 & T12-L1 40%, 45% and 23%
O'Neill 1999 <sup>144</sup>	1180	Population-based (499/681)	X-ray	Anterior osteophytes, grading 0 to 4; "vertebral osteophytosis"	Of the subjects; moderate-to-severe: ♀ 23.8% / ♂ 51.1%
Hult 1954 <sup>137</sup>	274	Male workers	X-ray	"disc degeneration"	Small/large in 51% / 24% of the subjects

Authors	N	Sample (♂/♀)	Method	Case definition	Prevalence
<b>OSTEOPHYTES continued</b>					
Nathan 1962 <sup>145</sup>	346	Cadavers (204/142)	Anatomic	Grading 0 to 4	Moderate-to-severe T1-T12* Anterior & posterior: 3%-60% / 0-7%
Goh 2000 <sup>127</sup>	169	Patients (81/88)	MRI	1) margins rounded, 2) tapering of margins, or small dark projections from margins <2 mm in size, 3) projections >2 mm with same intensity as marrow; "disc degeneration"	♀ / ♂ Grade 2 & 3# T1-4: 18% / 17% & 11% / 10% T5-8: 34% / 28% & 19% / 14% T9-12: 10% / 16% & 8% / 15%
<b>FACET JOINT OSTEOPHYTES</b>					
Shore 1935 <sup>38</sup>	126	Cadavers	Anatomic	Presence of facet joint osteophytes; "osteoarthritis"	By level (T1-T12): 10%-25%
Malmivaara 1987 <sup>23</sup>	37	Male cadavers	X-ray, pathologic	Grading 0 to 6; "anatomical and pathological findings"	T10-11, T11-12 & T12-L1 (slight-to-severe) 8%, 38% & 40%
<b>COSTOVERTEBRAL JOINT OSTEOPHYTES</b>					
Malmivaara 1987 <sup>23</sup>	37	Male cadavers	X-ray, pathologic	Grading 0 to 6; "anatomical and pathological findings"	T10-11, T11-12 & T12-L1 (slight-to-severe) 17%, 21% & 57%
Nathan 1964 <sup>37</sup>	346	Cadavers	Pathologic	Distinct lipping of the border or erosion of the articular surfaces; "arthritis"	T1-T12: 2% - 22%
<b>VERTEBRAL WEDGING</b>					
Lauridsen 1984 <sup>146</sup>	164	Oncology patients (68/96)	X-ray	Anterior / posterior ratio	95% confidence limits for men (ratio) T8-T12: 0.75-0.80
Goh 2000 <sup>127</sup>	169	Patients (81/88)	MRI	Anterior wedge index: Ha/Hp; "vertebral morphology"	Of the vertebrae T1-4, T5-8 & T9-12 ♀ / ♂# 0.95 / 0.96, 0.90 / 0.91 and 0.93 / 0.92
Burger 1997 <sup>147</sup>	1441	Stratified sample >55 yrs (724/717)	X-ray	Anterior height (Ah) / posterior height (Ph); "vertebral deformities"	Ah / Ph ratios (T4-T12) ♀ / ♂ 0.867-0.941 / 0.854-0.954
Goh 2000 <sup>148</sup>	220	Patients (106/114)	MRI	Anterior wedge index: Ha/Hp; "vertebral morphology"	♀ / ♂: 0.98-0.91 / 0.98-0.90*
<b>VERTEBRAL DEFORMITIES</b>					
Ismail 1999 <sup>149</sup>	13562	From 19 European countries >50 yrs (6362/7200)	X-ray	Wedge: Ha/Hp decreased + Ha/H-pred <3SD below reference mean, Biconcave: Hm/Hp and Hm/H-pred <3SD; Crush: Ha/H-pred and Hp/H-pred <3SD+; "vertebral deformities"	Deformity types by level (T4-T12)* Wedge: ♀ 0.5%-1.3% / ♂ 0.4%-1.2% Biconcave: ♀ 0.1%-0.5% / ♂ 0.2%-0.5% Crush: ♀ 0.2%-0.3% / ♂ 0.06%-0.2%

Authors	N	Sample (♂/♀)	Method	Case definition	Prevalence
<b>VERTEBRAL DEFORMITIES</b>					
Mann 1992 <sup>139</sup>	144	Men from hospitals	X-ray	Anterior deformity=Ha/Hp <2SD specified level mean; "vertebral deformities"	T7-T12 by level: 3.5%-4.5%*
Härmä 1986 <sup>150</sup>	57440	Population sample 30188/27252	Photofluorograms	Collapse of anterior vertebral cortex (wedge) or both anterior and posterior (collapse); "compression fractures"	For 15908 men (age 35-74 yrs) per 1000: 9.2%

\*Estimated from a figure

#Calculated from a figure showing the prevalence rates or mean Ha/Hp ratios for five different age groups by summing them up and dividing by five.

Ha= anterior height of the vertebra, Hp= posterior height, H-pred= predicted posterior height calculated from the posterior heights of up to four adjacent vertebrae, Hm= middle height



*Disc bulging* is one of the common features of disc degeneration, but has not been commonly investigated in the thoracic region. The prevalence of disc bulging has been reported to be 65 % among asymptomatic men.<sup>120</sup> When examined for levels T6-T7 through T11-T12, bulging has occurred most often at the T11-T12 level, with a prevalence of 70% among 232 men who were a sub-sample of this thesis's subjects<sup>119</sup> and 5.5% in 20 divers aged 10 to 21 years.<sup>126</sup> The difference between young divers and men is likely explained by an increase in the prevalence of disc bulging with age.

Similar to disc bulging, decreased (darkening of the disc) *disc signal* appears to be common in the general population of men,<sup>119</sup> in patients,<sup>127</sup> as well as in adolescents,<sup>126</sup> which is expected since decreased disc signal is the imaging finding most highly associated with age.<sup>116</sup> Most often decreased signal is detected in the last two thoracic levels, and has varied in reports from 23.5% of discs from subjects aged 10-21 years<sup>126</sup> to almost every disc in a patient sample<sup>127</sup> and in men over 35 years of age.<sup>119</sup>

*Disc height narrowing* which is considered a sign of more advanced disc degeneration<sup>148</sup> is, as could be expected, more common in men<sup>119</sup> than in adolescents.<sup>126</sup> The prevalence of disc height narrowing in the sub-sample of men from this thesis increased caudally from 5.1% at T6-T7 level to 15.9% at T11-T12 level.<sup>119</sup>

*Vertebral osteophytes*, another finding commonly associated with the presence of disc degeneration especially on radiography,<sup>116,141,149,150</sup> may occur as a part of a 'normal' aging process<sup>151</sup> or secondary to other degenerative findings, such as disc herniation or annular tears.<sup>152</sup> The prevalence of osteophytes in the thoracic region has been investigated using MRI,<sup>119,127</sup> X-ray<sup>23,134,141,150</sup> and anatomic inspections.<sup>23,142</sup> Osteophytes were found to be common in all groups examined. For example, a prevalence of over 50% in male workers<sup>134,150</sup> and in men over 50 years of age<sup>141</sup> has been reported. The prevalence has been higher in cadavers using anatomic inspections<sup>23,142</sup> than in men using MRI<sup>119</sup> or X-ray,<sup>141</sup> which is most likely due to the ability to detect osteophytes better using bony inspections than either MRI or X-ray, especially if located in the 'corners' of the vertebrae.

However, the most common site of occurrence of osteophytes is not clear. The studies examining the whole thoracic region found osteophytes to be more common either at T9 to T10 vertebrae<sup>142</sup> or at mid-thoracic levels (T5-T8)<sup>127</sup> anteriorly and at T1 to

T3 vertebrae posteriorly.<sup>142</sup> The sub-sample of subjects from the current thesis, which examined osteophytes for levels T6-T7 through T11-T12, found T11-T12 level to be the most common site of osteophytes, with a prevalence of 20.7%.<sup>119</sup> Osteophytes tend to occur at sites where the tension is greatest, like in the concavities of the vertebral column.<sup>153</sup> The formation of osteophytes at these sites can occur as a defence mechanism to withstand the compressive forces,<sup>42</sup> and for this reason anterior osteophytes appear more common than posterior osteophytes in the thoracic region.<sup>142</sup>

*Annular tears*, which have been suggested of being associated with disc bulging, especially with large bulges,<sup>154</sup> and with low-back pain (LBP)<sup>102,155-157</sup> have been found to be commonly present in cadavers,<sup>23,128</sup> in subjects deemed symptomatic<sup>127</sup> or asymptomatic,<sup>120</sup> and even in fairly young adults between the ages of 23 and 42 years.<sup>93</sup> The prevalence of annular tears in asymptomatic men has varied from 50% to 63%.<sup>120</sup> The studies reporting the prevalence of annular tears by level have mostly examined the thoracolumbar junction only. In 117 cadavers using anatomic inspections, a prevalence of 51.3% in the thoracolumbar junction has been reported.<sup>128</sup> Malmivaara<sup>23</sup> found most tears at the T10-T11 level, with partial tears in 35% and full tears in 8% of the discs in 37 male cadavers aged 21-69 years using discography. In younger asymptomatic subjects, of the eleven full tears observed, only one occurred below T8-T9.<sup>93</sup> However, the detection of annular tears in MRI may be impaired by the lack of enough contrast<sup>73,112</sup> and some tears may be missed.

Ever since the introduction of *disc herniation* as a probable cause of back pain by Mixter and Barr<sup>158</sup> in 1934 it has gained a lot of attention. Before the availability of MRI as an imaging method of choice, thoracic herniations were believed to be rare.<sup>159-162</sup> The prevalence of operated thoracic disc herniations has varied between 0.2% and 4.5%.<sup>160,163-167</sup> The prevalence of thoracic disc herniations in the general population of men using MRI has been negligible,<sup>119</sup> whereas the prevalence in patient sample and in asymptomatic subjects has varied from 9.2% to 41% using MRI and CT.<sup>117,120,121</sup> The variations in the prevalence rates may be explained by the differences in methodology, including the subjective assessments of the images and CT versus MRI as an imaging method because MRI is more likely to detect herniations than CT.

The prevalence of *Schmorl's nodes*, which are herniations of the disc through the endplates into the vertebral body,<sup>168</sup> remains controversial. A prevalence of 9.6% in patients has been reported,<sup>117</sup> but in male cadavers the rates vary from 25% to 45% for the region T8 through T12.<sup>130</sup> In addition, the prevalence of Schmorl's nodes varies greatly by level. From T1 to T6, Schmorl's nodes appear to be almost non-existent in cadavers and in patients,<sup>127,132</sup> whereas, a prevalence of about 40% has been found in the T9-T12 region in patients<sup>127</sup> and of 35% in the T11-T12 region in cadavers.<sup>132</sup> Similarly other studies examining only parts of the thoracic region have found the nodes to be most common at the two lowest levels,<sup>23,119,126,133</sup> with varying prevalence rates from 19% to 65% at T10-T11 level and from 30% to 61% at T11-T12 level in cadavers.<sup>23,131-133</sup>

The reason for the differences in prevalence rates between the studies is not fully clear; x-ray has yielded the higher prevalence rates<sup>133</sup> even though the node needs to be large enough and have enough sclerosis around the margin to be visible on x-ray.<sup>13,168</sup> Malmivaara<sup>23</sup> found that at least half of the nodes that were visible in pathological examination were not visible on x-ray. Conversely, Silberstein et al.<sup>131</sup> reported that in 28% of spines examined, x-ray revealed a greater number of Schmorl's nodes than pathological examination. The difference between the studies was probably due to the use of only mid-sagittal sections in the pathological examination by Silberstein et al.<sup>131</sup> when compared to x-ray.

Schmorl's nodes have also appeared more commonly in the upper endplates of the disc than in the lower endplates, as was found in a sub-group of men from this doctoral work examined earlier,<sup>119</sup> and supported by others using anatomic inspections,<sup>23</sup> X-ray<sup>132,133</sup> and MRI.<sup>169</sup> The developmental weakening of the endplates by such as, ossification gaps or remnants of the vascular canals,<sup>13,43,52,69,170</sup> is one of the mechanisms through which the nodes may occur, but it is unclear why upper endplate of the disc would be affected more than the lower endplate. Another theory highlights the role of axial loading in the formation of Schmorl's nodes,<sup>171,172</sup> but it also would require the endplates to be affected differently. This difference in the occurrence of Schmorl's nodes has not been examined and the reason remains unclear. However, Schmorl's nodes have occurred more commonly in straight endplates than in the endplates of normal concavity leading the authors to speculate that the larger pressure per surface ratio in the straight endplates

with smaller surface area would explain the difference.<sup>132</sup> But also this theory requires upper and lower endplates to be geometrically different to explain the difference in the occurrence of Schmorl's nodes and this seems unlikely.

*Vertebral deformity* is one of the most important manifestations of osteoporosis but the prevalence rates between studies vary. In men, quantitative measurements of vertebral heights from T4 through L4 vertebrae using x-ray have revealed a prevalence of deformities from 7.5% to 34.3% of the subjects<sup>146,173</sup> with wedge deformity in the mid-thoracic region being the most common type.<sup>136,146</sup> Unfortunately, comparisons between studies are challenged by the different definitions for vertebral deformities.<sup>146</sup> Usually the presence of vertebral deformity is determined by comparing the observed ratios of vertebral heights with reference values or with predicted vertebral heights calculated from adjacent vertebrae but no consensus as to which criterion to use exists.<sup>173</sup> With this in mind, Mann and colleagues<sup>136</sup> investigated the effects of four commonly used quantitative criteria, based on the height ratios and deviations from reference data, and qualitative assessments by a radiologist on the prevalence rates and found extensive variations between the criteria. For example, the prevalence of wedge deformity varied between 8% and 86% depending on the assessment criteria. The less selective methods for wedging deformity yielded high prevalence rates using anterior and posterior vertebral height ratios (15% and 20% reduction) as indicators of the presence of wedge deformity. The higher prevalence may be explained by assessing the vertebrae within the ranges of 'normal' physiological wedging as being deformed.<sup>136</sup> Hence, the standardization of diagnostic criteria is sorely needed for advances in understanding the vertebral deformities and fractures.

As a result of these challenges a semiquantitative technique was suggested for vertebral deformity assessment.<sup>174</sup> The intraobserver and interobserver reliabilities were found to be good to excellent without the experience of the assessor affecting the reliability. The semiquantitative technique was also compared to a quantitative technique based on the ratios of vertebral heights, and the first technique detected more fractures at the mid-thoracic levels<sup>174</sup> where they appear to be most common.<sup>136,146</sup> Therefore, since the development of this technique, it has been widely used in the research on the vertebral deformities and fractures.

*Vertebral hemangioma* is a benign vascular tumour and often an incidental imaging finding.<sup>175</sup> Usually hemangiomas are asymptomatic and without clinical consequence but occasionally, if large enough, may compress the spinal cord and nerve roots causing back pain, radiculopathy and myelopathy.<sup>176</sup> The prevalence of hemangiomas in the literature varies greatly. A prevalence of 0.5% in French women older than 75 years of age<sup>177</sup> and 9.8% in men 30 years or older has been reported.<sup>13</sup> The difference is probably due to an anatomic inspection versus radiography. Additionally, no definitions for hemangiomas were provided and differences in the assessment protocols may have been present.

Most often vertebral hemangiomas seem to exist in the thoracic region and be slightly more common in women than in men.<sup>13</sup> The clinical sequence of vertebral hemangiomas is unclear. The hemangioma results in coarsening of the bony trabecular arrangement, but vertebral body collapse is relatively rare.<sup>13</sup> Still, the presence of vertebral hemangioma may be an indication for vertebroplasty (i.e. injection of cement into vertebral bodies).<sup>178,179</sup>

*Scheuermann's disease* which initially was described as a rigid kyphosis associated with wedged vertebral bodies occurring in late childhood<sup>180</sup> is a characteristic to thoracic region. Using radiographs Sørensen<sup>138</sup> described a specific criterion for diagnosing Scheuermann's disease with at least three adjacent vertebrae with wedging of 5° or more. Despite this specific criterion, several diagnostic criteria appear in the subsequent literature<sup>181</sup> and the prevalence rates remain unclear.

The prevalence for Scheuermann's disease (kyphosis) has varied from 28% to 47% using endplate irregularity as the criterion.<sup>92,93</sup> With Sørensen's<sup>138</sup> criterion, prevalence rates have varied from 6.1% among young draftees<sup>135</sup> to 9.7% among 60-year-old men<sup>139</sup> using x-ray. The use of different case definitions in x-ray has resulted the prevalence to vary from 9.7%<sup>136</sup> to 30%.<sup>134</sup> Hult's<sup>134</sup> criterion was wedging of vertebrae whereas Mann and colleagues'<sup>136</sup> definition included the associated findings of endplate irregularity and sclerotic deformity with wedging. Yet, the use of similar case definition has resulted in similar prevalence rates.

Both the etiology and natural history of Scheuermann's disease remain unknown and controversial.<sup>82,181</sup> Several theories on its occurrence have been proposed<sup>13,180,182</sup> but other studies have not confirmed these theories.<sup>181</sup> Most studies agree that mechanical

factors seem to play an important role in the pathogenesis.<sup>181</sup> Scheuermann's disease have said to have a benign course usually resulting in little deformity and few symptoms.<sup>183</sup> In fact, it seems symptomatic during teenage years but less painful in late teenage years<sup>82,138</sup> even though adults with surgically-treated Scheuermann's disease often report disabling back pain.<sup>184,185</sup> Symptoms may be related more to severe rather than to mild form of Scheuermann's disease and untreated rather than treated form.

### **Association of degenerative findings with age**

A correlation of particular findings with age may offer insights into validity of a finding as a degenerative parameter and to help distinguish the findings that are indicators of age-related degeneration. As mentioned before, the loss of disc signal seems to be the most sensitive sign for disc degeneration and should correlate with age. Indeed, the previous analysis of the sub sample of this thesis's subjects<sup>119</sup> found disc signal ( $r=0.62$ ,  $p<0.001$ ), disc bulging ( $r=0.41$ ,  $p<0.001$ ), disc height narrowing ( $r=0.16$ ,  $p=0.013$ ), and the presence of osteophytes ( $r=0.38$ ,  $p<0.001$ ) to correlate with age. However, correlations were examined for combined levels from T6 to S1.<sup>119</sup> Osteophytes have also been associated with age in different samples<sup>23,127,141,150</sup> supporting the findings of the general population study.<sup>119</sup> Also, regardless of the varying definitions for disc degeneration it has been associated with age.<sup>23,127,129</sup> All the correlations with age seem proper considering what is known of disc degeneration, although, as said, a low correlation may question the validity of the finding as a degenerative parameter. The association with age may also be dependent on other factors, such as the presence of disc degeneration. For example, disc height has been shown to increase with age where the narrowing of the anterior and posterior disc heights are being counteracted by the increased convexity of the disc.<sup>186,187</sup> However, this relationship is affected by disc degeneration; in the absence of disc degeneration the disc height increases with age, while in the presence of disc degeneration the disc height and the convexity of the disc decreases.<sup>187,188</sup>

Other findings not associated with age are disc herniations and Schmorl's nodes.<sup>23,119,120,130,133</sup> The lack of association between Schmorl's nodes and age may be explained by pathogenesis of the nodes which occur through defects in the endplates. The defects has been reported to be due to: 1) developmental weakening by embryonic de-

fects such as ossification gaps;<sup>13,43,52,69</sup> 2) degenerative weakening by aging process;<sup>13,168</sup> 3) pathologic weakening by different diseases;<sup>13,168</sup> and 4) acute or chronic trauma by excessive axial loading<sup>171,172</sup> and repetitive loading.<sup>189</sup> Therefore, Schmorl's nodes may develop early in life and not present an age-related degenerative process.

Similarly, the development and recovery of disc herniations over time may affect the correlation with age. Girard et al.<sup>117</sup> and Wood et al.<sup>92</sup> found that most of the herniations at baseline remained the same size while some decreased in size with a follow-up of 1-37 months. The decrease in size was size-dependent; large herniations (canal compromise more than 20%) were more likely to decrease in size than small herniations.<sup>92</sup> Contrary, decreased disc signal is unlikely to revert once present leading to an increased prevalence with age.

#### **Association of degenerative findings with one another**

Associations of degenerative findings to one another could offer insights into the common etiology and/or pathogenesis of disc degeneration. Due to the disc's integrated function, an alteration in one of the components of the disc is likely to cause alterations in other components as well. For example, desiccation of the nucleus will deteriorate the capability of a disc to resist compressive loading.<sup>190</sup> This causes the disc to bulge and to lose disc height leading to the "temporary dysfunction" of the segment and the occurrence of osteophytes at the attachment of longitudinal ligaments as an effort to support the unstable vertebra-disc-vertebra -unit.<sup>35</sup> Therefore, the coexistence of findings would offer insight information on which findings tend to occur together and on their pathogenesis.

The coexistence of findings has been most commonly studied for Schmorl's nodes. In cadavers, it remains inconclusive whether Schmorl's nodes are associated with disc degeneration. Malmivaara<sup>23</sup> found no association, while Hilton et al.<sup>133</sup> did, adjusting for age ( $r=0.36-0.53$ ,  $p<0.05$ ). Difference may be explained by the different definitions for disc degeneration; Malmivaara<sup>23</sup> defined degeneration as the extent of contrast medium spread in discography and Hilton et al.<sup>133</sup> using disc height narrowing and osteophytes. Schmorl's nodes have also been associated with disc height narrowing and osteophytes in cadavers<sup>132</sup> and with herniated discs in patients.<sup>191</sup> Osteophytes have been cor-

related with disc degeneration ( $r=0.51$ ,  $p<0.05$ ) in cadavers<sup>23</sup> and “Scheuermann type of changes” have coexisted with other disc-related findings (annular tears, disc bulging and herniations).<sup>120</sup> However, if severely degenerated discs (i.e., end-stage degeneration) are examined several different findings are likely to be associated with one another considering the dependence of the structures on one another.

In the sub-sample of this thesis’s subjects<sup>119</sup> disc height and disc signal, and upper and lower endplate irregularities were associated with one another in six of the seven levels examined for levels T6-T7 through T11-T12, and osteophytes with disc bulging in all levels. Hence, degenerative findings tend to coexist with other findings at the same level, which is important to keep in mind when, for example, investigating the association of imaging findings to pain history.

## **UPPER OR MID-BACK PAIN**

The beginning of this section takes a biomedical approach on pain, although to fully explain one’s pain experience it may need to be interpreted in the biopsychosocial context. The section starts with a description of the occurrence rates of upper or mid-back pain and its characteristics. Next, an overview of the pain sensation and different upper or mid-back pain types with the possible pain mechanisms will be offered. Lastly, an overview of the role of biological and psychosocial factors on pain perception and reporting is offered as a background for subsequent discussion of upper or mid-back pain.

### **The epidemiology of upper or mid-back pain**

LBP appear to be the most common back and neck pain complaint, especially in the general population of men, while upper or mid-back pain is the least common (Table 2-2 and Appendix C). However, regardless of upper or mid-back pain being the least common pain complaint, the prevalence of pain is still substantial.



**Table 2-2.** The one-year prevalence of back pain in general population and general work-force samples.

Authors	Subjects	Question	Prevalence of back pain
Linton 1998 <sup>192</sup>	2305	“Have you suffered from back or neck pain during the past 12 months?”	Both genders • neck: 44% • upper or mid-back: 15% • low-back: 56%
Linton & Ryberg 2000 <sup>193a</sup>	1914	“Have you suffered from back or neck pain during the past 12 months?”	♂ / ♀ • neck: 35% / 49% • upper or mid-back: 18% / 23% • low-back: 48% / 44%
Natvig 1995 <sup>194</sup>	2726	“Have you ever in the last 12 months experienced symptoms (pain or discomfort)?”	♂ / ♀ • neck: 37% / 58% • upper or mid-back: 15% / 31% • low-back: 51% / 55%
Guo 2004 <sup>195b</sup>	18942	“In the past year at your job, did you have soreness or pain in any body part?”	♂ / ♀ • neck: 12% / 15% • upper or mid-back: 4% / 5% • low-back: 18% / 20%
Guo 1995 <sup>196b</sup>	30074	“At any time during the past 12 months, that is since (a specific date) a year ago, did you have back pain every day for a week or more?”	♂ / ♀ • neck: 11% / 17% • upper or mid-back: 11% / 12% • low-back: 78% / 70%

<sup>a</sup>Prevalence rates estimated from a figure.

<sup>b</sup>Work-related back pain.

The epidemiological studies of back and neck pain can be characterized as a collection of studies with varying objectives, designs, populations, definitions of the problem, and measurement techniques<sup>193</sup> of which most are “unacceptable methodological quality”.<sup>197</sup> These differences may explain, in part, the wide range of reported prevalence rates in the literature. For example, the one-year prevalence of upper or mid-back pain has varied from 3% among nurses<sup>198</sup> to 41% among physical therapists.<sup>199</sup>

The reason for the difference is not entirely clear. It is unclear whether nurses were specifically queried about their upper or mid-back pain as physiotherapists were. Additionally, physiotherapists were, in particular, queried about their job-related pain. These differences may explain some of the variation in the prevalence rates. The use of similar methodologies (including cultural background of the subjects) have yielded equal prevalence rates for upper or mid-back pain from 15% to 18%.<sup>192-194</sup>

**Table 2-3.** The characteristics of back and neck pain in occupational groups.

Author	Sample	Disability due to pain
Bork 1996 <sup>200</sup>	928 physical therapists	<ul style="list-style-type: none"> <li>• Missing work due to pain</li> <li>• neck: 0.7%</li> <li>• upper or mid-back: 0.7%</li> <li>• low-back: 2.8%</li> </ul>
Merlino 2003 <sup>201</sup>	996 apprentice construction workers	<ul style="list-style-type: none"> <li>• Missed work because of complaints</li> <li>• neck: 1.6%</li> <li>• upper or mid-back: 2.8%</li> <li>• lowback: 7.3%</li> </ul>
Olafsdottir 2000 <sup>202</sup>	254 fish-filleting women	<ul style="list-style-type: none"> <li>• Pain hindering normal work</li> <li>• neck: 13%</li> <li>• upper or mid-back: 10%</li> <li>• low back: 19%</li> </ul>
Ratzon 2000 <sup>203</sup>	60 male dentists	<ul style="list-style-type: none"> <li>• Prevented from doing normal work</li> <li>• neck: 8.3%</li> <li>• upper or mid-back: 3.3%</li> <li>• low-back: 8.3%</li> </ul>
Rosecrance 1996 <sup>204</sup>	526 plumbers and pipe-fitters	<ul style="list-style-type: none"> <li>• Missing the work due to pain</li> <li>• neck: 0.7%</li> <li>• upper or mid-back: 0.7%</li> <li>• low-back: 2.8%</li> </ul>
Törner 1991 <sup>205</sup>	Two groups: welders (n=58) and clerks (n=33)	<ul style="list-style-type: none"> <li>• Unable to perform daily work: welders / clerks</li> <li>• neck: 31% / 3%</li> <li>• upper or mid-back: 7% / -</li> <li>• low-back: 38% / 9%</li> </ul>
Zimmermann 1997 <sup>206</sup>	410 operating engineers	<ul style="list-style-type: none"> <li>• Missed work due to pain</li> <li>• neck: 1.6%</li> <li>• upper or mid-back: 1.4%</li> <li>• low-back: 7.8%</li> </ul>
Author	Sample	Severity of pain
Cromie 2000 <sup>199</sup>	536 physical therapists	<ul style="list-style-type: none"> <li>• Severity score higher than 3 out of 5</li> <li>• neck: 27.1%</li> <li>• upper or mid-back: 19%</li> <li>• low-back: 34.9%</li> </ul>
Zimmermann 1997 <sup>206</sup>	410 operating engineers	<ul style="list-style-type: none"> <li>• Visited physician due to pain</li> <li>• neck: 19.7%</li> <li>• upper or mid-back: 13.3%</li> <li>• low-back: 25.0%</li> </ul>
Osborn 1990 <sup>207</sup>	385 dental hygienists	<ul style="list-style-type: none"> <li>• Mean intensity (1-10)</li> <li>• neck: 4.8</li> <li>• upper or mid-back: 5.7</li> <li>• low-back: 4.8</li> </ul>
Torp 1996 <sup>208,208</sup>	103 car mechanics	<ul style="list-style-type: none"> <li>• Most troublesome site of pain at work</li> <li>• neck: 23%</li> <li>• upper or mid-back: 28%</li> <li>• low-back: 43%</li> </ul>
Author	Sample	Duration of pain
Osborn 1990 <sup>207</sup>	385 dental hygienists	<ul style="list-style-type: none"> <li>• Mean number of days with pain during 12 months</li> <li>• neck: 93</li> <li>• upper or mid-back: 116</li> <li>• low-back: 85</li> </ul>

Similar to the prevalence of neck and back pain, LBP has yielded the highest *severity* ratings, whereas neck and upper or mid-back pain have been more similar to each other. Nevertheless, upper or mid-back pain has also been rated as the most troublesome regional spinal pain in construction workers and in dental hygienists,<sup>201,207</sup> and more severe than neck pain in the general population.<sup>209</sup> Similarly, the *duration of upper or mid-back pain* has been examined in a few studies in dentists and dental hygienists, who either reported the number of days with upper or mid-back pain to be similar or higher than with neck or LBP.<sup>207,210</sup> (Table 2-3.) The validity of reports of pain and associated disability are limited by their subjective nature, which may limit comparisons between subjects. However, it should be reasonable to compare pain experiences in different body regions within subjects.

Having *pain in one region of the back* has been associated with pain in other regions, as well. For example, in orienteers, low-back, upper or mid-back and chest pain were found to be highly associated.<sup>211</sup> In nurses, 15.9% of the nurses reported pain in two regions and 7.4% in all three regions of the back.<sup>212</sup> Similarly, in the general population, persistent pain has occurred in multiple body sites<sup>209</sup> as well as neck and upper or mid-back pain in workers sick-listed due to LBP.<sup>213</sup> This coexistence of pain may indicate difficulty determining the boundaries for different areas of the body, peripheral or central sensitization, or the different pain complaints may have the same risk factors.<sup>214</sup>

### **The sensation of pain**

The sensation of pain occurs through the activation of peripheral sensory organs by noxious stimuli that is followed by a conduction of electrical signals along the afferent pathways to the central nervous system.<sup>215,216</sup> These peripheral sensory organs (nociceptors) consist of *pain-sensitive nerve endings* which are made of plexuses and free endings of unmyelinated nerve fibres derived from branches of adjacent peripheral nerves<sup>217</sup> (Appendix D). Nociceptive afferents are comprised of lightly-myelinated A-delta fibres and unmyelinated slow conducting C-fibres<sup>215</sup> which both have a small-diameter.<sup>218,219</sup> The nerve fibres with larger diameter conduct impulses faster than those with small diameter<sup>42</sup> and the presence of myelin sheath further enhances the speed of the impulse conduction.<sup>220</sup>

The A-delta fibres convey discrete, sharp, short-lasting pain and C-fibres transmit chronic, burning pain.<sup>221</sup> The *C- or A-delta fibres* transport the impulses to the dorsal horn of the spinal cord where the first synapse is made.<sup>218</sup> Spinothalamic tract, which is located on the antero-lateral part of the white substance of spinal cord, continues the signal to the thalamus where a second synapse is made. Lastly, the third-order neuron continues the action potential to the somatosensory cortex of the brain<sup>218</sup> where the impulses are converted into a sensation of pain.<sup>222</sup>

#### *Pain receptors in spinal tissues*

Most spinal structures can act as a source of pain. Ligamentum flavum appears to be the only spinal structure with conflicting results of its innervation.<sup>223,224</sup> Nerve endings have been demonstrated, for example in the joint capsules of facet joints,<sup>225,226</sup> in the longitudinal ligaments,<sup>225,226</sup> in the outer portion of annulus<sup>2,226-228</sup> and in the endplates.<sup>226</sup> In addition, vertebral bodies, muscles, dura mater and costovertebral joints are innervated and can be possible sources of back pain.<sup>2,229</sup>

Even though many structures in the spine are innervated and may evoke pain, disc still remains as the main suspect for back pain (discogenic pain). The mechanism of discogenic back pain is poorly understood. In a normal adult disc no nerve endings exist in the nucleus.<sup>226,228</sup> Nerve in-growth into the nucleus have been observed in chronic LBP or together with disc degeneration.<sup>230-233</sup> Similarly, normal adult human disc is avascular, but angiogenesis associated with disc disorders has been observed. Neovascularization of degenerated discs seems associated with in-growth of potentially nociceptive nerves.<sup>230</sup> The nerve in-growth into the nucleus provide the morphological basis for discogenic pain<sup>230</sup> and several studies have supported the role of disc in back pain.<sup>234-240</sup>

A number of mechanisms have been suggested to explain how discs can induce back pain. The mechanisms include mechanical, inflammatory, immunological, and chemical, and are described below. The different pain mechanisms will be discussed with respect to the different pain types suggested by Wyke<sup>217</sup> which are primary, secondary, reflex and referred pain. However, the separation between different mechanisms is somewhat artificial because different mechanisms may act together to evoke pain responses. Similarly, the same mechanism may produce different types of pain.

## Different pain types

### *Primary pain*

Primary pain results from a direct irritation of the pain receptor endings in the spinal tissues<sup>217</sup> and may be evoked by immunological, inflammatory and/or chemical irritation of the nociceptors.

Immunological irritation. Adult nucleus is normally contained tightly within the annulus and does not make any vascular contact with the systemic circulation after its embryological formation. Therefore, nucleus would be capable of stimulating an autoimmune inflammation.<sup>241</sup> In other words, some chemicals capable of irritating nociceptors, nerve roots, neural tissue and even epidural space<sup>242-244</sup> may originate from the herniated nucleus. The capacity of the nucleus to act as an antigen in both animal and human lumbar discs has been shown and proteoglycans may be the probable source of the reaction.<sup>245</sup>

Inflammatory irritation. Inflammatory response causes the release of intracellular contents from damaged cells and chemical mediators from inflammatory cells. These chemicals sensitize high-threshold nociceptors to perceive low-intensity stimuli that normally would not cause pain to be perceived as painful (peripheral sensitization). Tissue damage and inflammation also seem to activate primary afferent fibres that normally do not respond to excessive mechanical or thermal stimuli.<sup>216</sup> Inflammation can occur without the full immune response<sup>246</sup> by directly stimulating the biochemical pathways or capable cell types.<sup>247,248</sup> Herniated lumbar discs have, for example, contained high levels of phospholipase A<sub>2</sub><sup>249</sup> which may cause inflammation without an immune response.<sup>250</sup> Other factors identified that are components of the nucleus and mediators of inflammation are proteases, prostaglandins, nitric oxide, and various cytokines.<sup>251-256</sup>

Chemical irritation. Plasticity of the nociceptors causes their responsiveness to stimuli to vary, particularly in the presence of chemical mediators of inflammation,<sup>257</sup> as described above. These neurogenic mediators are, for example, substance P which causes vasodilatation, plasma extravasation and release of histamine from mast cells<sup>218</sup> and has been observed in lumbar spinal tissues.<sup>258</sup> Further, substance P stimulates the release of a variety of inflammatory mediators such as interleukins, tumor necrosis factor (TNF) and arachnoid acid.<sup>259</sup> Other pain-producing non-neurogenic chemicals, such as bradykinin, sero-

tonin, histamine, potassium ions and prostaglandins, are also released during tissue damage.<sup>257</sup>

### *Secondary pain*

Secondary pain arises through the irritation of the afferent nerve fibres that connect the pain receptors to the spinal cord through dorsal nerve roots. The irritation of dorsal nerve root frequently occurs at, or close to, the intervertebral foramina by, for example, osteophytes or disc herniation<sup>217</sup> and can be characterized as mechanical irritation.

Mechanical irritation. Back pain may arise from compression or damage to nerve roots and the spinal cord itself.<sup>216</sup> However, whether nerve root compression alone is enough to induce pain remains unclear.<sup>260,261</sup> In subjects without pain, compression of nerve roots or spinal cord have been observed.<sup>120,262</sup> Isolated, acute compression of a normal nerve rather leads to parasthesias, sensory deficits, motor loss and maybe reflex abnormalities than pain but as a result of compression of an inflamed nerve also pain has occurred.<sup>263</sup>

### *Reflex pain*

Reflex pain is produced by stimulation, whether chemical or mechanical, of the pain receptor system of the connective tissues<sup>217</sup> which further produces polysynaptic reflex contraction of the related portions of the paravertebral muscles.<sup>225</sup>

### *Referred pain*

The last pain type, referred pain,<sup>217</sup> is defined as occurring in a region of the body distinct from the region of the actual source of pain. A more specific definition suggests that the regions do not have to be remote to one another but to have different nerve supply.<sup>264</sup> In this description of referred pain to the thoracic region the focus is on referred pain of visceral origin. The potential causes of upper or mid-back pain may be classified as painful conditions of the thoracic region and conditions referring pain to the thoracic region.<sup>265</sup> Although it is recognized that also thoracic region can refer pain to the viscera and the periphery.<sup>42</sup>

An explanation for the referred pain is that the anatomic structures referring pain to the thoracic region have sensory-afferent neural pathways that converge with those of the sensory nerves of the thoracic region in the central nervous system.<sup>265</sup> This mecha-

nism of convergence seems well agreed on in the literature. The convergence causes distorted central perception of the site of pain via the confluence of afferent nerve fibres from disparate areas within the dorsal horn of the spinal cord<sup>266</sup> because the same cells receive noxious sensations from afferents both in the somatic structures and in the viscera.<sup>221</sup> (Appendix D.) As an example, kidneys can refer pain to lower thoracic region. The spinal segments that convey pain from the kidneys also receive afferents from the lower thoracic levels (convergence theory) and the area of referred pain is determined by the spinal cord segment receiving the pain impulses.<sup>267</sup> Pain from almost any abdominal organ may be referred to the back<sup>268</sup> and the location of thoracic pain may not correspond to the location of the source of pain.<sup>269</sup> Pain in the thoracic region can arise for example, from cardiac and vascular sources, as well as originate from pulmonary, oesophageal, stomach, gallbladder, pancreas and intestinal problems.

### **Biological factors and pain**

As described above, the sensation of pain results from the activation of nociceptors by the noxious stimuli.<sup>215,216</sup> Under normal conditions, nociceptors have a high threshold for eliciting a pain response and only a high-intensity stimulus results in the activation of these receptors.<sup>216</sup> As a result of the plasticity of the nervous system, the responses to noxious stimuli may vary and a repeated occurrence of noxious stimuli may lead either to habituation (decreased response) or sensitization (increased response).<sup>270</sup> In this section only the sensitization of pain will be included since it may be involved in the generation of hyperalgesia in multiple spine segments.

Sensitization may occur as a peripheral and/or a central sensitization. Peripheral sensitization, which has been described in the prior section under inflammatory and chemical irritation, is characterized by a decrease in pain threshold and/or increased pain to a subthreshold stimulus at the site of tissue damage and may lead to primary hyperalgesia.<sup>216,271</sup> In addition to primary hyperalgesia, a secondary hyperalgesia may occur at a distant area from the initial site of damage. Secondary hyperalgesia is caused by central sensitization, which is further believed to result from increased excitability of dorsal horn neurons to innocuous and noxious stimuli.<sup>216,272,273</sup> The hyperexcitability of these neurons is manifested by enlarged receptive field areas and by an increase in the number of re-

sponses evoked by natural stimuli.<sup>274</sup> The mechanism of central sensitization involves the activation of the peripheral nociceptive C-fibres which carry the information of the nociceptive impulses to the dorsal horn of the spinal cord where both nociceptive and non-nociceptive neurons exist (wide-dynamic-range neurons). As a result of the activation of both types of neurons, a stimulus that normally would not be perceived as painful is felt as painful (allodynia). This process involves several neurotransmitters, such as substance P, nerve growth factor and glutamate, which are able to modulate the postsynaptic responses and cause synaptic hyperexcitement and activate second-order neurons in the dorsal horn.<sup>275</sup>

Primary and secondary hyperalgesia are of importance since they may result in diffuse, global pain, and should be kept in mind when examining pain in multiple body areas. This may be especially relevant in cases with pain in multiple spinal regions.

### **Psychosocial factors and pain**

In addition to biological factors affecting the perception of pain, it also is an individual, multifactorial experience influenced by culture, previous pain events, beliefs, mood and ability to cope with the pain.<sup>215</sup> Due to the subjective nature of pain,<sup>276,277</sup> the reporting of pain is affected by several factors other than underlying pathology. Knowledge of nociception and somatic contributors is crucial in understanding pain, but often is not enough to explain reported pain without understanding of the contribution of psychosocial factors.<sup>215</sup> Hence, Engel<sup>278</sup> proposed the biopsychosocial model of illness in 1977 according to which pain experience is a result of a dynamic interaction between psychological, social, and pathophysiological variables. Kendall<sup>279</sup> further stated that underlying pathology is not caused by the psychosocial factors, but the perception of pain is readily influenced by such factors and their complex interactions with medical and work-related beliefs and behaviours, all of which may affect the decision to report pain, to take time off work and whether to respond to treatment or not.<sup>280,281</sup>

The individual and work-related psychosocial factors associated with back pain have been summarized by several reviews<sup>281-283</sup> and include both occupational and individual risk factors for back pain. Some of the occupational factors include job dissatisfaction, mental stress at work, monotonous work, heavy physical work, static work postures,



repetitive work and whole-body vibration, while some of the individual factors are anxiety, depression, negative body image, age, sex, social class and education.<sup>281,283,284</sup> Arguably, this is not a complete list, while pain reports have even varied according to the social context as has been shown in soldiers during peace and wartime.<sup>285</sup> All these factors affecting pain reports have implications on efforts to correlate pathology with pain reports because other factors independent of the underlying pathology may affect the reports and dilute the observed associations between pain and findings. Hence, a formula for the determinants of pain can be expressed as a regression equation where the contributions of independent variables on pain are not known, but pathology is assumed to be present (Figure 2.3). In addition, the equation includes some error (i.e. unidentified factors) and may include interactions between variables.

$$\text{Pain} = \beta_{\text{Pathology}}(1 + \beta_{\text{Physical loading}} + \beta_{\text{Psychological factors}} + \beta_{\text{Social factors}} + \beta_{\text{Individual factors}}) + e$$

**Figure 2-3.** Determinants of pain.

### ASSOCIATION BETWEEN IMAGING FINDINGS AND BACK PAIN

The research on specific imaging findings as a possible source of pain has involved mainly the lumbar region of the spine where various forms of disc ‘pathology’ have been associated with different measures of LBP. For example, a review of radiological degenerative signs rating the methodological quality of the studies, found that based on the results of the higher-quality studies, disc degeneration (without further definition) was the only radiographic finding associated with non-specific LBP.<sup>286</sup>

Of the *imaging findings studied in this work*, disc height narrowing, disc signal, and disc bulging have all been associated with LBP during prior year using x-ray or MRI (Table 2-4). In addition, LBP in the last ten years has been associated with radiological signs of disc degeneration (sclerosis or osteophytes and disc height narrowing) in 60-year-old men and women<sup>139</sup> as well as disc signal, and anterior and posterior bulging with the ‘history of three or more back accidents’.<sup>287</sup> However, a common problem with the imaging findings associated with back pain is poor sensitivity.<sup>102</sup>

Other studies have suggested that *rare occurrence of certain findings* in ‘asymptomatic’ subjects might be indicative of the symptomatology. Some of these findings include the presence of neural compromise,<sup>288,289</sup> endplate abnormalities, osteoarthritis of the facet joints, disc sequestration and extrusion,<sup>289-291</sup> displacement of nerve root and interruption of annuloligamentous complex.<sup>291</sup>

However, in the thoracic region of the spine the association between imaging findings and pain has not been widely examined. Earlier x-ray studies of 1200 workers<sup>150</sup> and a random general population sample of 444 men and women aged 15 to over 75 years<sup>153</sup> found disc degeneration (osteophytes with or without disc height narrowing) to show a slight trend towards association with upper or mid-back pain<sup>150</sup> or no association.<sup>153</sup> Interestingly, both studies found disc degeneration to be associated with neck and low-back pain. Therefore, it is unclear whether the association also exists for thoracic region and the studies simply failed to demonstrate it, or whether such an association is truly absent. In fact, Hult<sup>150</sup> reported that the number of subjects with upper or mid-back pain was too small to demonstrate statistical significance and this may have been similar in the study by Lawrence et al.<sup>153</sup> since they did not report the prevalence of upper or mid-back pain in their sample. Additionally, while Hult<sup>150</sup> reported upper or mid-back pain to be more common in workers with light work than in those with heavy work and disc degeneration to demonstrate an opposite trend, it was not adjusted for in the analyses as was not age. Due to these limitations it is unclear whether the association between disc degeneration and upper or mid-back pain exists.

**Table 2-4.** The association between MRI findings and 12-month LBP, odds ratios (95% confidence intervals).

Author	Disc height	Annular tears	Endplate irregularities	Reduced disc signal	Nucleus shape	High-intensity zone	Modic changes	Disc bulging (ant/post)	Osteophytes
Videman 2003 <sup>102#</sup>	2.4 (1.4, 4.0)	1.9 (1.2, 3.1)	1.5 (1.1, 2.1)	NS	-	-	-	NS	NS
	2.2 (1.4, 3.7)	1.8 (1.1, 2.9)							
Pye 2004 <sup>292†</sup>	1.7 (1.5, 3.0)	-	NS (sclerosis)	-	-	-	-	-	NS
Kjaer 2005 <sup>157</sup>	3.9 (2.1, 7.2)	2.3 (1.2, 4.4)	NS	2.4 (1.3, 4.4)	2.8 (1.4, 5.5)	2.3 (1.2, 4.4)	4.0 (1.6, 9.9)	2.6 (1.4, 4.4)	-
Luoma 2000 <sup>238‡</sup>	-	-	-	1.7 (1.1, 2.5)	-	-	-	P:2.2 (1.4, 3.7) A:3.8 (1.7, 8.1)	-

*Univariate analysis, multivariate analysis with regards to other imaging findings*

NS= not significant

- = not investigated

# Age-adjusted; frequency of pain

† A adjusted for age and gender

‡ A adjusted for height, history of car driving, smoking and overweight; frequency of pain

More recently, a case-control study to investigate the association of MRI findings to pain in the thoracic region has been conducted. Disc degeneration in MRI (decreased disc signal intensity with or without disc height narrowing) was found to be more common in patients than in controls, especially in patients under 50 years of age. The cases were patients with clinically confirmed upper or mid-back pain (pain and tenderness around the mid-thoracic region radiating around the chest and aggravated by movements), while the controls were matched for age and sex and had no chest or back pain.<sup>88</sup> The methodological shortcomings of the study include the small samples size (10 cases and 15 controls) and whether the assessor(s) was blinded to the pain status of the subject during the assessments of images which may have had an effect on the results. Interestingly, the study found almost 90% of the controls to have “completely normal MRI” whereas later studies have found MRI findings to be common in asymptomatic subjects of similar age as well.<sup>92,93,120</sup> Due to discrepancies in the literature currently available, studies with clearly defined specific and/or new degenerative findings are needed to understand upper or mid-back pain and its possible causes better.

## **CONCLUSION**

Degeneration in the thoracic region of the spine and upper or mid-back pain have received less attention than neighbouring regions. Despite the development of non-invasive imaging methods with superior soft tissue contrast, such as MRI, a lack of knowledge of thoracic MRI findings in the general population is evident. Knowledge of structural variations in the general population (i.e. normative data) would be important as a reference for related observations in patients. As summarized by White<sup>15</sup> “Accurate and reliable information about the normal is generally the basis, if not the prerequisite, for progress in the understanding and treatment of the abnormal”. Even though, pain arising from the structures of the thoracic region seems to be less common than from the cervical and lumbar regions, it still presents a significant problem for those affected as assessed by associated difficulties in daily activities due to the pain. The epidemiology of upper or mid-back pain is characterized by methodological shortcomings and a lack of general population samples. Similarly, the association between pain and imaging findings remains currently unclear and faces challenges by the current MRI parameters that may not

be sensitive enough to detect the underlying pathology and the validity of the reported pain as an outcome.

## REFERENCES

1. Fitzgerald MJT, Fitzgerald M. *Human Embryology*. 1st ed. London, UK: Baillière Tindall; 1994:251.
2. Bogduk N. *Clinical Anatomy of the Lumbar Spine and Sacrum*. 4th ed. New York, NY: Elsevier/Churchill Livingstone; 2005.
3. Noback CR, Robertson GG. Sequences of appearance of ossification centers in the human skeleton during the first five prenatal months. *Am J Anat*. 1951;89(1):1-28.
4. Bagnall KM, Harris PF, Jones PR. A radiographic study of the human fetal spine. 2. the sequence of development of ossification centres in the vertebral column. *J Anat*. 1977;124(3):791-802.
5. Peacock A. Observations on the postnatal structure of the intervertebral disc in man. *J Anat*. 1952;86(2):162-179.
6. Snell RS. *Clinical Anatomy*. 7th ed. Philadelphia, PA: Lippincott Williams & Wilkins; 2004.
7. Kahle W, Leonhardt H, Platzer W. *Color Atlas/Text of Human Anatomy, Volume 1. Locomotor System*. 4th revised ed. Stuttgart, Germany: Georg Thieme Verlag; 1992.
8. Edmondston SJ, Singer KP. Thoracic spine: Anatomical and biomechanical considerations for manual therapy. *Man Ther*. 1997;2(3):132-143.
9. Fon GT, Pitt MJ, Thies AC, Jr. Thoracic kyphosis: Range in normal subjects. *AJR Am J Roentgenol*. 1980;134(5):979-983.
10. Goh S, Price RI, Leedman PJ, Singer KP. A comparison of three methods for measuring thoracic kyphosis: Implications for clinical studies. *Rheumatology (Oxford)*. 2000;39(3):310-315.
11. Goh S, Price RI, Leedman PJ, Singer KP. The relative influence of vertebral body and intervertebral disc shape on thoracic kyphosis. *Clin Biomech (Bristol, Avon)*. 1999;14(7):439-448.
12. Manns RA, Haddaway MJ, McCall IW, Cassar Pullicino V, Davie MW. The relative contribution of disc and vertebral morphometry to the angle of kyphosis in asymptomatic subjects. *Clin Radiol*. 1996;51(4):258-262.
13. Schmorl G, Junghanns H. *The Human Spine in Health and Disease*. 2nd American edition ed. New York: Grune & Stratton; 1971.
14. Singer KP, Goh S. Anatomy of the thoracic spine. In: Giles LGF, Singer KP, eds. *Volume 2: Clinical Anatomy and Management of Thoracic Spine Pain*. 1st ed. Oxford, UK: Butterworth-Heinemann; 2000:17-33.
15. White AA, 3rd. Analysis of the mechanics of the thoracic spine in man. An experimental study of autopsy specimens. *Acta Orthop Scand Suppl*. 1969;127:1-105.
16. Panjabi MM, Takata K, Goel V, et al. Thoracic human vertebrae. Quantitative three-dimensional anatomy. *Spine*. 1991;16(8):888-901.
17. Dommissie GF. The blood supply of the spinal cord. A critical vascular zone in spinal surgery. *J Bone Joint Surg Br*. 1974;56-B(2):225-235.

18. Takeuchi T, Abumi K, Shono Y, Oda I, Kaneda K. Biomechanical role of the intervertebral disc and costovertebral joint in stability of the thoracic spine. A canine model study. *Spine*. 1999;24(14):1414-1420.
19. White AA, Panjabi MM. *Clinical Biomechanics of the Spine*. 2nd ed. Philadelphia: Lippincott; 1990.
20. Shinohara H. Changes in the surface of the superior articular joint from the lower thoracic to the upper lumbar vertebrae. *J Anat*. 1997;190 (3):461-465.
21. Singer KP, Willen J, Breidahl PD, Day RE. Radiologic study of the influence of zygapophyseal joint orientation on spinal injuries at the thoracolumbar junction. *Surg Radiol Anat*. 1989;11(3):233-239.
22. Pal GP, Routal RV. Mechanism of change in the orientation of the articular process of the zygapophyseal joint at the thoracolumbar junction. *J Anat*. 1999;195 (2):199-209.
23. Malmivaara A. *Thoracolumbar Junctional Region of the Spine. An Anatomical and Radiological Study*. [PhD]. Medical Faculty of the University of Helsinki; 1987.
24. Davis PR. The thoraco-lumbar mortice joint. *J Anat*. 1955;89(3):370-377.
25. Willems JM, Jull GA, J KF. An in vivo study of the primary and coupled rotations of the thoracic spine. *Clin Biomech (Bristol, Avon)*. 1996;11(6):311-316.
26. Markolf KL. Deformation of the thoracolumbar intervertebral joints in response to external loads: A biomechanical study using autopsy material. *J Bone Joint Surg Am*. 1972;54-A(3):511-533.
27. Andriacchi T, Schultz A, Belytschko T, Galante J. A model for studies of mechanical interactions between the human spine and rib cage. *J Biomech*. 1974;7(6):497-507.
28. Jiang H, Raso JV, Moreau MJ, Russell G, Hill DL, Bagnall KM. Quantitative morphology of the lateral ligaments of the spine. Assessment of their importance in maintaining lateral stability. *Spine*. 1994;19(23):2676-2682.
29. Bohatirchuk F. The ageing vertebral column; macro- and historadiographical study. *Br J Radiol*. 1955;28(332):389-404.
30. Champion JM, Maricic MJ. Osteoporosis in men. *Am Fam Physician*. 2003;67(7):1521-1526.
31. Melton LJ,3rd. Epidemiology of spinal osteoporosis. *Spine*. 1997;22(24 Suppl):2S-11S.
32. WHO Study Group on Assessment of Fracture Risk and its Applications to Screening for Postmenopausal Osteoporosis. Assessment of fracture risk and its application to screening for postmenopausal osteoporosis: A report of WHO study group. . 1994;Technical Report Series, No. 843.
33. Loitz-Ramage B, Zernicke RF. Bone biology and mechanics. In: Zachazewski JE, Magee DJ, Quillen WS, eds. *Athletic Injuries and Rehabilitation*. 1st ed. United States of America: W.B Saunders Company; 1996:99-120.
34. Videman T. An experimental study of the effects of growth on the relationship of tendons and ligaments to bone at the site of diaphyseal insertion. *Acta Orthop Scand Suppl*. 1970:1-22.
35. Kirkaldy-Willis WH, Farfan HF. Instability of the lumbar spine. *Clin Orthop Relat Res*. 1982;(165):110-123.

36. Andersson GB. What are the age-related changes in the spine? *Baillieres Clin Rheumatol*. 1998;12(1):161-173.
37. Nathan H, Weinberg H, Robin GC, Aviad I. The costovertebral joints, anatomical/clinical observations in arthritis. *Arthritis Rheum*. 1964;7:228-240.
38. Shore LR. On osteo-arthritis in the dorsal intervertebral joints. A study in morbid anatomy. *Br J Surg*. 1935;22(88):833-849.
39. Urban JP, Winlove CP. Pathophysiology of the intervertebral disc and the challenges for MRI. *J Magn Reson Imaging*. 2007;25(2):419-432.
40. Inoue H. Three-dimensional architecture of lumbar intervertebral discs. *Spine*. 1981;6(2):139-146.
41. Marchand F, Ahmed AM. Investigation of the laminate structure of lumbar disc annulus fibrosus. *Spine*. 1990;15(5):402-410.
42. Middleditch A, Oliver J. *Functional Anatomy of the Spine*. 2nd ed. London, UK: Elsevier Butterworth-Heinemann; 2005.
43. Harris RI, Macnab I. Structural changes in the lumbar intervertebral discs; their relationship to low back pain and sciatica. *J Bone Joint Surg Br*. 1954;36-B(2):304-322.
44. Urban JP, Roberts S. Degeneration of the intervertebral disc. *Arthritis Res Ther*. 2003;5(3):120-130.
45. Feng H, Danfelter M, Stromqvist B, Heinegard D. Extracellular matrix in disc degeneration. *J Bone Joint Surg Am*. 2006;88-A(Suppl 2):25-29.
46. Roberts S, Evans H, Trivedi J, Menage J. Histology and pathology of the human intervertebral disc. *J Bone Joint Surg Am*. 2006;88-A(Suppl 2):10-14.
47. Antoniou J, Steffen T, Nelson F, et al. The human lumbar intervertebral disc: Evidence for changes in the biosynthesis and denaturation of the extracellular matrix with growth, maturation, ageing, and degeneration. *J Clin Invest*. 1996;98(4):996-1003.
48. Yu J, Winlove PC, Roberts S, Urban JP. Elastic fibre organization in the intervertebral discs of the bovine tail. *J Anat*. 2002;201(6):465-475.
49. Nerlich AG, Boos N, Wiest I, Aebi M. Immunolocalization of major interstitial collagen types in human lumbar intervertebral discs of various ages. *Virchows Arch*. 1998;432(1):67-76.
50. Nerlich AG, Schleicher ED, Boos N. Immunohistologic markers for age-related changes of human lumbar intervertebral discs. *Spine*. 1997;22(24):2781-2795.
51. Urban JPG, Roberts S, Ralphs JR. The nucleus of the intervertebral disc from development to degeneration. *Amer Zool*. 2000;40(1):53-61.
52. Coventry MB, Ghormley RK, Kernohan JW. The intervertebral disc: Its microscopic anatomy and pathology. Part I: Anatomy, development and physiology. *J Bone Joint Surg*. 1945;27(2):105-112.
53. Adams P, Eyre DR, Muir H. Biochemical aspects of development and ageing of human lumbar intervertebral discs. *Rheumatol Rehabil*. 1977;16(1):22-29.
54. Roberts S, Menage J, Urban JP. Biochemical and structural properties of the cartilage end-plate and its relation to the intervertebral disc. *Spine*. 1989;14(2):166-174.



55. Eyre DR, Matsui Y, Wu JJ. Collagen polymorphisms of the intervertebral disc. *Biochem Soc Trans.* 2002;30(Pt 6):844-848.
56. Ogata K, Whiteside LA. Nutritional pathways of the intervertebral disc. An experimental study using hydrogen washout technique. *Spine.* 1981;6(3):211-216.
57. Holm S, Maroudas A, Urban JP, Selstam G, Nachemson A. Nutrition of the intervertebral disc: Solute transport and metabolism. *Connect Tissue Res.* 1981;8(2):101-119.
58. Putz RV, Muller-Gerbl M. Ligaments of the human vertebral column. In: Giles LGF, Singer KP, eds. *Clinical Anatomy and Management of Thoracic Spine Pain.* 1st ed. Oxford, UK: Butterworth-Heinemann; 2000:34-44.
59. Boos N, Weissbach S, Rohrbach H, Weiler C, Spratt KF, Nerlich AG. Classification of age-related changes in lumbar intervertebral discs. *Spine.* 2002;27(23):2631-2644.
60. Pooni JS, Hukins DW, Harris PF, Hilton RC, Davies KE. Comparison of the structure of human intervertebral discs in the cervical, thoracic and lumbar regions of the spine. *Surg Radiol Anat.* 1986;8(3):175-182.
61. Hickey DS, Hukins DW. Relation between the structure of the annulus fibrosus and the function and failure of the intervertebral disc. *Spine.* 1980;5(2):106-116.
62. Scott JE, Bosworth TR, Cribb AM, Taylor JR. The chemical morphology of age-related changes in human intervertebral disc glycosaminoglycans from cervical, thoracic and lumbar nucleus pulposus and annulus fibrosus. *J Anat.* 1994;184 (1):73-82.
63. Adams MA, Roughley PJ. What is intervertebral disc degeneration, and what causes it? *Spine.* 2006;31(18):2151-2161.
64. Maroudas A, Stockwell RA, Nachemson A, Urban J. Factors involved in the nutrition of the human lumbar intervertebral disc: Cellularity and diffusion of glucose in vitro. *J Anat.* 1975;120(1):113-130.
65. Stockwell RA. The interrelationship of cell density and cartilage thickness in mammalian articular cartilage. *J Anat.* 1971;109(3):411-421.
66. Urban JP. The role of the physicochemical environment in determining disc cell behaviour. *Biochem Soc Trans.* 2002;30(6):858-864.
67. Roughley PJ. Biology of intervertebral disc aging and degeneration: Involvement of the extracellular matrix. *Spine.* 2004;29(23):2691-2699.
68. Roughley PJ, Alini M, Antoniou J. The role of proteoglycans in aging, degeneration and repair of the intervertebral disc. *Biochem Soc Trans.* 2002;30(6):869-874.
69. Coventry MB, Ghormley RK, Kernohan JW. The intervertebral disc: Its microscopic anatomy and pathology. Part II: Changes in the intervertebral disc concomitant with age. *J Bone Joint Surg.* 1945;27(2):233-247.
70. Lyons G, Eisenstein SM, Sweet MB. Biochemical changes in intervertebral disc degeneration. *Biochim Biophys Acta.* 198;673(4):443-453.
71. Adams MA, Hutton WC. The effect of posture on the fluid content of lumbar intervertebral discs. *Spine.* 1983;8(6):665-671.
72. Buckwalter JA. Aging and degeneration of the human intervertebral disc. *Spine.* 1995;20(11):1307-1314.

73. Herzog RJ. The role of magnetic resonance imaging in the assessment of disk degeneration and diskogenic pain. In: Weinstein JN, Gordon SL, eds. *Low Back Pain. A Scientific and Clinical Overview*. 1st ed. Rosemont, Illinois: American Academy of Orthopaedic Surgeons; 1996:385-405.
74. Adams MA, Dolan P, Hutton WC. The stages of disc degeneration as revealed by discograms. *J Bone Joint Surg Br*. 1986;68-B(1):36-41.
75. Hirsch C, Schajowicz F. Studies on structural changes in the lumbar annulus fibrosus. *Acta Orthop Scand*. 1953;22(3):184-231.
76. Miller JA, Schmatz C, Schultz AB. Lumbar disc degeneration: Correlation with age, sex, and spine level in 600 autopsy specimens. *Spine*. 1988;13(2):173-178.
77. Jarvik JG, Deyo RA. Diagnostic evaluation of low back pain with emphasis on imaging. *Ann Intern Med*. 2002;137(7):586-597.
78. Gundry CR, Fritts HM. Magnetic resonance imaging of the musculoskeletal system. Part 8. The spine, section 1. *Clin Orthop*. 1997;(338):275-287.
79. Saal JS. General principles of diagnostic testing as related to painful lumbar spine disorders: A critical appraisal of current diagnostic techniques. *Spine*. 2002;27(22):2538-2545.
80. McCall IW. Radiology of the thoracic spine. In: Giles LGF, Singer KP, eds. *Clinical Anatomy and Management of Thoracic Spine Pain*. 1st ed. Oxford, UK: Butterworth-Heinemann; 2000:177-202.
81. Malfair D, Beall DP. Imaging the degenerative diseases of the lumbar spine. *Magn Reson Imaging Clin N Am*. 2007;15(2):221-38.
82. Garfin SR, Vaccaro AR, eds. *Orthopaedic Knowledge Update: Spine*. 1st ed. Rosemont, IL: American Academy of Orthopaedic Surgeons; 1997.
83. Jayson MI, Barks JS. Structural changes in the intervertebral disc. *Ann Rheum Dis*. 1973;32(1):10-15.
84. An HS, Anderson PA, Haughton VM, et al. Introduction: Disc degeneration: Summary. *Spine*. 2004;29(23):2677-2678.
85. Williams MP, Cherryman GR, Husband JE. Significance of thoracic disc herniation demonstrated by MR imaging. *J Comput Assist Tomogr*. 1989;13(2):211-214.
86. Ross JS, Perez-Reyes N, Masaryk TJ, Bohlman H, Modic MT. Thoracic disk herniation: MR imaging. *Radiology*. 1987;165(2):511-515.
87. Berns DH, Blaser SI, Modic MT. Magnetic resonance imaging of the spine. *Clin Orthop Relat Res*. 1989;(244):78-100.
88. Bruckner FE, Greco A, Leung AW. 'Benign thoracic pain' syndrome: Role of magnetic resonance imaging in the detection and localization of thoracic disc disease. *J R Soc Med*. 1989;82(2):81-83.
89. Tertti M, Paajanen H, Laato M, Aho H, Komu M, Kormanen M. Disc degeneration in magnetic resonance imaging. A comparative biochemical, histologic, and radiologic study in cadaver spines. *Spine*. 1991;16(6):629-634.

90. Benneker LM, Heini PF, Anderson SE, Alini M, Ito K. Correlation of radiographic and MRI parameters to morphological and biochemical assessment of intervertebral disc degeneration. *Eur Spine J.* 2005;14(1):27-35.
91. Weidenbaum M, Foster RJ, Best BA, et al. Correlating magnetic resonance imaging with the biochemical content of the normal human intervertebral disc. *J Orthop Res.* 1992;10(4):552-561.
92. Wood KB, Blair JM, Aeppl DM, et al. The natural history of asymptomatic thoracic disc herniations. *Spine.* 1997;22(5):525-529.
93. Wood KB, Schellhas KP, Garvey TA, Aeppli D. Thoracic discography in healthy individuals. A controlled prospective study of magnetic resonance imaging and discography in asymptomatic and symptomatic individuals. *Spine.* 1999;24(15):1548-1555.
94. McRobbie DW, Moore EA, Graves MJ, Prince MR. *MRI from Picture to Proton.* 1st ed. Cambridge, United Kingdom: Cambridge University Press; 2003.
95. Schild HH. *MRI made Easy (...Well almost).* 1st ed. Berlin, Germany: H. Heenemann GmbH & Co; 1990.
96. Beattie PF, Meyers SP. Magnetic resonance imaging in low back pain: General principles and clinical issues. *Phys Ther.* 1998;78(7):738-753.
97. Modic MT, Masaryk TJ, Ross JS, Carter JR. Imaging of degenerative disk disease. *Radiology.* 1988;168(1):177-186.
98. Raininko R, Manninen H, Battie MC, Gibbons LE, Gill K, Fisher LD. Observer variability in the assessment of disc degeneration on magnetic resonance images of the lumbar and thoracic spine. *Spine.* 1995;20(9):1029-1035.
99. Videman T, Nummi P, Battie MC, Gill K. Digital assessment of MRI for lumbar disc desiccation. A comparison of digital versus subjective assessments and digital intensity profiles versus discogram and macroanatomic findings. *Spine.* 1994;19(2):192-198.
100. Luoma K, Raininko R, Nummi P, Luukkonen R. Is the signal intensity of cerebrospinal fluid constant? Intensity measurements with high and low field magnetic resonance imagers. *Magn Reson Imaging.* 1993;11(4):549-555.
101. Luoma EK, Raininko R, Nummi PJ, Luukkonen R, Manninen HI, Riihimaki HA. Suitability of cerebrospinal fluid as a signal-intensity reference on MRI: Evaluation of signal-intensity variations in the lumbosacral dural sac. *Neuroradiology.* 1997;39(10):728-732.
102. Videman T, Battie MC, Gibbons LE, Maravilla K, Manninen H, Kaprio J. Associations between back pain history and lumbar MRI findings. *Spine.* 2003;28(6):582-588.
103. Videman T, Battie MC, Ripatti S, Gill K, Manninen H, Kaprio J. Determinants of the progression in lumbar degeneration: A 5-year follow-up study of adult male monozygotic twins. *Spine.* 2006;31(6):671-678.
104. Du Boulay GH. Pulsatile movements in the CSF pathways. *Br J Radiol.* 1966;39(460):255-262.
105. Schellinger D, LeBihan D, Rajan SS, et al. MR of slow CSF flow in the spine. *AJNR Am J Neuroradiol.* 1992;13(5):1393-1403.

106. Scoliosis Research Society. Glossary. <http://www.srs.org/patients/glossary.asp>. Accessed 02/15, 2008.
107. Alvarez O, Roque CT, Pampati M. Multilevel thoracic disk herniations: CT and MR studies. *J Comput Assist Tomogr*. 1988;12(4):649-652.
108. Modic MT, Pavlicek W, Weinstein MA, et al. Magnetic resonance imaging of intervertebral disk disease. Clinical and pulse sequence considerations. *Radiology*. 1984;152(1):103-111.
109. Mirowitz SA. *Pitfalls, Variants and Artifacts in Body MR Imaging*. 1st ed. St. Louis, MO: Mosby-Year Book; 1996:520.
110. Westbrook C. *MRI at a Glance*. 1st ed. Oxford, United Kingdom: Blackwell Science; 2002.
111. Tehranzadeh J, Andrews C, Wong E. Lumbar spine imaging. Normal variants, imaging pitfalls, and artifacts. *Radiol Clin North Am*. 2000;38(6):1207-53.
112. Haughton V. Medical imaging of intervertebral disc degeneration: Current status of imaging. *Spine*. 2004;29(23):2751-2756.
113. Haughton V. Imaging intervertebral disc degeneration. *J Bone Joint Surg Am*. 2006;88-A(Suppl 2):15-20.
114. Castinel BH, Adam P, Milburn PD, et al. Epidemiology of cervical spine abnormalities in asymptomatic adult professional rugby union players using static and dynamic MRI protocols - 2002 to 2006. *Br J Sports Med*. 2008 Apr 2. [Epub ahead of print].
115. Zou J, Yang H, Miyazaki M, et al. Missed lumbar disc herniations diagnosed with kinetic magnetic resonance imaging. *Spine*. 2008;33(5):140-144.
116. Battie MC, Videman T, Parent E. Lumbar disc degeneration: Epidemiology and genetic influences. *Spine*. 2004;29(23):2679-2690.
117. Girard CJ, Schweitzer ME, Morrison WB, Parellada JA, Carrino JA. Thoracic spine disc-related abnormalities: Longitudinal MR imaging assessment. *Skeletal Radiol*. 2004;33(4):216-222.
118. Fardon DF, Milette PC, Combined Task Forces of the North American Spine Society, American Society of Spine Radiology, and American Society of Neuroradiology. Nomenclature and classification of lumbar disc pathology. *Spine*. 2001;26(5):93-113.
119. Videman T, Battie MC, Gill K, Manninen H, Gibbons LE, Fisher LD. Magnetic resonance imaging findings and their relationships in the thoracic and lumbar spine. Insights into the etiopathogenesis of spinal degeneration. *Spine*. 1995;20(8):928-935.
120. Wood KB, Garvey TA, Gundry C, Heithoff KB. Magnetic resonance imaging of the thoracic spine. Evaluation of asymptomatic individuals. *J Bone Joint Surg Am*. 1995;77-A(11):1631-1638.
121. Awwad EE, Martin DS, Smith KR, Jr, Baker BK. Asymptomatic versus symptomatic herniated thoracic discs: Their frequency and characteristics as detected by computed tomography after myelography. *Neurosurgery*. 1991;28(2):180-186.

122. Sachs BL, Vanharanta H, Spivey MA, et al. Dallas discogram description. A new classification of CT/discography in low-back disorders. *Spine*. 1987;12(3):287-294.
123. Arana E, Marti-Bonmati L, Dosda R, Molla E. Concomitant lower thoracic spine disc disease in lumbar spine MR imaging studies. *Eur Radiol*. 2002;12(11):2794-2798.
124. Arana E, Marti-Bonmati L, Molla E, Costa S. Upper thoracic-spine disc degeneration in patients with cervical pain. *Skeletal Radiol*. 2004;33(1):29-33.
125. Ryan RW, Lally JF, Kozic Z. Asymptomatic calcified herniated thoracic disks: CT recognition. *AJNR Am J Neuroradiol*. 1988;9(2):363-366.
126. Baranto A, Hellstrom M, Nyman R, Lundin O, Sward L. Back pain and degenerative abnormalities in the spine of young elite divers: A 5-year follow-up magnetic resonance imaging study. *Knee Surg Sports Traumatol Arthrosc*. 2006;14(9):907-914.
127. Goh S, Tan C, Price RI, et al. Influence of age and gender on thoracic vertebral body shape and disc degeneration: An MR investigation of 169 cases. *J Anat*. 2000;197(4):647-657.
128. Hilton RC, Ball J, Benn RT. Annular tears in the dorsolumbar spine. *Ann Rheum Dis*. 1980;39(6):533-538.
129. Chanchairujira K, Chung CB, Kim JY, et al. Intervertebral disk calcification of the spine in an elderly population: Radiographic prevalence, location, and distribution and correlation with spinal degeneration. *Radiology*. 2004;230(2):499-503.
130. Saluja G, Fitzpatrick K, Bruce M, Cross J. Schmorl's nodes (intravertebral herniations of intervertebral disc tissue) in two historic British populations. *J Anat*. 1986;145:87-96.
131. Silberstein M, Opeskin K, Fahey V. Spinal Schmorl's nodes: Sagittal sectional imaging and pathological examination. *Australas Radiol*. 1999;43(1):27-30.
132. Pfirrmann CW, Resnick D. Schmorl nodes of the thoracic and lumbar spine: Radiographic-pathologic study of prevalence, characterization, and correlation with degenerative changes of 1,650 spinal levels in 100 cadavers. *Radiology*. 2001;219(2):368-374.
133. Hilton RC, Ball J, Benn RT. Vertebral end-plate lesions (Schmorl's nodes) in the dorsolumbar spine. *Ann Rheum Dis*. 1976;35(2):127-132.
134. Hult L. The Munkfors investigation; a study of the frequency and causes of the stiff neck-brachialgia and lumbago-sciatica syndromes, as well as observations on certain signs and symptoms from the dorsal spine and the joints of the extremities in industrial and forest workers. *Acta Orthop Scand Suppl*. 1954;16:1-76.
135. Dameron TE, Jr, Gullledge WH. Adolescent kyphosis. *U S Armed Forces Med J*. 1953;4(6):871-875.
136. Mann T, Oviatt SK, Wilson D, Nelson D, Orwoll ES. Vertebral deformity in men. *J Bone Miner Res*. 1992;7(11):1259-1265.
137. Scoles PV, Latimer BM, Digiovanni BF, Vargo E, Bauza S, Jellema LM. Vertebral alterations in Scheuermann's kyphosis. *Spine*. 1991;16(5):509-515.
138. Sørensen KH. *Scheuermann's Juvenile Kyphosis: Clinical Appearances, Radiology, Aetiology, and Prognosis*. Copenhagen: Munksgaard; 1964.

139. Biering-Sorensen F, Hansen FR, Schroll M, Runeborg O. The relation of spinal x-ray to low-back pain and physical activity among 60-year-old men and women. *Spine*. 1985;10(5):445-451.
140. Modic MT, Steinberg PM, Ross JS, Masaryk TJ, Carter JR. Degenerative disk disease: Assessment of changes in vertebral body marrow with MR imaging. *Radiology*. 1988;166(1):193-199.
141. O'Neill TW, McCloskey EV, Kanis JA, et al. The distribution, determinants, and clinical correlates of vertebral osteophytosis: A population based survey. *J Rheumatol*. 1999;26(4):842-848.
142. Nathan H. Osteophytes of the vertebral column. An anatomical study of their development according to age, race, and sex with consideration as to their etiology and significance. *J Bone Joint Surg Am*. 1962;44-A:243-268.
143. Lauridsen KN, De Carvalho A, Andersen AH. Degree of vertebral wedging of the dorso-lumbar spine. *Acta Radiol Diagn (Stockh)*. 1984;25(1):29-32.
144. Burger H, Van Daele PL, Grashuis K, et al. Vertebral deformities and functional impairment in men and women. *J Bone Miner Res*. 1997;12(1):152-157.
145. Goh S, Price RI, Song S, Davis S, Singer KP. Magnetic resonance-based vertebral morphometry of the thoracic spine: Age, gender and level-specific influences. *Clin Biomech (Bristol, Avon)*. 2000;15(6):417-425.
146. Ismail AA, Cooper C, Felsenberg D, et al. Number and type of vertebral deformities: Epidemiological characteristics and relation to back pain and height loss. European Vertebral Osteoporosis Study group. *Osteoporos Int*. 1999;9(3):206-213.
147. Harma M, Heliovaara M, Aromaa A, Knekt P. Thoracic spine compression fractures in finland. *Clin Orthop Relat Res*. 1986;(205):188-194.
148. Frobin W, Brinckmann P, Kramer M, Hartwig E. Height of lumbar discs measured from radiographs compared with degeneration and height classified from MR images. *Eur Radiol*. 2001;11(2):263-269.
149. Lawrence JS, Molyneux MK, Dingwall-Fordyce I. Rheumatism in foundry workers. *Br J Ind Med*. 1966;23(1):42-52.
150. Hult L. Cervical, dorsal and lumbar spinal syndromes; a field investigation of a non-selected material of 1200 workers in different occupations with special reference to disc degeneration and so-called muscular rheumatism. *Acta Orthop Scand Suppl*. 1954;17:1-102.
151. Torgerson WR, Dotter WE. Comparative roentgenographic study of the asymptomatic and symptomatic lumbar spine. *J Bone Joint Surg Am*. 1976;58-A(6):850-853.
152. Lipson SJ, Muir H. Vertebral osteophyte formation in experimental disc degeneration. Morphologic and proteoglycan changes over time. *Arthritis Rheum*. 1980;23(3):319-324.
153. Lawrence JS, de Graaff R, Laine VAI. Degenerative joint disease in random samples and occupational groups. In: Kellgren JH, Jeffrey MR, Ball J, eds. *The Epidemiology of Chronic Rheumatism*. Vol 1. Oxford, UK: Blackwell; 1963:98-119.

154. Yu SW, Houghton VM, Sether LA, Wagner M. Anulus fibrosus in bulging intervertebral disks. *Radiology*. 1988;169(3):761-763.
155. Videman T, Nurminen M, Troup JD. Lumbar spinal pathology in cadaveric material in relation to history of back pain, occupation, and physical loading. *Spine*. 1990;15(8):728-740.
156. Videman T, Nurminen M. The occurrence of annular tears and their relation to lifetime back pain history: A cadaveric study using barium sulfate discography. *Spine*. 2004;29(23):2668-2676.
157. Kjaer P, Leboeuf-Yde C, Korsholm L, Sorensen JS, Bendix T. Magnetic resonance imaging and low back pain in adults: A diagnostic imaging study of 40-year-old men and women. *Spine*. 2005;30(10):1173-1180.
158. Mixer WJ, Barr JS. Rupture of the intervertebral disc with involvement of the spinal canal. *N Engl J Med*. 1934;211:210.
159. Rosenbloom SA. Thoracic disc disease and stenosis. *Radiol Clin North Am*. 1991;29(4):765-775.
160. Arseni C, Nash F. Thoracic intervertebral disc protrusion: A clinical study. *J Neurosurg*. 1960;17:418-430.
161. Arce CA, Dohrmann GJ. Thoracic disc herniation. Improved diagnosis with computed tomographic scanning and a review of the literature. *Surg Neurol*. 1985;23(4):356-361.
162. Otani K, Nakai S, Fujimura Y, Manzoku S, Shibasaki K. Surgical treatment of thoracic disc herniation using the anterior approach. *J Bone Joint Surg Br*. 1982;64-B(3):340-343.
163. Love JG, Schorn VG. Thoracic disk protrusions. *Rheumatism*. 1967;23(1):2-10.
164. Abbott KH, Retter RH. Protrusions of thoracic intervertebral disks. *Neurology*. 1956;6(1):1-10.
165. Logue V. Thoracic intervertebral disc prolapse with spinal cord compression. *J Neurochem*. 1952;15(4):227-241.
166. Love JG, Kiefer EJ. Root pain and paraplegia due to protrusions of thoracic intervertebral disks. *J Neurosurg*. 1950;7(1):62-69.
167. Love JG, Schorn VG. Thoracic-disk protrusions. *JAMA*. 1965;191:627-631.
168. Coventry MB, Ghormley RK, Kernohan JW. The intervertebral disc. Its microscopic anatomy and pathology. Part III: Pathological changes in the intervertebral disc. *J Bone Joint Surg*. 1945;27:460-474.
169. Williams FM, Manek NJ, Sambrook PN, Spector TD, Macgregor AJ. Schmorl's nodes: Common, highly heritable, and related to lumbar disc disease. *Arthritis Rheum*. 2007;57(5):855-860.
170. Chandraraj S, Briggs CA, Opeskin K. Disc herniations in the young and end-plate vascularity. *Clin Anat*. 1998;11(3):171-176.
171. Fahey V, Opeskin K, Silberstein M, Anderson R, Briggs C. The pathogenesis of Schmorl's nodes in relation to acute trauma. an autopsy study. *Spine*. 1998;23(21):2272-2275.

172. Wagner AL, Murtagh FR, Arrington JA, Stallworth D. Relationship of Schmorl's nodes to vertebral body endplate fractures and acute endplate disk extrusions. *AJNR Am J Neuroradiol.* 2000;21(2):276-281.
173. O'Neill TW, Felsenberg D, Varlow J, Cooper C, Kanis JA, Silman AJ. The prevalence of vertebral deformity in European men and women: The European Vertebral Osteoporosis Study. *J Bone Miner Res.* 1996;11(7):1010-1018.
174. Genant HK, Wu CY, van Kuijk C, Nevitt MC. Vertebral fracture assessment using a semiquantitative technique. *J Bone Miner Res.* 1993;8(9):1137-1148.
175. Templin CR, Stambough JB, Stambough JL. Acute spinal cord compression caused by vertebral hemangioma. *Spine J.* 2004;4(5):595-600.
176. Cross JJ, Antoun NM, Laing RJ, Xuereb J. Imaging of compressive vertebral haemangiomas. *Eur Radiol.* 2000;10(6):997-1002.
177. Lecuyer N, Grados F, Dargent-Molina P, Deramond H, Meunier PJ, Fardellone P. Prevalence of Paget's disease of bone and spinal hemangioma in French women older than 75 years: Data from the EPIDOS study. *Joint Bone Spine.* 2000;67(4):315-318.
178. Peh WC, Gilula LA. Percutaneous vertebroplasty: Indications, contraindications, and technique. *Br J Radiol.* 2003;76(901):69-75.
179. Guglielmi G, Andreula C, Muto M, Gilula LA. Percutaneous vertebroplasty: Indications, contraindications, technique, and complications. *Acta Radiol.* 2005;46(3):256-268.
180. Scheuermann H. Kyphosis dorsalis juvenilis. *Ugeskr f Læger.* 1920;9(3):385-393.
181. Wenger DR, Frick SL. Scheuermann kyphosis. *Spine.* 1999;24(24):2630-2639.
182. Ferguson AB, Jr. The etiology of preadolescent kyphosis. *J Bone Joint Surg Am.* 1956;38-A(1):149-157.
183. Lowe TG. Scheuermann's disease. *Orthop Clin North Am.* 1999;30(3):475-87.
184. Bradford DS, Moe JH, Montalvo FJ, Winter RB. Scheuermann's kyphosis. Results of surgical treatment by posterior spine arthrodesis in twenty-two patients. *J Bone Joint Surg Am.* 1975;57-A(4):439-448.
185. Bradford DS, Ahmed KB, Moe JH, Winter RB, Lonstein JE. The surgical management of patients with Scheuermann's disease: A review of twenty-four cases managed by combined anterior and posterior spine fusion. *J Bone Joint Surg Am.* 1980;62-A(5):705-712.
186. Twomey L, Taylor J. Age changes in lumbar intervertebral discs. *Acta Orthop Scand.* 1985;56(6):496-499.
187. Roberts N, Gratin C, Whitehouse GH. MRI analysis of lumbar intervertebral disc height in young and older populations. *J Magn Reson Imaging.* 1997;7(5):880-886.
188. Pfirrmann CW, Metzdorf A, Elfering A, Hodler J, Boos N. Effect of aging and degeneration on disc volume and shape: A quantitative study in asymptomatic volunteers. *J Orthop Res.* 2006;24(5):1086-1094.
189. Rachbauer F, Sterzinger W, Eibl G. Radiographic abnormalities in the thoracolumbar spine of young elite skiers. *Am J Sports Med.* 2001;29(4):446-449.



190. Kulak RF, Schultz AB, Belytschko T, Galante J. Biomechanical characteristics of vertebral motion segments and intervertebral discs. *Orthop Clin North Am.* 1975;6(1):121-133.
191. Awwad EE, Martin DS, Smith KR, Jr. The nuclear trial sign in thoracic herniated disks. *AJNR Am J Neuroradiol.* 1992;13(1):137-143.
192. Linton SJ, Hellsing AL, Hallden K. A population-based study of spinal pain among 35-45-year-old individuals. Prevalence, sick leave, and health care use. *Spine.* 1998;23(13):1457-1463.
193. Linton SJ, Ryberg M. Do epidemiological results replicate? The prevalence and health-economic consequences of neck and back pain in the general population. *Eur J Pain.* 2000;4(4):347-354.
194. Natvig B, Nessiøy I, Bruusgaard D, Rutle O. Musculoskeletal symptoms in a local community. *Eur J Gen Practice.* 1995;1(1):25-28.
195. Guo HR, Chang YC, Yeh WY, Chen CW, Guo YL. Prevalence of musculoskeletal disorder among workers in Taiwan: A nationwide study. *J Occup Health.* 2004;46(1):26-36.
196. Guo HR, Tanaka S, Cameron LL, et al. Back pain among workers in the United States: National estimates and workers at high risk. *Am J Ind Med.* 1995;28(5):591-602.
197. Leboeuf-Yde C, Lauritsen JM. The prevalence of low back pain in the literature. A structured review of 26 Nordic studies from 1954 to 1993. *Spine.* 1995;20(19):2112-2118.
198. Knibbe JJ, Friele RD. Prevalence of back pain and characteristics of the physical workload of community nurses. *Ergonomics.* 1996;39(2):186-198.
199. Cromie JE, Robertson VJ, Best MO. Work-related musculoskeletal disorders and the culture of physical therapy. *Phys Ther.* 2002;82(5):459-472.
200. Bork BE, Cook TM, Rosecrance JC, et al. Work-related musculoskeletal disorders among physical therapists. *Phys Ther.* 1996;76(8):827-835.
201. Merlino LA, Rosecrance JC, Anton D, Cook TM. Symptoms of musculoskeletal disorders among apprentice construction workers. *Appl Occup Environ Hyg.* 2003;18(1):57-64.
202. Olafsdottir H, Rafnsson V. Musculoskeletal symptoms among women currently and formerly working in fish-filleting plants. *Int J Occup Environ Health.* 2000;6(1):44-49.
203. Ratzon NZ, Yaros T, Mizlik A, Kanner T. Musculoskeletal symptoms among dentists in relation to work posture. *Work.* 2000;15(3):153-158.
204. Rosecrance JC, Cook TM, Zimmermann CL. Work-related musculoskeletal symptoms among construction workers in the pipe trades. *Work.* 1996;7:13-20.
205. Torner M, Zetterberg C, Anden U, Hansson T, Lindell V. Workload and musculoskeletal problems: A comparison between welders and office clerks (with reference also to fishermen). *Ergonomics.* 1991;34(9):1179-1196.

206. Zimmermann CL, Cook TM, Rosecrance JC. Operating engineers: Work-related musculoskeletal disorders and the trade. *Appl Occup Environ Hyg.* 1997;12(10):670-680.
207. Osborn JB, Newell KJ, Rudney JD, Stoltenberg JL. Musculoskeletal pain among Minnesota dental hygienists. *J Dent Hyg.* 1990;64(3):132-138.
208. Torp S, Riise T, Moen BE. Work-related musculoskeletal symptoms among car mechanics: A descriptive study. *Occup Med (Lond).* 1996;46(6):407-413.
209. Brattberg G, Thorslund M, Wikman A. The prevalence of pain in a general population. The results of a postal survey in a county of Sweden. *Pain.* 1989;37(2):215-222.
210. Shugars D, Miller D, Williams D, Fishburne C, Strickland D. Musculoskeletal pain among general dentists. *Gen Dent.* 1987;35(4):272-276.
211. Van der Linden SM, Fahrer H. Occurrence of spinal pain syndromes in a group of apparently healthy and physically fit sportsmen (orienteers). *Scand J Rheumatol.* 1988;17(6):475-481.
212. Niedhammer I, Lert F, Marne MJ. Back pain and associated factors in French nurses. *Int Arch Occup Environ Health.* 1994;66(5):349-357.
213. Horal J. The clinical appearance of low back disorders in the city of Gothenburg, Sweden. Comparisons of incapacitated probands with matched controls. *Acta Orthop Scand Suppl.* 1969;118:1-109.
214. Croft P, Dunn KM, Von Korff M. Chronic pain syndromes: You can't have one without another. *Pain.* 2007;131(3):237-238.
215. Australian and New Zealand College of Anaesthetists and Faculty of Pain Medicine. *Acute Pain Management: Scientific Evidence.* Second Edition ed. Australian Government National Health and Medical Research Council; 2005:309.
216. Siddall PJ, Cousins MJ. Spinal pain mechanisms. *Spine.* 1997;22(1):98-104.
217. Wyke B. The neurological basis of thoracic spinal pain. *Rheumatol Phys Med.* 1970;10(7):356-367.
218. Cavanaugh JM. Neural mechanisms of lumbar pain. *Spine.* 1995;20(16):1804-1809.
219. Cavanaugh JM, Ozaktay AC, Yamashita T, Avramov A, Getchell TV, King AI. Mechanisms of low back pain: A neurophysiologic and neuroanatomic study. *Clin Orthop Relat Res.* 1997;(335):166-180.
220. Jacques A. Physiology of pain. *Br J Nurs.* 1994;3(12):607-610.
221. Waxman SG. *Clinical Neuroanatomy.* 25th ed. New York, N.Y.: Lange Medical Books/McGraw-Hill; 2003.
222. Moseley GL. A pain neuromatrix approach to patients with chronic pain. *Man Ther.* 2003;8(3):130-140.
223. Ashton IK, Ashton BA, Gibson SJ, Polak JM, Jaffray DC, Eisenstein SM. Morphological basis for back pain: The demonstration of nerve fibers and neuropeptides in the lumbar facet joint capsule but not in ligamentum flavum. *J Orthop Res.* 1992;10(1):72-78.
224. Ahmed M, Bjurholm A, Kreicbergs A, Schultzberg M. Sensory and autonomic innervation of the facet joint in the rat lumbar spine. *Spine.* 1993;18(14):2121-2126.

225. Pedersen HE, Blunck CF, Gardner E. The anatomy of lumbosacral posterior rami and meningeal branches of spinal nerve (sinu-vertebral nerves); with an experimental study of their functions. *J Bone Joint Surg Am.* 1956;38-A(2):377-391.
226. Jackson HC, 2nd, Winkelmann RK, Bickel WH. Nerve endings in the human lumbar spinal column and related structures. *J Bone Joint Surg Am.* 1966;48-A(7):1272-1281.
227. Mendel T, Wink CS, Zimny ML. Neural elements in human cervical intervertebral discs. *Spine.* 1992;17(2):132-135.
228. Yoshizawa H, O'Brien JP, Smith WT, Trumper M. The neuropathology of intervertebral discs removed for low-back pain. *J Pathol.* 1980;132(2):95-104.
229. Groen GJ, Stolker RJ. Thoracic neural anatomy. In: Giles LGF, Singer KP, eds. *Clinical Anatomy and Management of Thoracic Spine Pain.* 1st ed. Oxford, UK: Butterworth-Heinemann; 2000:114-141.
230. Freemont AJ, Peacock TE, Goupille P, Hoyland JA, O'Brien J, Jayson MI. Nerve ingrowth into diseased intervertebral disc in chronic back pain. *Lancet.* 1997;350(9072):178-181.
231. Coppes MH, Marani E, Thomeer RT, Groen GJ. Innervation of "painful" lumbar discs. *Spine.* 1997;22(20):2342-2349.
232. Coppes MH, Marani E, Thomeer RT, Oudega M, Groen GJ. Innervation of annulus fibrosis in low back pain. *Lancet.* 1990;336(8708):189-190.
233. Palmgren T, Gronblad M, Virri J, Seitsalo S, Ruuskanen M, Karaharju E. Immunohistochemical demonstration of sensory and autonomic nerve terminals in herniated lumbar disc tissue. *Spine.* 1996;21(11):1301-1306.
234. Weinstein J, Claverie W, Gibson S. The pain of discography. *Spine.* 1988;13(12):1344-1348.
235. Vanharanta H, Sachs BL, Spivey MA, et al. The relationship of pain provocation to lumbar disc deterioration as seen by CT/discography. *Spine.* 1987;12(3):295-298.
236. Moneta GB, Videman T, Kaivanto K, et al. Reported pain during lumbar discography as a function of annular ruptures and disc degeneration. A re-analysis of 833 discograms. *Spine.* 1994;19(17):1968-1974.
237. Aprill C, Bogduk N. High-intensity zone: A diagnostic sign of painful lumbar disc on magnetic resonance imaging. *Br J Radiol.* 1992;65(773):361-369.
238. Luoma K, Riihimaki H, Luukkonen R, Raininko R, Viikari-Juntura E, Lamminen A. Low back pain in relation to lumbar disc degeneration. *Spine.* 2000;25(4):487-492.
239. Mooney V, Brown M, Modic M. Clinical perspectives. In: Frymoyer JW, Gordon SL, eds. *New Perspectives on Low Back Pain.* Chicago, IL: AAOS; 1989:133-146.
240. Kuslich SD, Ulstrom CL, Michael CJ. The tissue origin of low back pain and sciatica: A report of pain response to tissue stimulation during operations on the lumbar spine using local anesthesia. *Orthop Clin North Am.* 1991;22(2):181-187.
241. Bobechko WP, Hirsch C. Auto-immune response to nucleus pulposus in the rabbit. *J Bone Joint Surg Br.* 1965;47:574-580.

242. Olmarker K, Rydevik B, Nordborg C. Autologous nucleus pulposus induces neurophysiologic and histologic changes in porcine cauda equina nerve roots. *Spine*. 1993;18(11):1425-1432.
243. Olmarker K, Nordborg C, Larsson K, Rydevik B. Ultrastructural changes in spinal nerve roots induced by autologous nucleus pulposus. *Spine*. 1996;21(4):411-414.
244. McCarron RF, Wimpee MW, Hudkins PG, Laros GS. The inflammatory effect of nucleus pulposus. A possible element in the pathogenesis of low-back pain. *Spine*. 1987;12(8):760-764.
245. Pankovich AM, Korngold L. A comparison of the antigenic properties of nucleus pulposus and cartilage protein polysaccharide complexes. *J Immunol*. 1967;99(2):431-437.
246. Famaey JP. Phospholipases, eicosanoid production and inflammation. *Clin Rheumatol*. 1982;1(2):84-94.
247. Greaves MW, Camp RD. Prostaglandins, leukotrienes, phospholipase, platelet activating factor, and cytokines: An integrated approach to inflammation of human skin. *Arch Dermatol Res*. 1988;280(Suppl):S33-41.
248. Chang J, Gilman SC, Lewis AJ. Interleukin 1 activates phospholipase A2 in rabbit chondrocytes: A possible signal for IL 1 action. *J Immunol*. 1986;136(4):1283-1287.
249. Saal JS. The role of inflammation in lumbar pain. *Spine*. 1995;20(16):1821-1827.
250. Saal JS, Franson RC, Dobrow R, Saal JA, White AH, Goldthwaite N. High levels of inflammatory phospholipase A2 activity in lumbar disc herniations. *Spine*. 1990;15(7):674-678.
251. Kang JD, Georgescu HI, McIntyre-Larkin L, Stefanovic-Racic M, Evans CH. Herniated cervical intervertebral discs spontaneously produce matrix metalloproteinases, nitric oxide, interleukin-6, and prostaglandin E2. *Spine*. 1995;20(22):2373-2378.
252. Liu J, Roughley PJ, Mort JS. Identification of human intervertebral disc stromelysin and its involvement in matrix degradation. *J Orthop Res*. 1991;9(4):568-575.
253. Marshall LL, Trethewie ER. Chemical irritation of nerve-root in disc prolapse. *Lancet*. 1973;2(7824):320.
254. Melrose J, Ghosh P, Taylor TK, Andrews JL. The serine proteinase inhibitory proteins of the human intervertebral disc: Their isolation, characterization and variation with ageing and degeneration. *Matrix*. 1992;12(6):456-470.
255. Sedowofia KA, Tomlinson IW, Weiss JB, Hilton RC, Jayson MI. Collagenolytic enzyme systems in human intervertebral disc: Their control, mechanism, and their possible role in the initiation of biomechanical failure. *Spine*. 1982;7(3):213-222.
256. Wehling P, Evans CH, Schulitz KP. The interaction between synovial cytokines and peripheral nerve function: A potential element in the development of radicular syndrome. *Z Orthop Ihre Grenzgeb*. 1990;128(5):442-446.
257. Rang HP, Bevan S, Dray A. Chemical activation of nociceptive peripheral neurones. *Br Med Bull*. 1991;47(3):534-548.

258. Korkala O, Gronblad M, Liesi P, Karaharju E. Immunohistochemical demonstration of nociceptors in the ligamentous structures of the lumbar spine. *Spine*. 1985;10(2):156-157.
259. Lotz M, Vaughan JH, Carson DA. Effect of neuropeptides on production of inflammatory cytokines by human monocytes. *Science*. 1988;241(4870):1218-1221.
260. Brisby H. Pathology and possible mechanisms of nervous system response to disc degeneration. *J Bone Joint Surg Am*. 2006;88-A(Suppl 2):68-71.
261. Garfin SR, Rydevik B, Lind B, Massie J. Spinal nerve root compression. *Spine*. 1995;20(16):1810-1820.
262. Wiesel SW, Tsourmas N, Feffer HL, Citrin CM, Patronas N. A study of computer-assisted tomography. I. The incidence of positive CAT scans in an asymptomatic group of patients. *Spine*. 1984;9(6):549-551.
263. Rydevik B, Brown MD, Lundborg G. Pathoanatomy and pathophysiology of nerve root compression. *Spine*. 1984;9(1):7-15.
264. Merskey H, Bogduk N, eds. *Classification of Chronic Pain. Descriptions of Chronic Pain Syndromes and Definitions of Pain Terms*. 2nd ed. Seattle, WA: IASP Press; 1994.
265. Australian Acute Musculoskeletal Pain Guidelines Group. Acute thoracic spinal pain. In: *Evidence-Based Management of Acute Musculoskeletal Pain* (Available at: <http://www.nhmrc.gov.au>). Brisbane, Australia: Australian Academic Press; 2003:63-82.
266. Doherty GM. The acute abdomen. In: Doherty GM, Way LW, eds. *Current Surgical Diagnosis and Treatment*. 12th ed. Los Altos, C.A.: Lange Medical Publications; 2006:479-492.
267. Levitt MD. Approach to the patient with abdominal pain. In: Kelley WN, ed. *Textbooks of Internal Medicine*. Vol 1. 3rd ed. Philadelphia, PA: Lippincott-Raven; 1997:593-599.
268. Jänig W, Morrison JFB. Functional properties of spinal visceral afferents supplying abdominal and pelvic organs, with special emphasis on visceral nociception. In: Cervero F, Morrison JFB, eds. *Progress in Brain Research: Visceral Sensation*. Vol 67. 1st ed. Amsterdam, The Netherlands: Elsevier; 1986:87-114.
269. Singer KP. Pathology of the thoracic spine. In: Giles LGF, Singer KP, eds. *Volume 2: Clinical Anatomy and Management of Thoracic Spine Pain*. 1st ed. Oxford, UK: Butterworth-Heinemann; 2000:63-82.
270. Eriksen HR, Ursin H. Subjective health complaints, sensitization, and sustained cognitive activation (stress). *J Psychosom Res*. 2004;56(4):445-448.
271. Meeus M, Nijs J. Central sensitization: A biopsychosocial explanation for chronic widespread pain in patients with fibromyalgia and chronic fatigue syndrome. *Clin Rheumatol*. 2007;26(4):465-473.
272. Dubner R, Ruda MA. Activity-dependent neuronal plasticity following tissue injury and inflammation. *Trends Neurosci*. 1992;15(3):96-103.
273. Woolf CJ. Evidence for a central component of post-injury pain hypersensitivity. *Nature*. 1983;306(5944):686-688.

274. Li J, Simone DA, Larson AA. Windup leads to characteristics of central sensitization. *Pain*. 1999;79(1):75-82.
275. Yunus MB. Role of central sensitization in symptoms beyond muscle pain, and the evaluation of a patient with widespread pain. *Best Pract Res Clin Rheumatol*. 2007;21(3):481-497.
276. Crook J, Rideout E, Browne G. The prevalence of pain complaints in a general population. *Pain*. 1984;18(3):299-314.
277. Salminen JJ, Erkintalo M, Laine M, Pentti J. Low back pain in the young. A prospective three-year follow-up study of subjects with and without low back pain. *Spine*. 1995;20(19):2101-2107.
278. Engel GL. The need for a new medical model: A challenge for biomedicine. *Science*. 1977;196(4286):129-136.
279. Kendall NA. Psychosocial approaches to the prevention of chronic pain: The low back paradigm. *Baillieres Best Pract Res Clin Rheumatol*. 1999;13(3):545-554.
280. Main CJ, Waddell G. Beliefs about back pain. In: Waddell G, ed. *The Back Pain Revolution*. 2nd ed. Edinburgh, Scotland: Churchill Livingstone; 1998:221-240.
281. Burton K, Waddell G. Risk factors for back pain. In: Waddell G, ed. *The Back Pain Revolution*. 2nd ed. Edinburgh, Scotland: Churchill Livingstone; 1998:91-113.
282. Andersson GB. Epidemiological features of chronic low-back pain. *Lancet*. 1999;354(9178):581-585.
283. Davis KG, Heaney CA. The relationship between psychosocial work characteristics and low back pain: Underlying methodological issues. *Clin Biomech (Bristol, Avon)*. 2000;15(6):389-406.
284. Andersson, G. B. J. The epidemiology of spinal disorders. In: Frymoyer JW, ed. *The Adult Spine: Principles and Practice*. Vol 1. 1st ed. New York, NY: Raven Press; 1991:107-146.
285. Carragee E. Self-reported back pain severity can vary with social context: A study of back pain in peacetime and wartime US army reserve soldiers performing the same duty. Proceedings of the 34<sup>th</sup> Annual meeting of the International Society for the Study of Lumbar Spine, Hong Kong, June 10th-14<sup>th</sup>, 2007:95.
286. van Tulder MW, Assendelft WJ, Koes BW, Bouter LM. Spinal radiographic findings and nonspecific low back pain. A systematic review of observational studies. *Spine*. 1997;22(4):427-434.
287. Luoma K, Riihimaki H, Raininko R, Luukkonen R, Lamminen A, Viikari-Juntura E. Lumbar disc degeneration in relation to occupation. *Scand J Work Environ Health*. 1998;24(5):358-366.
288. Boos N, Rieder R, Schade V, Spratt KF, Semmer N, Aebi M. the diagnostic accuracy of magnetic resonance imaging, work perception, and psychosocial factors in identifying symptomatic disc herniations. *Spine*. 1995;20(24):2613-2625.
289. Weishaupt D, Zanetti M, Hodler J, Boos N. MR imaging of the lumbar spine: Prevalence of intervertebral disk extrusion and sequestration, nerve root compression, end plate abnormalities, and osteoarthritis of the facet joints in asymptomatic volunteers. *Radiology*. 1998;209(3):661-666.

290. Jensen MC, Brant-Zawadzki MN, Obuchowski N, Modic MT, Malkasian D, Ross JS. Magnetic resonance imaging of the lumbar spine in people without back pain. *N Engl J Med*. 1994;331(2):69-73.
291. Stadnik TW, Lee RR, Coen HL, Neiryck EC, Buisseret TS, Osteaux MJ. Annular tears and disk herniation: Prevalence and contrast enhancement on MR images in the absence of low back pain or sciatica. *Radiology*. 1998;206(1):49-55.
292. Pye SR, Reid DM, Smith R, et al. Radiographic features of lumbar disc degeneration and self-reported back pain. *J Rheumatol*. 2004;31(4):753-758.

## **CHAPTER 3: STUDY SUBJECTS AND THORACIC MRI VARIABLES**

### **SUBJECT CHARACTERISTICS AND REPRESENTATIVENESS**

The subjects of this thesis are part of the Twin Spine Study to which the subjects were selected from the Finnish Twin Cohort. The Finnish Twin Cohort contains all sex-matched Finnish twin pairs born before 1958 and alive in 1975, including 13,888 male pairs of known zygosity.<sup>1,2</sup> Two extensive questionnaires in 1975 and 1981 obtained information from the subjects in the Finnish Twin Cohort on health-related variables, including occupational exposures. The overall response rates were 89% and 84%.<sup>3,4</sup> The questionnaire was also used to determine zygosity, which was based on the answers of both members of a twin pair to two questions on similarity and confusion in childhood.<sup>5</sup> The correct classification of zygosity from the questionnaires was found to be 100% in a sub-sample of 104 pairs as determined by eleven blood markers with an estimated probability of misclassification of 1.7% at the population level.<sup>5</sup> The zygosity of the twins in the Twin Spine Study sample has since been confirmed by DNA analyses.

Subjects for the Twin Spine Study (TSS), which were used in this thesis, were selected from the Finnish Twin Cohort to investigate the role of suspected risk factors for common musculoskeletal problems. Twin pairs with consistent discordance between co-twins in common environmental and behavioural exposures (occupational materials handling, sedentary work, exercise participation and vehicular vibration) as determined from the 1975 and 1981 questionnaires were invited to participate in the TSS.<sup>3</sup> In the first stage of the selection process, monozygotic (MZ) twin pairs were selected from the total of 2050 MZ pairs,<sup>6</sup> and of the pairs asked to participate 82% (117 pairs) volunteered. History of back pain was not considered in the selection process.<sup>3</sup> In the second stage of the selection process, 117 dizygotic (DZ) twin pairs were selected based on an identical process to that of the MZ pairs. In addition, randomly selected MZ and DZ pairs<sup>7</sup> were added to increase the sample to 600 male twins (152 MZ and 148 DZ pairs) aged 35 to 70 years. The response rate was 71.8% for the total sample of 300 male twin pairs. It was these 600 subjects that were included in the research of this thesis.



The number of exposure-discordant twin studies has increased manifold in the last decade. The strength of such twin studies is the increased level of matching between subjects.<sup>8</sup> However, as in this thesis, twin status can also be ignored to use the twin population as an ordinary non-twin sample, as long as the representativeness to the general population is examined<sup>9</sup> and the dependence of the co-twin data is adjusted for in the statistical analyses. The representativeness of the twins used in this thesis was previously examined by comparing the sample of MZ twins from the TSS to the Finnish Twin Cohort including extensive, periodically-collected data from the entire Cohort, which is representative of the Finnish population.<sup>4</sup>

No significant differences for a history of work-incapacitating neck, shoulder or back pain, or a history of sciatica were observed when MZ subjects were compared to the Finnish Twin Cohort. Also, no significant differences between the MZ subjects and the Finnish Twin Cohort have been found for the amount smoked per day, life-satisfaction scales, level of education, level of leisure time physical activity, outdoor and indoor work, shift work, work monotony, health behaviour, occupational category and social class. The only significant differences between the subjects and the referents were for current work status and physical loading at work. Subjects were more likely to be employed and working in more physically-demanding jobs than the referents.<sup>10</sup> Further, no statistically significant differences between the DZ subjects in this thesis were found when compared to the MZ subjects, which had been shown to be representative of the Finnish Twin Cohort. Thus, the subjects appear to be highly representative of the population from which they were drawn (Finnish men). However, differences in factors that were not measured cannot be ruled out, which may potentially affect the representativeness of the sample and generalizability of the results to the broader population.

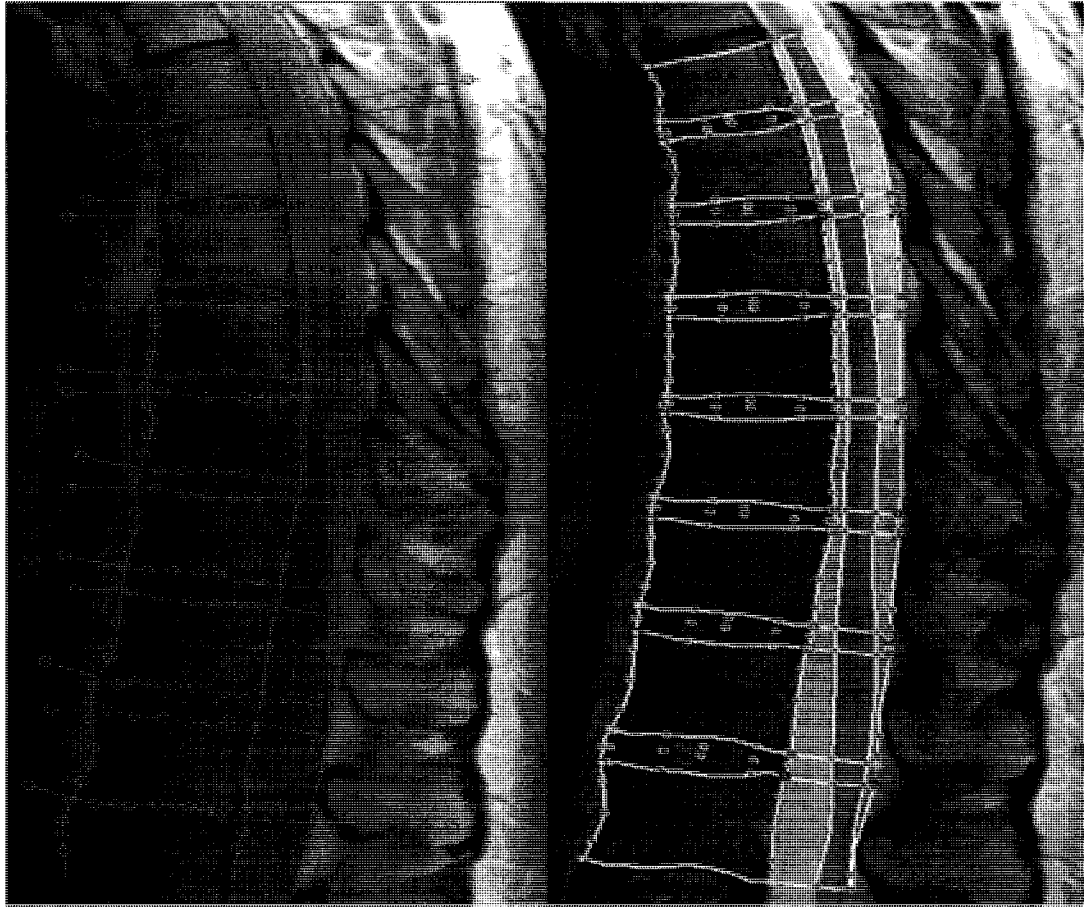
## **DATA ACQUISITION FROM THE MR IMAGES**

*Imaging.* Two 1.5 Tesla scanners (Magnetom or Vision, Siemens AG, Germany) with surface coils were used to acquire sagittal T2- and PD-weighted images of the thoracic spine including T6-T12 levels. Spin-echo (SE) sequences for the Magnetom scanner were 2600/22-90 with a slice thickness of 4 mm and slice gaps of 0.4 mm. The matrix was 256 x 256 and field of view (FOV) 260 mm. Corresponding settings for the Vision scanner

were SE sequences of 3500/20-120, slice thickness of 4 mm and slice gaps of 0.4 mm. The matrix was 512 x 512 and FOV 254 x 290mm. Other differences between scanners, which may have had implication on disc signal measurements, existed for coils (Magnetom had a single loop coil and Vision a 4-element phased array coil) and gradient strength (10 mT/m for Magnetom and 25 mT/m for Vision). Before imaging the subjects spent at least 30 minutes lying down to recover possible fluid loss from the disc.<sup>11,12</sup>

*Quantitative data acquisition.* Custom-made image analysis software (SpEx<sup>®</sup> version 2.63, Edmonton, Canada) was used to acquire quantitative data on MRI findings from T6 through T12 vertebrae. Regions of interest were manually traced from mid-sagittal sections. Mid-sagittal images were determined from the presence of spinous processes and clear demarcation of the spinal cord.<sup>13</sup> It is recognized that due to the use of only mid-sagittal sections the findings occurring laterally were missed.

First, the contours of the thoracic structures, including discs, vertebrae and spinal canal, were segmented manually on the mid-sagittal PD-weighted image. The contour of the vertebrae and discs were vertically segmented by following the anterior and posterior longitudinal ligaments which could clearly be seen. However, the lack of contrast did not allow the annulus of the disc and the ligaments to be distinguished at the disc level. To segment the disc from the vertebra, the boundary between the vertebral bone and the endplate was followed. The segmentation was then transferred onto the T2-weighted image to complete the manual segmentation by outlining the spinal cord and making necessary adjustments to the original segmentation. (Figure 3-1.) The regions of interest were formed by the intersections of the segmentation lines corresponding to the discs, vertebrae, spinal canal and spinal cord from which the measurements were derived. All distance measurements were further transformed into actual distances (mm) by multiplying the distance in pixels by the size of the pixel.



**Figure 3-1.** The manual segmentation in the PD-weighted image (left) of the thoracic discs, vertebrae and spinal canal. The segmentation was completed in the T2-weighted image (right) where spinal cord was outlined and necessary adjustments to the original segmentation were made before obtaining the measurements.

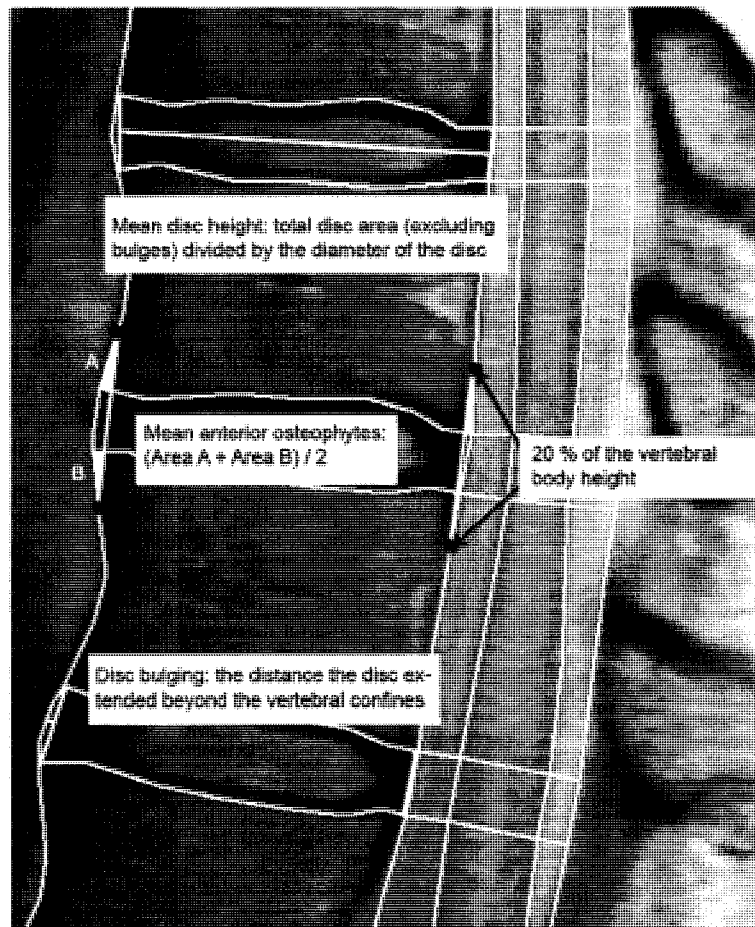
The following variables were created from the segmented images:

*Disc signal* measurements were adjusted by the signal of the adjacent spinal cord.

*Mean disc height* was measured by calculating the total area of the disc excluding bulging beyond the vertebral confines and dividing the area by the anterior-posterior diameter of the disc (Figure 3-2).

*Disc bulging* was measured as the distance a bulge extended beyond the vertebral confines; distances up to a pixel were considered to represent no bulging (Figure 3-2).

*Osteophyte areas* were measured by connecting the points located on the vertebral body wall, 20% of the vertebral body height above and below the disc, anteriorly and posteriorly ('theoretical corners'). The areas formed were then measured to obtain the area measurements for anterior and posterior osteophytes.<sup>14</sup> (Figure 3-2.)

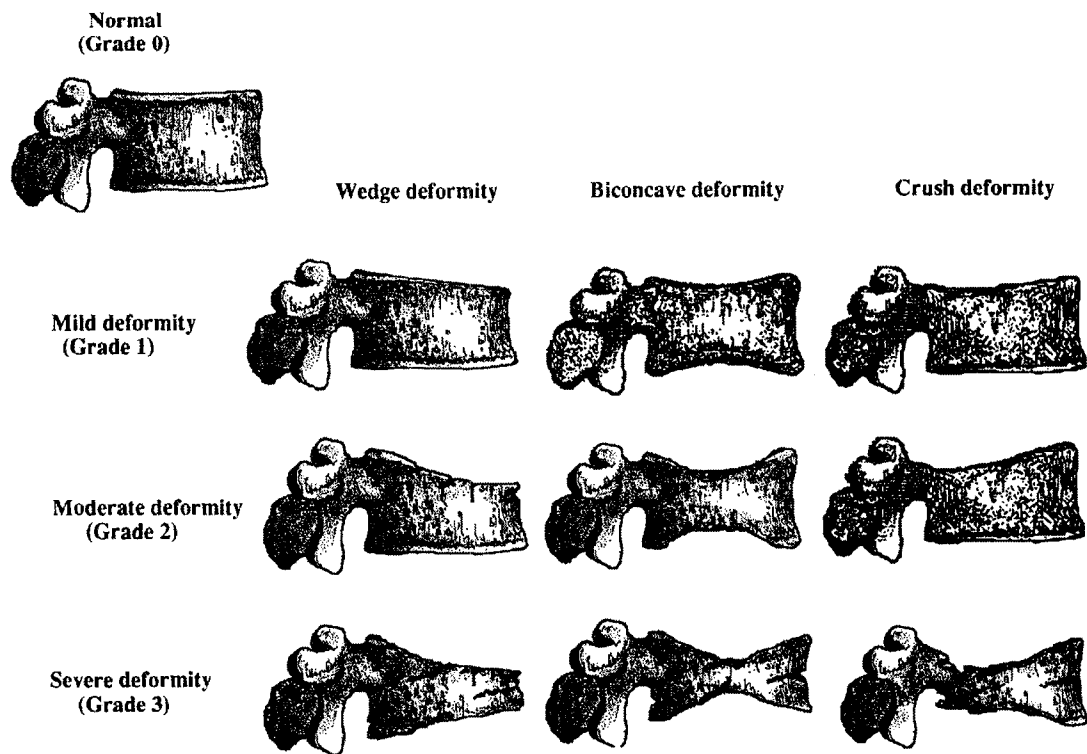


**Figure 3-2.** The acquisition of mean disc height, osteophyte and disc bulging measurements.

*Wedging of the vertebrae* was measured from the angle formed by the vertebral endplates.

*Scheuermann's disease* was determined using the original diagnostic criterion by Sørensen<sup>15</sup> of three or more consecutive wedged vertebrae of 5 degrees or more.

In addition to the quantitative measurements, the presence of vertebral deformities and hemangiomas was assessed qualitatively. *Vertebral deformities and their severity* were assessed using a technique by Genant et al.<sup>16</sup> where vertebrae were graded based on a visual inspection and without direct vertebral measurement as normal, mildly, moderately and severely deformed. Mild deformity (grade 1) was graded based on approximately 20-25% reduction in anterior, middle and/or posterior height and a reduction of area of 10-20%. Moderately deformed (grade 2) vertebra had approximately 25-40% reduction in any height and 20-40% reduction in area whereas for severe deformity (grade 3) the reductions were 40% reduction in any height and area.<sup>16</sup> (Figure 3-3.) Additionally, if unsure about the amount of reduction in the heights, the height was further quantitatively-measured to determine the grade of deformity.



**Figure 3-3.** Semiquantitative visual grading of vertebral deformities.<sup>16</sup> (Reprinted with permission from the American Society for Bone and Mineral Research)

*Hemangioma* was considered to be present if a hyperintense circular spot was observed in the vertebral body on both PD- and T2-weighted images.<sup>17</sup>

Other *qualitative assessments* of degenerative findings, including disc height narrowing and bulging, and endplate irregularities, were performed by a spine surgeon. Each MRI finding was rated using a scale from 0 to 3 with 0 being normal and 1-3 representing progressive degrees of severity using the three middle sections (Table 3-1).

**Table 3-1.** Grading scale for qualitative assessments of the thoracic MRI findings.<sup>18</sup>

Variable	
Disc height	0: Normal –typically disc higher than the upper disc 1: Slight –disc as high as the upper disc if it is normal 2: Moderate – Disc narrower than the upper disc if it is normal 3: Severe – endplates almost in contact
Upper and lower endplates Schmorl’s nodes	0: None present 1: Slight defect (1-5 mm) 2: Moderate defect (5-10 mm) 3: Severe defect (>10 mm)
Disc bulging	0: None –normal contour of the disc 1: Slight –approximately 1.5 ± 1 mm 2: Moderate –approximately 3.5 ± 1 mm 3: Severe - ≥ 4.5 mm

*The reliability of the quantitative measurements and qualitative assessments*

The reliability of quantitative measurements was examined in a randomly selected sample of thirty subjects. The website <http://www.mdani.demon.co.uk/para/random.htm> was used to create the list of thirty subjects. Both intraobserver and interobserver reliabilities were assessed using the intraclass correlation coefficient (ICC, model 2) (Table 3-2). The second observer for the reliability study was a spine researcher with extensive experience working with the image analysis software. The principles for manual segmentation were discussed between the observers before initiation of the segmentation process. The process was blinded to any additional subject information and observers did not have access to each other’s measurements. The reliability was calculated as mean reliability. Values greater than 0.75 are generally interpreted as indicating excellent agreement, values between 0.40 to 0.75 fair to good agreement and below 0.40 poor agreement.<sup>19</sup>

**Table 3-2.** Reliability of the measurements.

	Intra	Inter
Disc signal	0.98	0.97
Disc height	0.91	0.88
Osteophytes anterior / posterior	0.66 / 0.65	0.56 / 0.50
Vertebral wedging	0.82	0.54

Due to the low prevalence of disc bulging, especially posterior bulges, it was not possible to calculate ICC or Kappa coefficients. Kappa coefficients can give erroneously low values if the prevalence is low.<sup>20</sup> Also, a certain amount of variability among subjects' measures is required for the ICC to be able to assess reliability.<sup>21,22</sup> In other words, if the subjects vary little in their measurements (a homogeneous sample), the ICC tends to be low.<sup>22</sup> This is because the calculation of ICC involves comparing the variance among subjects to the total variance (including variability between observers and random error).<sup>21,22</sup> As a result, the actual limits of the ICC may not match the theoretical limits of 0 and 1.<sup>21</sup>

The observer reliability of quantitative measurements of bulging was examined by looking at the agreement between observers for separating bulging from no bulging. For anterior bulging, the interobserver agreement was 84% and for posterior bulging 97%. A disagreement in the determination of presence or absence of anterior bulging was present in twenty-five of 152 discs assessed. For all, but two, of the 25 discs read as bulging by one observer and not the other, the bulging distances were only three pixels or less. No posterior bulging was indicated from the segmentations of one observer and the other was in agreement with the exception of four discs where the bulging distance was only two pixels. The intraobserver agreements were 96% and 99% for anterior and posterior bulging.

The interobserver reliability of qualitative assessments has been examined before and has generally been found to be poor. Depending on the spinal level, the ICC for interobserver reliability ranged from 0.22 to 0.40 for disc height narrowing, 0.47 to 0.56 for disc bulging, 0.57 to 0.66 for upper endplate irregularities, and 0.24 to 0.33 for lower endplate irregularities.<sup>23</sup> From the same data, the intraobserver reliability was determined using repeat assessments by the same clinician in a sample of twenty subjects. Intraobserver reliability (ICC, model 2) was higher than the interobserver; 0.70 for disc height narrowing, 0.77 for upper endplate irregularities, and 0.77 and 1 for anterior and posterior bulging, respectively. Only four discs out of 120 were read as mild posterior bulges on both occasions. Unfortunately, due to the lack of findings, the reliability for lower endplate irregularities could not be assessed.

## REFERENCES

1. Kaprio J, Koskenvuo M, Langinvainio H, Romanov K, Sarna S, Rose RJ. Genetic influences on use and abuse of alcohol: A study of 5638 adult Finnish twin brothers. *Alcohol Clin Exp Res*. 1987;11(4):349-356.
2. Kaprio J, Verkasalo PK, Koskenvuo M. Sample selection and outcome definition in twin studies: Experiences from the Finnish twin cohort study. In: Spector TD, Snieder H, MacGregor AJ, eds. *Advances in Twin and Sib-Pair Analysis*. 1st ed. London, UK: Greenwich Medical Media Ltd.; 2000:24-34.
3. Battie MC, Videman T, Gibbons LE, Fisher LD, Manninen H, Gill K. Determinants of lumbar disc degeneration. A study relating lifetime exposures and magnetic resonance imaging findings in identical twins. *Spine*. 1995;20(24):2601-2612.
4. Kaprio J, Koskenvuo M, Artimo M, Sarna S, Rantasalo I. *The Finnish Twin Registry: Baseline Characteristics. Section I: Materials, Methods, Representativeness and Results for Variables Special to Twin Studies*. Helsinki, Finland: Kansanterveyslaitoksen julkaisu M47; 1979.
5. Sarna S, Kaprio J, Sistonen P, Koskenvuo M. Diagnosis of twin zygosity by mailed questionnaire. *Hum Hered*. 1978;28(4):241-254.
6. Battie MC, Videman T, Gill K, et al. Smoking and lumbar intervertebral disc degeneration: An MRI study of identical twins. *Spine*. 1991;16(9):1015-1021.
7. Simonen R, Levalahti E, Kaprio J, Videman T, Battie MC. Multivariate genetic analysis of lifetime exercise and environmental factors. *Med Sci Sports Exerc*. 2004;36(9):1559-1566.
8. Cederlof R, Friberg L, Lundman T. The interactions of smoking, environment and heredity and their implications for disease etiology. A report of epidemiological studies on the Swedish twin registries. *Acta Med Scand Suppl*. 1977;612:1-128.
9. Cederlof R, Rantasalo I, Floderus-Myrhed B, et al. A cross-national epidemiological resource: The Swedish and Finnish cohort studies of like-sexed twins. *Int J Epidemiol*. 1982;11(4):387-390.
10. Simonen RL, Videman T, Kaprio J, Levalahti E, Battie MC. Factors associated with exercise lifestyle--a study of monozygotic twins. *Int J Sports Med*. 2003;24(7):499-505.
11. Boos N, Wallin A, Gbedegbegnon T, Aebi M, Boesch C. Quantitative MR imaging of lumbar intervertebral disks and vertebral bodies: Influence of diurnal water content variations. *Radiology*. 1993;188(2):351-354.
12. Botsford DJ, Esses SI, Ogilvie-Harris DJ. In vivo diurnal variation in intervertebral disc volume and morphology. *Spine*. 1994;19(8):935-940.
13. Goh S, Tan C, Price RI, et al. Influence of age and gender on thoracic vertebral body shape and disc degeneration: An MR investigation of 169 cases. *J Anat*. 2000;197(4):647-657.
14. Harada A, Okuizumi H, Miyagi N, Genda E. Correlation between bone mineral density and intervertebral disc degeneration. *Spine*. 1998;23(8):857-861.
15. Sørensen KH. *Scheuermann's Juvenile Kyphosis: Clinical Appearances, Radiology, Aetiology, and Prognosis*. Copenhagen: Munksgaard; 1964.



16. Genant HK, Wu CY, van Kuijk C, Nevitt MC. Vertebral fracture assessment using a semiquantitative technique. *J Bone Miner Res*. 1993;8(9):1137-1148.
17. Garfin SR, Vaccaro AR, eds. *Orthopaedic Knowledge Update: Spine*. 1st ed. Rosemont, IL: American Academy of Orthopaedic Surgeons; 1997.
18. Videman T, Battie MC, Ripatti S, Gill K, Manninen H, Kaprio J. Determinants of the progression in lumbar degeneration: A 5-year follow-up study of adult male monozygotic twins. *Spine*. 2006;31(6):671-678.
19. Fleiss JL. *Statistical Methods for Rates and Proportions*. Revised ed. New York, United States of America: John Wiley & Sons, Inc; 1981.
20. Feinstein AR, Cicchetti DV. High agreement but low kappa: I. The problems of two paradoxes. *J Clin Epidemiol*. 1990;43(6):543-549.
21. Portney LG, Watkins MP. *Foundations of Clinical Research. Applications to Practice*. 2nd ed. Upper Saddle River, NJ: Prentice-Hall; 2000.
22. Deyo RA, Diehr P, Patrick DL. Reproducibility and responsiveness of health status measures. Statistics and strategies for evaluation. *Control Clin Trials*. 1991;12(4Suppl):142S-158S.
23. Raininko R, Manninen H, Battie MC, Gibbons LE, Gill K, Fisher LD. Observer variability in the assessment of disc degeneration on magnetic resonance images of the lumbar and thoracic spine. *Spine*. 1995;20(9):1029-1035.

## **CHAPTER 4: PREVALENCE AND CHARACTERISTICS OF UPPER OR MID-BACK PAIN IN FINNISH MEN**

(Published in *Spine* 2006; 31(16):1846-1849)

### **INTRODUCTION**

Back pain is a subjective symptom of clinical importance as it often motivates patients to seek health care, causes disability, and affects quality of life.<sup>1</sup> General population studies are scarce, and most of the studies on prevalence or incidence of back pain have focused on investigations of particular professions or working conditions.<sup>2</sup> Also, epidemiologic studies of back pain have mainly focused on low-back pain, and relatively little research has been reported on upper or mid-back (thoracic) pain. In the literature, the 1-year prevalence of self-reported upper or mid-back pain in specific occupational groups varies between 2.6%<sup>3</sup> and 41.0%.<sup>4</sup> In studies of the general population or general workforce, both of which are fewer in number, the 1-year prevalence varies from 4.4% to 30.6%.<sup>5-9</sup> However, to our knowledge, no studies describing upper or mid-back pain in the general population and comparing the characteristics of upper or mid-back pain to neck and low-back pain in the same population have been published. Examining the association between pain in various spinal regions might offer insights into the etiology of spinal pain and its reporting.

This study focuses on characterizing upper or mid-back pain in a general population sample of men by examining its 1-year prevalence, severity, and frequency, and comparing the rates of symptoms and pain characteristics to those of other regions of the spine. Specifically, the goals of the study were: 1) to determine the 1-year prevalence and characteristics of upper or mid-back pain in adult Finnish men, 2) to compare the 1-year prevalence and characteristics of upper or mid-back pain with neck and low-back pain within the same sample, and 3) to determine the within-subject correlation of upper or mid-back pain with neck and low-back pain. In other words, are persons with upper or mid-back pain more likely to report neck or low-back pain?

## METHODS

### *Study Design*

A descriptive epidemiologic study of the 1-year prevalence and severity of self-reported upper or mid-back pain in Finnish men was conducted using cross-sectional data.

### *Subjects*

The subjects were selected from the Finnish Twin Cohort, which contains all Finnish twin pairs born before 1958 and alive in 1975.<sup>10,11</sup> The sample of twins (monozygotic (MZ) and dizygotic (DZ)) was selected for a cohort study investigating the role of suspected risk factors for disc degeneration, and the selection of pairs was based solely on discordance between cotwins for one of several specific, common behavioral or environmental factors, described in more detail elsewhere.<sup>12</sup> In addition, the sample included 33 randomly selected MZ and DZ pairs.<sup>13</sup> The response rate was 71.8% for a total sample of 600 male twins (147 MZ and 153 DZ pairs) aged 35 to 70 years. The mean age was 49.8 years (SD, 7.7 years).

The representativeness of the sample has been previously examined by comparing the sample of MZ twins to the Finnish Twin Cohort, which includes extensive, periodically collected data from the entire cohort, which is representative of the Finnish population. No significant differences between the subjects and the Cohort have been found for level of education, level of leisure-time physical activity, outdoor and indoor work, shift work, work monotony and health behavior. Also, no significant differences were observed for a history of work-incapacitating neck or back pain. The only statistically significant differences between the subjects and the Cohort representative of the Finnish population were for current work status and physical loading at work. Subjects were more likely to be employed and working in more physically-demanding jobs. These differences likely exist because selection was partly based on these characteristics.<sup>14</sup>

Study protocols were approved by the Ethical Committee of the Department of Public Health, University of Helsinki, the University of Washington, and the University of Alberta. Informed consent was obtained from the subjects before participation.

### *Data Acquisition*

A structured interview was used to obtain data on history of upper or mid-back pain, neck pain, and low-back pain. The 1-year prevalence and severity of self-reported upper or mid-back pain were acquired through the following questions:

- *“Over the past 12 months, about how often have you experienced upper or mid-back pain?”* The frequency of the pain was indicated with one of the seven following options: daily, weekly, monthly, several times a year, 2 or 3 times a year, once a year, or none at all.
- *“How would you rate your worst upper or mid-back ache/pain over the past 12 months on a scale from 0 to 100, with 0 being no pain and 100 being the worst pain imaginable?”*
- *“Over the past 12 months, how many days have you had difficulty doing your daily work (at home or at work site) due to upper or mid-back problems?”*

The same questions were used for the “neck” and “low-back”. Subjects were first queried about low-back pain and then upper or mid-back pain, followed by neck pain. Additional information further defining the neck, upper or mid-back and low-back was not given for the subjects.

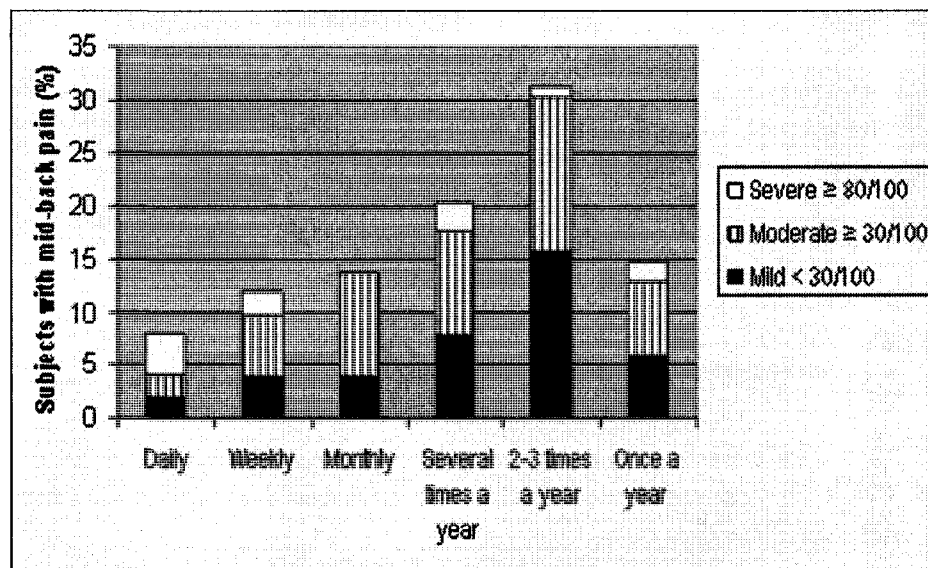
### *Data Analysis*

Data analyses were performed using STATA (StataCorp LP, Texas USA) statistical software. STATA’s survey methods were used for all analyses, with the twin pair as the sampling unit, to adjust for any correlation between the twins. The prevalence rates for back pain, severity of pain, and disability caused by pain were computed. A cutoff point of 30 on the 0 to 100 numerical pain scale was used to denote moderate pain according to the literature.<sup>15</sup> For 1-year prevalence rates, the seven ordinal responses for frequency of pain were recoded to 0 if the subject reported no pain during the previous year and to 1 if pain had been present, regardless of frequency. Logistic regression analysis was used to obtain crude odds ratios for neck and low-back pain using upper or mid-back pain as the independent variable.

## RESULTS

### *1-year prevalence and severity of upper or mid-back pain*

The point estimate for self-reported 1-year prevalence of upper or mid-back pain was 17.0% (95% confidence interval (CI), 14.3-19.7), (n=102 of 599). Of those reporting upper or mid-back pain, daily pain was present in 7.8% (n=8) and half of these rated their worst pain as greater than 80 on a numerical pain scale from 0 to 100 (Figure 4.1). The mean severity rating of the worst pain experienced was 38.0 (95% CI, 33.3-42.6). The majority of the subjects (76.9%) with upper or mid-back pain did not report difficulties performing daily activities due to the pain. Among the 24 subjects reporting difficulties, the mean number of days of difficulty doing daily work or leisure activities was 33.4 (95% CI, 2.4-64.3) with a median of 13.5 days. (Table 4-1.)



**Figure 4-1.** Frequency and severity of upper or mid-back pain over the previous 12 months (n=102).

### *Prevalence of upper or mid-back pain versus prevalence of neck and low-back pain*

The 1-year prevalence of upper or mid-back pain was 17.0% (95% CI, 14.3-19.7) as compared with 64.0% (95% CI, 60.6-67.5) (n=384 of 598) for neck pain, and 66.8% (95% CI, 63.4-70.3) (n=401 of 600) for low-back pain. Among those with pain in a par-

ticular region over the prior 12 months, the descriptive findings showed that upper or mid-back pain occurred at a similar frequency as low-back pain, and less frequently than neck pain. The mean severity of the worst pain episode was the highest for low-back pain followed by neck and upper or mid-back pain, which were rated similarly. Difficulties with normal activities due to the pain tended to occur less often with upper or mid-back pain (23.5%) than with low-back pain (41.1%), with neck pain being more similar (30.3%). The number of days experiencing difficulties in normal activities appeared to be similar for all three pain regions. (Table 4-1.)

**Table 4-1.** A comparison of pain characteristics for subjects' neck, upper or mid-back and low-back pain. Percents with 95% CI given unless otherwise noted.

	Neck	Upper or mid-back	Low-back
Any pain during the year	64.0% (60.6, 67.5)	17.0% (14.3, 19.7)	66.8% (63.4, 70.3)
When pain was reported:	(n=384)	(n=102)	(n=401)
Pain occurring daily to monthly	55.1% (50.6, 59.5)	33.3% (24.5, 42.2)	39.9% (35.5, 44.3)
Severity of the worst pain (0-100; mean)	40.2 (38.1, 42.2)	38.0 (33.3, 42.6)	45.4 (42.8, 48.0)
Worst pain $\geq$ 80	7.8% (3.4, 10.2)	11.8% (2.9, 20.6)	15.7% (12.3, 19.1)
Difficulties in normal activities due to the pain	30.3% (26.2, 32.7)	23.1% (15.6, 31.5)	41.1% (36.7, 45.6)
Number of days experiencing difficulties in normal activities due to the pain (median, interquartile range)	7.0 (3.0-30.0)	13.5 (5.0-30.0)	10.0 (4.0-30.0)

*Associations of upper or mid-back, neck and low-back pain*

Crude odds ratios for the 1-year prevalence of neck and low-back pain when upper or mid-back pain was reported were 2.32 (95% CI, 1.53-3.51) and 2.86 (95% CI, 1.80-4.54) higher than in the absence of upper or mid-back pain reports. Having had pain in the upper or mid-back was almost always associated with having had pain in the neck, low-

back, or both. Of the subjects with upper or mid-back pain, 66.7% reported having had pain in all three areas of the back. Only 4.9% (n=5) of subjects with upper or mid-back pain reported having had only upper or mid-back pain, whereas low-back pain was the only complaint in 25.7% (n=103) of subjects with low-back pain and neck pain was the only complaint in 23.4% (n=90) of subjects reporting neck pain. Fifteen percent (n=90) did not report pain in any spinal region during the previous 12 months.

## DISCUSSION

The 1-year prevalence of self-reported upper or mid-back pain in this study was similar to rates from 15% to 18%<sup>5,6,9</sup> reported for methodologically similar studies of males in the general population, which examined pain in various spine regions (Table 4-2). The questions we used to determine prevalence are similar to other standardized pain questions that have demonstrated reasonable reliability.<sup>16</sup> However, in all three earlier studies, the subjects were asked to provide a yes or no response when asked whether they had experienced pain in the prior 12 months. In our study, seven ordinal response options were provided based on frequency of pain. While it is not clear which method is better, these two approaches may lead to variations in reported prevalence of presence or absence of pain. It is also recognized that reporting rates of incidents from a prior time period always contain some error due to recall. It can be speculated that due to recall error of pain episodes, including those hindering normal living, the pain prevalence and disability reported may actually be an underestimation of that experienced. Finally, it must be emphasized that the prevalence rates from this study apply only to men, as women have been shown in some studies to have higher back pain reporting rates.<sup>5,7-9</sup> Yet, the present study results should provide a reasonable estimate of the prevalence of self-reported upper or mid-back pain in Finnish men. The subjects appear to be representative of the adult male population<sup>14</sup> and missing values were few.

The point estimates for the 1-year prevalence of self-reported pain in this study were approximately four times higher for neck and low-back pain than for upper or mid-back pain. Regardless of the variation in absolute prevalence rates for pain in the various spinal regions in the literature, the same overall order of prevalence rates was found. Low-back pain was reported most commonly in men, followed closely by neck pain, with

mid-back pain clearly less frequent. However, in the studies reporting separately on both genders, neck and low-back pain vied for the most prevalent painful spinal region in women. (Table 4.2) No other general population studies assessing the severity of all spine regions were found, except one reporting severity of persistent neck and back pain, as defined as pain of at least 1 month duration. In that study, almost 79% of the subjects with mid-back pain reported being bothered by the pain at least to quite a high degree (severity  $\geq 4$  on a 6-point scale). A similarly high degree of pain was reported in 69% with neck pain and 82% with low-back pain.<sup>17</sup>

**Table 4-2.** Methodologically similar studies to the current study reporting the one-year prevalence of self-reported back pain in the general population.

Authors	Sample	Question	Prevalence of back pain
Linton 1998 <sup>6</sup>	2305 subjects 35-45 years of age	“Have you suffered from back or neck pain during the past 12 months?”	<ul style="list-style-type: none"> <li>• neck: 44%</li> <li>• mid-back: 15%</li> <li>• low-back: 56%</li> </ul>
Linton & Ryberg 2000 <sup>5</sup>	1914 subjects 35-45 years of age	“Have you suffered from back or neck pain during the past 12 months?”	Males / females <sup>a</sup> <ul style="list-style-type: none"> <li>• neck: 35% / 49%</li> <li>• mid-back: 18% / 23%</li> <li>• low-back: 48% / 44%</li> </ul>
Natvig 1995 <sup>9</sup>	2726 subjects	“Have you ever in the last twelve months experienced symptoms (pain or discomfort)?”	Males / females <ul style="list-style-type: none"> <li>• neck: 37% / 58%</li> <li>• mid-back: 15% / 31%</li> <li>• low-back: 51% / 55%</li> </ul>

<sup>a</sup>Prevalence rates estimated from a figure.

The majority of subjects reporting upper or mid-back pain over the prior year in the present study reported having had pain in all regions of the spine. However, whether or not pain in the various regions coincided or occurred at different times in the previous year is unknown. To our knowledge, there are no other studies examining the associations of pain between spine regions in a general population. However, a few studies (of persistent or chronic pain or among orienteers) have reported that, if symptoms are reported in one region of the spine, reports of pain in other body regions are more likely as well.<sup>17-19</sup>



In conclusion, the 1-year prevalence of upper or mid-back pain in adult Finnish men was 17%, approximately one-fourth of the prevalence of neck and low-back pain. Worst episodes of upper or mid-back pain were less severe than for low-back pain, but similarly severe for neck pain, and somewhat less likely to be disabling. Men reporting upper or mid-back pain were nearly three times as likely to also report pain in other spine regions as those without upper or mid-back pain.

## REFERENCES

1. Crook J, Rideout E, Browne G. The prevalence of pain complaints in a general population. *Pain*. 1984;18(3):299-314.
2. Svensson HO, Andersson GB. Low back pain in forty to forty-seven year old men. I. Frequency of occurrence and impact on medical services. *Scand J Rehabil Med*. 1982;14(2):47-53.
3. Stubbs DA, Buckle PW, Hudson MP, Rivers PM, Worringham CJ. Back pain in the nursing profession. I. Epidemiology and pilot methodology. *Ergonomics*. 1983;26(8):755-765.
4. Cromie JE, Robertson VJ, Best MO. Work-related musculoskeletal disorders and the culture of physical therapy. *Phys Ther*. 2002;82(5):459-472.
5. Linton SJ, Ryberg M. Do epidemiological results replicate? The prevalence and health-economic consequences of neck and back pain in the general population. *Eur J Pain*. 2000;4(4):347-354.
6. Linton SJ, Hellsing AL, Hallden K. A population-based study of spinal pain among 35-45-year-old individuals. Prevalence, sick leave, and health care use. *Spine*. 1998;23(13):1457-1463.
7. Guo HR, Chang YC, Yeh WY, Chen CW, Guo YL. Prevalence of musculoskeletal disorder among workers in Taiwan: a nationwide study. *J Occup Health*. 2004;46(1):26-36.
8. Guo HR, Tanaka S, Cameron LL, et al. Back pain among workers in the United States: National estimates and workers at high risk. *Am J Ind Med*. 1995;28(5):591-602.
9. Natvig B, Nessiøy I, Bruusgaard D, Rutle O. Musculoskeletal symptoms in a local community. *Eur J Gen Practice*. 1995;1(1):25-28.
10. Kaprio J, Koskenvuo M, Langinvainio H, Romanov K, Sama S, Rose RJ. Genetic influences on use and abuse of alcohol: a study of 5638 adult Finnish twin brothers. *Alcohol Clin Exp Res*. 1987;11(4):349-356.
11. Videman T, Battie MC, Gill K, Manninen H, Gibbons LE, Fisher LD. Magnetic resonance imaging findings and their relationships in the thoracic and lumbar spine: insights into the etiopathogenesis of spinal degeneration. *Spine*. 1995;20(8):928-935.
12. Battie MC, Videman T, Gibbons LE, Fisher LD, Manninen H, Gill K. Determinants of lumbar disc degeneration: a study relating lifetime exposures and magnetic resonance imaging findings in identical twins. *Spine*. 1995;20(24):2601-2612.
13. Simonen R, Levalahti E, Kaprio J, Videman T, Battie MC. Multivariate genetic analysis of lifetime exercise and environmental factors. *Med Sci Sports Exerc*. 2004;36(9):1559-1566.
14. Simonen RL, Videman T, Kaprio J, Levalahti E, Battie MC. Factors associated with exercise lifestyle: a study of monozygotic twins. *Int J Sports Med*. 2003;24(7):499-505.
15. Collins SL, Moore RA, McQuay HJ. The visual analogue pain intensity scale: what is moderate pain in millimetres? *Pain*. 1997;72(1-2):95-97.

16. Kuorinka I, Jonsson B, Kilbom A, et al. Standardised Nordic questionnaires for the analysis of musculoskeletal symptoms. *Appl Ergon.* 1987;18(3):233-237.
17. Brattberg G, Thorslund M, Wikman A. The prevalence of pain in a general population: the results of a postal survey in a county of Sweden. *Pain.* 1989;37(2):215-222.
18. Van der Linden SM, Fahrer H. Occurrence of spinal pain syndromes in a group of apparently healthy and physically fit sportsmen (orienteers). *Scand J Rheumatol.* 1988;17(6):475-481.
19. Von Korff M, Crane P, Lane M, et al. Chronic spinal pain and physical-mental comorbidity in the United States: results from the national comorbidity survey replication. *Pain.* 2005;113(3):331-339.

## CHAPTER 5: QUANTITATIVE MEASUREMENT OF INTERVERTEBRAL DISC SIGNAL USING MRI

(Published in *Clinical Radiology* 2008; 63(3):252-255)

### INTRODUCTION

The breakdown of collagen and glycosaminoglycans and a gradual desiccation of the disc are dominant phenomena in disc degeneration. Magnetic resonance imaging (MRI) can detect disc desiccation changes based on a loss of signal (decreased brightness).<sup>1</sup> Disc signal on T2-weighted imaging seems to be the most sensitive sign for disc degeneration.<sup>2</sup> The loss of signal may, in fact, be the earliest degenerative change seen in MRI. Disc signal is also the most highly specific MRI finding associated with age.<sup>3</sup> Thus, it is of great interest, particularly in studies of the etiopathogenesis of disc degeneration, including studies of genetic influences. However, reliable and sensitive disc signal measurements are needed.

Qualitative assessments that require visual interpretation of the signal have commonly been used. Disc signal is assessed by assigning it to one of usually three to five categories, indicating a progressive degree of signal intensity loss. The assessments of signal may be affected by the inhomogeneity of the magnetic field and the coexistence of other degenerative findings. As a result, the interobserver reliability of qualitative assessments for thoracic disc signal is poor (ICC =0.42-0.48).<sup>4</sup> The use of gross categorical variables in qualitative assessments also impairs the detection of small differences in signals. Conversely, quantitative assessments are better at detecting small variations and tend to be more reliable.<sup>1</sup> The difficulty with quantitative measurements is the arbitrary scaling of the signal.<sup>5</sup> The measured signal can be affected by magnetic field inhomogeneities. Observed differences in signal between discs may be due to magnetic field inhomogeneities rather than actual differences in the water content or biochemical composition.<sup>6</sup> The measured signal of the disc may also be affected by the MRI protocol. To remove the effect of an arbitrary scale, the signal of the disc should be measured with respect to an adjacent intra-body reference.<sup>5,6</sup> Cerebrospinal fluid (CSF) has been used for this purpose in the lumbar spine.<sup>1,5,7,8</sup>

Use of CSF as an internal reference is hampered by the transmitted cardiac pulsations resulting in periodic motion of CSF<sup>9</sup> and the physiological flow of CSF. These can cause changes in the signal, which most often occur in cervical and thoracic regions.<sup>10</sup> Furthermore, narrowing in the dural sac may locally increase the turbulence of CSF and lead to aberrant signal.<sup>11</sup> The paucity of CSF at thoracic disc levels can also hinder obtaining an adequate CSF sample for reference. Selecting another intra-body reference remote to the disc is not an alternative as it may introduce errors due to the magnetic field inhomogeneities. Therefore, an alternative reference for signal measurements in the thoracic (and cervical) spine may be needed.

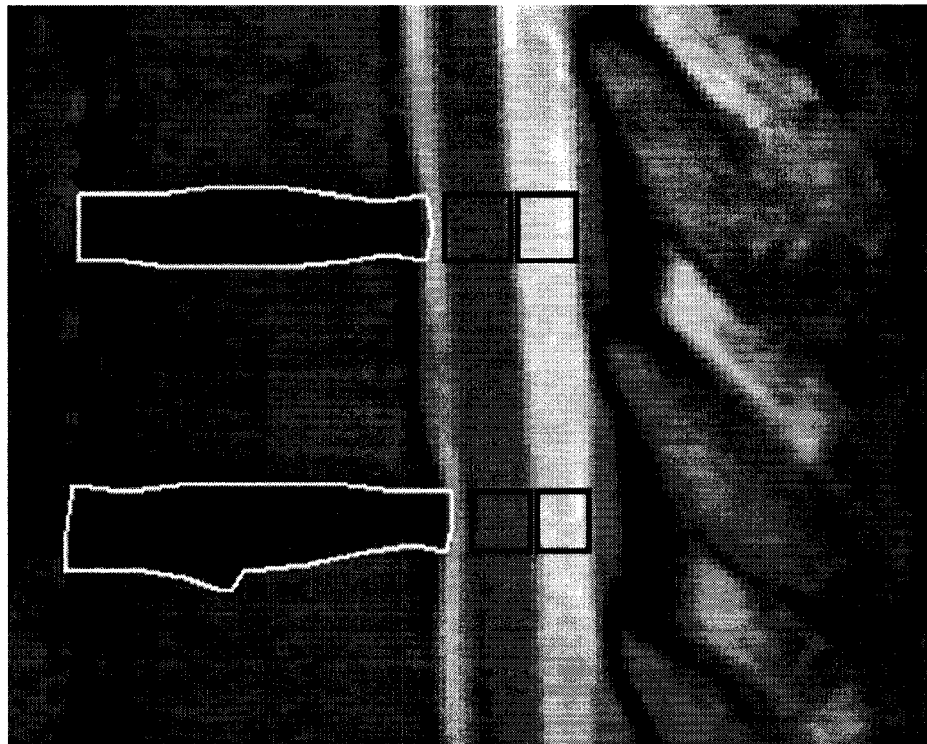
The purpose of the present study was to investigate the spinal cord as an alternative reference to CSF in evaluating thoracic disc signal by examining reliability and validity evidence. The reliability and validity of using spinal cord as an alternative reference was believed to be supported if: 1) repeated measurements of the spinal cord signal reached excellent agreement, 2) the signal of the spinal cord correlated highly with the signal of clear CSF samples (the criterion reference), and 3) the spinal cord-adjusted disc signal correlated with age at least as highly as the CSF-adjusted disc signal, while the correlation of non-adjusted disc signal was low.

## **METHODS**

### *Subjects and Data Acquisition*

MRI mid-sagittal thoracic spine images were available for 523 men (age 35-70 years) from a population sample. The T2-weighted MRI images of the thoracic spine included T6-T12 and were obtained using either a 1.5 T Magnetom or Vision machine (Siemens AG, Erlangen, Germany) with surface coil. For the Magnetom machine sagittal images were obtained using a spin-echo sequence 2600/90 with a section thickness of 4 mm and section gaps of 0.4 mm. The matrix was 256 x 256 and field of view 260 mm. For the Vision machine a spin-echo sequence 3500/120 with a section thickness of 4 mm and section gaps of 0.4 mm were used. The matrix was 512 x 512 and field of view 254 x 290 mm. Custom-made image analysis software (SpEx<sup>®</sup>), developed to allow simultaneous measurements of multiple areas, was used to acquire quantitative data on the signals of the disc, CSF, and spinal cord from T6-T7 through T11-T12. Regions of interest were

manually traced from mid-sagittal sections by one of the authors (R.N.), and their mean signal values were calculated by the software (Figure 5-1). The reliability of acquiring the spinal cord measurements was examined in a sample of 30 subjects, while the correlational analyses between spinal cord and CSF signal measurements were examined in a subgroup of subjects with visually stable CSF samples without any apparent turbulence or other artefacts. Adjusted disc signal is a ratio of disc signal to the signal of the intra-body reference. The mid-sagittal spinal cord was selected based on its homogeneous appearance on MRI in the thoracic spine and its proximity to the thoracic discs. Study protocols were approved by the institutional ethics committee and informed consent was obtained from the subjects before participation.



**Figure 5-1.** Cord and CSF reference samples were acquired at the adjacent level to the disc.

### *Data Analysis*

The reliability and validity of the spinal cord as an intra-body reference were studied in three steps. First, the interobserver reliability of spinal cord signal measurements was examined using the intraclass correlation coefficient (ICC). Pearson correlation coefficients were used for the remaining correlational analyses examining evidence of validity. In the second step in the analysis, the mean signal of CSF was correlated with the mean signal of the adjacent spinal cord for each disc level in the subgroup of subjects. In the third and final analyses the disc signals were correlated with age in three ways: without adjustment and adjusted using both intra-body references. Signals of the spinal cord and the CSF were also correlated with age. Statistical analyses were performed using the SPSS (version 14.0 SPSS Inc. Chicago, Illinois) and STATA (version 9.2 STATA Corp LP, Texas, USA) statistical softwares.

### **RESULTS**

CSF reference samples were not available for 58 subjects (11.1%; 72 samples) due to narrow canal or flow artefact causing local decreased signal. For six subjects (1.1%; nine samples) spinal cord reference samples were not available due to the presence of scoliosis or interference by the spinal nerve root exiting the cord. Additionally, six subjects were excluded due to reasons ranging from fused vertebrae to artefacts affecting image quality. After checking for the outliers for adjusted disc signal 14 additional samples in nine subjects were excluded due to local changes in CSF signal.

The reliability of spinal cord signal measurements was extremely high, ranging from 0.99-1 for the various disc levels. The CSF samples correlated very highly with the signal of the spinal cord, with correlation coefficients from 0.91-0.99 (Table 5-1). The correlation of spinal cord-adjusted disc signal with age was similar to that for age and CSF-adjusted disc signal. In comparison, the correlations between non-adjusted disc signal and age were all low (Table 5-2). The correlations with age were similarly small for both intra-body references, varying from 0.006 to -0.058 for spinal cord, and 0.005 to -0.050 for CSF.

**Table 5-1.** Correlations between signal intensities of the clear cerebrospinal fluid (CSF) samples and spinal cord.

Level	N	Pearson's r
T6-7	23	0.91
T7-8	30	0.97
T8-9	33	0.97
T9-10	32	0.99
T10-11	31	0.98
T11-12	27	0.97

All correlation coefficients were statistically significant, with  $p < 0.001$ .

**Table 5-2.** Correlations between disc signal intensity and age without adjustment and with adjustment using cerebrospinal fluid (CSF) and spinal cord.

Level	N	Without adjustment	Adjustment using CSF	Adjustment using spinal cord
T6-7	324	-0.11	-0.26**	-0.30**
T7-8	411	-0.11	-0.27**	-0.31**
T8-9	442	-0.16*	-0.31**	-0.35**
T9-10	452	-0.17*	-0.31**	-0.33**
T10-11	454	-0.17*	-0.35**	-0.40**
T11-12	449	-0.19*	-0.36**	-0.40**

Correlation coefficients were statistically significant with  $p < 0.05^*$  or  $p < 0.0001^{**}$ .

## DISCUSSION

The spinal cord seems to be at least as good as CSF as an intra-body reference for disc signal measurements in the thoracic spine, and it has a more stable signal that is less affected by other factors. We are not aware of any previous studies performing quantitative measurements of thoracic disc signal using an intra-body reference. Two studies with quantitative disc signal measurements of the cervical spine were found. However, no intra-body reference was used in one,<sup>12</sup> and the other used only a single distal point in the upper cervical cord as a reference.<sup>13</sup> In the lumbar spine, previous studies have found CSF to be a suitable signal reference in the absence of severe narrowing of the dural sac, marked scoliosis, or flow and pulsatile movement.<sup>5,6</sup> These factors affecting the utility of CSF as an intra-body reference were thought to be more pronounced in the thoracic spine



than in the lumbar spine due to the relatively smaller space for CSF. Therefore, the need for an alternative intra-body reference was raised, in particular related to research.

The theory behind the selection of spinal cord was its homogeneous appearance and the mid-section of the spinal cord was thought to be ideal for signal measurements. However, some samples had to be excluded due to the failure of imaging the mid-sagittal section secondary to the presence of scoliosis, posing a limitation to use of spinal cord as a reference in the present study. However, exclusions due to missing reference samples were less likely when using the spinal cord as opposed to the CSF in the thoracic region (from 1.1% of the subjects versus 11.1% of the subjects). Obtaining a CSF sample was also compromised in some cases because of scoliosis or a narrow canal when no sample was available. Reference samples for 86 discs had to be excluded because of obvious local signal changes in the reference sample possibly due to the movement of CSF. Although relatively rare, the signal of the spinal cord can also be affected, but in the present study none of the levels were excluded due to a distinctive change in the signal suggesting cord pathology. In most cases any abnormal changes in cord signal are recognizable at the time of acquiring the reference sample, and therefore, do not prevent the use of spinal cord as an intra-body reference, particularly in population studies. In addition to the thoracic spine, these principles may be applicable to the cervical spine where similar problems related to CSF exist. The method also should be applicable to any disc signal measurement studies regardless of the particular software used.

The large number of subjects available for this study with quantitative information of signals allowed direct comparisons between CSF, which has been used previously, and spinal cord as a reference for disc signal adjustments. The signal of the spinal cord correlated very highly with the signal of the CSF (the criterion measurement). Furthermore, the correlations between spinal cord-adjusted disc signal and age were at least as high as with CSF-adjusted disc signal and age. These findings support the validity of using spinal cord as an internal reference to adjust disc signal measurements. Additionally, the correlations between non-adjusted disc signal and age were clearly lower; thus, supporting the importance of using an intra-body reference when studying disc signal in MRI. Also, the low correlation between spinal cord signal and age suggests that the mid-sagittal cord signal is not affected by age.

In conclusion, all of the study findings support the validity of spinal cord as an intra-body reference for adjusted thoracic disc signal, and its comparability to CSF. The decisive strength of spinal cord as a reference is the lower exclusion rate and ready availability of samples. Spinal cord-adjusted disc signal is a sensitive and reliable measurement, which may be particularly useful in “gene-hunting” and longitudinal studies of disc degeneration, especially when weak associations or small changes are of interest.

## REFERENCES

1. Videman T, Nummi P, Battié MC, Gill K. Digital assessment of MRI for lumbar disc desiccation. A comparison of digital versus subjective assessments and digital intensity profiles versus discogram and macroanatomic findings. *Spine* 1994;19(2):192-198.
2. An HS, Anderson PA, Haughton VM, et al. Introduction: Disc degeneration: Summary. *Spine* 2004;29(23):2677-2678.
3. Battié MC, Videman T, Parent E. Lumbar disc degeneration: Epidemiology and genetic influences. *Spine* 2004;29(23):2679-2690.
4. Raininko R, Manninen H, Battié MC, Gibbons LE, Gill K, Fisher LD. Observer variability in the assessment of disc degeneration on magnetic resonance images of the lumbar and thoracic spine. *Spine* 1995;20(9):1029-1035.
5. Luoma EK, Raininko R, Nummi PJ, Luukkonen R, Manninen HI, Riihimäki HA. Suitability of cerebrospinal fluid as a signal-intensity reference on MRI: Evaluation of signal-intensity variations in the lumbosacral dural sac. *Neuroradiology* 1997;30(10):728-732.
6. Luoma K, Raininko R, Nummi P, Luukkonen R. Is the signal intensity of cerebrospinal fluid constant? Intensity measurements with high and low field magnetic resonance imagers. *Magn Reson Imaging* 1993;11(4):549-555.
7. Videman T, Battié MC, Gibbons LE, Maravilla K, Manninen H, Kaprio J. Associations between back pain history and lumbar MRI findings. *Spine* 2003;28(6):582-588.
8. Videman T, Battié MC, Ripatti S, Gill K, Manninen H, Kaprio J. Determinants of the progression in lumbar degeneration: A 5-year follow-up study of adult male monozygotic twins. *Spine* 2006;31(6):671-678.
9. Mirowitz SA. *Pitfalls, Variants and Artifacts in Body MR Imaging*. St. Louis, USA: Mosby-Year Book; 1996.
10. Rubin JB, Enzmann DR. Imaging of spinal CSF pulsation by 2DFT MR: Significance during clinical imaging. *AJR Am J Roentgenol* 1987;148(5):973-982.
11. Schellinger D, LeBihan D, Rajan SS, et al. MR of slow CSF flow in the spine. *AJNR Am J Neuroradiol* 1992;13(5):1393-1403.
12. Abdulkarim JA, Dhingsa R, L Finlay DB. Magnetic resonance imaging of the cervical spine: Frequency of degenerative changes in the intervertebral disc with relation to age. *Clin Radiol* 2003;58(12):980-984.
13. Iseda T, Goya T, Nakano S, Kodama T, Moriyama T, Wakisaka S. Serial changes in signal intensities of the adjacent discs on T2-weighted sagittal images after surgical treatment of cervical spondylosis: Anterior interbody fusion versus expansive laminoplasty. *Acta Neurochir (Wien)* 2001;143(7):707-710.

## **CHAPTER 6: THE PREVALENCE AND CHARACTERISTICS OF THORACIC MRI FINDINGS IN MEN**

(In press, *Spine*)

### **INTRODUCTION**

Although cervical and lumbar disc degeneration have received much attention in common spinal disorders related research, the thoracic region has been largely ignored. To date there is a dearth of descriptive epidemiology of thoracic MRI findings in the general population, which would be of value as a reference in clinical settings for related observations in patients. Additionally, associations of findings with age and each other could potentially offer insights into the etiopathogenesis of disc degeneration. Currently, only one general population study of thoracic disc degeneration has been carried out.<sup>1</sup> Some cadaver studies are available<sup>2-10</sup> but most present data on Schmorl's nodes and bone-related changes. A few studies of specific occupational groups exist<sup>11-13</sup> in which radiological signs of disc degeneration were examined. The other available studies have used selected patient groups,<sup>14-22</sup> subjects with neck<sup>23</sup> or low-back pain,<sup>24</sup> or asymptomatic subjects.<sup>25,26</sup> The results are difficult to interpret due to the varying definitions of degenerative findings between studies.

The only previous study of thoracic MRI findings in subjects drawn from a population-based sample was conducted on a sub sample<sup>1</sup> of the subjects included in the current study and only qualitative assessments were used. The present study includes a much greater number of subjects, which is important for reporting normative data, and expands on the types of findings assessed qualitatively and quantitatively. The goals were 1) to describe the prevalence of specific MRI findings associated with thoracic disc degeneration and pathology by spinal level (from T6 to T12 vertebrae) in a general population sample of men, and 2) to examine the association of these findings with age and one another.

## METHODS

### *Study Design*

A cross-sectional population-based MRI study was used to describe and characterize the thoracic MRI findings in men.

### *Subjects*

Thoracic MR images were available for 580 men (age 35-70 years) selected from the population-based Finnish Twin Cohort that contains all Finnish twin pairs born before 1958 and alive in 1975.<sup>1,27</sup> The sample of twins (monozygotic (MZ) and dizygotic (DZ)) for the present study was selected for a cohort study investigating the role of suspected risk factors for common musculoskeletal problems, and the selection of pairs was solely based on discordance between co-twins for one of several, specific, common behavioral or environmental factors (smoking, exercise, occupational materials handling, sitting or driving) described in more detail elsewhere.<sup>28</sup> In addition, the sample included 33 randomly selected MZ and DZ pairs.<sup>29</sup>

The representativeness of this study sample has been previously examined by comparing the sample of MZ twins to the Finnish Twin Cohort on a variety of characteristics from extensive, periodically collected data from the entire cohort, whose representativeness of the Finnish population has been established.<sup>30</sup> No significant differences between the study sample and the Finnish Twin Cohort have been found for level of education, level of leisure-time physical activity, outdoor and indoor work, shift work, work monotony and health behaviour. Also, no significant differences were observed for a history of work-incapacitating neck or back pain. The only statistically significant differences between the study subjects and the Finnish Twin Cohort representative of the Finnish population were for current work status and physical loading at work. Subjects were more likely to be employed and working in slightly more physically demanding jobs. These differences likely exist because selection was partly based on these characteristics.<sup>31</sup> Dizygotic subjects were selected using identical criteria, suggesting that they would be similarly representative.

Of the 580 subjects, 53 subjects were excluded because their images were in a format which was not compatible with the remaining images that were in a standard DICOM format. Additionally, three subjects were excluded because of poor image quality. Thus, the total number of subjects available for quantitative assessments was 524 men (229 MZ and 295 DZ subjects) with a mean age of 50.0 years (SD 7.8). Qualitative assessment data were also missing for an additional five subjects. Of the remaining subjects included in analyses, 93 men (17.7%) reported upper or mid-back pain during prior year.

Study protocols were approved by the Ethical Committees of the University of Alberta and the Department of Public Health of the University of Helsinki and informed consent was obtained from the subjects before participation.

#### *Imaging technique*

T2- and PD-weighted images of the thoracic spine included T6-T12 and were obtained using either a 1.5-Tesla Magnetom or Vision scanner (Siemens AG, Germany) with surface coil. For the Magnetom scanner (referred to as Magnetom) sagittal images were obtained using spin-echo (SE) sequences of 2600/22-90 with a slice thickness of 4 mm and slice gaps of 0.4 mm. The matrix was 256 x 256 and field of view (FOV) 260 mm. For the Vision scanner (Vision in the rest of the text) SE sequences of 3500/20-120 with a slice thickness of 4 mm and slice gaps of 0.4 mm were used. The matrix was 512 x 512 and FOV 254 x 290mm. Other differences between scanners existed for coils (Magnetom had a single loop coil and Vision a 4-element phased array coil) and gradient strength (10 mT/m for Magnetom and 25 mT/m for Vision). The subjects spent at least 30 minutes lying down before imaging to recover possible fluid loss from the disc.<sup>32,33</sup>

#### *Qualitative and quantitative MRI assessments*

Qualitative assessments of disc degeneration were performed by a spine surgeon. Each MRI finding was rated using a scale from 0 to 3, with 0 being normal and 1-3 representing progressive degrees of severity from the three middle sections (Table 6-1). The interobserver reliability for qualitative assessments have been reported previously.<sup>34</sup> Depending on the spinal level, interobserver reliability intraclass correlation coefficients (ICC) ranged from 0.22 to 0.40 for thoracic disc height narrowing and 0.47 to 0.56 for disc bulging. Kappa coefficients for separating findings classified as normal or mild-to-

severe varied between 0.57 and 0.66 for upper endplate irregularities, and 0.24 to 0.33 for lower endplate irregularities.

**Table 6-1.** Grading scale for qualitative assessments of thoracic disc degeneration with intraobserver reliability from a sample of twenty subjects.

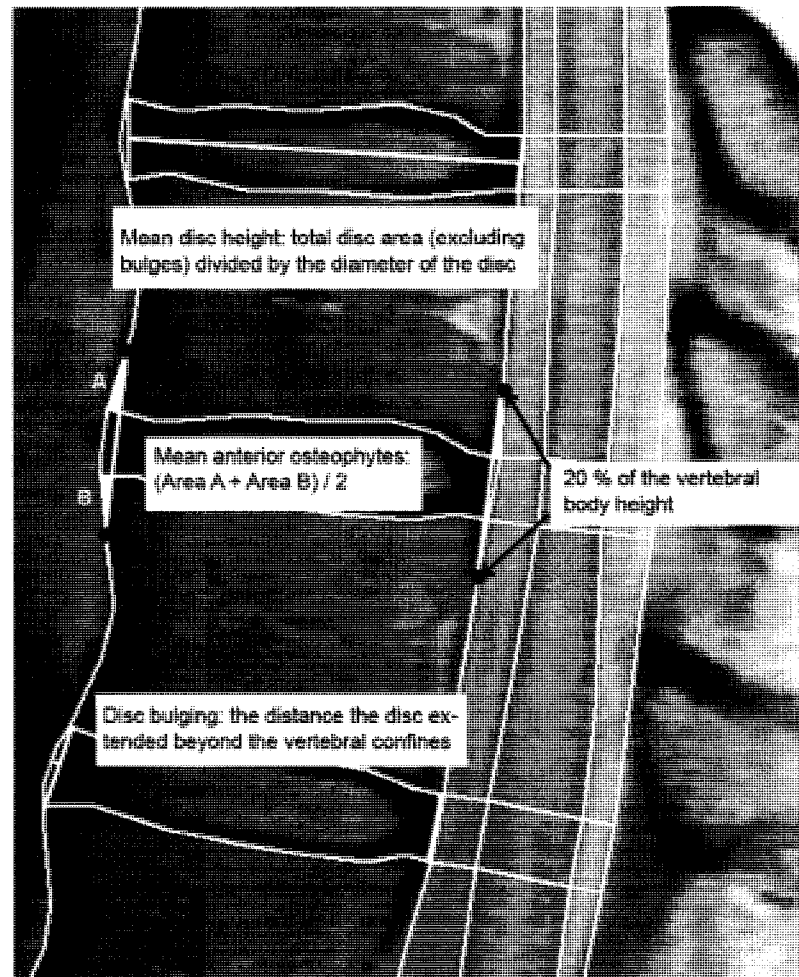
Variable	
Disc height (ICC=0.70)	0: Normal –typically disc higher than the upper disc 1: Slight –disc as high as the upper disc if it is normal 2: Moderate – Disc narrower than the upper disc if it is normal 3: Severe – endplates almost in contact
Vertebral endplates Schmorl’s nodes (ICC=0.77 for irregularities of the upper endplate relative to the disc*)	0: None present 1: Slight defect (1-5 mm) 2: Moderate defect (5-10 mm) 3: Severe defect (>10 mm)
Disc bulging (ICC=0.77 and 1.00 for anterior and posterior bulging)	0: None –normal contour of the disc 1: Slight –approximately 1.5 ± 1 mm 2: Moderate –approximately 3.5 ± 1 mm 3: Severe - ≥ 4.5 mm

\*) Reliability of measurements of lower endplate irregularities could not be assessed due to too few findings.

Quantitative measurements of disc degeneration from vertebrae T6 to T12 were acquired using custom-made image analysis software (SpEx<sup>®</sup>, Edmonton, Canada). The contours of the thoracic discs, vertebrae, spinal canal and spinal cord were segmented manually on the mid-sagittal PD-weighted image. The contours of the vertebrae and discs were segmented by first following the anterior and posterior longitudinal ligaments; the contrast did not allow the annulus and longitudinal ligaments to be distinguished at the disc level. Next, the boundary between the vertebral bone and the endplate was followed. These tracings were then transferred onto the T2-weighted image to complete the manual segmentation by outlining the spinal cord and making necessary adjustments to the original segmentation. (Figure 6-1.) The regions of interest were formed by the intersections of the segmentation lines corresponding to the discs, vertebrae, spinal canal and spinal cord from which measurements were derived, all from mid-sagittal images. The distance measurements were transformed into actual distances (mm) by multiplying the pixel distance by the size of the pixel and areas as mm<sup>2</sup>.

Segmentation of all subjects’ MRI was performed by one of the authors (R.N.) to obtain the quantitative measurements used in the analysis. One of the other investigators

(T.V.) repeated the segmentation for a random sample of 30 subjects' images to obtain quantitative measures from which interobserver reliability could be determined using intraclass correlation coefficients (ICC; 2, 1). Intraobserver reliability was examined in the same sample of 30 subjects with repeat segmentations by the first author.



**Figure 6-1.** Example segmentation and disc height, osteophyte and bulging measurements.

*Disc signal* was expressed as the signal of the disc adjusted by the signal of the adjacent spinal cord (interobserver and intraobserver ICC = 0.97, 0.98). Adjustment of disc signal using an intra-body reference (spinal cord) was performed to allow comparisons between spinal levels and individuals.



*Mean disc height* was calculated by dividing the total area of the disc, excluding bulging beyond the vertebral confines (i.e. corners), by the anterior-posterior diameter of the disc (Figure 6-1, ICC=0.88, 0.91).

*Disc bulging* was defined as the distance that the disc extended beyond the vertebral confines; distances up to a pixel were considered to represent no bulging (Figure 6-1). Due to the low prevalence of disc bulging, especially posterior bulges, it was not possible to calculate ICC or Kappa coefficients. The interobserver agreement for separating bulging from no bulging was 84% for anterior bulging and 97% for posterior bulging. There was disagreement in the presence or absence of anterior bulging in twenty-five of 152 discs assessed. For all but two of the 25 discs segmented as bulging by one observer and not the other, the bulging distances were only three pixels or less. No posterior bulging was indicated from the segmentations of one observer while the other was in agreement with the exception of four discs where the bulging distance was only two pixels for all four discs. The intraobserver agreements were 96% and 99% for anterior and posterior bulging.

*Osteophyte areas* were measured by connecting points located on the vertebral body wall 20% of the vertebral body height above and below the disc both anteriorly and posteriorly. A line connecting the points was used to measure the bony areas anteriorly and posteriorly. The osteophyte area was the mean of the areas above and below the disc (interobserver and intraobserver ICC=0.56, 0.66 and 0.50, 0.65 for anterior and posterior osteophytes, respectively). (Figure 6-1.)

*Scheuermann's disease* was determined using the diagnostic criterion of three or more consecutive wedged vertebrae of 5 degrees or more.<sup>35</sup> Wedging was calculated by measuring the angle formed by the vertebral endplates (ICC=0.54, 0.82).

*Vertebral deformities and their severity* were assessed using a technique suggested by Genant et al. which has yielded good reliability.<sup>36</sup> In addition, when the severity of the deformity was uncertain (i.e. borderline cases) a measurement of vertebral height was performed using SpEx<sup>®</sup>. Only moderate and severe deformities were reported.

*Hemangioma* was considered to be present if bright a circular spot was observed in the vertebral body on both PD- and T2-weighted images.

#### *Data Analysis*

Descriptive statistics were used for the prevalence of MRI findings in the thoracic spine. Pearson's and Spearman's correlation coefficients were used to assess the association of findings with age and one another. Partial correlation (adjusting for scanner) was used to examine the association of disc signal to age and other findings in case the intra-body reference did not fully adjust for all scanner-related differences. Linear regression with repeated measures was used to evaluate caudal change in disc height, bulging and osteophytes. STATA's survey analysis (STATA Corp 2007, version 9.2 SE, College Station, TX) was used for correlated data to account for twinship. P-values for correlational analyses were obtained from univariate regression analysis, and as a conservative approach the least statistically significant p-value was chosen.<sup>37</sup> 95% confidence intervals were reported.

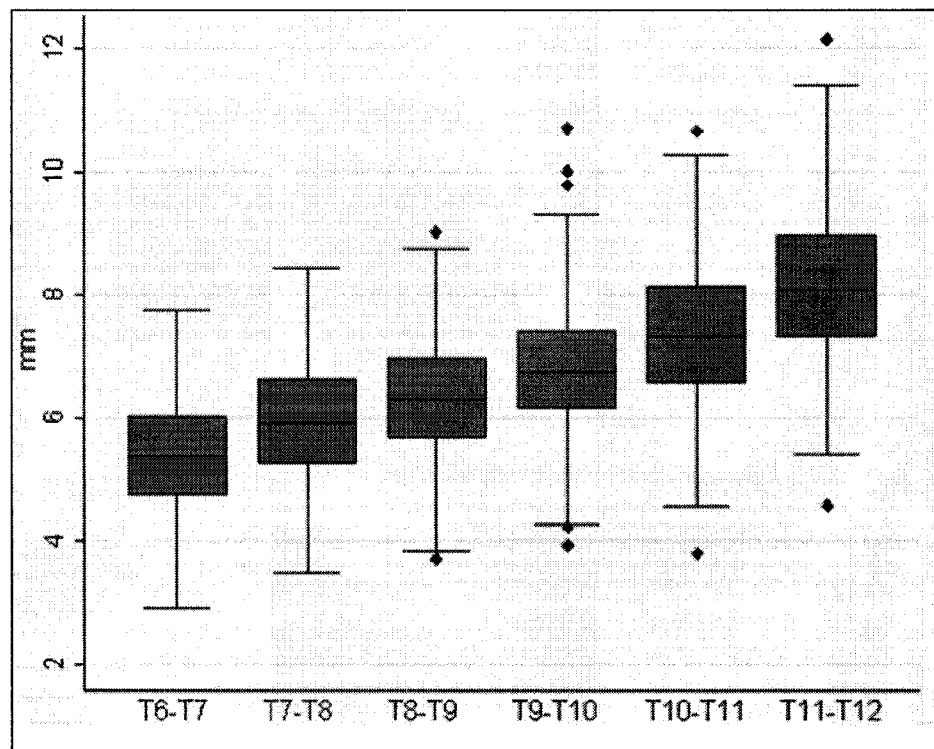
## **RESULTS**

#### *Prevalence of MRI findings*

As expected, mean *disc height* as measured quantitatively increased caudally ( $p < 0.001$ ). However, large individual variations were present (Figure 6-2). Individual variation in relative disc height between adjacent levels of the thoracic spine remained even when only those discs that were determined qualitatively to be "normal" (i.e. having no disc height narrowing) were examined. A difference between scanners was observed but the same caudal trend and overlap between levels was obvious for both scanners. According to qualitative assessments moderate-to-severe disc height narrowing was present in 5.4% to 9.5% of the discs by level, and 21.4% (17.4%, 25.4%) of the subjects had at least one moderately or severely narrowed disc (Table 6-2).

The mean spinal cord-adjusted *disc signal* (ratio of disc signal to spinal cord signal) was slightly higher for the lower thoracic levels, ranging from 0.32 to 0.36 for Magnetom and 0.30 to 0.36 for Vision scanners.

Quantitatively-measured *disc bulging* was most frequently observed anteriorly with the prevalence increasing caudally ( $p < 0.0001$ ) (Figure 6-3). Conversely, qualitatively-assessed posterior disc bulging was more common in the upper two disc levels. For the rest of the levels anterior bulging was substantially more common, particularly at the lowest three levels (Table 6-2). At least one quantitatively-measured anterior bulge was present in 45.2% (40.6%, 49.9%) of the subjects and posterior bulging in 9.2% (6.6%, 11.7%) of the subjects. One or more bulging discs, regardless of direction, was seen in 49.8% (45.2%, 54.4%) of the subjects.



**Figure 6-2.** Quantitative mean disc height by level (n=403-524) (The variation in the number of discs by level is due to the missing data, primarily at T6-T7).

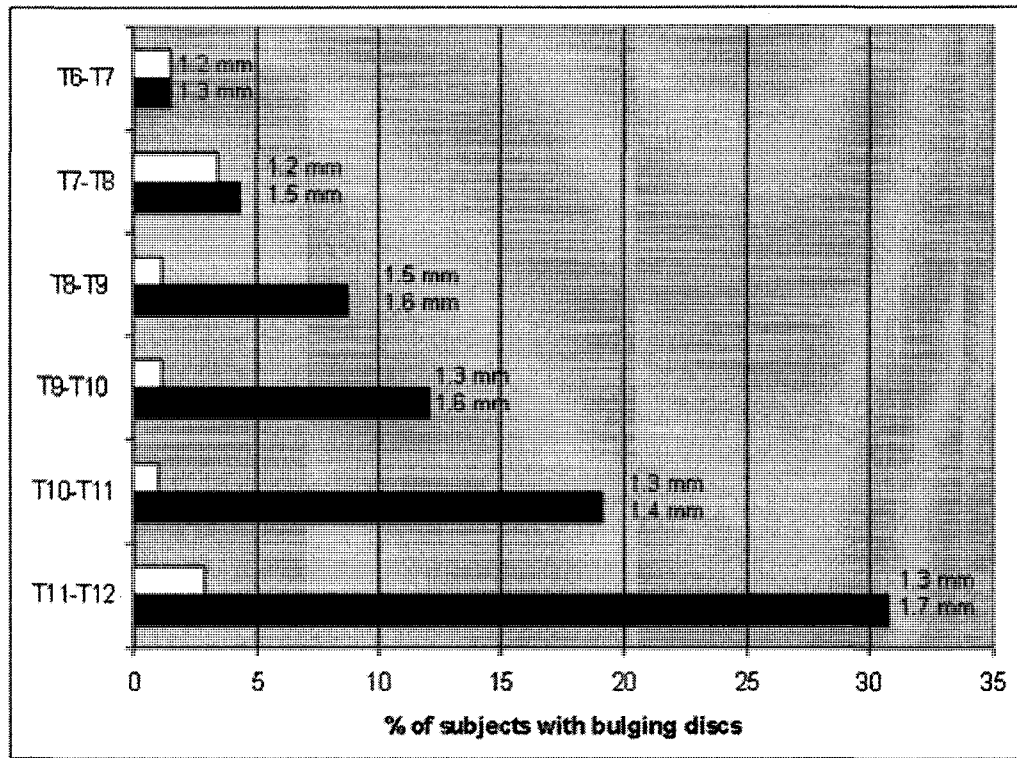
The size of *osteophytes* (area) increased caudally ( $p < 0.0001$ ). The average size of anterior osteophytes at T11-T12 was 2.3 mm<sup>2</sup> and posterior osteophytes 0.9 mm<sup>2</sup>. On average, osteophytes were larger anteriorly than posteriorly, except for the upper two levels where posterior osteophytes were larger.

Qualitatively-assessed *endplate irregularities* were more common in the upper endplates (superior to the disc) (Table 6.2). Moderate or severe endplate irregularities were noted in at least one of the thoracic endplates from T6 through T12 in 27.1% (95% CI: 22.8%, 31.5%) of the subjects.

**Table 6-2.** The prevalence of MRI findings based on qualitative assessments (%) (N=519).

Variable	T6-T7	T7-T8	T8-T9	T9-T10	T10-T11	T11-T12
Disc height narrowing						
Mild	33.3 (29.1, 37.5)	41.8 (37.4, 46.2)	46.2 (41.7, 50.7)	48.7 (44.1, 53.3)	40.3 (35.6, 45.0)	39.5 (34.9, 44.1)
Moderate	6.4 (4.2, 8.6)	8.7 (6.2, 11.3)	6.9 (4.5, 9.3)	6.2 (3.9, 8.5)	4.8 (2.9, 6.7)	4.8 (2.9, 6.7)
Severe	0.6 (-0.2, 1.4)	0.8 (-0.1, 1.7)	0.8 (-0.1, 1.7)	0.4 (-0.1, 0.9)	1.0 (0.2, 1.8)	0.6 (-0.1, 1.3)
Anterior disc bulging						
Mild	1.2 (0.09, 2.2)	2.7 (1.2, 4.2)	5.6 (3.6, 7.6)	8.5 (6.0, 11.0)	11.9 (8.9, 15.0)	14.8 (11.5, 18.1)
Moderate						0.4 (-0.1, 0.9)
Posterior disc bulging						
Mild	2.7 (1.3, 4.1)	3.9 (2.1, 5.6)	5.8 (3.7, 7.9)	4.2 (2.4, 6.0)	4.4 (2.5, 6.4)	8.2 (5.9, 10.7)
Upper endplate irregularities						
Mild	9.2 (6.6, 11.9)	16.2 (12.9, 19.5)	22.0 (18.0, 26.0)	28.3 (24.1, 32.5)	29.3 (25.0, 33.5)	28.5 (24.4, 32.7)
Moderate	3.1 (1.5, 4.7)	7.1 (4.7, 9.5)	8.1 (5.6, 10.6)	6.6 (4.3, 8.8)	6.9 (4.4, 9.4)	9.1 (6.4, 11.7)
Severe			0.2 (-0.2, 0.6)	0.2 (-0.2, 0.6)	0.4 (-0.1, 0.9)	0.2 (-0.2, 0.6)
Lower endplate irregularities						
Mild	2.5 (1.2, 3.8)	3.9 (2.0, 5.7)	2.9 (1.5, 4.3)	5.0 (3.1, 6.9)	7.7 (5.4, 10.0)	5.4 (3.4, 7.4)
Moderate	0.2 (-0.2, 0.6)	0.8 (0.02, 1.5)	0.4 (-0.2, 0.9)	0.8 (0.02, 1.5)	1.7 (0.6, 2.9)	2.1 (0.7, 3.6)
Severe	0.2 (-0.2, 0.6)	0.4 (-0.2, 0.9)	-	-	0.4 (-0.2, 0.9)	0.4 (-0.2, 0.9)

The commonly accepted diagnostic criterion for Scheuermann's disease was fulfilled by 14.1% (10.9%, 17.4%) of the subjects. Thirty-two (6.1%; 3.8%, 8.4%) subjects had at least one moderate or severe vertebral deformity according to the grading scheme. Of those, the majority (68.8%; 51.8%, 85.7%) had only one deformed vertebra. And vertebral hemangiomas, mainly of small size, were present in 2.3% (1.0%, 3.6%) of the subjects.



**Figure 6.3.** The prevalence of anterior (black bar) and posterior (white bar) quantitative disc bulging by level with the mean bulging distance (n=409-524).

*Correlation of findings with age and one another*

Correlations of spinal cord-adjusted disc signal with age varied from -0.31 to -0.42 ( $p < 0.0001$ ), with the highest correlation observed for T10-T11. The extent of quantitatively-assessed anterior disc bulging ( $r = 0.15-0.23$ ,  $p < 0.05$ ) was positively correlated with age at all levels. Conversely, higher age was associated with less quantitatively-assessed posterior bulging at the T7-T8 disc level only ( $r = 0.09$ ,  $p < 0.05$ ). Similar to quantitative measurements, qualitatively-assessed anterior disc bulging correlated with age from T8-T12 (Spearman's rho,  $\rho = 0.14-0.15$ ,  $p < 0.01$ ) but posterior bulging correlated with age only for the T11-T12 level ( $\rho = 0.13$ ,  $p < 0.01$ ). Quantitatively-measured anterior osteophytes also correlated with age ( $r = 0.10-0.20$ ,  $p < 0.05$ ).

More qualitatively-assessed disc height narrowing was associated with lower disc signal for all levels with correlations increasing caudally ( $r = 0.29-0.46$ ,  $p < 0.0001$ ). Concordantly, higher quantitatively-assessed mean disc height (mm) was correlated with

brighter discs (i.e. higher signal) ( $r=0.11-0.29$ ,  $p<0.05$ ). More disc height narrowing also was associated with lower quantitative disc height measurements ( $r=0.13-0.35$ ,  $p<0.01$ ). Upper and lower endplate irregularities were associated with each other ( $r=0.17-0.32$ ,  $p<0.05$ ), as were quantitatively-assessed anterior disc bulging and anterior osteophytes ( $r=0.35-0.61$ ,  $p<0.0001$ ) and posterior disc bulging and posterior osteophytes ( $r=0.26-0.45$ ,  $p<0.01$ ). All correlations were adjusted for age. (Table 6-3.)

## **DISCUSSION**

This study reports on quantitatively and qualitatively assessed prevalence of thoracic MRI findings and their associations with age and one another in a general population sample highly representative of Finnish men.<sup>31</sup> Thoracic MRI findings associated with disc degeneration are less common than what has been reported for the lumbar spine. For example, an earlier report of moderate-to-severe lumbar disc bulging among MZ subjects included in the present study sample, using the same assessor, found a prevalence of 15.8% to 33.7% by level<sup>1</sup>, whereas in the thoracic region we found moderate-to-severe bulging in 0.4% of the discs at T11-T12 level only. Similarly, moderate-to-severe disc height narrowing varied from 4.9% to 35.6% by lumbar level<sup>1</sup> while we found it to vary from 5.4% to 9.5% by thoracic level.

Comparisons with data from the earlier analyses of the subgroup of the subjects from the current sample<sup>1</sup> highlighted the influence of individual nuances on qualitative judgments on thoracic MRI findings. For example, in the current study the prevalence of moderate-to-severe disc height narrowing was assessed as 5.4 – 9.5% depending on level, whereas earlier assessments of the smaller sample yielded prevalence rates of 0.4 – 7.1%. In contrast, we found moderate-to-severe disc bulging at only one level in 0.4% of the discs, whereas earlier assessments ranged from 0.2% to 21.1% by level. The assessments were performed by the same clinician nearly ten years apart. Consequently, it is clear that qualitatively-assessed prevalence rates provide gross estimates only because of the variation due to the subjective nature of the assessments. Well-defined quantitative assessments should be less affected.

Contributing to the typically low reliability of qualitative measurements is the relatively small object size in the thoracic spine, as compared to the lumbar spine, the

relative size of the MR image pixels and the low prevalence of some findings. These also pose limitations to the present study. While these issues affect both qualitative and quantitative measurements of disc degeneration, the latter typically are more reliable and provide more precision than commonly used qualitative ratings. A strength of this study was the large sample whose representativeness has been examined in a variety of variables. While subjects were found to be working in slightly more physically demanding jobs as compared to the population base from which they were drawn, the impact of this on the results is likely to be modest, since higher physical demands have been shown to have only small effects on disc degeneration in the lumbar spine.<sup>28</sup> However, it is possible that differences in factors that were not measured may have been present, affecting the representativeness of the sample.

Our quantitatively-measured mean disc height was higher than those reported using radiography.<sup>38</sup> However, our height measurements (area/diameter) represent a mean disc height and include disc convexity, which is not commonly included when calculating disc height simply from anterior and posterior height measurements. It is unclear whether the difference we observed in disc heights between scanners is due to a scanner effect or whether it reflects a true difference in the mean disc height between the groups scanned on each scanner. However, the same trend and the same variation between and within levels were observed for subjects scanned with either scanner. Unfortunately, due to the wide individual variation in the height of a disc at one level relative to other levels, even in subjects assessed as having no signs of disc degeneration it was not possible to determine if a disc was narrowed compared to the adjacent ones. Aharinejad et al<sup>39</sup> also found that efforts to classify thoracic discs by their relative size were unproductive because of the extensive inter-individual variation. Quantitative measurements of disc height may, however, be very useful in follow-up studies examining the progression of disc height narrowing.

We found at least one qualitatively-assessed bulge in 38.2% of subjects based on findings from T6-T12, as compared to a previous study that found a prevalence of 65% in asymptomatic men for the whole thoracic spine.<sup>26</sup> Due to the absence of a standard grading scheme for thoracic disc bulging, no categorization by severity for quantitative measurements was performed. However, only one posterior bulge out of 55 bulges and one-

fifth of the anterior bulges extended more than 2 mm beyond the corners of the vertebral bodies.

The overall prevalence of Schmorl's nodes in the general population remains controversial. Similar to our findings, cadaver studies have found Schmorl's nodes to be more prevalent in the upper endplates (relative to the disc).<sup>2,4</sup> In cadavers, the prevalence has varied from 39% to 65% for the lower thoracic region<sup>4,6</sup> and from a few percent at T1 to 35% at T12 by level.<sup>7</sup> Similar to our findings (2.9% - 9.8% for lower and 12.3% - 37.8% for upper endplates), another study reporting on the same thoracic levels in cadavers reported a prevalence of 9% to 35%, depending on the level.<sup>7</sup> We used the mid-sagittal images for quantitative measurements which may have led to underreporting of prevalence because findings occurring laterally may have been missed. However, qualitative assessments did examine the three middle sections.

The criterion for Scheuermann's disease described by Sørensen<sup>35</sup> was used in the current study. Previously reported prevalence rates vary from 7.4% in cadavers<sup>40</sup> to 9.7% in men as assessed from x-ray.<sup>41</sup> Our finding of 14.1% is slightly higher but almost one-third of the cadavers were females,<sup>40</sup> which may have affected the prevalence since it appears to be lower among females.<sup>35,41</sup>

The previously published grading scheme<sup>36</sup> to examine vertebral deformities was developed using radiography, but has been used before with MRI and should be similarly applicable.<sup>42</sup> The cross-sectional nature of the study together with the imaging sequences did not allow differentiation of recent and old deformities. Quantitative measurements of vertebral heights have resulted in prevalence rates for vertebral deformities among men over 50 years of age of 12.2% to 26.2%.<sup>43,44</sup> Our finding of a prevalence of 6.1% fits well with the estimates, considering that only moderate or severe deformities from T6 to T12 were recorded. Overall, wedge deformity seems to be the most common type of deformity.<sup>43</sup>

In accordance with the lumbar spine<sup>45</sup> the highest correlation with age was found for disc signal. Disc bulging and osteophytes also correlated with age as reported from earlier studies<sup>1,2,11</sup> but disc height narrowing did not. The previously reported correlation for disc height and age<sup>1</sup> was found using combined levels from T6-T7 to L5-S1, and the inclusion of lumbar levels may have been responsible for the correlation. Similar to the



previous analysis,<sup>1</sup> we found disc bulging to correlate with osteophytes. Disc signal and disc height narrowing are commonly examined variables for disc degeneration and we found them to be among the MRI findings most highly correlated with one another. The correlation was higher with qualitatively-assessed disc height narrowing than with quantitative disc height. Qualitative assessments likely incorporate other information from the level in question as well as other levels to determine narrowing. For example, ‘dark discs’ may be more likely to be assessed as being narrowed than ‘brighter discs’. The low reliability of some of the findings most likely has affected the correlations. The observed correlations, therefore, can be assumed to be rather conservative estimates of the ‘true’ associations.

In summary, the present study provides normative data as a reference for thoracic MRI findings associated with disc degeneration and vertebral pathology in men. However, it must be kept in mind that prevalence rates depend substantially on assessment protocols and individual judgments. Correlations of different MRI findings, such as disc height narrowing and disc signal, may suggest a shared etiopathogenesis.

**Table 6-3.** Correlations of different MRI findings for T7-T8 and T11-T12, adjusted for age (n=490-523).

T7-T8	Disc height#	Disc signal	Mean disc height	Anterior bulge	Posterior bulge	Upper e-p irregularities#	Lower irregularities#	Anterior osteophytes
Disc signal	<b>-0.34</b>							
Mean disc height	<b>-0.23</b>	<b>0.18</b>						
Anterior bulge	0.03	-0.05	<b>0.14</b>					
Posterior bulge	<b>0.15</b>	<b>-0.09</b>	0.06	<b>0.09</b>				
Upper e-p irregularities#	0.34	-0.05	0.08	-0.004	<b>0.14</b>			
Lower e-p irregularities#	0.08	-0.04	0.07	-0.008	0.04	<b>0.29</b>		
Anterior osteophytes	-0.02	-0.02	<b>0.13</b>	<b>0.42</b>	0.04	0.03	<b>-0.009</b>	
Posterior osteophytes	<b>0.18</b>	<b>-0.24</b>	-0.06	0.04	<b>0.44</b>	<b>0.05</b>	<b>-0.05</b>	<b>0.08</b>
<b>T11-T12</b>								
Disc signal	<b>-0.46</b>							
Mean disc height	<b>-0.27</b>	<b>0.27</b>						
Anterior bulge	<b>0.14</b>	<b>-0.18</b>	<b>0.21</b>					
Posterior bulge	<b>0.16</b>	<b>-0.17</b>	-0.06	<b>0.19</b>				
Upper e-p irregularities#	<b>0.29</b>	<b>-0.12</b>	-0.06	0.005	<b>0.11</b>			
Lower e-p irregularities#	<b>0.18</b>	-0.02	-0.08	-0.03	0.04	<b>0.26</b>		
Anterior osteophytes	<b>0.11</b>	<b>-0.18</b>	<b>0.18</b>	<b>0.61</b>	<b>0.11</b>	-0.04	<b>-0.06</b>	
Posterior Osteophytes	<b>0.34</b>	<b>-0.41</b>	<b>-0.19</b>	<b>0.12</b>	<b>0.28</b>	<b>0.20</b>	<b>0.09</b>	<b>0.05</b>

Bolded = p<0.05

Correlations involving disc signal and mean disc height are adjusted for scanner.

# = qualitative assessment, e-p = endplate

## REFERENCES

1. Videman T, Battie MC, Gill K, Manninen H, Gibbons LE, Fisher LD. Magnetic resonance imaging findings and their relationships in the thoracic and lumbar spine. Insights into the etiopathogenesis of spinal degeneration. *Spine*. 1995;20(8):928-935.
2. Malmivaara A. *Thoracolumbar Junctional Region of the Spine. An Anatomical and Radiological Study*. [PhD]. Medical Faculty of the University of Helsinki; 1987.
3. Hilton RC, Ball J, Benn RT. Annular tears in the dorsolumbar spine. *Ann Rheum Dis*. 1980;39(6):533-538.
4. Hilton RC, Ball J, Benn RT. Vertebral end-plate lesions (Schmorl's nodes) in the dorsolumbar spine. *Ann Rheum Dis*. 1976;35(2):127-132.
5. Saluja G, Fitzpatrick K, Bruce M, Cross J. Schmorl's nodes (intravertebral herniations of intervertebral disc tissue) in two historic British populations. *J Anat*. 1986;145:87-96.
6. Silberstein M, Opeskin K, Fahey V. Spinal Schmorl's nodes: Sagittal sectional imaging and pathological examination. *Australas Radiol*. 1999;43(1):27-30.
7. Pfirrmann CW, Resnick D. Schmorl nodes of the thoracic and lumbar spine: Radiographic-pathologic study of prevalence, characterization, and correlation with degenerative changes of 1,650 spinal levels in 100 cadavers. *Radiology*. 2001;219(2):368-374.
8. Nathan H. Osteophytes of the vertebral column. An anatomical study of their development according to age, race, and sex with consideration as to their etiology and significance. *J Bone Joint Surg Am*. 1962;44-A:243-268.
9. Shore LR. On osteo-arthritis in the dorsal intervertebral joints. A study in morbid anatomy. *Br J Surg*. 1935;22(88):833-849.
10. Chanchairujira K, Chung CB, Kim JY, et al. Intervertebral disk calcification of the spine in an elderly population: Radiographic prevalence, location, and distribution and correlation with spinal degeneration. *Radiology*. 2004;230(2):499-503.
11. Hult L. Cervical, dorsal and lumbar spinal syndromes; a field investigation of a non-selected material of 1200 workers in different occupations with special reference to disc degeneration and so-called muscular rheumatism. *Acta Orthop Scand Suppl*. 1954;17:1-102.
12. Lawrence JS, Molyneux MK, Dingwall-Fordyce I. Rheumatism in foundry workers. *Br J Ind Med*. 1966;23(1):42-52.
13. Hult L. The Munkfors investigation; a study of the frequency and causes of the stiff neck-brachialgia and lumbago-sciatica syndromes, as well as observations on certain signs and symptoms from the dorsal spine and the joints of the extremities in industrial and forest workers. *Acta Orthop Scand Suppl*. 1954;16:1-76.
14. Girard CJ, Schweitzer ME, Morrison WB, Parellada JA, Carrino JA. Thoracic spine disc-related abnormalities: Longitudinal MR imaging assessment. *Skeletal Radiol*. 2004;33(4):216-222.
15. Awwad EE, Martin DS, Smith KR, Jr, Baker BK. Asymptomatic versus symptomatic herniated thoracic discs: Their frequency and characteristics as detected by computed tomography after myelography. *Neurosurgery*. 1991;28(2):180-186.

16. Goh S, Tan C, Price RI, et al. Influence of age and gender on thoracic vertebral body shape and disc degeneration: An MR investigation of 169 cases. *J Anat.* 2000;197(4):647-657.
17. Mann T, Oviatt SK, Wilson D, Nelson D, Orwoll ES. Vertebral deformity in men. *J Bone Miner Res.* 1992;7(11):1259-1265.
18. O'Neill TW, McCloskey EV, Kanis JA, et al. The distribution, determinants, and clinical correlates of vertebral osteophytosis: A population based survey. *J Rheumatol.* 1999;26(4):842-848.
19. Lauridsen KN, De Carvalho A, Andersen AH. Degree of vertebral wedging of the dorso-lumbar spine. *Acta Radiol Diagn (Stockh).* 1984;25(1):29-32.
20. Goh S, Price RI, Song S, Davis S, Singer KP. Magnetic resonance-based vertebral morphometry of the thoracic spine: Age, gender and level-specific influences. *Clin Biomech (Bristol, Avon).* 2000;15(6):417-425.
21. Ryan RW, Lally JF, Kozic Z. Asymptomatic calcified herniated thoracic disks: CT recognition. *AJNR Am J Neuroradiol.* 1988;9(2):363-366.
22. Tan CIC, Song S, Edmondston SJ, Singer KP. Patterns of thoracic disc degeneration from MRI: Age, gender and spinal level influences. *JMR.* 2001;5(4):269-278.
23. Arana E, Marti-Bonmati L, Molla E, Costa S. Upper thoracic-spine disc degeneration in patients with cervical pain. *Skeletal Radiol.* 2004;33(1):29-33.
24. Arana E, Marti-Bonmati L, Dosda R, Molla E. Concomitant lower thoracic spine disc disease in lumbar spine MR imaging studies. *Eur Radiol.* 2002;12(11):2794-2798.
25. Wood KB, Blair JM, Aepple DM, et al. The natural history of asymptomatic thoracic disc herniations. *Spine.* 1997;22(5):525-529.
26. Wood KB, Garvey TA, Gundry C, Heithoff KB. Magnetic resonance imaging of the thoracic spine. Evaluation of asymptomatic individuals. *J Bone Joint Surg Am.* 1995;77-A(11):1631-1638.
27. Kaprio J, Koskenvuo M, Langinvainio H, Romanov K, Sarna S, Rose RJ. Genetic influences on use and abuse of alcohol: A study of 5638 adult Finnish twin brothers. *Alcohol Clin Exp Res.* 1987;11(4):349-356.
28. Battie MC, Videman T, Gibbons LE, Fisher LD, Manninen H, Gill K. Determinants of lumbar disc degeneration. A study relating lifetime exposures and magnetic resonance imaging findings in identical twins. *Spine.* 1995;20(24):2601-2612.
29. Simonen R, Levalahti E, Kaprio J, Videman T, Battie MC. Multivariate genetic analysis of lifetime exercise and environmental factors. *Med Sci Sports Exerc.* 2004;36(9):1559-1566.
30. Kaprio J, Koskenvuo M, Artimo M, Sarna S, Rantasalo I. *The Finnish Twin Registry: Baseline Characteristics. Section I: Materials, Methods, Representativeness and Results for Variables Special to Twin Studies.* Helsinki, Finland: Kansanterveyslaitoksen julkaisu M47; 1979.
31. Simonen RL, Videman T, Kaprio J, Levalahti E, Battie MC. Factors associated with exercise lifestyle--a study of monozygotic twins. *Int J Sports Med.* 2003;24(7):499-505.

32. Boos N, Wallin A, Gbedegbegnon T, Aebi M, Boesch C. Quantitative MR imaging of lumbar intervertebral disks and vertebral bodies: Influence of diurnal water content variations. *Radiology*. 1993;188(2):351-354.
33. Botsford DJ, Esses SI, Ogilvie-Harris DJ. In vivo diurnal variation in intervertebral disc volume and morphology. *Spine*. 1994;19(8):935-940.
34. Raininko R, Manninen H, Battie MC, Gibbons LE, Gill K, Fisher LD. Observer variability in the assessment of disc degeneration on magnetic resonance images of the lumbar and thoracic spine. *Spine*. 1995;20(9):1029-1035.
35. Sørensen KH. *Scheuermann's Juvenile Kyphosis: Clinical Appearances, Radiology, Aetiology, and Prognosis*. Copenhagen: Munksgaard; 1964.
36. Genant HK, Wu CY, van Kuijk C, Nevitt MC. Vertebral fracture assessment using a semiquantitative technique. *J Bone Miner Res*. 1993;8(9):1137-1148.
37. Bill Sribney S. Estimating correlations with survey data. . <http://www.stata.com/support/faqs/stat/survey.html>. Updated 2005. Accessed 10/15, 2007.
38. Harrison DD, Harrison DE, Janik TJ, Cailliet R, Haas J. Do alterations in vertebral and disc dimensions affect an elliptical model of thoracic kyphosis? *Spine*. 2003;28(5):463-469.
39. Aharinejad S, Bertagnoli R, Wicke K, Firbas W, Schneider B. Morphometric analysis of vertebrae and intervertebral discs as a basis of disc replacement. *Am J Anat*. 1990;189(1):69-76.
40. Scoles PV, Latimer BM, DigIovanni BF, Vargo E, Bauza S, Jellema LM. Vertebral alterations in Scheuermann's kyphosis. *Spine*. 1991;16(5):509-515.
41. Biering-Sorensen F, Hansen FR, Schroll M, Runeborg O. The relation of spinal x-ray to low-back pain and physical activity among 60-year-old men and women. *Spine*. 1985;10(5):445-451.
42. Donescu OS, Battie MC, Videman T. The influence of magnetic resonance imaging findings of degenerative disease on dual-energy X-ray absorptiometry measurements in middle-aged men. *Acta Radiol*. 2007;48(2):193-199.
43. Ismail AA, Cooper C, Felsenberg D, et al. Number and type of vertebral deformities: Epidemiological characteristics and relation to back pain and height loss. European Vertebral Osteoporosis Study group. *Osteoporos Int*. 1999;9(3):206-213.
44. O'Neill TW, Felsenberg D, Varlow J, Cooper C, Kanis JA, Silman AJ. The prevalence of vertebral deformity in European men and women: The European Vertebral Osteoporosis Study. *J Bone Miner Res*. 1996;11(7):1010-1018.
45. Battie MC, Videman T, Parent E. Lumbar disc degeneration: Epidemiology and genetic influences. *Spine*. 2004;29(23):2679-2690.

## **CHAPTER 7: ARE MRI FINDINGS OF THE THORACIC SPINE ASSOCIATED WITH A HISTORY OF UPPER OR MID-BACK PAIN IN MEN?**

(Submitted for publication)

### **INTRODUCTION**

While several studies have examined the association between imaging findings and pain reports in the cervical and lumbar regions, the thoracic region of the spine has received very little attention. Yet, in a recent study of Finnish men, 17% reported having had upper or mid-back pain during the prior year, and 23% of those noted associated disability.<sup>1</sup>

Upper or mid-back pain can be elicited from a number of structures in the spine, such as intervertebral discs, spinal ligaments, facet joints, costovertebral and –transverse joints, and muscles<sup>2-9</sup> but similar to low-back pain the relevance of specific imaging findings to pain is often unknown.<sup>10</sup> Only one study was found that looked at the association of degenerative findings using MRI and upper or mid-back pain. It was a small case-control study of 10 patients and 15 controls, demonstrating an association between pain and disc degeneration, defined as a decrease in disc signal with or without disc height narrowing on MRI.<sup>11</sup> However, in addition to the small sample size, several questions related to the methodology of the study remain about the assessment protocol, blinding and measurement reliability. Two x-ray studies from several decades ago, one of 1200 workers<sup>12</sup> and another of a general population sample of 444 men and women aged 15 to over 75 years,<sup>13</sup> were conducted to examine the association of thoracic disc degeneration (osteophytes with or without disc height narrowing) with pain. While neither study found an association with pain, a trend towards an association was observed in one<sup>12</sup> but the prevalence of upper or mid-back pain was too low to detect statistically significant association. The prevalence of upper or mid-back pain was not reported in the other study.<sup>13</sup> Further, Wood et al.<sup>14</sup> reported that imaging findings believed to be symptomatic, such as annular tears, disc herniations, and spinal cord deformation, were also seen in subjects without upper or mid-back pain.

The goal of this study was to examine the association between MRI findings of the lower thoracic region (T6-T12) and upper or mid-back pain over the past 12 months in a general population sample of men, while controlling for age and other possible confounding factors. MRI findings of interest included disc height narrowing, disc signal, disc bulging, osteophytes, endplate irregularities and vertebral deformities suggestive of fracture. We were particularly interested in disc height narrowing as an indicator of substantial disc degeneration because of its association with low-back pain history when found in the lumbar spine.

## **METHODS**

A cross-sectional study was conducted to examine the association of thoracic MRI findings and recent upper or mid-back pain history.

### *Subjects*

The 600 subjects (152 monozygotic (MZ) and 148 dizygotic (DZ) twin pairs) were selected from the population-based Finnish Twin Cohort.<sup>15</sup> Back pain was not taken into account in the selection process, which has been described in more detail elsewhere.<sup>16</sup> The representativeness of the sample of MZ twins has been previously examined and no statistically significant differences between the MZ subjects and the Cohort, which is representative of the total Finnish population,<sup>17</sup> were found for level of education, level of leisure-time physical activity, outdoor and indoor work, shift work, work monotony, health behaviour (such as smoking), and history of work-incapacitating neck or back pain. The only statistically significant differences were for current work status (working versus not working) and physical demands at work. Subjects were more likely to be employed and working in slightly more physically-demanding jobs.<sup>18,19</sup> The same selection process as for MZ subjects was applied to the sample of DZ subjects.

Ethical Committees of the Department of Public Health of the University of Helsinki and the University of Alberta approved the study protocols and informed consent was obtained before participation.

### *MR Imaging and Assessments*

T2- and PD -weighted MR images of the lower thoracic spine, including T6-T12, were obtained using either a 1.5-Tesla Magnetom or Vision scanner (Siemens AG, Erlangen, Germany) with surface coil. Qualitative assessments of disc height narrowing, anterior and posterior bulging, and endplate irregularities, were performed by an experienced spine surgeon from three mid-sagittal sections. Each MRI finding was rated using a scale from 0 to 3, with 0 being normal and 1-3 representing progressive degrees of severity. Custom-made image analysis software (SpEx<sup>®</sup>, Edmonton, Canada) was used to acquire quantitative data on disc characteristics for T6-T7 through T11-T12 discs from the mid-sagittal section. The quantitative assessment process has previously been described and included disc signal, anterior and posterior disc bulging, and osteophytes. (Niemeläinen et al. 2007, in press) The intraobserver reliability coefficients (ICC) for quantitative assessments varied from 0.97 for disc signal to 0.65 for posterior osteophytes and for the qualitative assessments from 1.00 for posterior bulging to 0.70 for disc height narrowing. Additionally, vertebral deformities, suggestive of fracture, were visually assessed according to a grading scheme by Genant et al.<sup>20</sup>

### *Upper or mid-back pain history*

An extensive, structured interview was carried out for each participant to determine pain history and exposure to suspected risk factors for common musculoskeletal problems. Upper or mid-back pain frequency, intensity and interference with daily activities due to the pain over the past 12 months were determined for each participant through self-report. The frequency of pain was indicated with one of the seven following options: *daily, weekly, monthly, several times a year, 2-3 times a year, once a year or none at all*. The pain intensity of the worst episode was rated on a numeric pain scale from 0 to 100, with 0 being no pain and 100 being the worst pain imaginable. Interference with daily activities because of the pain was assessed by indicating the number of days when the subject experienced difficulties doing daily work at home or at work.

In an effort to identify subjects with a recent history of a 'substantial' upper or mid-back pain problem, a summary severity variable was created based on the measures of pain intensity and interference with daily activities. The dichotomous variable denoted



the presence (23 subjects, 4.4 %) or absence (496 subjects, 95.6%) of a history of upper or mid-back pain intensity rated equal to or greater than 80 on the VAS and/or associated difficulties in daily activities due to the pain. The cut-off value for severe pain was selected based on two earlier studies, one suggesting that the mean value for “severe” pain is 75 mm on a scale from 0 to 100<sup>21</sup> and another finding where most subjects reporting “severe” pain rated their pain intensity 80 mm or greater.<sup>22</sup>

Diseases that may be responsible for referred pain to the thoracic region were identified following the Evidence-based Management of Acute Musculoskeletal Pain – guidelines section on Acute Thoracic Spinal Pain.<sup>10</sup> The diseases include myocardial ischemia, peptic ulcer, pancreatitis, renal colic, acute pyelonephritis, acute cholecystitis and dissecting thoracic aorta. During the interview, all subjects were asked to note any diagnosed disease(s) and were specifically asked about kidney diseases. In addition, the MZ subjects were also queried specifically about diagnosed liver, stomach and intestinal diseases. All subjects were asked about current medications and those with medication for coronary heart disease were noted.

#### *Possible confounding factors*

In addition to age, the following possible confounding factors for the previous 12 months obtained from the interview data were considered, including job physical demands score (1-4, higher values indicate progressively greater degrees of materials handling and work in bent or twisted positions), sitting/sedentary work, lifting at work, occupational driving, physically heavy leisure-time activities, cigarette smoking, height, and body mass index, which have been described in detail previously.<sup>19</sup>

#### *Data analysis*

The analyses were performed using STATA’s statistical software (STATACorp 2007, version 9.2 SE, College Station, TX) adjusting for age and treating each twin pair as a cluster to obtain correct p-values and confidence intervals. Ordinal logistic regression was used to examine the association of MRI findings with frequency of pain reports and binary logistic regression with the summary severity variable. The Brant test was used to test for the proportional odds assumption in ordinal logistic regression. Odds-ratios (OR) with 95% confidence intervals (CI) were reported. For analyses, pain frequency was

placed into four categories because of the low number of cases in some categories (Table 7-1). Similarly, the qualitative MRI findings were collapsed into two or three categories because of the low prevalence of findings. Disc height narrowing and endplate irregularity categories were collapsed by combining moderate and severe findings, and disc bulging to denote presence or absence of bulging.

**Table 7-1.** The prevalence of upper or mid-back pain in frequency categorizations (n=519).

<b>Frequency of pain</b>	<b>% (n)</b>
None	82.9 (430)
1-3 times a year	8.1 (42)
Monthly to several times a year	5.6 (29)
Daily to weekly	3.5 (18)

The association of MRI findings with pain was examined using: 1) the mean score for the MRI findings at all levels from T6-T7 through T11-T12, and 2) the highest score found at any one level. All variables significant in crude analyses were candidates for the multivariable model. Confounding was deemed to be present if a 20% change in the point estimate resulted from the inclusion of a possible confounder.

## **RESULTS**

### *Subject characteristics and associated findings*

Of the 600 potential subjects, 20 did not have thoracic MR images. A further 53 subjects were excluded because the image data were in a format which was not compatible with the remaining images in DICOM format. Additionally, three subjects were excluded because of poor image quality. Another subject was excluded due to missing data on upper or mid-back pain. The subjects reporting a history of kidney and liver conditions had all been previously treated and none reported currently existing conditions. Two subjects had ongoing symptoms due to duodenal ulcer, two due to stomach irritation, and eight subjects were currently taking medication for coronary heart disease. Of these 12 subjects, four reported upper or mid-back pain and were removed from the analyses. Thus, the total number of subjects with quantitative MRI measurements available was 519 men (285

MZ and 234 DZ subjects), with a mean age of 49.9 years (SD 7.8). Qualitative MRI assessment data were missing for five additional subjects. Subject characteristics and possible confounding factors are presented in Table 7-2.

**Table 7-2.** Subject characteristics and possible confounding factors (n=514-519).

<b>Variables</b>	<b>Mean (SD)</b>
Mean-weighted occupational demands score (1-4)	1.9 (1.3)
Involvement in physically demanding leisure-time activities (0-1)	0.2 (0.4)
Sitting, hrs / day	1.9 (2.5)
Driving, hrs / day	1.5 (2.7)
Maximum weight lifted at work at least once a month, kg	57 (31)
Mean-weighted lifting at work (kg x frequency /day)	771 (1565)
Smoking, pack-years	14.1 (17.2)
Height, cm	175 (6)
Body mass index	25.8 (3.2)

Of the 519 subjects, 17.1% (89 men) reported having had upper or mid-back pain in the previous year, with a reported mean pain intensity score of 38.2 (SD 24.4) on a scale from 0-100. Of those 89 men with pain, 23.6% (21 men) reported interference with daily activities on 35.7 days in mean (SD 78.3); the median was 12 days. The prevalence of upper or mid-back pain in the frequency categories is noted in the Table 7-1. Among those with pain, measures of pain frequency and intensity were correlated ( $r=0.25$ ,  $p=0.03$ ), as were frequency and intensity with whether or not interference with daily activities was reported ( $r=0.29$ ,  $p=0.006$  and  $r=0.63$ ,  $p<0.0001$ , respectively), adjusting for age and co-twin correlation.

Qualitative MRI assessments revealed moderate-to-severe disc height narrowing and endplate irregularities in 7% and 4.1% of discs, respectively, whereas 51.3% and 82.5% of the discs were deemed normal. Disc bulging was only mild, when present, in 7.6% and 4.9% of the discs, anteriorly and posteriorly. Moderate-to-severe vertebral deformities were present in 6.2% of the subjects. Means and standard deviations for the MRI findings of interest are presented in Table 7.3 for the mean scores across the levels and for the highest scores found at any one level.

**Table 7-3.** The means and standard deviations (SD) for the MRI findings using the mean score and the highest score to denote the level of degeneration.

<b>MRI findings</b>	<b>Mean score<sup>#</sup> (SD)</b>	<b>Highest score* (SD)</b>
Disc height narrowing (0-2) <sup>a</sup>	0.6 (0.4)	1.0 (0.6)
Endplate irregularities (0-2) <sup>a</sup>	0.2 (0.2)	0.9 (0.8)
Anterior bulging (0-1) <sup>a</sup>	0.08 (0.2)	0.3 (0.4)
Posterior bulging (0-1) <sup>a</sup>	0.05 (0.1)	0.2 (0.4)
Disc signal (0-1) <sup>b</sup>	0.33 (0.05)	0.27 (0.05)
Anterior bulge (distance, mm)	0.5 (0.3)	1.1 (1.0)
Posterior bulge (distance, mm)	0.1 (0.1)	0.5 (0.4)
Anterior osteophytes (area, mm <sup>2</sup> )	1.1 (0.6)	2.6 (1.5)
Posterior osteophytes (area, mm <sup>2</sup> )	0.7 (0.3)	1.4 (0.7)

<sup>#</sup>Mean score from the levels T6-T7 through T11-T12

\*Highest score found at any level.

<sup>a</sup>Qualitative assessments

<sup>b</sup>Higher value is better

#### *Crude associations*

Of the multiple comparisons, only the qualitatively-assessed mean score for anterior bulging ( $p < 0.05$ ) was associated with upper or mid-back pain frequency after controlling for age. A unit increase in the mean anterior bulging (i.e. no bulging at all discs compared to mild to moderate bulging at all discs) increased the odds of reporting more frequent upper or mid-back pain by 5.3 (95 % CI: 1.2, 23.6), as compared to pain of lesser frequency or none at all.

Conversely, several MRI findings (disc height narrowing, endplate irregularities, anterior bulging and posterior osteophytes), either expressed as the mean score or the highest score, were associated ( $p < 0.05$ ) with the presence of severe upper or mid-back pain after adjusting for age. One unit increase in the mean score for disc height narrowing (0-2) increased the subject's likelihood of reporting severe pain 3.1-times (95 % CI: 1.2, 8.1), as compared to the absence of severe pain. A unit increase in the mean and the highest score for endplate irregularities (0-2) resulted in an increased likelihood of 4.7-times (95 % CI: 1.2, 18.8) and 2.0-times (95 % CI: 1.1, 3.6), respectively, to report severe pain. Similarly, a unit increase in the qualitatively-assessed anterior bulging (0-1) increased the

subject's likelihood 7.7-fold (95% CI: 1.3, 46.3) for the mean score and 3.0-fold (95% CI: 1.2, 7.5) for the highest score to report severe pain. And lastly, a unit increase in the quantitatively-measured posterior osteophytes (area, mm<sup>2</sup>) resulted in the increased risks of 2.1-times (95% CI: 1.5, 2.8) for the mean score and 1.3-times (95% CI: 1.1, 1.7) for the highest score to report severe pain.

#### *Multivariable analysis for severe upper or mid-back pain*

No confounding by physical loading, behavioral and anthropometric factors (Table 7-2) was observed for any of the associations between MRI findings and pain reports. No multivariable model was created for the pain frequency since only one MRI finding was significantly associated with frequency of pain in crude analyses. Of the seven candidate MRI findings for severe pain from crude analyses, quantitatively-assessed mean posterior osteophytes (OR: 2.1; 95% CI: 1.5, 2.8) was included in the final model first because it was the variable most highly associated with severe pain. No other MRI variable contributed to the multivariable model at a statistically significant level after mean posterior osteophytes was in the model adjusting for age.

## **DISCUSSION**

To our knowledge this is the first study to examine the association between MRI findings and pain in the thoracic region in a population-based sample. Anterior bulging of the disc was associated with pain frequency and posterior osteophytes with severe pain, supporting an association of thoracic MRI findings with upper or mid-back pain.

Based on the earlier studies, that found an association between disc height narrowing and low-back pain over the prior 12 months<sup>23-25</sup> and low-back pain ever,<sup>26</sup> we initially expected that disc height narrowing would be associated with a history of upper or mid-back pain. Even though we found an association between disc height narrowing and severe upper or mid-back pain, it was only observed for the mean score for disc height narrowing and in crude analysis only. Also, contrary to what was expected, the mean scores for MRI findings across the levels examined tended to be more associated with severe pain than the highest scores. However, similar to our findings with pain frequency,

Luoma et al.<sup>27</sup> also found anterior bulging to be associated with low-back pain while posterior osteophytes have<sup>25</sup> and have not<sup>26</sup> been found to be associated with back pain.

Several challenges in assessing thoracic MRI findings and their association with pain exist. Similar to the lumbar region, the thoracic region is a site of referred pain from other structures and organs, which is made possible by the confluence of afferent nerve fibres from disparate areas within the dorsal horn of the spinal cord causing distorted central perception of the site of pain<sup>28,29</sup> and the extensive longitudinal orientation of the dural nerves<sup>30</sup> which may cause pain to be referred from a distant site of the spine. Although an effort was made to identify subjects with the possibility of referred pain of visceral origin, some subjects may have had ongoing conditions that had not been diagnosed and treated or reported. Even though it is important to be aware of the possibility of serious underlying pathology, such as cancer, most patients presenting in primary care with back pain have pain of mechanical origin.<sup>31,32</sup>

The recall of upper or mid-back pain over the prior 12 months and associated misclassification presents another challenge for examining the association between pain reports and MRI findings. The outcome variable, based on pain intensity and interference with daily activities, was created in an effort to capture substantial pain problems and eliminate those that were mild or inconsequential since disc degeneration (disc height narrowing and osteophytes) has been found to be more likely associated with incapacitating rather than trivial pain.<sup>33</sup> Also, given the episodic nature of back pain problems, while imaging findings are mostly cumulative and irreversible,<sup>24</sup> it may not be surprising that associations between imaging findings and pain parameters have been clearer for lifetime parameters than for current or recent symptoms.<sup>24,25,33</sup>

However, the strengths of this study include the representativeness of the population-based sample<sup>18</sup> and the extensive interview data on subjects' exposure to suspected behavioural and environmental risk factors, which allowed for control of possible confounders of the association between pain reporting and MRI findings. On the other hand, the limitations of the study include the low prevalence of some findings, such as posterior bulging, which poses limitations to identifying associations. In addition, examining the MRI findings only from the T6 vertebra caudally, may have resulted in missing MRI findings in the upper thoracic region that may have been responsible for pain. This may

be more problematic for the highest score than for the mean score, as the latter may be less affected by missing levels. This is supported by two retrospective studies on patients<sup>34,35</sup> that found MRI findings, such as herniations, osteophytes and disc and endplate degeneration, to be more prevalent in the middle to low thoracic regions than in the upper region. Furthermore, the three middle sagittal sections were used for qualitative MRI assessments, but quantitative measurements were only taken from the mid-sagittal sections, which may have led to missing some findings in the thoracic levels examined. Also, while the intraobserver reliability was adequate to examine the associations between MRI findings and pain reports, the assessments may vary between observers, affecting comparisons between studies. This is especially the case for qualitative assessments that require making subjective decisions. These limitations can be expected to have diluted the associations between thoracic MRI findings and pain reports. It is also noteworthy that even though quantitatively-assessed posterior osteophytes were most highly associated with severe pain in the multivariable model, their higher association as compared to some other MRI findings could have been due to more accurate measurement.

In conclusion, several MRI findings were associated with severe upper or mid-back pain, while only anterior bulging was associated with pain frequency. In multivariable modelling for severe pain, the mean score for posterior osteophytes across the spinal levels was the only MRI variable to enter the model for severe pain after controlling for age. Due to measurement limitations, the observed associations between thoracic MRI findings and upper or mid-back pain history are likely to be under-estimations of the 'true' associations. While this study supports an association of thoracic degenerative findings in upper or mid-back pain, it is not known whether the observed associations are directly associated with severe pain or indirectly associated via some other degenerative finding or other phenomenon that was not assessed in the current study. Similar to the lumbar region, the MRI findings associated with upper or mid-back pain also occurred commonly in subjects without reported pain and, therefore, the MRI findings by themselves are of limited clinical value.

## REFERENCES

1. Niemelainen R, Videman T, Battie MC. Prevalence and characteristics of upper or mid-back pain in Finnish men. *Spine*. 2006;31(16):1846-1849.
2. Bogduk N, Tynan W, Wilson AS. The nerve supply to the human lumbar intervertebral discs. *J Anat*. 1981;132(1):39-56.
3. Bogduk N. The innervation of the lumbar spine. *Spine*. 1983;8(3):286-293.
4. Mooney V, Robertson J. The facet syndrome. *Clin Orthop Relat Res*. 1976;(115):149-156.
5. Jayson MI. Mechanisms underlying chronic back pain. *BMJ*. 1994;309(6956):681-682.
6. Brown MF, Hukkanen MV, McCarthy ID, et al. Sensory and sympathetic innervation of the vertebral endplate in patients with degenerative disc disease. *J Bone Joint Surg Br*. 1997;79-B(1):147-153.
7. Jackson HC, 2nd, Winkelmann RK, Bickel WH. Nerve endings in the human lumbar spinal column and related structures. *J Bone Joint Surg Am*. 1966;48-A(7):1272-1281.
8. Pedersen HE, Blunck CF, Gardner E. The anatomy of lumbosacral posterior rami and meningeal branches of spinal nerve (sinu-vertebral nerves); with an experimental study of their functions. *J Bone Joint Surg Am*. 1956;38-A(2):377-391.
9. Mendel T, Wink CS, Zimny ML. Neural elements in human cervical intervertebral discs. *Spine*. 1992;17(2):132-135.
10. Australian Acute Musculoskeletal Pain Guidelines Group. Acute thoracic spinal pain. In: *Evidence-Based Management of Acute Musculoskeletal Pain (Available at: <http://www.nhmrc.gov.au>)*. Brisbane, Australia: Australian Academic Press; 2003:63-82.
11. Bruckner FE, Greco A, Leung AW. 'Benign thoracic pain' syndrome: Role of magnetic resonance imaging in the detection and localization of thoracic disc disease. *J R Soc Med*. 1989;82(2):81-83.
12. Hult L. Cervical, dorsal and lumbar spinal syndromes; a field investigation of a non-selected material of 1200 workers in different occupations with special reference to disc degeneration and so-called muscular rheumatism. *Acta Orthop Scand Suppl*. 1954;17:1-102.
13. Lawrence JS, de Graaff R, Laine VAI. Degenerative joint disease in random samples and occupational groups. In: Kellgren JH, Jeffrey MR, Ball J, eds. *The Epidemiology of Chronic Rheumatism*. Vol 1. Oxford, UK: Blackwell; 1963:98-119.
14. Wood KB, Garvey TA, Gundry C, Heithoff KB. Magnetic resonance imaging of the thoracic spine. Evaluation of asymptomatic individuals. *J Bone Joint Surg Am*. 1995;77-A(11):1631-1638.
15. Kaprio J, Koskenvuo M, Langinvainio H, Romanov K, Sarna S, Rose RJ. Genetic influences on use and abuse of alcohol: A study of 5638 adult Finnish twin brothers. *Alcohol Clin Exp Res*. 1987;11(4):349-356.
16. Battie MC, Videman T, Levalahti E, Gill K, Kaprio J. Heritability of low back pain and the role of disc degeneration. *Pain*. 2007;131(3):272-280.



17. Kaprio J, Koskenvuo M, Artimo M, Sarna S, Rantasalo I. *The Finnish Twin Registry: Baseline Characteristics. Section I: Materials, Methods, Representativeness and Results for Variables Special to Twin Studies*. Helsinki, Finland: Kansanterveystieteen julkaisuja M47; 1979.
18. Simonen RL, Videman T, Kaprio J, Levalahti E, Battie MC. Factors associated with exercise lifestyle--a study of monozygotic twins. *Int J Sports Med*. 2003;24(7):499-505.
19. Battie MC, Videman T, Gibbons LE, Fisher LD, Manninen H, Gill K. Determinants of lumbar disc degeneration. A study relating lifetime exposures and magnetic resonance imaging findings in identical twins. *Spine*. 1995;20(24):2601-2612.
20. Genant HK, Wu CY, van Kuijk C, Nevitt MC. Vertebral fracture assessment using a semiquantitative technique. *J Bone Miner Res*. 1993;8(9):1137-1148.
21. Collins SL, Moore RA, McQuay HJ. The visual analogue pain intensity scale: What is moderate pain in millimetres? *Pain*. 1997;72(1-2):95-97.
22. Jensen MP, Chen C, Brugger AM. Interpretation of visual analog scale ratings and change scores: A reanalysis of two clinical trials of postoperative pain. *J Pain*. 2003;4(7):407-414.
23. Kjaer P, Leboeuf-Yde C, Korsholm L, Sorensen JS, Bendix T. Magnetic resonance imaging and low back pain in adults: A diagnostic imaging study of 40-year-old men and women. *Spine*. 2005;30(10):1173-1180.
24. Videman T, Battie MC, Gibbons LE, Maravilla K, Manninen H, Kaprio J. Associations between back pain history and lumbar MRI findings. *Spine*. 2003;28(6):582-588.
25. Pye SR, Reid DM, Smith R, et al. Radiographic features of lumbar disc degeneration and self-reported back pain. *J Rheumatol*. 2004;31(4):753-758.
26. Torgerson WR, Dotter WE. Comparative roentgenographic study of the asymptomatic and symptomatic lumbar spine. *J Bone Joint Surg Am*. 1976;58(6):850-853.
27. Luoma K, Riihimaki H, Luukkonen R, Raininko R, Viikari-Juntura E, Lamminen A. Low back pain in relation to lumbar disc degeneration. *Spine*. 2000;25(4):487-492.
28. Doherty GM. The acute abdomen. In: Doherty GM, Way LW, eds. *Current Surgical Diagnosis and Treatment*. 12th ed. Los Altos, C.A.: Lange Medical Publications; 2006:479-492.
29. Levitt MD. Approach to the patient with abdominal pain. In: Kelley WN, ed. *Textbooks of Internal Medicine*. Vol 1. 3rd ed. Philadelphia, PA: Lippincott-Raven; 1997:593-599.
30. Groen GJ, Baljet B, Drukker J. The innervation of the spinal dura mater: Anatomy and clinical implications. *Acta Neurochir (Wien)*. 1988;92(1-4):39-46.
31. Deyo RA, Diehl AK. Cancer as a cause of back pain: Frequency, clinical presentation, and diagnostic strategies. *J Gen Intern Med*. 1988;3(3):230-238.
32. Deyo RA, Phillips WR. Low back pain. A primary care challenge. *Spine*. 1996;21(24):2826-2832.
33. Lawrence JS. Disc degeneration. Its frequency and relationship to symptoms. *Ann Rheum Dis*. 1969;28(2):121-138.

34. Tan CIC, Song S, Edmondston SJ, Singer KP. Patterns of thoracic disc degeneration from MRI: Age, gender and spinal level influences. *JMR*. 2001;5(4):269-278.
35. Girard CJ, Schweitzer ME, Morrison WB, Parellada JA, Carrino JA. Thoracic spine disc-related abnormalities: Longitudinal MR imaging assessment. *Skeletal Radiol*. 2004;33(4):216-222.

## **CHAPTER 8: GENERAL DISCUSSION AND CONCLUSIONS**

### **OVERVIEW**

The literature on imaging findings and pain in the cervical and lumbar regions of the spine is abundant, but information on the thoracic region remains relatively scarce. The often expressed explanation for this lack of interest is that the thoracic region is less commonly identified in relation to pain than the other spinal regions. The presence of ribs and their connections with the discs and vertebrae may result in lesser forces across the thoracic region than in more mobile regions of the spine. However, thoracic structures are still subject to loading applied to the spine, as well as to the processes of aging, and when pain occurs it can present a significant problem.

This thesis contributes to the currently scarce knowledge of thoracic problems by describing the prevalence and characteristics of upper or mid-back pain and degenerative findings of the thoracic region, and examining associations between MRI findings and pain. It also introduces a new method to measure thoracic disc signal reflecting dehydration, which is the basic biochemical phenomenon in disc degeneration.

### **UPPER OR MID-BACK PAIN**

One objective of this thesis was to examine the one-year prevalence, intensity, frequency and associated interference in daily activities due to upper or mid-back pain, and to compare these with neck and low-back pain.

#### *Key findings*

- The prevalence of self-reported upper or mid-back pain was 17%, which was on average rated as 38 out of 100, a similar intensity to neck pain, and approximately one-quarter of the occurrence of neck and low-back pain.
- Associated disability in normal activities due to upper or mid-back pain was reported by 23% of the subjects, which was less than for neck (30%) and low-back (41%) pain.
- Upper or mid-back pain rarely occurred in isolation, but coexisted with neck and low-back pain.

### *Discussion*

The prevalence of upper or mid-back pain in this investigation was well in accordance with the previously reported prevalence rates in the general population of Scandinavians.<sup>1-3</sup> However, even though the subjects were found to be highly representative of Finnish men, they were more likely working and had slightly more physically demanding work than the referents. This difference between subjects and referents can be explained by the selection of pairs that was partly based on these occupational factors. The impact of this, if any, on the results is not clear. It is possible that the so-called healthy-worker effect, where those with more pain have discontinued working, may have led to an underestimation of prevalence of pain in general population. On the other hand, one could speculate that greater occupational demands could exacerbate symptoms leading to somewhat greater reporting.

The intensity and frequency of pain and interference with daily activities indicate the importance of upper or mid-back pain when present to the individual, regardless of the relatively low prevalence. Further, the similarity of pain intensity<sup>4-6</sup> and associated interference with daily activities<sup>6-8</sup> with neck pain, and the coexistence of other musculoskeletal pain<sup>9-14</sup> found in this thesis are concordant with the literature. However, this thesis appeared to be the first investigation to examine all these aspects of spinal pain in the same sample to allow comparisons between neck, upper or mid-back and low-back pain.

Measurement of pain is difficult because of the lack of a gold standard or clear operational definition of pain. However, numeric pain scales, such as the one used in this thesis, are commonly accepted measures of pain intensity with face validity and understood by subjects.<sup>15</sup> Advantages of a numeric pain intensity scale are its ratio scale properties,<sup>16</sup> where equality of ratios is implied, and its use for rapid and simple assessments of pain.<sup>17</sup> Unfortunately, the reliability of the pain reports was not assessed in this thesis, but the questions to determine upper or mid-back prevalence are similar to other standardized pain questions that have demonstrated reasonable reliability.<sup>18,19</sup> Still, it is important to keep in mind that pain scores can never measure pain perfectly, but that they also reflect both measurement error and systematic individual differences.<sup>20</sup>

Recently, a consensus question for back pain prevalence studies was suggested in order to standardize the definitions of back pain where the suggested timeframe to determine the prevalence of back pain was 4 weeks.<sup>21</sup> However, in the current thesis upper or mid-back pain was queried over the past 12 months because the associations between imaging findings and pain were also of interest. As a result of the cumulative nature of imaging findings, associations between recent pain reports and imaging findings may be missed. However, the common criticisms of the methodological quality of prevalence studies such as unclear reporting of the methods, the lack of analyses of non-respondents and questionable representativeness of the samples,<sup>22-25</sup> have been addressed in this thesis.

### **MRI FINDINGS OF THE THORACIC REGION**

Another objective of this thesis was to examine the prevalence and characteristics of MRI findings in the thoracic region by level (from T6 through T12 vertebrae), and the association of these findings with age and one another. The following MRI findings were examined from the MR images: disc signal, disc height narrowing, disc bulging, osteophytes, endplate irregularities, Scheuermann's disease, vertebral deformities and hemangiomas, and were assessed either qualitatively or quantitatively. As a first step, a methodological problem with quantitative thoracic disc signal measurements was identified and addressed by conducting a study of the reliability and validity of using the spinal cord as an intra-body reference for disc signal measurements.

#### *Key findings*

- Spinal cord-adjustment was found to offer a reliable and valid method to perform quantitative measurements of thoracic disc signal.
- MRI findings of the thoracic region associated with disc degeneration appeared less commonly than what has been previously reported for the lumbar region. In particular, posterior bulging of the thoracic discs was relatively rare and mild when present.

- Most of the MRI findings examined were rated as mild. Severe findings were only observed for disc height narrowing and endplate irregularities, and with a very low prevalence ( ~1 %).
- MRI findings varied by level. For example, quantitatively-measured anterior bulging varied from 1.5% at the T6-T7 level to 30.8% at the T11-T12 level.
- The prevalence rates for Scheuermann's disease, vertebral hemangiomas and moderate-to-severe vertebral deformities were 14.1%, 2.1% and 6.1%, respectively.
- The MRI finding with the greatest association with age was disc signal ( $r=0.31$  to  $-0.42$  by level), as has also been found in the lumbar spine.<sup>26</sup> Also similar to previous reports of MRI findings in the lumbar spine,<sup>27</sup> several findings commonly coexisted at the same spinal levels, such as bulging and osteophytes anteriorly ( $r=0.35-0.61$ ) and disc height narrowing and disc signal ( $r=0.29-0.46$ ).
- Qualitative assessments of degenerative findings appear to depend substantially on individual judgments that can vary and, therefore, provide only gross estimates of prevalence rates.

### *Discussion*

This thesis found *spinal cord-adjusted quantitative disc signal measurements* to offer reliable and valid information of disc degeneration, which may also allow for detection of small differences in disc signal. Spinal cord was chosen because of its homogeneous appearance on MRI. While the amount of white and grey matter is not constant throughout the spinal levels,<sup>28</sup> the ratio of white matter to grey matter should be less affected, especially in the mid-sagittal sections of the thoracic levels which were used in this thesis. Spinal cord-adjusted disc signal measurements resulted in similar correlations with age CSF-adjusted disc signal measurements, which have been regarded as the MRI finding most highly associated with age in the lumbar spine,<sup>26</sup> supporting the validity of using spinal cord as an intra-body reference. However, the main advantage of spinal cord over CSF was clearly fewer missing adequate reference samples resulting in exclusion of fewer disc levels.

It was also found that the only thoracic MRI findings qualitatively-rated as severe were disc height narrowing and endplate irregularities (including Schmorl's nodes). A greater occurrence of Schmorl's nodes in the thoracic region have been reported than in the lumbar region,<sup>27,29-32</sup> but no clear explanation for the difference has been offered. Several theories of the cause of the Schmorl's nodes have been suggested which all emphasize weakening of the endplates<sup>33-38</sup> but it is not clear why the thoracic region would be affected more than the lumbar region. Interestingly, Schmorl's nodes appear commonly in the lower thoracic levels which are also common sites for vertebral fractures,<sup>39</sup> perhaps due to the greater susceptibility to axial loading caused by the sudden change in the facet joint orientation. Hence, one theory highlights the role of trauma in the formation of Schmorl's nodes<sup>37</sup> because of the greater occurrence of nodes in persons subjected to higher axial loading, such as gymnasts<sup>40</sup> and motorcyclists.<sup>37</sup>

Another finding from this thesis is that MRI findings of the thoracic region were more common *anteriorly*, which has been explained by the thoracic kyphosis.<sup>41</sup> The thoracic region is concave anteriorly and the line of the center of gravity passes anterior to the vertebral bodies,<sup>42,43</sup> which causes greater mechanical loads to be imposed on the anterior aspects of the vertebral bodies and discs.<sup>44,45</sup> The rare occurrence of posterior findings, such as posterior bulging, may also be explained by the more prominent longitudinal ligament posteriorly than anteriorly.<sup>46</sup> Usually, a separation in the measurement and reporting of anterior and posterior degenerative findings has not been done, limiting the comparisons between studies. However, similar to this thesis, Nathan found the occurrence of anterior osteophytes to be more common than posterior osteophytes.<sup>41</sup>

Additionally, the prevalence of thoracic MRI findings was found to depend on the *disc level*. Others have also reported characteristic patterns of degenerative findings at different thoracic levels. Malmivaara<sup>47</sup> found anterior degeneration (disc degeneration, osteophytes and Schmorl's nodes) to characterize the T10-T11 level and posterior degeneration (facet and costovertebral joints) to be dominant at the T12-L1 level, whereas both types of degeneration were demonstrated at the T11-T12 level. Similarly, Tan and colleagues<sup>48</sup> observed that degeneration in the nucleus and endplates occurred more often in the lower thoracic levels, degeneration in the annulus in the middle to low thoracic levels (T6-T7 to T11-T12) and osteophytes in the middle region (T4-T5 to T9-T10). These dif-

ferences in degeneration are likely explained by the morphological differences in the thoracic region (the connections with the ribs, the change in facet joint alignment and kyphosis) affecting the mechanical behaviour of the discs, and supporting reporting prevalence by level. For example, the alignment of the facet joints in the thoracic region offers little resistance to axial rotation, which combined with little resistance by ribs leads to restriction of axial rotation mainly by the discs.<sup>47,49-52</sup> The kyphosis, on the other hand, predisposes the anterior parts of the discs to higher compressive loads.

The other thoracic pathologies examined in this thesis were *Scheuermann's disease, and vertebral hemangiomas and deformities*. Scheuermann's disease was found slightly more commonly than in previous reports using a similar definition.<sup>53,54</sup> However, quantitative measurements of vertebral wedging in MRI may have resulted in more accurate measurements of wedging than in x-ray. A prevalence of 7.4% has been reported using anatomic inspections in a sample of historic collection of cadavers including spines from subjects of varying races. One-third of the subjects were females who had a lower prevalence of Scheuermann's disease than males and also one-third of the male subjects were black who also had a lower prevalence of Scheuermann's disease than white males.<sup>55</sup>

Vertebral deformities suggesting fracture are the most important manifestations of osteoporosis, but the prevalence rates vary between studies of general populations.<sup>56,57</sup> The differences are most likely caused by the different quantitative assessment protocols. Therefore, a validated semiquantitative method to assess vertebral deformities has been created.<sup>58</sup> Most of the reports on vertebral deformities also include mild deformities limiting the comparisons with this thesis where only moderate-to-severe deformities were included. However, several studies using the semiquantitative method have assessed incidental moderate-to-severe vertebral deformities in patients with chest images available and have found the prevalence to vary from 9.5% to 16%.<sup>59-61</sup> The lower prevalence in this thesis, may be explained by the inclusion of women and older subjects in the prior studies,<sup>59-61</sup> both which may increase the risk for vertebral deformities.<sup>56,62</sup>

In addition to vertebral deformities, this thesis also examined the prevalence of vertebral hemangiomas (2.1%), which has rarely been investigated. Only one previous study of general population sample was found examining the prevalence of vertebral he-



mangiomas using anatomic inspections. Among 3829 spines of all ages and both genders, the prevalence of hemangiomas was found to be 10.7%.<sup>35</sup> Contrary, in a sample of women 75 years or older, the reported prevalence was negligible 0.5%,<sup>63</sup> even though the prior study<sup>35</sup> found the prevalence to be higher in women and with age above 60 years. The reason for the differences between studies is therefore not clear. Anatomic inspections may have resulted in more accurate measurements of hemangiomas than X-ray since only sufficiently large hemangiomas are recognized as coarse vertical striations within the vertebral body on X-ray.<sup>64</sup> MRI, on the other hand, offers an enhanced ability to detect hemangiomas.<sup>64</sup> Hemangiomas are typically viewed as incidental, asymptomatic imaging findings,<sup>64,65</sup> but they can also be of clinical importance<sup>66</sup> by causing vertebral body collapses and neurological deficits.<sup>64</sup> Currently, vertebral hemangiomas are occasionally treated by percutaneous vertebroplasty (i.e. injecting cement into the vertebral body).<sup>67</sup>

With respect to associations of MRI findings with age, the greatest association was found for the spinal cord-adjusted measure of disc signal, supporting its construct validity as a degenerative parameter. In addition to disc signal, only anteriorly-occurring findings of osteophytes and bulging were associated with age, which seems to support the notion that age-related thoracic disc degeneration tends to occur anteriorly. Also, as a result of the interdependence of the disc structures it is not surprising that several MRI findings correlated with one another. The greatest associations were found for bulging and osteophytes, especially for those occurring anteriorly, and for disc height narrowing and disc signal. According to a theory proposed by Kirkaldy-Willis, disc bulging results in “temporary dysfunction” of the segment and osteophytes occur to support the unstable vertebra-disc-vertebra -unit.<sup>68</sup> In X-ray where soft tissues cannot be visualized, the presence of osteophytes is considered a sign of disc degeneration. In MRI, on the other hand, two commonly assessed findings of disc degeneration are disc signal and disc height narrowing. Disc signal is considered to be the earliest degenerative sign seen in MRI<sup>69</sup> and disc height narrowing is considered a sign of more advanced degeneration.<sup>70</sup> Qualitative assessments of disc height narrowing may be influenced by other concomitant degenerative findings, such as ‘dark’ discs, inflating their association with one another. The observed associations also likely were influenced by the different degree of measurement

error associated with the measures. Additionally, even though this thesis provides information as to which MRI findings appear to be associated, a longitudinal investigation of disc degeneration is required to assess the temporal relationship of the observed associations. This allows examining the sequence of occurrence of different degenerative findings and could offer further insights into the etiopathogenesis of disc degeneration.

This investigation of thoracic MRI findings has several strengths. One of the strengths is that only two scanners were used to perform the imaging. Differences between scanners exist, as was found in this thesis, in measurements of disc signal, and disc height measurements may also be affected. Yet, studies examining MRI findings and their associations seldom consider such issues. In a study of multiple sclerosis, Filippi et al.<sup>71</sup> found that the interscanner difference in assessing brain lesion volumes was 5.8% among 1.5 T scanners. The difference was smaller in the higher field strengths (1.5 T as opposed to 0.5 T or 1 T),<sup>71</sup> which have also yielded higher interobserver reliabilities of the appearance of the disc as compared to lower field strength (0.3 T).<sup>72</sup> However, the observed interscanner difference also includes repositioning of the subject, which alone may lead to differences between measurements.<sup>73,74</sup> It is important to be aware of measurement variation due to imaging, because even though ideally only one scanner should be used to perform the imaging this usually is not possible in real life, especially in longitudinal studies.

Another study strength was the development and use of a quantitative measure of thoracic disc signal. Quantitative measurements of thoracic disc signal had not been performed prior to this thesis. Aging discs undergo extensive biochemical alterations of which the most significant is the loss of proteoglycan,<sup>75,76</sup> leading to dehydration of the disc as the main phenomenon in disc degeneration.<sup>77,78</sup> Dehydration can be measured in T2-weighted imaging as a loss of signal,<sup>79</sup> but a sensitive and reliable method to measure thoracic disc signal was not previously available. MRI findings related to spinal disorders are commonly assessed qualitatively using subjective assessments, which often have low measurement reliability. Quantitative measurements offer more reliable and sensitive methods to measure disc degeneration and its progression, which are of value particularly when small associations are of interest, such as in longitudinal studies and ‘gene-hunting’ studies of polygenic conditions.

This investigation also has several limitations affecting the interpretation of results. One was the use of only *mid-sagittal sections* in quantitative measurements, which may have resulted in missed findings that were present laterally. Conversely, qualitative assessments included the three middle sections. Also, annular tears were not assessed. In T2-weighted imaging a normal annulus shows a low signal and, therefore, the material in the tear, which is more hydrated than a normal annulus, appears as a focus of increased signal.<sup>80</sup> If the whole disc appears dark in T2-weighted imaging, the detection of annular tears may be limited in MRI without the presence of appropriate contrast. However, “neither contrast enhanced images nor T2-weighted images demonstrate radial tears with a high degree of accuracy”.<sup>81</sup> In any event, the use of a contrast medium is not feasible in a large population sample. The presence of annular tears may also be detected in T2-weighted imaging as a region of high signal intensity (high intensity zone, HIZ) in a portion of the annulus that normally has low signal intensity.<sup>81</sup> The presence of HIZ was initially described as a marker for a painful disc,<sup>82</sup> but its role as a marker for discogenic pain currently remains unclear.<sup>83-87</sup>

Secondly, the assessed MRI findings were limited to the lower half of the thoracic region. Due to the restrictions in the field of view of the available images, T6 was chosen as the *uppermost level* because it was included in the majority of the available images. Thus, findings occurring above T6 were typically unavailable. The third limitation related to the study was the *MRI sequences* available. Due to practical reasons, only T2- and PD-weighted images were available, which can be acquired simultaneously. T1-weighted images, which show fluids as dark and fat-based tissues as bright<sup>88</sup> were not available; thus it was not possible to assess Modic changes (signal of the vertebral bone marrow).<sup>89</sup> Additionally, the imaging was conducted with the subjects supine, which could have decreased the size of bulges while some bulges could occur only in the upright position.<sup>90</sup> However, since most spine imaging is still performed in the supine position and the purpose of this thesis was to provide reference data, it is important that imaging is being performed in a similar position.

## ASSOCIATION OF MRI FINDINGS IN THE THORACIC REGION AND UPPER OR MID-BACK PAIN

The last part of this thesis examined the association of MRI findings of the thoracic region with upper or mid-back pain reporting. The objective was to examine these associations while controlling for possible behavioural and environmental confounding factors.

### *Key findings*

- Several MRI findings (disc height narrowing, endplate irregularities, anterior bulging and posterior osteophytes) were associated with a history of severe upper or mid-back pain in crude analyses after controlling for age, but only quantitatively-measured posterior osteophytes entered the multivariable model. Only qualitatively-assessed anterior bulging was associated with pain frequency.
- The observed associations are likely under-estimations of the 'true' associations due to measurement limitations in the study related to pain reports, imaging and the origin of pain. However, it remains unclear whether the observed associations with pain are direct or indirect via some other findings that were not measured.
- MRI findings associated with pain were also common in subjects without reported pain and therefore alone are of limited clinical value.

### *Discussion*

The findings of this thesis support modest association between MRI findings and upper or mid-back pain. A prior study also found anterior bulging<sup>91</sup> to be associated with LBP, while the association of posterior osteophytes with back pain has remained unclear.<sup>92,93</sup> Even though the anterior longitudinal ligament<sup>94,95</sup> and outer annulus<sup>95-98</sup> are innervated, the more frequently found anterior findings may not be clinically as meaningful as posterior findings where interference with the nerve roots and spinal cord can occur. However, the anterior longitudinal ligament has a denser innervation throughout its whole length than the posterior longitudinal ligament and could be more capable of producing pain.<sup>99</sup>

It was found that several MRI findings were associated with severe upper or mid-back pain, as compared to absence of severe pain, but only mean posterior osteophytes entered the multivariable model. Because of its highest association with severe pain,

mean posterior osteophytes was entered into the multivariable model first and no other MRI finding remained a significant predictor of severe pain to add to the model. It cannot be concluded that posterior osteophytes truly are more highly associated with severe pain than all the other measured MRI findings since the associations may have been influenced by different degrees of measurement error. Also, regardless of the associations with pain reports, similar MRI findings also commonly occurred in subjects without reported pain, which has also been the case in prior studies of the lumbar region.<sup>54,100,101</sup>

*Correlating pain and imaging findings* allows evaluating the importance of clinical observations of MRI findings.<sup>102</sup> However, any true correlation is likely to be diminished by the intermittent nature of back pain, with painful and pain-free periods, and the cumulative and mostly irreversible nature of the imaging findings.<sup>100</sup> An important aspect for the validity of the pain measurements in this thesis was that the subjects were queried about their pain in neutral environment without any benefits from reporting pain, such as compensation due to disability, which has increased pain reports.<sup>103,104</sup> The limitations in pain reporting are important to acknowledge. Pain is a subjective experience with important affective, cognitive, behavioural and sensory components,<sup>20</sup> which affect reporting and may have diluted the observed associations between MRI findings and pain.

Additionally, upper or mid-back pain can also arise from *structures other than discs and vertebral bodies*. The focus of this study was on degenerative findings of the disc and their role in pain, but almost all thoracic structures are capable of producing pain. For example, ossification of the spinal ligaments, such as the ligamentum flavum and posterior longitudinal ligament, can produce symptoms,<sup>105</sup> as can costovertebral arthritis.<sup>106</sup> Annular tears and Modic changes, both of which have been found to be associated with LBP,<sup>100,101,107-110</sup> could not be examined for their association with upper or mid-back pain due to the limitations in image data.

Also, the association of MRI findings with pain may have been diluted by the fact that the *location of the painful area* may not correspond to the origin of pain. In addition to referred pain of visceral origin; upper or mid-back pain can also be referred from somatic structures from adjacent regions. The difficulty to localize pain may be explained, at least partly, by the great amount of overlap between adjacent dural nerves, which may extend up to four levels caudally and cranially to the level of entry in the dural

plexus<sup>99,111,112</sup> and the existence of craniocaudal connections between the nerves of adjacent levels and between right and left sides.<sup>94,113,114</sup> Furthermore, the dual pattern of the sensory pathways of the vertebral column and discs via dorsal root and sympathetic pathways may lead to poorly localized pain.<sup>113,114</sup> Therefore, for example, pain in the scapular region can arise from cervical structures,<sup>115-118</sup> and disc herniation in the thoracic region can present with pain in the upper<sup>119-121</sup> and lower<sup>122-133</sup> extremities, in the flanks,<sup>126,134</sup> chest,<sup>123,135</sup> and abdomen.<sup>136-138</sup> Due to the myriad clinical presentations of thoracic disc herniations, the diagnosis is often delayed.<sup>139,140</sup> The difference between thoracic and lumbar regions is that in the thoracic levels interference of the spinal cord by degenerative finding can occur and cause ‘disturbances’ of the main ascending and descending tracts and symptoms can be poorly localized and vague.<sup>111</sup> The spinal cord is further exposed to such perturbations because, as a result of the kyphosis, the spinal cord lies directly on the posterior aspects of the vertebral bodies and discs and displacement of the cord is prevented by the dentate ligaments.<sup>141</sup>

Alternatively, central sensitization may have caused secondary hyperalgesia occurring at a site distant to the actual source of pain and, therefore, it cannot be ruled out that the cause of upper or mid-back pain may actually have been in the adjacent spinal regions. This could have been the case since most of the subjects reporting upper or mid-back pain also reported neck and low-back pain. This would have affected the analyses of associations between imaging findings and pain.

The limitations mentioned above may have resulted in failing to observe an association between MRI findings and pain when one is present. Therefore, for those variables with crude measurements of poor reliability where no association was observed, their role in upper or mid-back pain remains unclear. On the other hand, regardless of the challenges involved, several thoracic MRI findings were associated with severe pain. Due to the numerous factors that may have diluted the associations between MRI findings and pain, the actual associations between thoracic MRI findings and pain are even stronger than what was observed.

## METHODOLOGICAL CONSIDERATIONS

### *Study design*

This thesis involved a cross-sectional study that examined a study population at a given point in time and can be subject to recall bias when events in the past are of interest,<sup>142</sup> as in the case of pain history. It allowed examining the associations between variables, such as MRI findings and upper or mid-back pain, but not determining causality. Nor did the design allow investigating the temporal course of disc degeneration. Such a study design, however, does enable the acquisition of a large sample, which is especially important to offer normative data on thoracic MRI findings.

The study design limitations are important to keep in mind when interpreting the results of this thesis. For example, it was not possible to determine whether pain in different back regions occurred simultaneously or on separate occasions, or which of the different MRI findings that correlated with one another occurred first.

### *Validity issues*

The validity of a study is the extent to which the conclusions are believable and useful<sup>143</sup> and is determined by internal and external validity.<sup>144</sup>

The types of bias affecting internal validity are selection and measurement bias including observer and interviewer bias, and recall bias. Selection bias can be a potential threat for the generalizability of the results affecting the external validity of the study. The subjects for this thesis were selected without the knowledge of pain history and MRI findings to avoid *selection bias* which causes systematic differences between comparison groups.<sup>144,145</sup> Additionally, selection bias can be caused by recruitment bias, which has been considered problematic in twin studies based on volunteerism.<sup>146-148</sup> Recruitment and selection bias should be of small concern in this thesis because subjects were selected from a population-based cohort including all same-sex twins, participation rates were high, and extensive information available for comparisons between the study subjects and the base population from which they were drawn suggested that the sample is highly representative.

Furthermore, to avoid *observer bias* the manual tracings of the spinal structures were performed without the knowledge of the subject's pain or any other exposure data.

*Interviewer bias*, on the other hand, was addressed by offering the interviewers limited information on the study hypotheses or specific purposes of the study at the time of data collection. The type of bias perhaps of greatest concern in this thesis is *recall bias*. Subjects with more troublesome pain may have been more likely to remember their pain experience than subjects with mild pain affecting the allocation of subjects into outcome groups based on pain. This is suggested by Figure 4-1 (on page 83) where moderate to severe upper or mid-back pain was more common than mild pain, which is contrary to other general population studies where mild pain has been more common.<sup>149,150</sup> Also, the recall of pain may be selective, based on other factors, such as has been observed in patients with motor vehicle accidents.<sup>151</sup>

Lastly, the *reliability of the measurements* is important for internal validity, but also for external validity. This thesis appeared to be the first one to use quantitative measurements of thoracic MRI findings and the comparison to other studies is limited. Of the 21 studies presented in Table 2.1, which examined disc-related findings, Schmorl's nodes or vertebral osteophytes using CT, X-ray or MRI, only five reported any statistics related to the reliability of the assessments. However, due to the differences in imaging, assessment protocols and statistics used, it was not possible to directly compare the reliabilities between the studies. The reliability of the qualitative assessments in this thesis was the same as previously reported in the earlier report of the subgroup of subjects from this thesis.<sup>27</sup> However, it is recognized that the reliability of qualitative assessments in this thesis is problematic and may have affected the statistical conclusions drawn from the study and, thus, internal and external validity. Increased error variance may have resulted in type II error where no association is found when one, in fact, is present.<sup>145</sup> Due to the error in the assessments, the observed associations are likely underestimations of the 'true' associations.

Due to the extensive number of statistical tests performed in this thesis, some associations may have occurred by *chance*. However, all statistically-significant associations were in accordance with current knowledge (i.e. biologically plausible) of degenerative findings associated with age and one another, as well as plausibility in pain production. The prevalence of some thoracic MRI findings, such as posterior bulges, was relatively low. The low occurrence of posterior bulges resulted in low statistical power to de-



tect associations between bulges and pain history predisposing the study to type II error.<sup>145</sup> Based on the existing literature of the MRI findings and their associations with pain, small, if not negligible, effect sizes can be expected. If a correlation of 0.1 is assumed to exist in the population between posterior bulges and severe upper or mid-back pain, to achieve a power of 0.80 when  $\alpha=0.05$ , the sample size requirement would have been 617, with a correlation of 0.2 the sample size requirement would decrease to 153 subjects.<sup>152</sup> Thus, the association of posterior bulges to upper or mid-back pain remains inconclusive. The subject with a largest posterior bulge of 2.9 mm reported both interference in daily activities due to the pain and rated his pain as moderate, whereas six subjects with bulges of 1.7 mm did not report any pain.

On the other hand, a rule of thumb for an adequate sample size in the multivariable modelling for logistic regression is ten cases for each independent variable.<sup>153,154</sup> Each of the final models included only two MRI findings with the least number of cases of approximating 20 fulfilled and, therefore, overfitting should not be of concern. In general, a large and representative sample is advisable because it will approximate the characteristics of the general population better than smaller sample. Unfortunately, the acquisition of a larger sample was limited by the practical and cost-related issues.

Lastly, the generalizability of the results (i.e. external validity), as eluded to previously has been discussed in more in-depth in Chapter 3. The subjects of this thesis were found to be representative of the total population of Finnish men on many factors, but differences in factors that were not measured may have been present.

## CONCLUSIONS

- The research on thoracic spinal disorders reported here provides reference data for clinical observations and insights into possible conditions underlying upper or mid-back pain.
- The disc has remained as the main suspect for back pain. The basic biochemical phenomenon in disc degeneration, disc desiccation, was the earliest and most sensitive sign of age-related degeneration. This thesis introduced a valid and reliable measure of spinal cord-adjusted disc signal to measure disc desiccation, which is especially valuable in studies of etiology and pathogenesis of disc degeneration.

The gross structural alterations of thoracic disc degeneration were found to appear less frequently than in the lumbar region, especially those occurring posteriorly, with ‘severe’ findings only observed for disc height narrowing and endplate irregularities. The MRI findings of the thoracic region were found to vary by level, likely as a result of the regional differences in morphology. Also, due to the nature of disc degeneration as an age-related process where the function of one part of the disc depends on the integrity of the other part, several thoracic MRI findings were found to be associated with age and one another.

- Upper or mid-back pain reporting was rarely found to occur in isolation, suggesting a condition influencing widespread pain rather than an isolated condition of local pathology. In the majority of subjects upper or mid-back pain reports were associated with neck and low-back pain reports, or both. Despite the lower prevalence of upper or mid-back pain, when present the pain intensity and interference with normal activities were similar to neck pain, highlighting the importance of upper or mid-back pain to the individual.
- Thoracic MRI findings appeared to have a role in severe upper or mid-back pain since several thoracic MRI findings were associated with severe pain in crude analyses adjusting for age, while associations with frequency of pain were only observed for anterior bulging. Only posterior osteophytes were associated with severe pain in multivariable modelling adjusting for age. Due to several inaccuracies in the assessments of pain, MR imaging and origin of pain, the observed associations are likely under-estimations of the ‘true’ association. However, the presence of these MRI findings was also common in subjects without reported pain, which is consistent with the current knowledge in the lumbar region.

## **DIRECTIONS FOR FUTURE RESEARCH**

### *Methodological implications for related research*

Firstly, the *association between different MRI findings* should be considered when the association between MRI findings and pain is of interest. For example, among back surgery candidates, using lumbar discography disc degeneration was predictive of pain in

univariate analysis, but controlling for the presence of annular tears, disc degeneration was no longer a significant predictor of the pain.<sup>155</sup> Similarly, another study found that, of the six MRI variables significantly associated with at least one of the pain history parameters studied in crude analyses, only annular tears (contiguous with the outer margin of the disc) and disc height narrowing remained significant in the multivariable analysis.<sup>100</sup>

However, the association of different MRI findings should not always be used to indicate which variables can be combined to summary scores to investigate the determinants of disc degeneration. Different signs of disc degeneration may have different determinants and be of opposite nature, such as disc bulging and osteophytes, where bulging is thought of as an atrophic phenomenon and osteophyte formation a proliferative process.<sup>156</sup>

Secondly, *the choice of outcome* depends on the purpose of the study. Regardless of the less than ideal reliability of qualitative assessments, they often appeared superior to quantitative measurements when the association between pain and MRI findings was examined. The advantage of qualitative assessments in clinical studies could be that additional, clinically relevant information from the image is incorporated into the assessments. In the case of bulging, for example, the quantitative measures simply provide an absolute measure of distance or area. Furthermore, quantitative measurements could not be used to indicate disc height narrowing in relation to adjacent discs due to the large inter-individual variation.

On the other hand, the development of well-defined quantitative measures of disc degeneration could lead to substantial advances in related research. The gross ordinal discontinuous scales commonly used in qualitative assessments do not effectively demonstrate disc degeneration because differences in the discs can not be detected until a transition to the next level of the degeneration score is present.<sup>90</sup> Albeit, currently qualitative assessments may be better for some clinical studies, but when accurate and sensitive measures of specific phenomena are needed, such as in longitudinal studies because of the slow progression of disc degeneration,<sup>157</sup> and in 'gene-hunting' studies where small associations are of interest, quantitative measures would be preferable.

*Other implications for future research*

**Is there an association between MRI findings of the thoracic region and upper or mid-back pain?**

There are several considerations in going forward with studies to examine the association between MRI findings and pain in the thoracic region. First would be the inclusion of 'new' MRI findings that were not examined in this thesis, such as Modic changes, annular tears, and other structures characteristic of the thoracic region, such as osteophytes in the facet and rib joints (costovertebrae and –transverse joints) and the measurement of reserve capacity of the spinal canal. Modic changes and annular tears have been suggested of being associated with LBP.<sup>100,101,107-110</sup> Also, a sagittal lumbar spinal canal diameter appears smaller in symptomatic subjects than in asymptomatic ones.<sup>158-162</sup> Smaller canal size has also predicted chronic LBP better than merely disc degeneration,<sup>163</sup> but has not been a risk factor for LBP later in life.<sup>164</sup>

In the thoracic region, there is relatively little excess space in the spinal canal beyond that occupied by the spinal cord.<sup>165</sup> Furthermore, both the diameters of the spinal cord<sup>166-168</sup> and the spinal canal<sup>169,170</sup> present remarkable variations among cadavers. Therefore, measurements of reserve capacity of the spinal canal, accounting for the size of the spinal cord, may enhance currently weak correlations between degenerative findings and pain.<sup>158</sup> It can be expected that the smaller reserve capacity would be associated with upper or mid-back pain.

The associations between the above mentioned MRI findings of the thoracic region and pain could initially be examined in a cross-sectional study design with sagittal and axial MRI images. However, a *follow-up study* with baseline data of disc degeneration and pain would allow examining the associations between 'new' MRI findings and 'new' pain reports. The baseline data allows addressing the problem of cumulative effects of MRI by focusing on the findings occurring during the follow-up and examining their association with pain reports that occurred during the same time period.

Alternatively adolescents could be examined. Disc degeneration is a normal physiologic process associated with aging. It is believed to be determined by genetics and, to a lesser extent, by mechanical factors, such as physical loading.<sup>23,171</sup> With age, the

amount of physical loading also increases and more degeneration can be expected. The presence of 'advanced' disc degeneration may complicate the identification of imaging findings that may be responsible for current pain. Therefore, even though the first clear signs of degeneration of tear formation in the nucleus and endplate cracks are present in the lumbar discs as early as in adolescents (11-16 years),<sup>172</sup> it could be argued that perhaps clear degenerative finding at such an early age could represent a "pathological" finding. Hence, examining the association between MRI findings and pain in adolescents, where they can be assumed to be rarer, may be more informative than in adults. Additionally, the use of adolescents in a longitudinal study design allows examining the appearance of 'new' MRI findings and their association to pain and the predictive role of MRI findings for future pain.

#### **What factors affect the progression of disc degeneration?**

The development and progression of disc degeneration remains a poorly understood entity and, yet, it persists as the main suspect for back pain and a primary target for diagnostic and therapeutic interventions.<sup>26</sup> A longitudinal study design would allow examining the factors that affect the progression of disc degeneration to be identified and may provide insights into disc degeneration. Furthermore, if a longitudinal study with adolescents is used, it may permit investigating the factors that affect the onset of the disc degeneration. For example, does Scheuermann's disease, which begins at a young age, affect the development of disc degeneration? Longitudinal study designs are needed to better understand factors affecting disc degeneration and its progression, which may lead to more effective interventions. For longitudinal studies of disc degeneration it is vital to use sensitive and reliable outcome measures and the same imaging protocol, including the same scanner, if possible.

## REFERENCES

1. Linton SJ, Hellsing AL, Hallden K. A population-based study of spinal pain among 35-45-year-old individuals. Prevalence, sick leave, and health care use. *Spine*. 1998;23(13):1457-1463.
2. Linton SJ, Ryberg M. Do epidemiological results replicate? The prevalence and health-economic consequences of neck and back pain in the general population. *Eur J Pain*. 2000;4(4):347-354.
3. Natvig B, Nessiøy I, Bruusgaard D, Rutle O. Musculoskeletal symptoms in a local community. *Eur J Gen Practice*. 1995;1(1):25-28.
4. Bork BE, Cook TM, Rosecrance JC, et al. Work-related musculoskeletal disorders among physical therapists. *Phys Ther*. 1996;76(8):827-835.
5. Torp S, Riise T, Moen BE. Work-related musculoskeletal symptoms among car mechanics: A descriptive study. *Occup Med (Lond)*. 1996;46(6):407-413.
6. Zimmermann CL, Cook TM, Rosecrance JC. Operating engineers: Work-related musculoskeletal disorders and the trade. *Appl Occup Environ Hyg*. 1997;12(10):670-680.
7. Rosecrance JC, Cook TM, Zimmermann CL. Work-related musculoskeletal symptoms among construction workers in the pipe trades. *Work*. 1996;7:13-20.
8. Olafsdottir H, Rafnsson V. Musculoskeletal symptoms among women currently and formerly working in fish-filleting plants. *Int J Occup Environ Health*. 2000;6(1):44-49.
9. Picavet HS, Hazes JM. Prevalence of self reported musculoskeletal diseases is high. *Ann Rheum Dis*. 2003;62(7):644-650.
10. Allison TR, Symmons DP, Brammah T, et al. Musculoskeletal pain is more generalised among people from ethnic minorities than among white people in greater Manchester. *Ann Rheum Dis*. 2002;61(2):151-156.
11. Bergman S, Herrstrom P, Hogstrom K, Petersson IF, Svensson B, Jacobsson LT. Chronic musculoskeletal pain, prevalence rates, and sociodemographic associations in a Swedish population study. *J Rheumatol*. 2001;28(6):1369-1377.
12. Van der Linden SM, Fahrner H. Occurrence of spinal pain syndromes in a group of apparently healthy and physically fit sportsmen (orienteers). *Scand J Rheumatol*. 1988;17(6):475-481.
13. Niedhammer I, Lert F, Marne MJ. Back pain and associated factors in French nurses. *Int Arch Occup Environ Health*. 1994;66(5):349-357.
14. Brattberg G, Thorslund M, Wikman A. The prevalence of pain in a general population. The results of a postal survey in a county of Sweden. *Pain*. 1989;37(2):215-222.
15. Salo D, Eget D, Lavery RF, Garner L, Bernstein S, Tandon K. Can patients accurately read a visual analog pain scale? *Am J Emerg Med*. 2003;21(7):515-519.
16. Price DD, McGrath PA, Rafii A, Buckingham B. The validation of visual analogue scales as ratio scale measures for chronic and experimental pain. *Pain*. 1983;17(1):45-56.
17. Nakamura Y, Chapman CR. Measuring pain: An introspective look at introspection. *Conscious Cogn*. 2002;11(4):582-592.

18. Kuorinka I, Jonsson B, Kilbom A, et al. Standardised Nordic questionnaires for the analysis of musculoskeletal symptoms. *Appl Ergon*. 1987;18(3):233-237.
19. Bijur PE, Silver W, Gallagher EJ. Reliability of the visual analog scale for measurement of acute pain. *Acad Emerg Med*. 2001;8(12):1153-1157.
20. Charlton JE, ed. *Core Curriculum for Professional Education in Pain*. 3rd ed. Seattle, WA: IASP Press; 2005.
21. Dionne CE, Dunn KM, Croft PR, et al. A consensus approach toward the standardization of back pain definitions for use in prevalence studies. *Spine*. 2008;33(1):95-103.
22. Kaprio J, Koskenvuo M, Artimo M, Sarna S, Rantasalo I. *The Finnish Twin Registry: Baseline Characteristics. Section I: Materials, Methods, Representativeness and Results for Variables Special to Twin Studies*. Helsinki, Finland: Kansanterveystieteen julkaisu M47; 1979.
23. Battie MC, Videman T, Gibbons LE, Fisher LD, Manninen H, Gill K. Determinants of lumbar disc degeneration. A study relating lifetime exposures and magnetic resonance imaging findings in identical twins. *Spine*. 1995;20(24):2601-2612.
24. Simonen RL, Videman T, Kaprio J, Levalahti E, Battie MC. Factors associated with exercise lifestyle--a study of monozygotic twins. *Int J Sports Med*. 2003;24(7):499-505.
25. Leboeuf-Yde C, Lauritsen JM. The prevalence of low back pain in the literature. A structured review of 26 Nordic studies from 1954 to 1993. *Spine*. 1995;20(19):2112-2118.
26. Battie MC, Videman T, Parent E. Lumbar disc degeneration: Epidemiology and genetic influences. *Spine*. 2004;29(23):2679-2690.
27. Videman T, Battie MC, Gill K, Manninen H, Gibbons LE, Fisher LD. Magnetic resonance imaging findings and their relationships in the thoracic and lumbar spine. Insights into the etiopathogenesis of spinal degeneration. *Spine*. 1995;20(8):928-935.
28. Gray H. *Anatomy, Descriptive and Surgical*. 1st ed. London, U.K.: John W. Carter and Son; 1858.
29. Silberstein M, Opeskin K, Fahey V. Spinal Schmorl's nodes: Sagittal sectional imaging and pathological examination. *Australas Radiol*. 1999;43(1):27-30.
30. Hilton RC, Ball J, Benn RT. Vertebral end-plate lesions (Schmorl's nodes) in the dorsolumbar spine. *Ann Rheum Dis*. 1976;35(2):127-132.
31. Pfirrmann CW, Resnick D. Schmorl nodes of the thoracic and lumbar spine: Radiographic-pathologic study of prevalence, characterization, and correlation with degenerative changes of 1,650 spinal levels in 100 cadavers. *Radiology*. 2001;219(2):368-374.
32. Baranto A, Hellstrom M, Nyman R, Lundin O, Sward L. Back pain and degenerative abnormalities in the spine of young elite divers: A 5-year follow-up magnetic resonance imaging study. *Knee Surg Sports Traumatol Arthrosc*. 2006;14(9):907-914.
33. Coventry MB, Ghormley RK, Kernohan JW. The intervertebral disc: Its microscopic anatomy and pathology. Part II: Changes in the intervertebral disc concomitant with age. *J Bone Joint Surg*. 1945;27(2):233-247.

34. Coventry MB, Ghormley RK, Kernohan JW. The intervertebral disc: Its microscopic anatomy and pathology. Part I: Anatomy, development and physiology. *J Bone Joint Surg.* 1945;27(2):105-112.
35. Schmorl G, Junghanns H. *The Human Spine in Health and Disease.* 2nd American edition ed. New York: Grune & Stratton; 1971.
36. Harris RI, Macnab I. Structural changes in the lumbar intervertebral discs; their relationship to low back pain and sciatica. *J Bone Joint Surg Br.* 1954;36-B(2):304-322.
37. Fahey V, Opeskin K, Silberstein M, Anderson R, Briggs C. The pathogenesis of Schmorl's nodes in relation to acute trauma. an autopsy study. *Spine.* 1998;23(21):2272-2275.
38. Rachbauer F, Sterzinger W, Eibl G. Radiographic abnormalities in the thoracolumbar spine of young elite skiers. *Am J Sports Med.* 2001;29(4):446-449.
39. Nicoll EA. Fractures of the dorso-lumbar spine. *J Bone Joint Surg Am.* 1949;31-A(3):376-394.
40. Sward L, Hellstrom M, Jacobsson B, Nyman R, Peterson L. Disc degeneration and associated abnormalities of the spine in elite gymnasts. A magnetic resonance imaging study. *Spine.* 1991;16(4):437-443.
41. Nathan H. Osteophytes of the vertebral column. An anatomical study of their development according to age, race, and sex with consideration as to their etiology and significance. *J Bone Joint Surg Am.* 1962;44-A:243-268.
42. Kahle W, Leonhardt H, Platzer W. *Color Atlas/Text of Human Anatomy, Volume 1. Locomotor System.* 4th revised ed. Stuttgart, Germany: Georg Thieme Verlag; 1992.
43. Shore LR. On osteo-arthritis in the dorsal intervertebral joints. A study in morbid anatomy. *Br J Surg.* 1935;22(88):833-849.
44. Singer KP, Jones TJ, Breidahl PD. A comparison of radiographic and computer-assisted measurements of thoracic and thoracolumbar sagittal curvature. *Skeletal Radiol.* 1990;19(1):21-26.
45. Pal GP, Routal RV. Mechanism of change in the orientation of the articular process of the zygapophyseal joint at the thoracolumbar junction. *J Anat.* 1999;195 (2):199-209.
46. Putz RV, Muller-Gerbl M. Ligaments of the human vertebral column. In: Giles LGF, Singer KP, eds. *Clinical Anatomy and Management of Thoracic Spine Pain.* 1st ed. Oxford, UK: Butterworth-Heinemann; 2000:34-44.
47. Malmivaara A. *Thoracolumbar Junctional Region of the Spine. An Anatomical and Radiological Study.* [PhD]. Medical Faculty of the University of Helsinki; 1987.
48. Tan CIC, Song S, Edmondston SJ, Singer KP. Patterns of thoracic disc degeneration from MRI: Age, gender and spinal level influences. *JMR.* 2001;5(4):269-278.
49. White AA, Panjabi MM. *Clinical Biomechanics of the Spine.* 2nd ed. Philadelphia: Lippincott; 1990:722.
50. Andriacchi T, Schultz A, Belytschko T, Galante J. A model for studies of mechanical interactions between the human spine and rib cage. *J Biomech.* 1974;7(6):497-507.
51. Takeuchi T, Abumi K, Shono Y, Oda I, Kaneda K. Biomechanical role of the intervertebral disc and costovertebral joint in stability of the thoracic spine. A canine model study. *Spine.* 1999;24(14):1414-1420.



52. Hickey DS, Hukins DW. Relation between the structure of the annulus fibrosus and the function and failure of the intervertebral disc. *Spine*. 1980;5(2):106-116.
53. Dameron TE, Jr, Gullledge WH. Adolescent kyphosis. *U S Armed Forces Med J*. 1953;4(6):871-875.
54. Biering-Sorensen F, Hansen FR, Schroll M, Runeborg O. The relation of spinal x-ray to low-back pain and physical activity among 60-year-old men and women. *Spine*. 1985;10(5):445-451.
55. Scoles PV, Latimer BM, Digiovanni BF, Vargo E, Bauza S, Jellema LM. Vertebral alterations in Scheuermann's kyphosis. *Spine*. 1991;16(5):509-515.
56. O'Neill TW, Felsenberg D, Varlow J, Cooper C, Kanis JA, Silman AJ. The prevalence of vertebral deformity in European men and women: The European Vertebral Osteoporosis Study. *J Bone Miner Res*. 1996;11(7):1010-1018.
57. Mann T, Oviatt SK, Wilson D, Nelson D, Orwoll ES. Vertebral deformity in men. *J Bone Miner Res*. 1992;7(11):1259-1265.
58. Genant HK, Wu CY, van Kuijk C, Nevitt MC. Vertebral fracture assessment using a semiquantitative technique. *J Bone Miner Res*. 1993;8(9):1137-1148.
59. Majumdar SR, Kim N, Colman I, et al. Incidental vertebral fractures discovered with chest radiography in the emergency department: Prevalence, recognition, and osteoporosis management in a cohort of elderly patients. *Arch Intern Med*. 2005;165(8):905-909.
60. Woo EK, Mansoubi H, Alyas F. Incidental vertebral fractures on multidetector CT images of the chest: Prevalence and recognition. *Clin Radiol*. 2008;63(2):160-164.
61. Gehlbach SH, Bigelow C, Heimisdottir M, May S, Walker M, Kirkwood JR. Recognition of vertebral fracture in a clinical setting. *Osteoporos Int*. 2000;11(7):577-582.
62. Kaptoge S, Armbrecht G, Felsenberg D, et al. Whom to treat? The contribution of vertebral X-rays to risk-based algorithms for fracture prediction. Results from the European Prospective Osteoporosis Study. *Osteoporos Int*. 2006;17(9):1369-1381.
63. Lecuyer N, Grados F, Dargent-Molina P, Deramond H, Meunier PJ, Fardellone P. Prevalence of Paget's disease of bone and spinal hemangioma in French women older than 75 years: Data from the EPIDOS study. *Joint Bone Spine*. 2000;67(4):315-318.
64. Garfin SR, Vaccaro AR, eds. *Orthopaedic Knowledge Update: Spine*. 1st ed. Rosemont, IL: American Academy of Orthopaedic Surgeons; 1997.
65. Templin CR, Stambough JB, Stambough JL. Acute spinal cord compression caused by vertebral hemangioma. *Spine J*. 2004;4(5):595-600.
66. Cross JJ, Antoun NM, Laing RJ, Xuereb J. Imaging of compressive vertebral haemangiomas. *Eur Radiol*. 2000;10(6):997-1002.
67. Guglielmi G, Andreula C, Muto M, Gilula LA. Percutaneous vertebroplasty: Indications, contraindications, technique, and complications. *Acta Radiol*. 2005;46(3):256-268.
68. Kirkaldy-Willis WH, Farfan HF. Instability of the lumbar spine. *Clin Orthop Relat Res*. 1982;(165):110-123.
69. An HS, Anderson PA, Hughton VM, et al. Introduction: Disc degeneration: Summary. *Spine*. 2004;29(23):2677-2678.

70. Frobin W, Brinckmann P, Kramer M, Hartwig E. Height of lumbar discs measured from radiographs compared with degeneration and height classified from MR images. *Eur Radiol.* 2001;11(2):263-269.
71. Filippi M, van Waesberghe JH, Horsfield MA, et al. Interscanner variation in brain MRI lesion load measurements in MS: Implications for clinical trials. *Neurology.* 1997;49(2):371-377.
72. Cihangiroglu M, Yildirim H, Bozgeyik Z, et al. Observer variability based on the strength of MR scanners in the assessment of lumbar degenerative disc disease. *Eur J Radiol.* 2004;51(3):202-208.
73. Gawne-Cain ML, Webb S, Tofts P, Miller DH. Lesion volume measurement in multiple sclerosis: How important is accurate repositioning? *J Magn Reson Imaging.* 1996;6(5):705-713.
74. Rovaris M, Gawne-Cain ML, Sormani MP, Miller DH, Filippi M. The effect of repositioning on brain MRI lesion load assessment in multiple sclerosis: Reliability of subjective quality criteria. *J Neurol.* 1998;245(5):273-275.
75. Lyons G, Eisenstein SM, Sweet MB. Biochemical changes in intervertebral disc degeneration. *Biochim Biophys Acta.* 1981;673(4):443-453.
76. Antoniou J, Steffen T, Nelson F, et al. The human lumbar intervertebral disc: Evidence for changes in the biosynthesis and denaturation of the extracellular matrix with growth, maturation, ageing, and degeneration. *J Clin Invest.* 1996;98(4):996-1003.
77. Urban JP, Roberts S. Degeneration of the intervertebral disc. *Arthritis Res Ther.* 2003;5(3):120-130.
78. Urban JP, Winlove CP. Pathophysiology of the intervertebral disc and the challenges for MRI. *J Magn Reson Imaging.* 2007;25(2):419-432.
79. Gundry CR, Fritts HM. Magnetic resonance imaging of the musculoskeletal system. Part 8. The spine, section 1. *Clin Orthop.* 1997;(338):275-287.
80. Herzog RJ. The role of magnetic resonance imaging in the assessment of disk degeneration and diskogenic pain. In: Weinstein JN, Gordon SL, eds. *Low Back Pain. A Scientific and Clinical Overview.* 1st ed. Rosemont, Illinois: American Academy of Orthopaedic Surgeons; 1996:385-405.
81. Haughton V. Medical imaging of intervertebral disc degeneration: Current status of imaging. *Spine.* 2004;29(23):2751-2756.
82. Aprill C, Bogduk N. High-intensity zone: A diagnostic sign of painful lumbar disc on magnetic resonance imaging. *Br J Radiol.* 1992;65(773):361-369.
83. Carragee EJ, Paragioudakis SJ, Khurana S. Lumbar high-intensity zone and discography in subjects without low back problems. *Spine.* 2000;25(23):2987-2992.
84. Lam KS, Carlin D, Mulholland RC. Lumbar disc high-intensity zone: The value and significance of provocative discography in the determination of the discogenic pain source. *Eur Spine J.* 2000;9(1):36-41.
85. Peng B, Hou S, Wu W, Zhang C, Yang Y. The pathogenesis and clinical significance of a high-intensity zone (HIZ) of lumbar intervertebral disc on MR imaging in the patient with discogenic low back pain. *Eur Spine J.* 2006;15(5):583-587.

86. Schellhas KP, Pollei SR, Gundry CR, Heithoff KB. Lumbar disc high-intensity zone. Correlation of magnetic resonance imaging and discography. *Spine*. 1996;21(1):79-86.
87. Rankine JJ, Gill KP, Hutchinson CE, Ross ER, Williamson JB. The clinical significance of the high-intensity zone on lumbar spine magnetic resonance imaging. *Spine*. 1999;24(18):1913-1919.
88. McRobbie DW, Moore EA, Graves MJ, Prince MR. *MRI from Picture to Proton*. 1st ed. Cambridge, United Kingdom: Cambridge University Press; 2003.
89. Modic MT, Steinberg PM, Ross JS, Masaryk TJ, Carter JR. Degenerative disk disease: Assessment of changes in vertebral body marrow with MR imaging. *Radiology*. 1988;166(1):193-199.
90. Haughton V. Imaging intervertebral disc degeneration. *J Bone Joint Surg Am*. 2006;88-A(Suppl 2):15-20.
91. Luoma K, Riihimaki H, Raininko R, Luukkonen R, Lamminen A, Viikari-Juntura E. Lumbar disc degeneration in relation to occupation. *Scand J Work Environ Health*. 1998;24(5):358-366.
92. Pye SR, Reid DM, Smith R, et al. Radiographic features of lumbar disc degeneration and self-reported back pain. *J Rheumatol*. 2004;31(4):753-758.
93. Torgerson WR, Dotter WE. Comparative roentgenographic study of the asymptomatic and symptomatic lumbar spine. *J Bone Joint Surg Am*. 1976;58-A(6):850-853.
94. Pedersen HE, Blunck CF, Gardner E. The anatomy of lumbosacral posterior rami and meningeal branches of spinal nerve (sinu-vertebral nerves); with an experimental study of their functions. *J Bone Joint Surg Am*. 1956;38-A(2):377-391.
95. Jackson HC, 2nd, Winkelmann RK, Bickel WH. Nerve endings in the human lumbar spinal column and related structures. *J Bone Joint Surg Am*. 1966;48-A(7):1272-1281.
96. Mendel T, Wink CS, Zimny ML. Neural elements in human cervical intervertebral discs. *Spine*. 1992;17(2):132-135.
97. Bogduk N. *Clinical Anatomy of the Lumbar Spine and Sacrum*. 4th ed. New York, NY: Elsevier/Churchill Livingstone; 2005.
98. Yoshizawa H, O'Brien JP, Smith WT, Trumper M. The neuropathology of intervertebral discs removed for low-back pain. *J Pathol*. 1980;132(2):95-104.
99. Groen GJ, Baljet B, Drukker J. Nerves and nerve plexuses of the human vertebral column. *Am J Anat*. 1990;188(3):282-296.
100. Videman T, Battie MC, Gibbons LE, Maravilla K, Manninen H, Kaprio J. Associations between back pain history and lumbar MRI findings. *Spine*. 2003;28(6):582-588.
101. Kjaer P, Leboeuf-Yde C, Korsholm L, Sorensen JS, Bendix T. Magnetic resonance imaging and low back pain in adults: A diagnostic imaging study of 40-year-old men and women. *Spine*. 2005;30(10):1173-1180.
102. Borenstein DG, O'Mara JW, Jr, Boden SD, et al. The value of magnetic resonance imaging of the lumbar spine to predict low-back pain in asymptomatic subjects: A seven-year follow-up study. *J Bone Joint Surg Am*. 2001;83-A(9):1306-1311.

103. Nachemson A. Backache--the bane of the welfare state? *Nord Med.* 1994;109(3):70-71.
104. Gardner JA. Benefit increases and system utilization: The Connecticut experience. . 1991;WC-91-5.
105. Mitra SR, Gurjar SG, Mitra KR. Degenerative disease of the thoracic spine in central India. *Spinal Cord.* 1996;34(6):333-337.
106. Arroyo JF, Jolliet P, Junod AF. Costovertebral joint dysfunction: Another misdiagnosed cause of atypical chest pain. *Postgrad Med J.* 1992;68(802):655-659.
107. Videman T, Nurminen M, Troup JD. Lumbar spinal pathology in cadaveric material in relation to history of back pain, occupation, and physical loading. *Spine.* 1990;15(8):728-740.
108. Videman T, Nurminen M. The occurrence of annular tears and their relation to lifetime back pain history: A cadaveric study using barium sulfate discography. *Spine.* 2004;29(23):2668-2676.
109. Kuisma M, Karppinen J, Niinimäki J, et al. Modic changes in endplates of lumbar vertebral bodies: Prevalence and association with low back and sciatic pain among middle-aged male workers. *Spine.* 2007;32(10):1116-1122.
110. Albert HB, Kjaer P, Jensen TS, Sorensen JS, Bendix T, Manniche C. Modic changes, possible causes and relation to low back pain. *Med Hypotheses.* 2008;70(2):361-368.
111. Groen GJ, Stolker RJ. Thoracic neural anatomy. In: Giles LGF, Singer KP, eds. *Clinical Anatomy and Management of Thoracic Spine Pain.* 1st ed. Oxford, UK: Butterworth-Heinemann; 2000:114-141.
112. Groen GJ, Baljet B, Drukker J. The innervation of the spinal dura mater: Anatomy and clinical implications. *Acta Neurochir (Wien).* 1988;92(1-4):39-46.
113. Groen GJ, Baljet B, Boekelaar AB, Drukker J. Branches of the thoracic sympathetic trunk in the human fetus. *Anat Embryol (Berl).* 1987;176(4):401-411.
114. Edgar MA. The nerve supply of the lumbar intervertebral disc. *J Bone Joint Surg Br.* 2007;89-B(9):1135-1139.
115. Tanaka Y, Kokubun S, Sato T, Ozawa H. Cervical roots as origin of pain in the neck or scapular regions. *Spine.* 2006;31(17):E568-73.
116. Dwyer A, Aprill C, Bogduk N. Cervical zygapophyseal joint pain patterns. I: A study in normal volunteers. *Spine.* 1990;15(6):453-457.
117. Aprill C, Dwyer A, Bogduk N. Cervical zygapophyseal joint pain patterns. II: A clinical evaluation. *Spine.* 1990;15(6):458-461.
118. Fukui S, Ohseto K, Shiotani M, et al. Referred pain distribution of the cervical zygapophyseal joints and cervical dorsal rami. *Pain.* 1996;68(1):79-83.
119. Wilke A, Wolf U, Lageard P, Griss P. Thoracic disc herniation: A diagnostic challenge. *Man Ther.* 2000;5(3):181-184.
120. Tovi D, Strang RR. Thoracic intervertebral disk protrusions. *Acta Chir Scand.* 1960;(Suppl 267):1-41.
121. Morgan H, Abood C. Disc herniation at T1-2. Report of four cases and literature review. *J Neurosurg.* 1998;88(1):148-150.

122. Lyu RK, Chang HS, Tang LM, Chen ST. Thoracic disc herniation mimicking acute lumbar disc disease. *Spine*. 1999;24(4):416-418.
123. Ross JS, Perez-Reyes N, Masaryk TJ, Bohlman H, Modic MT. Thoracic disk herniation: MR imaging. *Radiology*. 1987;165(2):511-515.
124. van Ameyden van Duym, F.C., van Wiechen PJ. Herniation of calcified nucleus pulposus in the thoracic spine. *J Comput Assist Tomogr*. 1983;7(6):1122-1123.
125. Parizel PM, Rodesch G, Baleriaux D, et al. Gd-DTPA-enhanced MR in thoracic disc herniations. *Neuroradiology*. 1989;31(1):75-79.
126. Blumenkopf B. Thoracic intervertebral disc herniations: Diagnostic value of magnetic resonance imaging. *Neurosurgery*. 1988;23(1):36-40.
127. Arce CA, Dohrmann GJ. Thoracic disc herniation. Improved diagnosis with computed tomographic scanning and a review of the literature. *Surg Neurol*. 1985;23(4):356-361.
128. Francavilla TL, Powers A, Dina T, Rizzoli HV. MR imaging of thoracic disk herniations. *J Comput Assist Tomogr*. 1987;11(6):1062-1065.
129. Balague F, Fankhauser H, Rosazza A, Waldburger M. Unusual presentation of thoracic disc herniation. *Clin Rheumatol*. 1989;8(2):269-273.
130. Almond LM, Hamid NA, Wasserberg J. Thoracic intradural disc herniation. *Br J Neurosurg*. 2007;21(1):32-34.
131. Sasaki S, Kaji K, Shiba K. Upper thoracic disc herniation followed by acutely progressing paraplegia. *Spinal Cord*. 2005;43(12):741-745.
132. Tokuhashi Y, Matsuzaki H, Uematsu Y, Oda H. Symptoms of thoracolumbar junction disc herniation. *Spine*. 2001;26(22):E512-8.
133. Boriani S, Biagini R, De Iure F, et al. Two-level thoracic disc herniation. *Spine*. 1994;19(21):2461-2466.
134. Ozturk C, Tezer M, Sirvanci M, Sarier M, Aydogan M, Hamzaoglu A. Far lateral thoracic disc herniation presenting with flank pain. *Spine J*. 2006;6(2):201-203.
135. Freccero D, Donovan DJ. Adjacent segment degeneration at T1-T2 presenting as chest pain: Case report. *Spine*. 2005;30(21):E655-7.
136. Xiong Y, Lachmann E, Marini S, Nagler W. Thoracic disk herniation presenting as abdominal and pelvic pain: A case report. *Arch Phys Med Rehabil*. 2001;82(8):1142-1144.
137. Rohde RS, Kang JD. Thoracic disc herniation presenting with chronic nausea and abdominal pain. A case report. *J Bone Joint Surg Am*. 2004;86-A(2):379-381.
138. Whitcomb DC, Martin SP, Schoen RE, Jho HD. Chronic abdominal pain caused by thoracic disc herniation. *Am J Gastroenterol*. 1995;90(5):835-837.
139. Rosenbloom SA. Thoracic disc disease and stenosis. *Radiol Clin North Am*. 1991;29(4):765-775.
140. Russell T. Thoracic intervertebral disc protrusion: Experience of 67 cases and review of the literature. *Br J Neurosurg*. 1989;3(2):153-160.
141. Vanichkachorn JS, Vaccaro AR. Thoracic disk disease: Diagnosis and treatment. *J Am Acad Orthop Surg*. 2000;8(3):159-169.

142. Hadler NM. *Occupational Musculoskeletal Disorders*. 3rd ed. Philadelphia, PA, United States of America: Lippincott Williams & Wilkins; 2005.
143. Domholdt E. *Rehabilitation Research: Principles and Applications*. 3rd ed. St. Louis, MO: Elsevier and Saunders; 2005.
144. Portney LG, Watkins MP. *Foundations of Clinical Research. Applications to Practice*. 2nd ed. Upper Saddle River, NJ: Prentice-Hall; 2000.
145. Oleckno WA. *Essential Epidemiology. Principles and Applications*. Illinois, United States of America: Waveland Press Inc.; 2002.
146. Lykken DT, McGue M, Tellegen A. Recruitment bias in twin research: The rule of two-thirds reconsidered. *Behav Genet*. 1987;17(4):343-362.
147. Simmons SF, Johansson B, Zarit SH, Ljungquist B, Plomin R, McClearn GE. Selection bias in samples of older twins? A comparison between octogenarian twins and singletons in sweden. *J Aging Health*. 1997;9(4):553-567.
148. Kyvik KO. Generalizability and assumptions of twin studies. In: Spector TD, Snieder, H.: MacGregor, A.J., eds. *Advances in Twin and Sib-Pair Analysis*. 1st ed. London, UK: Greenwich Medical Media Ltd.; 2000:67-77.
149. Ihlebaek C, Eriksen HR, Ursin H. Prevalence of subjective health complaints (SHC) in norway. *Scand J Public Health*. 2002;30(1):20-29.
150. Eriksen HR, Ihlebaek C, Ursin H. A scoring system for subjective health complaints (SHC). *Scand J Public Health*. 1999;27(1):63-72.
151. Carragee EJ. Validity of self-reported history in patients with acute back or neck pain after motor vehicle accidents. *Spine J*. 2008;8(2):311-319.
152. Cohen J. *Statistical Power Analysis for the Behavioral Sciences*. 2nd ed. Hillsdale, NJ: Lawrence Erlbaum Associates, Inc.; 1988.
153. Katz MH. *Multivariable Analysis: A Practical Guide for Clinicians*. 2nd ed. Cambridge, UK: Cambridge University Press; 2006.
154. Hosmer DW, Lemeshow S. *Applied Logistic Regression*. 2nd ed. New York, NY, United States of America: John Wiley & Sons; 2000.
155. Moneta GB, Videman T, Kaivanto K, et al. Reported pain during lumbar discography as a function of annular ruptures and disc degeneration. A re-analysis of 833 discograms. *Spine*. 1994;19(17):1968-1974.
156. Videman T, Gibbons LE, Battie MC, et al. The relative roles of intragenic polymorphisms of the vitamin d receptor gene in lumbar spine degeneration and bone density. *Spine*. 2001;26(3):E7-E12.
157. Videman T, Battie MC, Ripatti S, Gill K, Manninen H, Kaprio J. Determinants of the progression in lumbar degeneration: A 5-year follow-up study of adult male monozygotic twins. *Spine*. 2006;31(6):671-678.
158. Dora C, Walchli B, Elfering A, Gal I, Weishaupt D, Boos N. The significance of spinal canal dimensions in discriminating symptomatic from asymptomatic disc herniations. *Eur Spine J*. 2002;11(6):575-581.
159. Kornberg M, Rehtine GR. Quantitative assessment of the fifth lumbar spinal canal by computed tomography in symptomatic L4-L5 disc disease. *Spine*. 1985;10(4):328-330.

160. Porter RW, Hibbert CS, Wicks M. The spinal canal in symptomatic lumbar disc lesions. *J Bone Joint Surg Br.* 1978;60-B(4):485-487.
161. Drinkall JN, Porter RW, Hibbert CS, Evans C. Value of ultrasonic measurement of spinal canal diameter in general practice. *Br Med J (Clin Res Ed).* 1984;288(6411):121-122.
162. Pneumaticos SG, Hipp JA, Esses SI. Sensitivity and specificity of dural sac and herniated disc dimensions in patients with low back-related leg pain. *J Magn Reson Imaging.* 2000;12(3):439-443.
163. Visuri T, Ulaska J, Eskelin M, Pulkkinen P. Narrowing of lumbar spinal canal predicts chronic low back pain more accurately than intervertebral disc degeneration: A magnetic resonance imaging study in young Finnish male conscripts. *Mil Med.* 2005;170(11):926-930.
164. Porter RW, Bewley B. A ten-year prospective study of vertebral canal size as a predictor of back pain. *Spine.* 1994;19(2):173-175.
165. Maurice-Williams RS. *Spinal Degenerative Disease.* Bristol, United Kingdom: John Wright & Sons Ltd.; 1981.
166. Ko HY, Park JH, Shin YB, Baek SY. Gross quantitative measurements of spinal cord segments in human. *Spinal Cord.* 2004;42(1):35-40.
167. Kameyama T, Hashizume Y, Sobue G. Morphologic features of the normal human cadaveric spinal cord. *Spine.* 1996;21(11):1285-1290.
168. Chandler Elliott H. Cross-sectional diameters and the areas of the human spinal cord. *Anat Rec.* 1945;93:287-293.
169. Tan SH, Teo EC, Chua HC. Quantitative three-dimensional anatomy of cervical, thoracic and lumbar vertebrae of Chinese Singaporeans. *Eur Spine J.* 2004;13(2):137-146.
170. Panjabi MM, Takata K, Goel V, et al. Thoracic human vertebrae. Quantitative three-dimensional anatomy. *Spine.* 1991;16(8):888-901.
171. Sambrook PN, MacGregor AJ, Spector TD. Genetic influences on cervical and lumbar disc degeneration: A magnetic resonance imaging study in twins. *Arthritis Rheum.* 1999;42(2):366-372.
172. Boos N, Weissbach S, Rohrbach H, Weiler C, Spratt KF, Nerlich AG. Classification of age-related changes in lumbar intervertebral discs. *Spine.* 2002;27(23):2631-2644.

## **APPENDIX A: MRI FINDINGS AND THEIR DEFINITIONS ACCORDING TO THE NOMENCLATURE AND CLASSIFICATION OF DISC PATHOLOGY**

The following definitions have been recommended by the Combined Task Forces of the North American Spine Society, American Society of Spine Radiology, and American Society of Neuroradiology.<sup>1</sup>

### **NORMAL**

Normal discs are defined as young discs that are morphologically normal, without consideration of the clinical context and not inclusive of degenerative, developmental, or adaptive findings.

### **DEGENERATIVE / TRAUMATIC**

The following MRI findings are included under degenerative / traumatic without implying trauma as a necessary factor or that degenerative findings are necessarily pathologic, as opposed to the normal aging process.

#### Disc herniation

Herniation is a localized (less than 50% of the periphery of the disc) displacement of disc material beyond the limits of the intervertebral disc space. Herniation can further be divided into protrusion and extrusion based on the shape of the displaced material. Extrusion can be called sequestration if the displaced disc material has lost completely any continuity with the parent disc.

#### Disc bulging

Disc bulging is not considered to be a form of herniation. Bulging is defined as being present when disc tissue is circumferentially (50-100%) beyond the edges of the ring apophyses, while herniation is a localized displacement of disc material beyond the edges of intervertebral disc space.

#### Disc height

Disc height is defined as the distance between the endplates of the vertebrae craniad and caudad to the disc. No further definition of disc height narrowing is provided.



### Annular tear

Annular tears, which can also be called fissures, are separations between annular fibres, avulsion of fibres from their vertebral body insertions or breaks through fibres that extend radially, concentrically or transversely.

### Disc degeneration

Disc degeneration is defined as disc-related changes including several structural alterations such as, desiccation, fibrosis and cleft formation in the nucleus, fissuring and mucinous degeneration of the annulus, defects and sclerosis of endplates, and/or osteophytes at the vertebral apophyses.

### Schmorl's nodes i.e. intravertebral herniations

A displacement of a portion of the disc through the endplate into the vertebral body.

### Osteophytes

An osteophyte is a focal hypertrophy of bone surface and / or ossification of soft tissue attachment to the bone.

1. Fardon DF, Milette PC, Combined Task Forces of the North American Spine Society, American Society of Spine Radiology, and American Society of Neuroradiology. Nomenclature and classification of lumbar disc pathology. Recommendations of the Combined Task Forces of the North American Spine Society, American Society of Spine Radiology, and American Society of Neuroradiology. *Spine*. 2001;26:E93-E113.

## APPENDIX B: EMBRYOLOGY AND DEVELOPMENT OF THE SPINE

Most of the vertebral column (vertebrae, endplates and annulus fibrosus) develops from mesoderm, but the nucleus pulposus, which is a remnant of notochord, is derived from the endoderm.<sup>1</sup> Although, according to a competitive theory, the notochord rescinds and the nucleus pulposus forms from the inner aspect of annulus fibrosus,<sup>2,3</sup> in the following description of embryology, the nucleus pulposus is considered to be formed from the notochord, which appears to be the commonly accepted view.

*The development of the vertebral column* starts around the 4<sup>th</sup> week of development when the paraxial mesoderm becomes divided into 42 to 44 blocks called somites. Somites appear first in the region of the head and emerge caudally from there on.<sup>4</sup> Intervening intersegmental vessel separates each somite, which further becomes differentiated into a ventromedial part (the sclerotome) and a dorsolateral part (the dermomyotome).<sup>5</sup> Each vertebral body is a intersegmental in origin because the caudal portion of each sclerotome segment binds with the cranial half of the adjacent sclerotome incorporating the intersegmental vessels into the precartilaginous vertebral body.<sup>5-8</sup> This mesenchymal vertebra gives rise to the dorsal and lateral outgrowths on each side. The dorsal outgrowths grow around the neural tube to form the neural arch, and the lateral outgrowths form the mesenchymal costal processes.<sup>5</sup> All vertebrae have costal elements, but only in the thoracic region they develop into ribs. In the cervical and lumbar region they contribute to the formation of transverse processes (in the lumbar region 'true' transverse processes develop into accessory processes).<sup>9,10</sup> The sternum, on the other hand, forms from the somatic mesoderm, which is a part of a lateral plate of the embryonic mesoderm. The ventral part of the somatic mesoderm forms two sternal bars which meet in the midline in the shape of an inverted V and unite from above downward.<sup>1</sup>

*Chondrification* centres appear in the centrum and neural arches late in the 5<sup>th</sup> week and at about the sixth week of development some mesenchymal cells become cartilaginous. The cartilaginous phase of vertebral development leads to the formation of a cartilaginous model of the future vertebra. The cartilaginous costal process at the thoracic levels will become detached from the parent neural arches by forming synovial joints

which will also form between the transverse processes. The ventral ends of six of the seven thoracic costal processes form small synovial joints with the sternum while the 1<sup>st</sup> costal process fuses with the sternum.<sup>1</sup>

Before the completion of the chondrification of the vertebrae, the process of ossification starts in the 8<sup>th</sup> week of development with the appearance of ossification centres in the cartilaginous centra, neural arches and the ribs.<sup>1</sup> The ossification of the centra occurs first in the lowest thoracic and upper lumbar levels and then progressively appears at adjacent caudal and cranial levels.<sup>11,12</sup> Neural arches do not show any exact pattern but ossify first in the cervicothoracic levels followed by upper cervical and the remaining cervical levels before the ossification extends to the mid-thoracic and thoracolumbar levels from where the remaining neural arches ossify cranially and caudally.<sup>12</sup> Ossification is not completed until adolescence and the ventral ends of the costal processes persist as the costal cartilages.<sup>1</sup> Similarly, the upper and lower surfaces of the vertebral body are covered by thick cartilage plates that are responsible for the longitudinal growth of the vertebral bodies while periosteal ossification is responsible for the horizontal growth.<sup>4</sup>

Mesenchymal cells between the cranial and caudal parts of the original sclerotome do not proliferate and fill the space between the precartilaginous vertebral bodies and contribute to *the formation of the intervertebral discs*.<sup>5,8</sup> Instead, the notochord becomes extruded into the intervertebral region due to the gradual closure of its canal. At the end of the 10<sup>th</sup> embryonic week the cells of the vertebral bodies have become cartilaginous and the cells of the notochord lie entirely within the intervertebral disc,<sup>7</sup> which further enlarges to form the nucleus pulposus at about 55 days of development.<sup>5,8</sup> This expanded notochord (chorda reticulum) is surrounded by embryonic cartilage and in the periphery of the intervertebral disc the collagen fibres appear to form the annulus fibrosus, which is derived from the sclerotomic mesenchyme located between the adjacent vertebral bodies.<sup>8</sup> The collagen fibres in the annulus fibrosus appear as early as in the 10<sup>th</sup> week of development.<sup>13</sup> By the time of birth only a few notochordal cells remain which disappear during the first few years of life.<sup>4</sup>

## REFERENCES

1. Fitzgerald MJT, Fitzgerald M. *Human Embryology*. 1st ed. London, UK: Baillière Tindall; 1994:251.
2. White AA,3rd. Analysis of the mechanics of the thoracic spine in man. An experimental study of autopsy specimens. *Acta Orthop Scand Suppl*. 1969;127:1-105.
3. Roberts S, Evans H, Trivedi J, Menage J. Histology and pathology of the human intervertebral disc. *J Bone Joint Surg Am*. 2006;88-A(Suppl 2):10-14.
4. Bogduk N. *Clinical Anatomy of the Lumbar Spine and Sacrum*. 4th ed. New York, NY: Elsevier/Churchill Livingstone; 2005.
5. Snell RS. *Clinical Anatomy*. 7th ed. Philadelphia, PA: Lippincott Williams & Wilkins; 2004.
6. Berns DH, Blaser SI, Modic MT. Magnetic resonance imaging of the spine. *Clin Orthop Relat Res*. 1989;244:78-100.
7. Coventry MB, Ghormley RK, Kernohan JW. The intervertebral disc: Its microscopic anatomy and pathology. Part I: Anatomy, development and physiology. *J Bone Joint Surg*. 1945;27(2):105-112.
8. Sadler TW. *Langman's Medical Embryology*. 5th ed. Baltimore, MD: Williams & Wilkins; 1985:410.
9. O'Rahilly R, Muller F, Meyer DB. The human vertebral column at the end of the embryonic period proper. 3. The thoracolumbar region. *J Anat*. 1990;168:81-93.
10. O'Rahilly R, Muller F, Meyer DB. The human vertebral column at the end of the embryonic period proper. 2. The occipitocervical region. *J Anat*. 1983;136(1):181-195.
11. Noback CR, Robertson GG. Sequences of appearance of ossification centers in the human skeleton during the first five prenatal months. *Am J Anat*. 1951;89(1):1-28.
12. Bagnall KM, Harris PF, Jones PR. A radiographic study of the human fetal spine. 2. The sequence of development of ossification centres in the vertebral column. *J Anat*. 1977;124(3):791-802.
13. Hickey DS, Hukins DW. Collagen fibril diameters and elastic fibres in the annulus fibrosus of human fetal intervertebral disc. *J Anat*. 1981;133(3):351-357.

## APPENDIX C: THE ONE-YEAR PREVALENCE OF BACK AND NECK PAIN IN OCCUPATIONAL GROUPS

Author	Sample	Question	Prevalence of back and neck pain
Bork 1996 <sup>1</sup>	928 physical therapists	“Have you at any time in the last 12 months had trouble (ache, pain, discomfort) in the neck, upper and low-back?”	<ul style="list-style-type: none"> <li>• neck: 25%</li> <li>• upper or mid-back: 29%</li> <li>• low-back: 45%</li> </ul>
Chee 2004 <sup>2</sup>	906 women workers	“Have you at any time in the last 12 months had trouble (ache, pain, discomfort) in the neck, upper and low-back?”	<ul style="list-style-type: none"> <li>• neck: 26%</li> <li>• upper or mid-back: 40%</li> <li>• low-back: 24%</li> </ul>
Cromie 2000 <sup>3</sup>	536 physical therapists	“Have you at any time in the last 12 months had trouble (ache, pain, discomfort) in the neck, upper and low-back?”	<ul style="list-style-type: none"> <li>• neck: 48%</li> <li>• upper or mid-back: 41%</li> <li>• low-back: 63%</li> </ul>
Engström 1999 <sup>4</sup>	67 automobile assembly workers	“Have you at any time in the last 12 months had trouble (ache, pain, discomfort) in the neck, upper and low-back?”	<ul style="list-style-type: none"> <li>• neck: 31%</li> <li>• upper or mid-back: 15%</li> <li>• low-back: 46%</li> </ul>
Finsen 1994 <sup>5a</sup>	99 dentists	“Have you at any time in the last 12 months had trouble (ache, pain, discomfort) in the neck, upper and low-back?”	<ul style="list-style-type: none"> <li>• ♂</li> <li>• neck: 59%</li> <li>• upper or mid-back: 15%</li> <li>• low-back: 59%</li> </ul>
Gamperiene 1999 <sup>6</sup>	363 workers	“Have you at any time in the last 12 months had trouble (ache, pain, discomfort) in the neck, upper and low-back?”	<ul style="list-style-type: none"> <li>• neck: 17%</li> <li>• upper or mid-back: 13%</li> <li>• low-back: 28%</li> </ul>
Goldsheyder 2002 <sup>7</sup>	300 mason tenders	Presence of musculoskeletal symptoms	<ul style="list-style-type: none"> <li>• neck: 41%</li> <li>• upper or mid-back: 31%</li> <li>• low-back: 65%</li> </ul>
Johanning 1991 <sup>8a</sup>	584 subway train and switch board operators	History, location, timing and severity of back pain	<ul style="list-style-type: none"> <li>• Subway / switch board</li> <li>• neck: 31% / 24%</li> <li>• upper or mid-back: 18% / 12%</li> <li>• low-back: 56% / 36%</li> </ul>
Johansson 1993 <sup>9</sup>	Two groups: n=17 and n=28	“Have you at any time in the last 12 months had trouble (ache, pain, discomfort) in the neck, upper and low-back?”	<ul style="list-style-type: none"> <li>• Groups</li> <li>• neck: 65% / 57%</li> <li>• upper or mid-back: 29% / 28%</li> <li>• low-back: 53% / 72%</li> </ul>
Johansson 1994 <sup>10</sup>	450 metal industry workers	“Have you at any time in the last 12 months had trouble (ache, pain, discomfort) in the neck, upper and low-back?”	<ul style="list-style-type: none"> <li>• Blue- / white-collar</li> <li>• neck: 39% / 45%</li> <li>• upper or mid-back: 21% / 16%</li> <li>• low-back: 43% / 42%</li> </ul>
Merlino 2003 <sup>11</sup>	996 apprentice construction workers	“During the last 12 months have you had a job-related ache, pain or discomfort in the neck, upper and low-back?”	<ul style="list-style-type: none"> <li>• neck: 32%</li> <li>• upper or mid-back: 27%</li> <li>• low-back: 54%</li> </ul>
Niedhammer 1994 <sup>12</sup>	310 acute care nurses	Any musculoskeletal complaint in the spine and its location	<ul style="list-style-type: none"> <li>• neck: 24%</li> <li>• upper or mid-back: 23%</li> <li>• low-back: 41%</li> </ul>

Author	Sample	Question	Prevalence of back and neck pain
Olafsdottir 2000 <sup>13</sup>	254 fish-filleting women	“Have you at any time in the last 12 months had trouble (ache, pain, discomfort) in the neck, upper and low-back?”	<ul style="list-style-type: none"> <li>• neck: 69%</li> <li>• upper or mid-back: 37%</li> <li>• low-back: 68%</li> </ul>
Osborn 1990 <sup>14</sup>	385 dental hygienists	Experienced pain (location, severity and frequency)	<ul style="list-style-type: none"> <li>• neck: 27%</li> <li>• upper or mid-back: 15%</li> <li>• low-back: 36%</li> </ul>
Palmer 1996 <sup>15</sup>	108 workers from tomato-growing nurseries	“Have you at any time in the last 12 months had trouble (ache, pain, discomfort) in the neck, upper and low-back?”	<ul style="list-style-type: none"> <li>• neck: 38%</li> <li>• upper or mid-back: 29%</li> <li>• low-back: 53%</li> </ul>
Ratzon 2000 <sup>16</sup>	60 male dentists	“Have you at any time in the last 12 months had trouble (ache, pain, discomfort) in the neck, upper and low-back?”	<ul style="list-style-type: none"> <li>• neck: 38%</li> <li>• upper or mid-back: 20%</li> <li>• low-back: 55%</li> </ul>
Rosecrance 1996 <sup>17</sup>	526 plumbers and pipefitters	“During the last 12 months have you had a job-related ache, pain or discomfort?”	<ul style="list-style-type: none"> <li>• neck: 25%</li> <li>• upper or mid-back: 29%</li> <li>• low-back: 45%</li> </ul>
Rundcrantz 1991 <sup>18</sup>	311 dentists	“Have you at any time in the last 12 months had trouble (ache, pain, discomfort) in the neck, upper and low-back?”	<ul style="list-style-type: none"> <li>• ♂</li> <li>• neck: 48%</li> <li>• upper or mid-back: 17%</li> <li>• low-back: 37%</li> </ul>
Rundcrantz 1990 <sup>19</sup>	359 dentists	“Have you at any time in the last 12 months had trouble (ache, pain, discomfort) in the neck, upper and low-back?”	<ul style="list-style-type: none"> <li>• ♂</li> <li>• neck: 46%</li> <li>• upper or mid-back: 10%</li> <li>• low-back: 34%</li> </ul>
Schibye 1995 <sup>20</sup>	306 sewing machine operators	“Have you at any time in the last 12 months had trouble (ache, pain, discomfort) in the neck, upper and low-back?”	<ul style="list-style-type: none"> <li>• neck: 56%</li> <li>• upper or mid-back: 33%</li> <li>• low-back: 45%</li> </ul>
Shugars 1987 <sup>21</sup>	1253 dentists	Musculoskeletal pain experienced in 1984	<ul style="list-style-type: none"> <li>• neck: 17%</li> <li>• upper or mid-back: 11%</li> <li>• low-back: 37%</li> </ul>
Torp 1996 <sup>22</sup>	103 car mechanics	“Have you at any time in the last 12 months had trouble (ache, pain, discomfort) in the neck, upper and low-back?”	<ul style="list-style-type: none"> <li>• neck: 62%</li> <li>• upper or mid-back: 29%</li> <li>• low-back: 76%</li> </ul>
Törner 1991 <sup>23</sup>	Welders (n=58) and clerks (n=33)	“Have you at any time in the last 12 months had trouble (ache, pain, discomfort) in the neck, upper and low-back?”	<ul style="list-style-type: none"> <li>• Welders / clerks</li> <li>• neck: 63% / 27%</li> <li>• upper or mid-back: 17% / 6%</li> <li>• low-back: 59% / 48%</li> </ul>
Törner 1988 <sup>24</sup>	1243 professional fishermen	“Have you at any time in the last 12 months had trouble (ache, pain, discomfort) in neck, upper and low-back?”	<ul style="list-style-type: none"> <li>• neck: 19%</li> <li>• upper or mid-back: 12%</li> <li>• low-back: 52%</li> </ul>
Yeung 2002 <sup>25</sup>	217 male manual handling workers	“Have you at any time in the last 12 months had trouble (ache, pain, discomfort) in the neck, upper and low-back?”	<ul style="list-style-type: none"> <li>• neck: 31%</li> <li>• upper or mid-back: 33%</li> <li>• low-back: 58%</li> </ul>
Zimmermann 1997 <sup>26</sup>	410 operating engineers	“Have you at any time in the last 12 months had trouble (ache, pain, discomfort) in neck, upper and low-back?”	<ul style="list-style-type: none"> <li>• neck: 44%</li> <li>• upper or mid-back: 24%</li> <li>• low-back: 60%</li> </ul>

Prevalence rates estimated from a figure.

## REFERENCES

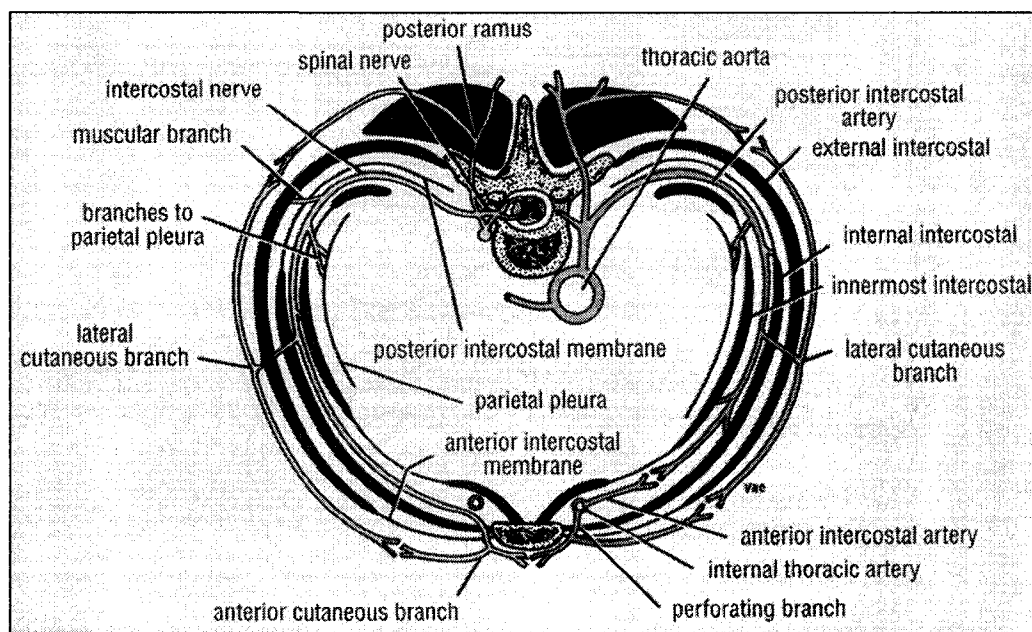
1. Bork BE, Cook TM, Rosecrance JC, et al. Work-related musculoskeletal disorders among physical therapists. *Phys Ther.* 1996;76(8):827-835.
2. Chee HL, Rampal KG. Work-related musculoskeletal problems among women workers in the semiconductor industry in peninsular Malaysia. *Int J Occup Environ Health.* 2004;10(1):63-71.
3. Cromie JE, Robertson VJ, Best MO. Work-related musculoskeletal disorders and the culture of physical therapy. *Phys Ther.* 2002;82(5):459-472.
4. Engstrom T, Hanse JJ, Kadefors R. Musculoskeletal symptoms due to technical pre-conditions in long cycle time work in an automobile assembly plant: A study of prevalence and relation to psychosocial factors and physical exposure. *Appl Ergon.* 1999;30(5):443-453.
5. Finsen L, Christensen H, Bakke M. Musculoskeletal disorders among dentists and variation in dental work. *Appl Ergon.* 1998;29(2):119-125.
6. Gamperiene M, Stigum H. Work related risk factors for musculoskeletal complaints in the spinning industry in Lithuania. *Occup Environ Med.* 1999;56(6):411-416.
7. Goldsheyder D, Nordin M, Weiner SS, Hiebert R. Musculoskeletal symptom survey among mason tenders. *Am J Ind Med.* 2002;42(5):384-396.
8. Johanning E. Back disorders and health problems among subway train operators exposed to whole-body vibration. *Scand J Work Environ Health.* 1991;17(6):414-419.
9. Johansson JA, Kadefors R, Rubenowitz S, et al. Musculoskeletal symptoms, ergonomic aspects and psychosocial factors in two different trucks assembly concepts. *Int J Ind Ergonom.* 1993;12:35-48.
10. Johansson JA. Work-related and non-work-related musculoskeletal symptoms. *Appl Ergon.* 1994;25(4):248-251.
11. Merlino LA, Rosecrance JC, Anton D, Cook TM. Symptoms of musculoskeletal disorders among apprentice construction workers. *Appl Occup Environ Hyg.* 2003;18(1):57-64.
12. Niedhammer I, Lert F, Marne MJ. Back pain and associated factors in French nurses. *Int Arch Occup Environ Health.* 1994;66(5):349-357.
13. Olafsdottir H, Rafnsson V. Musculoskeletal symptoms among women currently and formerly working in fish-filleting plants. *Int J Occup Environ Health.* 2000;6(1):44-49.
14. Osborn JB, Newell KJ, Rudney JD, Stoltenberg JL. Musculoskeletal pain among Minnesota dental hygienists. *J Dent Hyg.* 1990;64(3):132-138.
15. Palmer KT. Musculoskeletal problems in the tomato growing industry: 'tomato trainer's shoulder'? *Occup Med (Lond).* 1996;46(6):428-431.
16. Ratzon NZ, Yaros T, Mizlik A, Kanner T. Musculoskeletal symptoms among dentists in relation to work posture. *Work.* 2000;15(3):153-158.
17. Rosecrance JC, Cook TM, Zimmermann CL. Work-related musculoskeletal symptoms among construction workers in the pipe trades. *Work.* 1996;7:13-20.

18. Rundcrantz BL, Johnsson B, Moritz U. Pain and discomfort in the musculoskeletal system among dentists. A prospective study. *Swed Dent J*. 1991;15(5):219-228.
19. Rundcrantz BL, Johnsson B, Moritz U. Cervical pain and discomfort among dentists. Epidemiological, clinical and therapeutic aspects. Part 1. A survey of pain and discomfort. *Swed Dent J*. 1990;14(2):71-80.
20. Schibye B, Skov T, Ekner D, Christiansen JU, Sjogaard G. Musculoskeletal symptoms among sewing machine operators. *Scand J Work Environ Health*. 1995;21(6):427-434.
21. Shugars D, Miller D, Williams D, Fishburne C, Strickland D. Musculoskeletal pain among general dentists. *Gen Dent*. 1987;35(4):272-276.
22. Torp S, Riise T, Moen BE. Work-related musculoskeletal symptoms among car mechanics: A descriptive study. *Occup Med (Lond)*. 1996;46(6):407-413.
23. Torner M, Zetterberg C, Anden U, Hansson T, Lindell V. Workload and musculoskeletal problems: A comparison between welders and office clerks (with reference also to fishermen). *Ergonomics*. 1991;34(9):1179-1196.
24. Torner M, Blide G, Eriksson H, Kadefors R, Karlsson R, Petersen I. Workload and ergonomics measures in Swedish professional fishing. *Appl Ergon*. 1988;19(3):202-212.
25. Yeung SS, Genaidy A, Deddens J, Alhemoood A, Leung PC. Prevalence of musculoskeletal symptoms in single and multiple body regions and effects of perceived risk of injury among manual handling workers. *Spine*. 2002;27(19):2166-2172.
26. Zimmermann CL, Cook TM, Rosecrance JC. Operating engineers: Work-related musculoskeletal disorders and the trade. *Appl Occup Environ Hyg*. 1997;12(10):670-680.



## APPENDIX D: INNERVATION AND NEURAL ANATOMY OF THE THORACIC REGION

The twelve thoracic *spinal nerves* are formed by the united dorsal (sensory) and ventral (motor) roots lateral to dorsal root ganglion. The spinal nerves contain both afferent and efferent fibres that either conduct information to (afferent) or from (efferent) the central nervous system.<sup>1</sup> The spinal nerve branches into a larger ventral ramus (intercostal nerve) and a smaller dorsal ramus which will divide into medial and lateral branch supplies the dorsal structures, such as facet joints.<sup>2,3</sup> The intercostal nerve further gives off several branches, such as lateral and anterior cutaneous branches, of which lateral portion reaches the skin on the side of the chest and divides into anterior and posterior branch, and anterior cutaneous branch, which reaches the skin near midline and divides into medial and lateral branch.<sup>4</sup> (Figure A-1.)



**Figure A-1.** Cross-section of the thorax with a distribution of a nerve at one level after exiting the spinal cord.<sup>4</sup> (Reprinted with permission from Lippincott Williams & Wilkins.)

Along the antero-lateral aspect of the vertebral column on either side are located the *sympathetic trunks*, containing approximately 11 ganglia in the thoracic region, which

communicate with the ventral rami via rami communicantes.<sup>2,5</sup> The sympathetic fibres emerge from the spinal cord through the ventral roots, join the spinal nerves and leave via (white) rami communicantes to the sympathetic trunk. After the fibres have synapsed on the principal ganglionic cells these postganglionic fibres may return to the spinal nerve in (grey) rami communicantes to be distributed to their target organs via either dorsal or ventral ramus or may leave the sympathetic trunk directly to the viscera.<sup>2</sup> Each thoracic sympathetic trunk gives off at least 4-5 nerves which can be divided into three categories: large, medium and small nerves.<sup>6</sup> The direct connections between sympathetic trunk and abdominal viscera are made of the large nerves of sympathetic branches,<sup>2,3</sup> and can be divided into greater, lesser and least splanchnic nerve.<sup>6</sup> These nerves arise from the lower eight ganglia and are each formed from a varying number of sympathetic ganglia. For example, the greater splanchnic nerve is formed by one to ten ganglia<sup>6-8</sup> and is most commonly found to be composed of T5–T9 levels. The lesser splanchnic nerve is formed by one to five ganglia with the most common levels being T10-T11, and the least splanchnic nerve by one to three ganglia consisting most often of levels T11-T12 or T12 only.<sup>7</sup> Perhaps due to the inter-individual variations differences between studies exist in the descriptions of splanchnic nerves.

The small- and medium-sized splanchnic nerves are directed towards thoracic viscera and costovertebral joints.<sup>6</sup> Sinuvertebral nerves, on the other hand, are recurrent branches of the ventral rami which originate from both the spinal nerve and the sympathetic trunk or its rami communicantes and re-enter the intervertebral foramen towards structures inside the spinal canal, such as posterior longitudinal ligament.<sup>2,5</sup> After the sinuvertebral nerves enter the spinal canal they have a variable course that may be short, long, ascending, descending, transverse or oblique and connect with sinuvertebral nerves of the other sides and neighbouring segments. Some branches may be particularly long and extend over two levels inferiorly and superiorly.<sup>9</sup>

The thoracic region can be divided into *ventral and dorsal compartments* by a coronal plane through the intervertebral foramen based on the source of innervation.<sup>10</sup> The ventral compartment in the thoracic region contains the vertebral bodies, discs, longitudinal ligaments, ventral dura, prevertebral muscles and costovertebral joints which are directly supplied by nerve fibres related to the sympathetic trunk and rami communi-

cantes from both sides. Dorsal compartment, on the other hand, is supplied via ipsilateral dorsal rami of the spinal nerves, and contains facet joints, dorsal part of the dura, intrinsic back muscles and ligaments, as well as costovertebral joints. Not only is the source of innervation different between the two compartments, but also the extent of overlap of innervation. The structures in the ventral compartment can be bi- or multisegmentally innervated whereas dorsal structures are either bi- or monosegmentally innervated and this may have implications for the patterns of referred pain.<sup>2</sup>

## REFERENCES

1. Waxman SG. *Clinical Neuroanatomy*. 25th ed. New York, N.Y.: Lange Medical Books/McGraw-Hill; 2003.
2. Groen GJ, Stolker RJ. Thoracic neural anatomy. In: Giles LGF, Singer KP, eds. *Clinical Anatomy and Management of Thoracic Spine Pain*. 1st ed. Oxford, UK: Butterworth-Heinemann; 2000:114-141.
3. Middleditch A, Oliver J. *Functional Anatomy of the Spine*. 2nd ed. London, UK: Elsevier Butterworth-Heinemann; 2005.
4. Snell RS. *Clinical Anatomy*. 7th ed. Philadelphia, PA: Lippincott Williams & Wilkins; 2004.
5. Bogduk N. *Clinical Anatomy of the Lumbar Spine and Sacrum*. 4th ed. New York, NY: Elsevier/Churchill Livingstone; 2005.
6. Groen GJ, Baljet B, Boekelaar AB, Drukker J. Branches of the thoracic sympathetic trunk in the human fetus. *Anat Embryol (Berl)*. 1987;176(4):401-411.
7. Yang HJ, Gil YC, Lee WJ, Kim TJ, Lee HY. Anatomy of thoracic splanchnic nerves for surgical resection. *Clin Anat*. 2008;21(2):171-177.
8. Naidoo N, Partab P, Pather N, Moodley J, Singh B, Satyapal KS. Thoracic splanchnic nerves: Implications for splanchnic denervation. *J Anat*. 2001;199(5):585-590.
9. Groen GJ, Baljet B, Drukker J. Nerves and nerve plexuses of the human vertebral column. *Am J Anat*. 1990;188(3):282-296.
10. Bogduk N. The innervation of the lumbar spine. *Spine*. 1983;8(3):286-293.

## APPENDIX E: DICTIONARY

**Caudal**= Toward the tail; downwards the spine.<sup>1</sup>

**Cranial**= Toward the head; upwards the spine.<sup>1</sup>

**Discography**= Injection of the disc.<sup>2</sup>

**Dorsal root ganglion**= Contains the cell bodies of the sensory fibres in the dorsal root.<sup>3</sup>

**Free nerve ending**= Peripheral endings of sensory nerve fibres.

**Frequency-encoding**= A spatial location of the signal along the long axis of the image using the precessional frequency of the magnetic moments.<sup>4</sup>

**Neuron**= A nerve cell consisting of a cell body, axon and dendrites.

**Nociceptor**= A sensory receptor that responds to pain.

**Pixel**= A picture element which is used to measure the resolution (or sharpness) of images.<sup>4</sup>

**PD-weighted**= Demonstrates differences in the proton densities (number of hydrogen protons in the tissues); long TR, short TE.<sup>4</sup>

**Phase-encoding**= A spatial location of the signal along the short axis of the image using the precessional phase of the magnetic moments.<sup>4</sup>

**Resonance**= An energy transition that occurs between objects subjected to a same frequency.<sup>4</sup>

**Scheuermann's disease**= Three or more wedged vertebrae of 5° or more.<sup>5</sup>

**Signal-to-noise ratio**= Ratio of signal relative to noise; signal can be increased for example by increasing field strength, imaging structures with high proton density, using small coil versus large coil which are placed in the transverse plane perpendicular to the main field and increasing TR, TE and flip angle.<sup>4</sup>

**Somite**= Serially arranged clumps of embryonic connective tissue.<sup>6</sup>

**Synapse**= A junction between neurons that permit them to communicate with each other.<sup>7</sup>

**T1**= Intrinsic contrast parameter that is inherent to the tissue being imaged. Defined as the time it takes 63% of the longitudinal magnetization to recover (spin-lattice energy transfer) after a TR (water has a long T1 and fat a short).<sup>4</sup>

**T1-weighted**= Demonstrating the differences in the T1 relaxation times of the tissues; short TR, short TE.<sup>4</sup>

**T2**= Intrinsic contrast parameter that is inherent to the tissue being imaged. Defined as the time it takes for the transverse magnetization to be reduced to 63% of its original value (spin-spin energy transfer). TE determined how much T2 decay occurs in a particular tissue (fat has a short T2 and water a long).<sup>4</sup>

**T2-weighted**= Demonstrating the differences in the T2 relaxation times of the tissues; long TR, long TE.<sup>4</sup>

**TE**= Time between the radiofrequency excitation pulse and the collection of the signal (echo), ms.

**TR**= Time between two consecutive radiofrequency pulses, ms.<sup>4</sup>

**Vertebral deformity**= Vertebral fracture; *anterior wedge* (collapse of the anterior border of the vertebral body), *biconcave* (collapse of the central portion of the body) and *crush* (collapse of the entire body).

**Vertebral hemangioma**= A benign vascular tumour.<sup>8</sup>

**Voxel**=A volume element in the three dimensional space corresponding to a pixel for a given slice thickness.<sup>4</sup>

**Wedge**= A wedge of 5° or more.<sup>5</sup>

## REFERENCES

1. Kahle W, Leonhardt H, Platzer W. *Color Atlas/Text of Human Anatomy, Volume 1. Locomotor System*. 4th revised ed. Stuttgart, Germany: Georg Thieme Verlag; 1992.
2. Wood KB, Schellhas KP, Garvey TA, Aeppli D. Thoracic discography in healthy individuals. A controlled prospective study of magnetic resonance imaging and discography in asymptomatic and symptomatic individuals. *Spine*. 1999;24(15):1548-1555.
3. Bogduk N. *Clinical Anatomy of the Lumbar Spine and Sacrum*. 4th ed. New York, NY: Elsevier/Churchill Livingstone; 2005.
4. Westbrook C. *MRI at a Glance*. 1st ed. Oxford, United Kingdom: Blackwell Science; 2002.
5. Sørensen KH. *Scheuermann's Juvenile Kyphosis: Clinical Appearances, Radiology, Aetiology, and Prognosis*. Copenhagen: Munksgaard; 1964.
6. Fitzgerald MJT, Fitzgerald M. *Human Embryology*. 1st ed. London, UK: Baillière Tindall; 1994.
7. Waxman SG. *Clinical Neuroanatomy*. 25th ed. New York, N.Y.: Lange Medical Books/McGraw-Hill; 2003.
8. Templin CR, Stambough JB, Stambough JL. Acute spinal cord compression caused by vertebral hemangioma. *Spine J*. 2004;4(5):595-600.