

Ischemic Signatures In Acute Intracerebral Hemorrhage

by

Laura Catherine Gioia

A thesis submitted in partial fulfillment of the requirements for the degree of

Master of Science

in

Translational Medicine

Department of Medicine
University of Alberta

© Laura Catherine Gioia, 2016

THESIS ABSTRACT

Introduction: Acute blood pressure (BP) reduction is among the few treatments options available in the acute management of intracerebral hemorrhage (ICH). Recent observational studies have demonstrated the presence of lesions suggestive of ischemia on diffusion-weighted sequences (DWI) on MRI. We hypothesized that DWI lesions in ICH are independent from acute BP reduction and hypoperfusion.

Methods: Patients with spontaneous ICH undergoing MR imaging were retrospectively enrolled in the first part of the study. In the second part of the study, ICH patients who underwent MRI with perfusion-weighted imaging were prospectively enrolled. Perilesional cerebral blood flow (CBF) was calculated on post-processed calibrated perfusion maps.

Results: One hundred-seventeen patients were enrolled in the first substudy. DWI lesions in regions remote to the hematoma were found in 17 (14.7%) patients. Maximal SBP drop at 24 hours was similar in patients with (-20.5(51) mmHg) and without remote DWI lesions (-27(33.5) mmHg, $p=0.96$). Nineteen patients were enrolled in the second substudy. On baseline MRI, 3 DWI hyperintensities remote to the hematoma were found in 2 patients and 1 subsequent remote DWI hyperintensity was found in one patient on day 7 MRI. Mean absolute perilesional CBF was 37.6 ± 17.2 ml/100g/min with a perilesional rCBF of 1.1 ± 0.1 . Mean absolute internal borderzone (BZ) CBF was slightly lower in patients with DWI lesions (18.8 ± 1.8 ml/100g per minute) than patients without DWI lesions (22.6 ± 8.0 ml/100g, $p=0.29$); however, mean rCBF in the internal BZ regions did not differ between groups (0.96 ± 0.01 and 1.0 ± 0.2 , respectively, $p=0.37$).

Conclusion: DWI lesions remote to the hematoma region are commonly observed in spontaneous ICH. Remote DWI lesions are not associated with acute 24-hour BP reduction nor do they appear to be associated with perilesional or borderzone hypoperfusion. These data do not support a hemodynamic mechanism of ischemic injury after spontaneous ICH.

PREFACE

Ethics approval

This thesis is an original work by Laura Gioia. The data acquired to conduct the research project, of which this thesis is a part, received research ethics approval from the University of Alberta Research Ethics Board, Title: *ICH-ADAPT II study and TIA-MISO studies*.

Published work

Chapter 1 of this thesis has been published as L.C. Gioia, M.P. Kate, D. Dowlatshahi, M.D. Hill, and K. Butcher, “Blood Pressure Management In Acute Intracerebral Hemorrhage: Current Evidence And Ongoing Controversies,” *Current Opinion of Critical Care*, 2015, vol. 21, issue 2, page 99-106, <http://journals.lww.com/co-criticalcare/Pages/default.aspx#>. I was responsible for the literature review, analyses as well as the manuscript composition. M.P.Kate assisted with the data collection and contributed to manuscript edits. D Dowlatshahi, M.D. Hill assisted with concept formation and contributed to manuscript edits. K. Butcher was the supervisory author and was involved with concept formation and manuscript composition.

Chapter 2 of this thesis has been published as L.C. Gioia, M.P. Kate, V Choi, L Sivakumar, T Jeerakathil, J Kosior, D Emery, and K. Butcher, “Ischemia in intracerebral hemorrhage is associated with leukoaraiosis and hematoma volume, not blood pressure reduction,” *Stroke*, 2015, vol. 46, issue 6, page 1541-7, <http://stroke.ahajournals.org>. I was responsible for the study design, data collection, data analyses as well as the manuscript composition. M.P.Kate and V Choi assisted with the data collection and contributed to manuscript edits. T. Jeerkathil assisted with statistical analyses and contributed to manuscript edits. J Kosior assisted with data analysis and interpretation. D Emery assisted with data collection and contributed to manuscript edits. K. Butcher was the supervisory author and was involved with concept formation and manuscript composition.

Acknowledgments

I would like to acknowledge the ongoing mentorship and support from my supervisor, Dr. Ken Butcher, from whom I have learned tremendously. I would also like to thank the supervisory committee (Dr. Christian Beaulieu, Dr. Thomas Jeerakathil, Dr. and Dr. Alan Wilman) for their invaluable insight and guidance. Lastly, I would like to acknowledge the salary support I received during my Clinical Research Fellowship and Master's degree from the Alberta Innovates Health Solutions and the foundation of the Centre Hospitalier de l'Université de Montréal.

Table of Contents

THESIS ABSTRACT

PREFACE

ACKNOWLEDGEMENTS

TABLE OF CONTENTS

LIST OF TABLES

LIST OF FIGURES

ABBREVIATIONS

CHAPTER 1. Introduction - Blood Pressure Management In Acute Intracerebral Hemorrhage: Current Evidence And Ongoing Controversies

I. Elevated Blood Pressure In Intracerebral Hemorrhage	1
II. Is Acute Blood Pressure Reduction Feasible?	2
III. Is Acute BP Reduction Safe?	4
IV. Is Acute BP Reduction Effective?	6
V. What Are The Remaining Knowledge Gaps?	9
VI. Conclusions	10
References	11

CHAPTER 2. Ischemia In Intracerebral Hemorrhage Is Associated With Leukoaraiosis And Hematoma Volume, Not Blood Pressure Reduction.

Introduction	17
Methods	18
Results	21
Discussion	25
Conclusion	29
References	30

CHAPTER 3. Analysis Of The Relationship Between Cerebral Blood Flow And Remote DWI Lesions In Patients With Acute Intracerebral Haemorrhage

Introduction	37
Methods	38
Results	41
Discussion	44
Conclusion	47
References	48

CHAPTER 4. Conclusions

Strengths and Limitations	54
Future Directions	55
Closing Remarks	55

Bibliography	56
---------------------	-----------

Appendix A. Request Permissions For Reproduction	64
---	-----------

List of Tables

Table 1.1	Prospective Clinical Trials of BP reduction in Intracerebral Hemorrhage.	15
Table 2.1	Baseline Clinical And Imaging Characteristics And Perihematoma DWI Lesions.	32
Table 2.2	Baseline Clinical And Imaging Characteristics And Remote DWI Lesions.	33
Table 3.1	Cerebral Perfusion Analyses In Patients With And Without Remote DWI Lesions.	51

List of Figures

Figure 1.1	Examples of hematoma and perihematoma edema regions of interest (ROI) on non-contrast CT images and cerebral blood flow (CBF) maps before and after blood pressure (BP) treatment.	16
Figure 2.1	Examples of Diffusion-Weighted Imaging (DWI) lesions in the perihematoma region and more remotely in patients with ICH.	34
Figure 2.2	Relationship Between Perihematoma Tissue Volumes Reaching Ischemic Thresholds And Hematoma Volume.	35
Figure 2.3	The relationship between BP change over the first 24 hours and DWI lesions.	36
Figure 3.1	Example of perihematoma and borderzone regions of interest (ROI) in perfusion-weighted MRI in patients with intracerebral hemorrhage (ICH).	52

Abbreviations

ACA	Anterior Cerebral Artery
ADC	Apparent Diffusion Coefficient
AIF	Arterial Input Function
ATACH	Antihypertensive Treatment of Acute Cerebral Hemorrhage
BP	Blood Pressure
CT	Computed Tomography
CTP	Computed Tomography Perfusion
CBF	Cerebral Blood Flow
CBV	Cerebral Blood Volume
DBP	Diastolic Blood Pressure
DSC-MRI	Dynamic Susceptibility Contrast MRI
DWI	Diffusion Weighted Imaging
FAST-MAG	Field Administration of Stroke Therapy – Magnesium Study
FLAIR	Fluid-Attenuated Inversion Recovery
GCS	Glasgow Coma Scale
GRE	Gradient Recalled Echo
ICH	Intracerebral Hemorrhage
IVH	Intraventricular Hemorrhage
INTERACT	Intensive Blood Pressure-Reduction in Acute Cerebral Hemorrhage Trial
ICHADAPT	Intracerebral Hemorrhage Acutely Decreasing Arterial Pressure Trial
IQR	Interquartile Range
LA	Leukoaraiosis
MAP	Mean Arterial Pressure
MCA	Middle Cerebral Artery
MRI	Magnetic Resonance Imaging
NIHSS	National Institute of Health Stroke Scale
OR	Odds Ratio
PCA	Posterior Cerebral Artery
PET	Positron Emission Tomography

PROBE	Prospective Randomized Open-Label with Blinded Endpoint
PWI	Perfusion-weighted Imaging
RCT	Randomized Controlled Trial
ROI	Region-of-Interest
SBP	Systolic Blood Pressure
SCAST	Scandinavian Candesartan Acute Stroke Trial
SD	Standard Deviation
SPECT	Single-photon emission computed tomography
SWI	Susceptibility-weighted Imaging
TIA	Transient Ischemic Attack
TIAMISO	Transient Ischemic Attack and Minor Stroke Study

CHAPTER 1.

Introduction - Blood Pressure Management In Acute Intracerebral Hemorrhage: Current Evidence And Ongoing Controversies

(published in Current Opinion of Critical Care, 2015, vol. 21, issue 2, page 99-106)

I. Elevated Blood Pressure In Intracerebral Hemorrhage

Spontaneous intracerebral hemorrhage (ICH) occurs in 7-8% of patients with acute stroke, and is associated with high rates of morbidity (60%) and mortality (30%) at 30 days. Few proven medical treatment options exist. One potential acute medical intervention is blood pressure (BP) reduction.

Elevated BP, defined as a systolic blood pressure ≥ 140 mmHg, is seen in 75% of acute ICH patients.(1) The etiology of this acute BP increase remains unknown. Although a history of uncontrolled hypertension is associated with elevated acute BP, there is an acute elevation in most patients, which begins to resolve within hours of admission to hospital.(2) Evidence that this is an acute hypertensive response also comes from a recent population-based study that compared admission BP following acute ICH with 10-year premorbid BP readings obtained from primary care records.(3) In this study, admission BP after ICH was significantly higher (189.8 ± 38.5 mmHg) than the mean 10-year premorbid BP (149.1 ± 17.9 mmHg). The authors reported, however, that SBP was also higher in the days to weeks prior to ICH when compared to premorbid levels ($P < 0.0001$), raising the possibility that this is etiologically related to the acute ICH.

Other proposed mechanisms for the acute post ICH BP elevation include stress activation of neuroendocrine systems (renin-angiotensin-aldosterone cascade, sympathetic nervous activity, or glucocorticoid system) and damage to the central

autonomic centers including the insular cortex. Alternatively, acute BP elevation has been proposed to be a compensatory homeostatic mechanism that serves to maintain adequate cerebral perfusion pressure in the presence of increased intracranial pressure.

Elevated BP is a robust predictor of early mortality in ICH. Several studies have shown that admission mean arterial pressures (MAP) ≥ 145 mmHg are associated with higher 30-day mortality rates (47-67%) than lower MAP values (21-40%) ($p < 0.01$).^(4,5) Elevated SBP, particularly > 180 mmHg, has also been reported to be a predictor of 12-month mortality.⁽⁶⁾ A biologically plausible link between elevated BP and mortality is higher hematoma volumes, secondary to ongoing bleeding and/or rebleeding after the initial arteriolar rupture. Data from observational serial CT scan studies suggest that higher SBP is associated with an increased likelihood of hematoma expansion^(7,8). This relationship is clinically relevant given that larger hematoma volumes, particularly > 30 mL, are associated with 30-day mortality rates ranging from 60-90%, irrespective of ICH location.⁽⁹⁾ An individual patient pooled meta-analysis indicated the hazard ratio of death increased by 3% for each 1 ml increase in hematoma growth ($p < 0.0001$).⁽¹⁰⁾

II. Is Acute BP Reduction Feasible?

Seven prospective trials have assessed acute BP reduction in ICH patients (11–17)(Table 1). In general, these studies indicate that rapid lowering of BP using IV antihypertensive agents is possible, but achieving pre-specified reduction targets in a timely manner is challenging. In the pilot INTERACT study, only 40% of patients randomized to the intensive arm achieved a SBP < 140 mmHg one hour after randomization⁽¹²⁾. Even at 6 hours, only 66% of patients were at or below this target.

The INTERACT II trial was subject to some of the same limitations seen in INTERACT I (13). Once again, the <140 mmHg target was achieved in only 33% of patients randomized to that group. At 6 hours, only 53% were at or below target. Failure to achieve the target in a timely fashion may have been related to the lack of a stringent treatment protocol. In both INTERACT studies, several protocols were provided, but the antihypertensive therapy administered was ultimately determined by local availability and investigator preference. Accordingly, the antihypertensive agents used in the trials varied considerably. In INTERACT I, 22% of patients were treated with IV furosemide, which reduces cardiac pre-load, but has limited efficacy as an acute antihypertensive agent. In INTERACT II, IV urapidil, an alpha-1-adrenoreceptor antagonist, was the most common antihypertensive agent used (23%). The somewhat slow reduction in BP in the INTERACT trials may also reflect treatment resistance. Indeed, approximately 40% of patients required 2 or more antihypertensive agents to achieve target.

Although pilot data from the Antihypertensive Treatment of Acute Cerebral Hemorrhage (ATACH) study showed that IV nicardipine can lower BP in a more rapid and sustained manner, assigned BP targets were only achieved at 2 hours after start of treatment. Furthermore, treatment failure was seen in 15% of patients at the lowest SBP tier (110-140 mmHg).(14) In ICH ADAPT, the use of a strict BP-lowering protocol with three agents permitted a significant BP differential (-22 mmHg) between groups at 2 hours after randomization. The target BP was achieved in 79% of patients in the <150 mmHg group at 2 hours.

III. Is Acute BP Reduction Safe?

Intensive BP reduction was not associated with an increase in serious adverse event rates in the INTERACT studies (380/1602 (23.7%) in <140 mmHg group, and 399/1631 (24.5%) in <180 mmHg group, $p=0.62$). Rates of neurological deterioration <72 hours were also similar between groups (14.6% and 15.1%, respectively, $p=0.67$). In a pilot study of 3 different BP tiers (170-200, 140-170, and <140 mmHg) with IV nicardipine, rates of neurological deterioration and serious adverse events were more common in the 2 lowest tiers, but remained above pre-specified safety thresholds.(14) At a physiological level, however, physicians have remained concerned that rapid BP reduction may precipitate ischemic injury in the region surrounding the hematoma and/or more globally.

Long-standing hypertension has been hypothesized that cerebral autoregulation is right-shifted toward higher BP values. In addition, autoregulation may be disrupted following ICH, resulting in cerebral blood flow (CBF) becoming passively dependent on systemic arterial BP. Cerebral blood flow studies using various modalities (SPECT (18), PET(19), and MR perfusion(20,21)) have demonstrated the presence of hypoperfusion within the perihematoma region. However, PET imaging studies have also shown that while present, perihematoma hypoperfusion is accompanied by decreased oxygen extraction fraction (rather than increased oxygen extraction fraction as seen in ischemia), suggesting a state of reduced metabolic demand rather than ischemia as the underlying mechanism of perihematoma hypoperfusion.(19) The same group further demonstrated that perihematoma and hemispheric CBF remained unchanged after pharmacological BP

reduction in patients 6-22 hours after ICH onset.(22) This indicates some preservation of cerebral autoregulation in acute ICH patients.

The Intracerebral Hemorrhage Acutely Decreasing Arterial Pressure Trial (ICH ADAPT) study was designed to assess the effect of two different BP management strategies on perihematoma cerebral blood flow in acute ICH(16). In ICH ADAPT, 75 ICH patients ≤ 24 hours from symptom onset were randomized 1:1 to SBP target <150 mmHg or <180 mmHg. Patients in the <150 mmHg group readily achieved BP control within 15 minutes from randomization using a treatment protocol of IV labetalol, IV hydralazine, and/or IV enalapril, and maintained SBP <150 mmHg until CT perfusion imaging at 2 hours. The primary endpoint was perihematoma CBF.

In all patients, the mean absolute perihematoma CBF was lower (38.7 ± 11.9 ml/100g/min) than contralateral homologous regions (44.4 ± 11.1 ml/100g/min, $p < 0.001$), but remained above proposed CBF thresholds for ischemia (<20 ml/100g/min).(24) Furthermore, perihematoma relative CBF was not exacerbated by aggressive BP reduction since rCBF values were similar (0.86 ± 0.12 vs. 0.89 ± 0.09 , absolute difference, 0.03; 95% confidence interval -0.018 to 0.078) in the <150 and <180 groups respectively; $P=0.19$).

Aggressive BP reduction was not associated with an increase in the proportion of hypoperfused tissue reaching ischemic thresholds (<18 ml/100g/min) in the perihematoma region nor in the vascular borderzone (watershed) regions.(24) A subgroup analysis of patients undergoing CTP before and after BP treatment showed aggressive antihypertensive therapy did not alter perihematoma or hemispheric CBF, suggesting some preservation of cerebral autoregulation after ICH (Figure 1).(25) Further studies

have also shown that perihematoma oxygen delivery (as measured by the maximum oxygen extraction fraction, and the resulting maximum cerebral metabolic rate of oxygen) were unaffected by aggressive BP treatment.(26) Finally, aggressive BP reduction did not result in an increase in the volume of perihematoma edema.(27) Data from ICH ADAPT trial provides direct physiological evidence that acute BP reduction does not precipitate cerebral ischemia in ICH patients.

A recent post-hoc analysis of 274 patients with ICH enrolled the Scandinavian Candesartan Acute Stroke Trial (SCAST) suggested that BP-lowering treatment with candesartan within the first week after ICH was associated with an increased risk of poorer functional outcome at 90 days (adjusted common OR 1.61 (95% CI: 1.03-2.50;p=0.036).(28) Several limitations including the absence of a significant SBP differential between groups and the lack of adjustment of key predictors of outcome in ICH limit the strength of conclusions of this study. (*Gioia et al. Stroke (In press)*).

IV. Is Acute BP Reduction Effective?

The best available evidence for the efficacy of aggressive BP reduction in acute ICH comes from the Intensive Blood Pressure-Reduction in Acute Cerebral Hemorrhage Trial (INTERACT) trials. In the pilot INTERACT study, the primary endpoint was mean hematoma growth at 24 hours. Unadjusted univariate analysis indicated the mean proportional hematoma growth increase at 24 hours was higher (36.3%) in patients randomized to the <180 mmHg target than those with a <140 mmHg target (13.7%, p=0.04). This association was no longer evident, however, after adjustment for baseline hematoma volume and time to first CT (16.2% proportional increase in <180 mmHg arm

versus 6.2% increase in <140 mmHg arm, (p=0.06), with an overall 1.7 mL mean absolute difference in hematoma volume between groups (p=0.12). It is possible that the limited efficacy of acute BP reduction was related to the failure to achieve targets in a timely fashion. A post-hoc analysis indicated patients in the lower tertile of achieved SBP (<144 mmHg) experienced lower mean absolute and proportional increases in hematoma volume than those with higher SBP (p=0.03).(29)

In INTERACT 2, the primary outcome was the proportion of death or major disability (defined as mRS scores of 3-6) at 90 days. There was a trend to reduction in the risk of death or major disability in patients randomized to the <140 mmHg target (3.6% absolute risk reduction), but this was not statistically significant (OR 0.87 [95% CI: 0.75, 1.01], p=0.06). Ordinal shift analysis of 90-day mRS scores revealed a favorable outcome was more likely in patients randomized to the <140 mmHg target (OR 0.87 (0.77-1.00), p=0.04). This was a pre-specified secondary endpoint of INTERACT 2.(30)

In addition to the difficulty in achieving intensive BP targets (Section II), failure to demonstrate clear-cut efficacy in INTERACT may have been related to delays in treatment initiation. In both INTERACT studies, the median time from symptom onset to start of IV BP treatment was 4 hours. This delay may be relevant to the efficacy of early intensive BP treatment, as observational data indicates the majority of hematoma expansion occurs within 3 hours from ICH onset.(31) It is possible that initiation of antihypertensive medication at 4 hours from symptom onset may have diluted the overall efficacy of intensive BP treatment in acute ICH.

Finally, many patients enrolled in INTERACT 2 may have been at relatively low risk for hematoma expansion and may have had an overall better prognosis irrespective of

treatment. Known predictors of hematoma expansion, include the CT angiographic spot sign,(32)(33) time to first CT,(8) and baseline hematoma volume(8)(34). In INTERACT 2, the median (IQR) baseline hematoma volumes was 11.0 (6-19) mL. Data from the Virtual Stroke Archives (VISTA-ICH) indicate that smaller baseline hematoma volumes, particularly those ≤ 10 mL, are associated with a lower probability (OR 0.1 95% CI: 0.0-0.2, $p < 0.001$) of ICH expansion (> 6 ml), and have better clinical outcomes relative to those with hematoma volumes > 30 ml.(34) Indeed, the 12% mortality rate at 90 days in both treatment arms reflects a trial population with a better prognosis than that seen in previous observational studies. (6,35) The rate of ICH growth in INTERACT 2 has not yet been published. However, preliminary results indicate that the mean absolute hematoma growth was lower in patients who achieved SBP < 140 mmHg within 1 hour of randomization (1.7 mL) than patients who achieved the this target at later time points (4.2 mL at 1-6 hours, and 4.6 mL at > 6 hours, $p = 0.04$).(36) Therefore, there does appear to be a treatment effect, which is likely maximized by early and intensive BP treatment. This conclusion is supported by the results of a meta-analysis, which pooled data on 24-hour hematoma volume from the 4 RCTs. This analysis indicated that intensive BP reduction is associated with attenuation of hematoma growth, relative to standard BP treatment (-1.54 ml (95% CI: 0.04-3.04)).(37) In the Antihypertensive Treatment of Acute Cerebral Hemorrhage (ATACH) pilot study, rates of hematoma expansion did not differ between patients treated with more aggressive (32%) or less aggressive SBP reduction (17%, $p > 0.05$). This was only a feasibility study, however, which was underpowered to adequately assess this endpoint.(38)

V. What Are The Remaining Knowledge Gaps?

The Phase III multicenter randomized-controlled study of the Antihypertensive Treatment of Acute Cerebral Hemorrhage (ATACH II) is currently underway.(15) A total of 1,280 patients will be treated with a single antihypertensive agent, IV nicardipine, titrated to achieve the BP target within one hour of randomization. The primary outcome is the rate of death or major disability at 90 days. The study design of ATACH II does have some theoretical advantages over INTERACT 2. Specifically, in that patients are randomized at an earlier time point (<4.5 hours) and with the use of strict BP-lowering protocol using a single agent (IV nicardipine).

All trial data to date indicate that actually achieving an intensive BP target within the high-risk period for hematoma expansion (<3 hours from onset) is difficult. The recently published FAST-MAG study demonstrated the feasibility of conducting acute stroke trials in the prehospital setting.(39) Aggressive BP reduction in the prehospital setting may be a logical next step, although differentiating ischemic from hemorrhagic stroke presents a barrier to this approach. Phase II studies of modest prehospital BP reduction, using topical nitroglycerin in undifferentiated acute stroke patients are currently underway.(40–41)

Beyond the perihematoma region, MRI observational studies have described the presence of lesions with restricted diffusion on diffusion-weighted images (DWI), suggestive of acute ischemic injury in ICH, with prevalences ranging from 14-41%.(42-47) Furthermore, two studies demonstrated that the presence of DWI lesions was associated with a five-fold increase in the likelihood of a poor functional outcome.(42) Predictors of DWI lesions in ICH patients include ICH volume, cerebral microbleed

burden and leukoariaosis. Most concerning is the association with acute BP reduction. (42,43,46) Definitions of BP reduction varied between studies and actual pressures were not measured prospectively or systemically in any of them. A recent study of 117 ICH patients with MRI <14 days from ICH indicated DWI lesions, present in 14.5% of patients, were associated with prior ICH, antiplatelet use, and higher leukoariaosis volumes.(48) Conversely, BP reduction, measured at 6 time points within the first 24 hours, was not associated with DWI lesions. It is possible that these lesions are an epiphenomenon, resulting from the same underlying cerebral microangiopathy that caused the original ICH.

The ongoing ICH ADAPT II trial is aimed at addressing whether BP reduction is causally associated with DWI lesion formation in ICH. (17) In ICH ADAPT II, 300 patients will be randomized to two BP targets, <140 mmHg or <180 mmHg. The primary endpoint, which is the DWI lesion frequency, will be assessed with MRI 48 hours later.

VI. Conclusions

More than 3000 acute ICH patients have been enrolled in randomized trials of aggressive BP reduction. To date, these studies indicate that BP reduction is safe is associated with a modest benefit with respect to both hematoma expansion and functional outcomes. These trials also make it clear that rapid pharmacological reduction of BP is feasible, but not easily accomplished in all cases. Although not yet proven, available data suggest that earlier and more aggressive antihypertensive therapy may have a greater clinical benefit. While some clinicians do have lingering safety concerns, these are increasingly difficult to support.

References

1. Qureshi AI, Ezzeddine MA, Nasar A, Suri MFK, Kirmani JF, Hussein HM, et al. Prevalence of elevated blood pressure in 563,704 adult patients with stroke presenting to the ED in the United States. *Am J Emerg Med.* 2007;25:32–8.
2. Britton M, Carlsson A de FU. Blood pressure course in patients with acute stroke and matched controls. *Stroke.* 1986 [cited 2014 Nov 6]. p. 17:861–864.
3. Fischer U, Cooney MT, Bull LM, Silver LE, Chalmers J, Anderson CS, et al. Acute post-stroke blood pressure relative to premorbid levels in intracerebral haemorrhage versus major ischaemic stroke: A population-based study. *Lancet Neurol.* 2014;13:374–84.
A recent population-based study analysing post-admission BP values in acute ischemic stroke and ICH compared to 10-year premorbid BP values.
4. Dandapani BK, Suzuki S, Kelley RE, Reyes-Iglesias Y, Duncan RC. Relation Between Blood Pressure and Outcome in Intracerebral Hemorrhage. *Stroke.* 1995. p. 21–4.
5. Fogelholm R, Avikainen S, Murros K. Prognostic value and determinants of first-day mean arterial pressure in spontaneous supratentorial intracerebral hemorrhage. *Stroke.* 1997;28:1396–400.
6. Vemmos KN, Tsivgoulis G, Spengos K, Zakopoulos N, Synetos A, Manios E, et al. U-shaped relationship between mortality and admission blood pressure in patients with acute stroke. *J Intern Med.* 2004;255:257–65.
7. Ohwaki K, Yano E, Nagashima H, Hirata M. Blood Pressure Management in Acute Intracerebral Hemorrhage Relationship Between Elevated Blood pressure and hematoma enlargement. *Stroke.* 2004;35:1364-7.
8. Kazui S, Minematsu K, Yamamoto H, Sawada T, Yamaguchi T. Predisposing factors to enlargement of spontaneous intracerebral hematoma. *Stroke.* 1997;28:2370–5.
9. Broderick JP, Brott TG, Duldner JE, Tomsick T, Huster G. Volume of intracerebral hemorrhage. A powerful and easy-to-use predictor of 30-day mortality. *Stroke.* 1993;24:987–93.
10. Davis SM, Broderick J, Hennerici M, Brun NC, Dinger MN, Mayer SA, et al. Hematoma growth is a determinant of mortality and poor outcome after intracerebral hemorrhage. *Neurology.* 2006;66:1175–81.
11. Koch S, Romano JG, Forteza A, Otero CM, Rabinstein A. Rapid blood pressure reduction in acute intracerebral hemorrhage: feasibility and safety. *Neurocrit Care.* 2008 Jan;8(3):316–21.
12. Anderson CS, Huang Y, Wang JG, Arima H, Neal B, Peng B, et al. Intensive blood pressure reduction in acute cerebral haemorrhage trial (INTERACT): a randomised pilot trial. *Lancet Neurol.* 2008;7:391–9.

13. Anderson CS, Heeley E, Huang Y, Wang J, Stapf C, Delcourt C, et al. Rapid blood-pressure lowering in patients with acute intracerebral hemorrhage. *N Engl J Med*. 2013;368:2355–65.
14. Qureshi AI. Antihypertensive treatment of acute cerebral hemorrhage. *Crit Care Med*. 2010;38:637–48.
15. Qureshi AI, Palesch YY. Antihypertensive treatment of acute cerebral hemorrhage (ATACH) II: Design, methods, and rationale. *Neurocrit Care*. 2011;15:559–76.
16. Butcher KS, Jeerakathil T, Hill M, Demchuk AM, Dowlatshahi D, Coutts SB, et al. The intracerebral hemorrhage acutely decreasing arterial pressure trial. *Stroke*. 2013;44:620–6.
17. The Intracerebral Hemorrhage Acutely Decreasing Arterial Pressure Trial II (ICHADAPT II). NCT 02281838. www.ClinicalTrials.gov.
18. Mayer SA, Lignelli A, Fink ME, Kessler DB, Thomas CE, Swarup R, et al. Perilesional blood flow and edema formation in acute intracerebral hemorrhage: a SPECT study. *Stroke*. 1998;29:1791–8.
19. Zazulia AR, Diringer MN, Videen TO, Adams RE, Yundt K, Aiyagari V, et al. Hypoperfusion without ischemia surrounding acute intracerebral hemorrhage. *J Cereb Blood Flow Metab*. 2001;21:804–10.
20. Schellinger PD, Fiebich JB, Hoffmann K, Becker K, Orakcioglu B, Kollmar R, et al. Stroke MRI in intracerebral hemorrhage: Is there a perihemorrhagic penumbra? *Stroke*. 2003;34:1674–9.
21. Butcher KS, Baird T, MacGregor L, Desmond P, Tress B, Davis S. Perihematomal edema in primary intracerebral hemorrhage is plasma derived. *Stroke*. 2004;35:1879–85.
22. Powers WJ, Zazulia a. R, Videen TO, Adams RE, Yundt KD, Aiyagari V, et al. Autoregulation of cerebral blood flow surrounding acute (6 to 22 hours) intracerebral hemorrhage. *Neurology*. 2001 Jul 10;57(1):18–24.
22. Astrup J, Siesjo BK SL. Thresholds in Cerebral Ischemia - the Ischemic Penumbra. *Stroke*. 1981 [cited 2014 Oct 16]. p. 723–5.
24. Gould B, McCourt R, Gioia LC, Kate M, Hill MD, Asdaghi N, et al. Acute blood pressure reduction in patients with intracerebral hemorrhage does not result in borderzone region hypoperfusion. *Stroke*. 2014 Oct;45(10):2894–9.
25. Gould B, McCourt R, Asdaghi N, Dowlatshahi D, Jeerakathil T, Kate M, et al. Autoregulation of cerebral blood flow is preserved in primary intracerebral hemorrhage. *Stroke*. 2013 Jun;44(6):1726–8.
26. Kate MP, Hansen MB, Mouridsen K, Ostergaard L, Choi V, Gould BE, et al. Blood pressure reduction does not reduce perihematoma oxygenation: a CT perfusion study. *J Cereb Blood Flow Metab*. 2014;34:81–6.
27. McCourt R, Gould B, Gioia L, Kate M, Coutts SB, Dowlatshahi D, et al. Cerebral perfusion and blood pressure do not affect perihematoma edema growth in acute intracerebral hemorrhage. *Stroke*. 2014;45:1292–8.

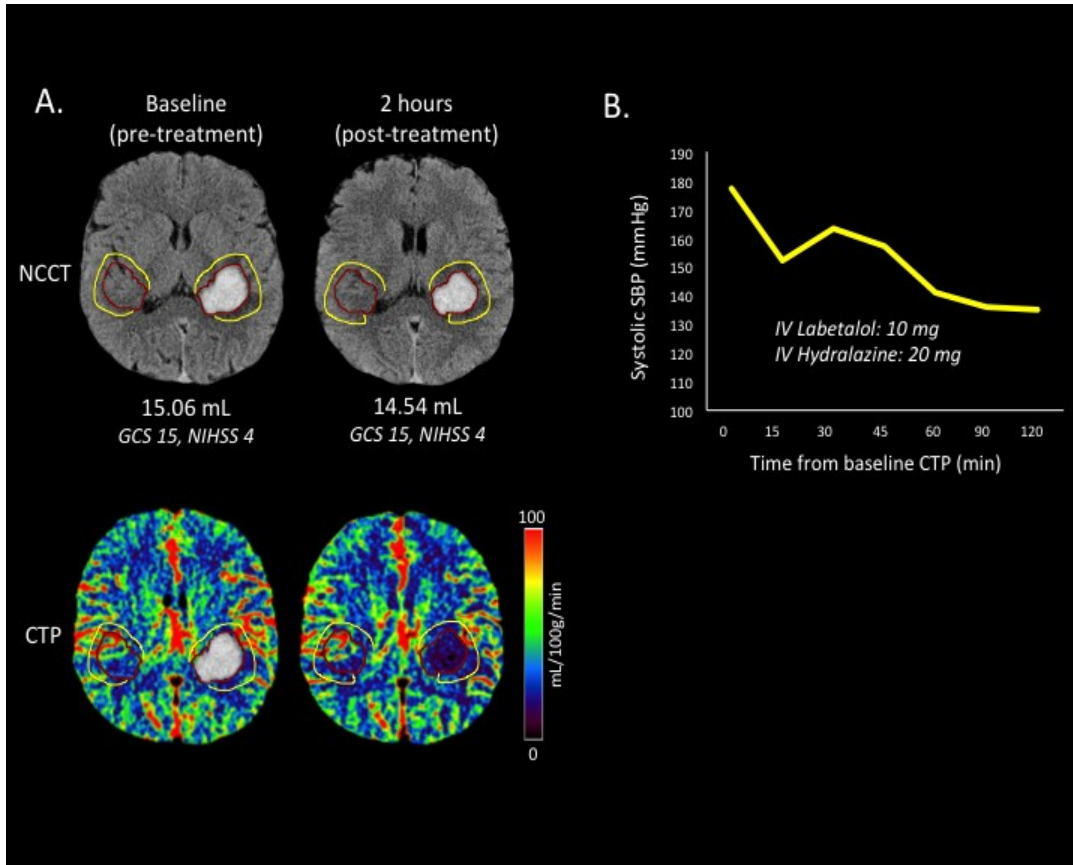
28. Jusufovic M, Sandset EC, Bath PMW, Berge E. Blood Pressure-Lowering Treatment With Candesartan in Patients With Acute Hemorrhagic Stroke. *Stroke*. 2014 Sep 25;
29. Arima H, Anderson CS, Wang JG, Huang Y, Heeley E, Neal B, et al. Lower treatment blood pressure is associated with greatest reduction in hematoma growth after acute intracerebral hemorrhage. *Hypertension*. 2010;56:852–8.
30. Delcourt C, Huang Y, Wang J, Heeley E, Lindley R, Stapf C, et al. The second (main) phase of an open, randomised, multicentre study to investigate the effectiveness of an intensive blood pressure reduction in acute cerebral haemorrhage trial (INTERACT2). *Int J Stroke*. 2010 Apr;5(2):110–6.
31. Brott T, Broderick J, Kothari R, Barsan W, Tomsick T, Sauerbeck L, et al. Early hemorrhage growth in patients with intracerebral hemorrhage. *Stroke*. 1997 Jan;28(1):1–5.
32. Wada R, Aviv RI, Fox AJ, Sahlas DJ, Gladstone DJ, Tomlinson G, et al. CT angiography “spot sign” predicts hematoma expansion in acute intracerebral hemorrhage. *Stroke*. 2007 Apr;38(4):1257–62.
33. Demchuk AM, Dowlatshahi D, Rodriguez-Luna D, Molina CA, Blas YS, Dzialowski I, et al. Prediction of haematoma growth and outcome in patients with intracerebral haemorrhage using the CT-angiography spot sign (PREDICT): A prospective observational study. *Lancet Neurol*. 2012;11:307–14.
34. Dowlatshahi D, Smith EE, Flaherty ML, Ali M, Lyden P, Demchuk AM. Small intracerebral haemorrhages are associated with less haematoma expansion and better outcomes. *Int J Stroke*. 2011;6:201–6.
35. Okumura K, Ohya Y, Maehara A, Wakugami K, Iseki K, Takishita S. Effects of blood pressure levels on case fatality after acute stroke. *J Hypertens* 2005;23:1217-23.
36. Stapf C, Heeley E, Delcourt C, Arima H, Chalmers J, Anderson CS. Abstract 180: The Relation of Timing and Degree of Blood Pressure Control with Hematoma Growth - Secondary Analysis of The Interact2 Trial. *Stroke*. 2014 Feb 1;45(Suppl_1):A180–.
37. Tsivgoulis G, Katsanos AH, Butcher KS, Boviatsis E, Triantafyllou N, Rizos I, et al. Intensive blood pressure reduction in acute intracerebral hemorrhage: A meta-analysis. *Neurology*. 2014 Sep 19;83(17):1523–9.
38. Qureshi AI, Palesch YY, Martin R, Novitzke J, Cruz-Flores S, Ehtisham A, et al. Effect of systolic blood pressure reduction on hematoma expansion, perihematomal edema, and 3-month outcome among patients with intracerebral hemorrhage: results from the antihypertensive treatment of acute cerebral hemorrhage study. *Arch Neurol*. 2010 May;67(5):570–6.
39. Saver JL, Eckstein M, Stratton S, Pratt F, Hamilton S, Conwit R, et al. Abstract 214: The Field Administration of Stroke Therapy - Magnesium (FAST-MAG) Phase 3 Trial: Primary Results. *Stroke*. 2014 Feb 1;45(Suppl_1):A214–.

40. Ankolekar S, Fuller M, Cross I, Renton C, Cox P, Sprigg N, et al. Feasibility of an ambulance-based stroke trial, and safety of glyceryl trinitrate in ultra-acute stroke: the rapid intervention with glyceryl trinitrate in Hypertensive Stroke Trial (RIGHT, ISRCTN66434824). *Stroke*. 2013 Nov;44(11):3120–8.
41. Field Administration of Stroke Therapy-Blood Pressure Lowering (FAST-BP). NCT 01811693. www.ClinicalTrials.gov.
42. Garg RK, Liebling SM, Maas MB, Nemeth AJ, Russell EJ, Naidech AM. Blood pressure reduction, decreased diffusion on MRI, and outcomes after intracerebral hemorrhage. *Stroke*. 2012;43:67–71.
43. Menon RS, Burgess RE, Wing JJ, Gibbons MC, Shara NM, Fernandez S, et al. Predictors of highly prevalent brain ischemia in intracerebral hemorrhage. *Ann Neurol*. 2012;71:199–205.
44. Gregoire SM, Charidimou A, Gadapa N, Dolan E, Antoun N, Peeters A, et al. Acute ischaemic brain lesions in intracerebral haemorrhage: multicentre cross-sectional magnetic resonance imaging study. *Brain*. 2011;134:2376–86.
45. Kimberly WT, Gilson A, Rost NS, Rosand J, Viswanathan A, Smith EE, et al. Silent ischemic infarcts are associated with hemorrhage burden in cerebral amyloid angiopathy. *Neurology*. 2009;72:1230–5.
46. Prabhakaran S, Gupta R, Ouyang B, John S, Temes RE, Mohammad Y, et al. Acute brain infarcts after spontaneous intracerebral hemorrhage: a diffusion-weighted imaging study. *Stroke*. 2010;41:89–94.
47. Kang DW, Han MK, Kim HJ, Yun SC, Jeon SB, Bae HJ, et al. New ischemic lesions coexisting with acute intracerebral hemorrhage. *Neurology*. 2012;79:848–55.
48. Gioia LC, Choi V, Kate M, Emery D, Butcher K. Abstract W P258: Magnitude of Acute Blood Pressure Decrease Does Not Predict the Presence of Diffusion-Restricted Lesions in Patients With Intracerebral Hemorrhage. *Stroke*. 2014 Feb 1;45(Suppl_1):AWP258–.

Table 1.1 Prospective clinical trials of BP reduction in Intracerebral Hemorrhage.

Trial	N	Study design	SBP targets (mmHg)	Time ICH onset to randomization	Intravenous Antihypertensive Agent studied	Mean SBP at 1 hour	Primary endpoint
<i>Trials with Clinical Endpoints</i>							
Koch et al. 2008 (11)	42	RCT, PROBE, phase II	Standard: MAP 110-130 Aggressive: MAP <110	≤8 hours -mean 3.2 hours -86% <6 hours	Variable	S: MAP 123 mmHg A: MAP 114 mmHg (0-3h MAP reported)	Neurological deterioration at 48 hours
INTERACT 2008 (12)	404	RCT, phase II	Standard: <180 Intensive: <140	-≤6 hours -median 3.4 hours	Variable	S: 167 mmHg I: 153 mmHg	24-hour hematoma growth
INTERACT 2 2013 (13)	2,839	RCT, phase III (PROBE)	Standard: <180 Intensive: <140	-≤6 hours -median 3.7 hours	Variable	S: 164 mmHg I: 150 mmHg	mRS @90 days
ATACH 2010 (14)	60	RCT, phase II	Tier 1: <170-200 Tier 2: <140-170 Tier 3: <110-140	-≤6 hours -mean 4 hours	Nicardipine	Tier 1: 200 mmHg Tier 2: 173 mmHg Tier 3: 160 mmHg	Treatment feasibility and safety
ATACH II 2013- (15)	1,200 (target)	RCT, (PROBE) phase III	Standard: <180 Aggressive: <140	-≤4.5 hours (ongoing)	Nicardipine	n/a	mRS at 90 days
<i>Trials with Imaging Endpoints</i>							
ICH ADAPT 2013 (16)	75	RCT, (PROBE) phase II	Standard: <180 Aggressive: <150	- ≤24 hours - median 8 hours - 46% <6 hours	Labetalol Hydralazine Enalapril	S: 164 mmHg A: 150 mmHg	Perihematoma CBF
ICH ADAPT II (17) 2013-	300 (target)	RCT, PROBE phase II	Standard: <180 Aggressive: <140	-≤6 hours (ongoing)	Labetalol Hydralazine Enalapril	n/a	DWI lesion frequency at 48 hours

Figure 1.



A, Examples of hematoma and perihematoma edema regions of interest (ROI) on non-contrast CT images and cerebral blood flow (CBF) maps before and after blood pressure (BP) treatment. The ROIs were drawn on the non-contrast CT and transferred to perfusion maps. B, Time course of systolic BP (SBP) reduction from baseline CT perfusion (CTP).

CHAPTER 2.

Ischemia In Intracerebral Hemorrhage Is Associated With Leukoaraiosis And Hematoma Volume, Not Blood Pressure Reduction

(published in Stroke, 2015, vol. 46, issue 6, page 1541-1547.)

Introduction

Primary intracerebral hemorrhage (ICH) is associated with high morbidity and mortality. Baseline hematoma volume¹, hematoma expansion², and high blood pressure³ are associated with poor outcome. The Intensive Reduction of Blood Pressure Reduction in Acute Cerebral Hemorrhage Trials (INTERACT and INTERACT II) have shown that aggressive blood pressure (BP) reduction (<140 mmHg) in ICH is associated with decreased hematoma growth at 24 hours and better functional outcomes.^{4,5} Despite this, the possibility of ischemic injury, both within the perihematoma region and remote from the hematoma remains a concern. Although few cases of clinically evident ischemic stroke were seen in either INTERACT trial, several MRI studies indicate subacute ischemic injury after ICH is relatively common.⁶⁻¹¹

The primary aim of this study was to identify the frequency of perihematoma and remote MRI ischemic lesions in primary ICH patients. We also aimed to determine whether acute BP change over the first 24 hours was associated with ischemic injury. We tested the hypotheses that larger ICH volumes and blood pressure (BP) reduction are associated with DWI lesions.

Methods

Patients

We conducted a retrospective analysis of all patients admitted to the University of Alberta Hospital between January 2007 and June 2014. Patients with primary ICH and who underwent MR imaging (MRI) including DWI sequences ≤ 14 days from symptom onset were included. All known or suspected causes of secondary ICH such as vascular malformations, structural lesions, trauma, or hemorrhagic transformation of an ischemic infarct were excluded. The research protocol was approved for waiver of consent by our local Human Research Ethics Board.

Blood Pressure Analyses

Clinical data and BP data (systolic (SBP)/diastolic (DBP)/mean arterial pressure (MAP) at baseline/1/2/6/12/24 hours) were collected by chart review. The maximal SBP drop in 24 hours was calculated as admission SBP minus nadir SBP within the first 24 hours. The weighted average BP was calculated as the area under the curve of systolic, diastolic, and mean arterial BP over 24 hours¹².

Imaging Analyses

All available neuroimaging, including CT, MRI and vascular studies were reviewed. Patients were imaged using either a single or 8-channel phased array radiofrequency head coil on a 1.5-T whole-body Siemens Sonata MRI scanner. The MRI protocol consisted of axial T1 and T2-weighted images, gradient recalled echo (GRE) or susceptibility-weighted imaging (SWI), Fluid-Attenuated Inversion Recovery (FLAIR), and DWI

sequences. Single shot Echoplanar (EPI) DWI images were obtained using diffusion gradient strengths (b values) between 0 s/mm², equivalent to a T2-weighted image, and 1000 s/mm², applied in 3 orthogonal planes. These were combined to form isotropic (trace) diffusion images and Apparent Diffusion Coefficient (ADC) maps were generated from these raw data. DWI acquisition parameters were: repetition time (TR) of 3 s, spin echo time (TE) of 86 ms, 8 averages, 128x128 matrix base resolution zero filled to 256x256, 22 cm field-of-view, and 1396 Hz/pixel acquisition bandwidth. The entire brain will be imaged using 19-24 contiguous axial slices each 5 mm in thickness, with a 1.5 mm inter-slice gap.

All planimetric analyses were performed using Analyze 11.0 (Biomedical Imaging Resource, Mayo Clinic, Rochester, NY).¹³ Hematoma volumes were measured on non-contrast CT scan images using semi-automatic threshold-based segmentation techniques. The boundaries of the hematoma and perihematoma edema regions on MRI were outlined manually, based on consensus between three authors (LCG, MK, KB), on baseline DWI (b=0; no diffusion gradients applied) images as described previously.¹⁴ Region-of interest (ROI) object maps were co-registered to ADC maps to obtain the absolute ADC values within the perihematoma edematous region. Perihematoma edema volumes were calculated as the tissue volume with an ADC >965 X 10⁻⁶mm²/s within the visibly edematous region. This threshold was based on the mean and standard deviation (SD) of the ADC within the edematous region reported previously,¹⁴ as well as the reported upper ADC of normal appearing white matter (960 X 10⁻⁶ mm²/s).¹⁵⁻¹⁷ Relative ADC was calculated as the ratio of the absolute perihematoma ADC to that in contralateral homologous regions. ADC thresholds for moderate ischemia (730 X 10⁻⁶

6 mm/s), and severe ischemia (550×10^{-6} mm/s) were applied within the visibly edematous perihematoma region as described previously.¹⁸ Areas with high signal on DWI (b=1000) images and corresponding low ADC both within the perihematoma region and remote from the hematoma were manually outlined.

Cerebral microbleeds were counted using either GRE or SWI sequences (whichever was available) and classified by anatomic location (lobar/deep/infratentorial) according to the BOMBS scale.¹⁹ The presence of any previous ICH identified on GRE/SWI (whether symptomatic or not) was also recorded. Leukoariosis was identified as hyperintensities on FLAIR sequences and leukoariosis volumes were measured using semi-automatic thresholding segmentation techniques. Leukoariosis severity was graded according to the Fazekas scale.²⁰

Statistical analyses

All statistical analyses were performed using the Statistical Package for Social Sciences version 21.0.0 (IBM SPSS Statistics Inc, 2013, Armonk, NY, USA). Differences in baseline patient characteristics and imaging data between patients with and without DWI lesions were assessed using independent t-tests or Mann-Whitney tests, for parametric and non-parametric data respectively. Pearson Chi-square or Fisher's exact tests were used to compare the frequencies of clinical and imaging characteristics between patients with and without DWI lesions. Spearman's rank correlations test was used to assess the correlation between perihematoma tissue volumes reaching ischemic thresholds and hematoma volumes. Volume data were subsequently log-transformed for univariate and multivariate linear regression analyses. Inter-rater reliability was estimated

using intra-class correlation coefficients (ICC) between two raters for hematoma and leukoariaosis volumes.

Results

One hundred and seventeen patients met the inclusion criteria. Sixty-two patients with primary ICH and MR imaging were excluded from analyses due to MRI performed without DWI sequences (n=47), MRI performed >14 days after onset (n=14), or decompressive hemicraniectomy performed prior to MRI (n=1). The mean age was 65.6±13.0 years, and 52.1% of patients were male. The median (IQR) GCS score was 15 (14-15) and the median NIHSS score was 5 (2-11). Sixty-five percent of patients had a previous history of hypertension (44.4% were taking antihypertensive therapy), 4.3% had a previous ischemic stroke, and 5.1% had a previous ICH. The ICH was associated with antiplatelet or anticoagulant use in 24.8% and 8.5% of patients respectively.

Forty-four percent of bleeds were lobar in location, 41.0% were deep, and 15.4% were infratentorial. Hypertension was the most common cause of ICH (45.7%), probable/possible amyloid angiopathy was considered to be the cause in 11 (9.4%) patients. A total of 10 (8.5%) of cases were considered to be anticoagulant-associated ICH. The cause of ICH was unknown in 36.4% of patients. The median hematoma volume, measured on CT scan, was 9.8 (2.6-23.0) ml (range 0.5-113.8mL). Inter-rater agreement for hematoma volumes was excellent (ICC 0.96). The median time to diagnostic CT scan was 2.8 (1.5-7.8) hours.

Perihematoma DWI Lesions

The median (IQR) time to MRI was 2 (1-5) days. The median perihematoma edema volume was 7.0 (2.9-18.6) ml with a mean absolute ADC value of $1260 \pm 117.3 \times 10^{-6} \text{mm}^2/\text{s}$. The mean relative ADC (rADC) value was 1.47 ± 0.18 and perihematoma rADC values were ≥ 1.1 in all patients.

The median (IQR) volume of tissue below the threshold for moderate ischemia was 0.7 (0.3-2.0) ml, which represented 8.0 (2.9-14.5)% of tissue within the perihematoma edematous region. The median volume of perihematoma tissue reaching severe ischemic thresholds was 0.13 (0.04-0.5) ml (1.1 (0.3-3.5)%). Focal areas of diffusion restriction within the perihematoma region were visible in 38 patients (32.4%), with a median volume of 1.3 (0.5-4.0) ml. The mean ADC in this tissue was $630.5 \pm 76.0 \times 10^{-6} \text{mm}^2/\text{s}$ (Figure 1). The volume of visually apparent perihematoma DWI lesions was directly correlated with the volume of tissue reaching both moderate ($R=0.72, p<0.001$) and severe ($R=0.80, p<0.001$) ischemic thresholds.

Patients with perihematoma DWI lesions had higher baseline NIHSS scores, larger hematoma and perihematoma edema volumes, as well as higher rates of subarachnoid extension than those who did not (Table 1). Both hematoma and perihematoma volumes reaching ischemic thresholds were log-transformed for further analyses. The volume of perihematoma tissue with ADC below the thresholds for both moderate ($R=0.53, \beta=0.62, p<0.001$) and severe ischemia ($R=0.56, \beta=0.69, p<0.001$) was correlated with hematoma volumes (Figure 2). The total volume of visible DWI lesions was also correlated with hematoma volume ($R=0.54, \beta=0.54, p<0.001$). In a multivariable linear regression model adjusting for age, baseline NIHSS scores, and perihematoma

edema volumes, hematoma volume remained the only independent predictor of perihematoma tissue volume reaching moderate ($R=0.59, \beta=0.60, p<0.001$) and severe ischemic thresholds ($R=0.66, \beta=0.94, p<0.001$).

Remote DWI Lesions

A total of 42 DWI lesions remote from the hematoma/perihematoma region were found in 17 patients (range 1-6 lesions/patient; 14.5% prevalence). The mean volume of remote DWI lesions was 0.44 ± 0.3 ml. Fifty percent of remote DWI lesions were cortical in location, while the remainder were subcortical except for 1 infratentorial lesion. Remote DWI lesions in 11 patients (66%) were located in the hemisphere contralateral to the hematoma. Three patients with DWI lesions underwent cerebral angiography prior to MRI and were excluded from further analyses.

Baseline clinical characteristics were similar between patients with and without remote DWI lesions, with the exception of higher rates of antiplatelet and antihypertensive drug use in patients with remote DWI lesions (Table 2). A history of prior ICH was also more common in patients with DWI lesions. There was a trend to larger hematoma volumes in patients with remote DWI lesions (16.2 (5.1-65.5) ml) relative to those without (8.6 (2.5-22.0) ml, $p=0.06$). Lobar ICH location was also more frequent in patients with remote DWI lesions (71.4%) compared to those without (41%, $p=0.03$).

The median leukoariosis volume was 6.8 (1.5-17.8) ml in all patients. Inter-rater agreement for leukoariosis volumes was excellent (ICC 0.99). Median leukoariosis (LA) volumes were larger in patients with remote DWI lesions (17.4 (9.6-46.5) ml vs. 5.3 (0.5-

16.9) ml ($p=0.02$)). Microbleed burden ($p=0.76$) and microbleed location ($p=0.55$) did not differ between patients with and without remote DWI lesions.

Blood Pressure Treatment and DWI Lesion Development

BP data were available in 103/117 patients (88.0%). Fourteen patients were excluded from BP analysis due to late hospital arrival (symptom onset or last time seen well ≥ 24 hours; $n=10$), or transfer from another hospital without accompanying BP documentation ($n=4$). All patients with remote DWI lesions, and 34 of 38 patients (89.5%) with perihematoma DWI lesions had available 24-hour BP data.

Mean admission SBP was similar in patients with (166.7 ± 30.9 mmHg) and without DWI lesions in any location (161.1 ± 30.3 mmHg, $p=0.36$; Figure 3A). The median maximal SBP drop at any time point during the first 24 hours relative to admission BP did not differ between patients with (-29 (-54 , -15) mmHg) and without perihematoma DWI lesions (-26.5 (-46 , -9) mmHg, $p=0.33$) or between patients with (-20.5 (-55 , -10) mmHg) and without remote DWI lesions (-27 (-46 , -13) mmHg, $p=0.96$). The median SBP drop at all time points relative to admission BP did not differ across patient groups (Figure 3B). The volume of perihematoma tissue reaching ischemic thresholds was not correlated with the maximal SBP drop at 24 hours ($R=-0.1$, $p=0.38$)(Figure 3C). Weighted average BPs over the first 6 hours and 24 hours were similar in patients with and without DWI lesions(Figure 3D). Rates of intravenous (IV) antihypertensive drug administration were not different between patients with/without perihematoma (38.8% vs. 31.6%, $p=0.24$) or remote DWI lesions (35.7% vs. 32%, $p=0.30$).

Discussion

In a large sample of patients with primary ICH using objective ADC thresholds, we showed that small volumes of tissue reaching moderate and severe ischemic thresholds are present both within and outside the perihematoma region. Perihematoma DWI lesions were independently predicted by larger ICH volumes. DWI lesions remote from the perihematoma region were associated with higher leukoaraiosis volumes, prior antiplatelet and antihypertensive use, prior ICH, and lobar ICH location. We found no relationship between any measure of BP reduction during the first 24 hours and DWI lesion development in any location.

Our study is consistent with previous studies describing perihematoma diffusion restriction after ICH. Limited areas of bioenergetic compromise within the perihematoma region have been described in 22-61% of patients within the first 6 hours of ICH.¹⁶⁻¹⁸ However, these studies had relatively small sample sizes (n=12-32) and sometimes included ICH with secondary etiologies, including hemorrhagic transformation of ischemic stroke and vascular malformations. Our results confirm that although the perihematoma region consists primarily of tissue with elevated ADC values, consistent with vasogenic edema, a small amount of perihematoma tissue reaching ischemic ADC thresholds is present. Furthermore, the probability of diffusion restriction is strongly correlated with hematoma volume.

It is unknown if perihematoma diffusion restriction represents true ischemic injury, presumably related to microvascular compromise, or bioenergetic compromise secondary to mechanical compression of the tissue, and/or neurotoxicity related to hematoma formation and/or degradation.²¹ Certainly, the correlation between hematoma

volume and diffusion restriction is compatible with all three of these hypotheses. The ischemic hypothesis is most relevant to patient management, due to the implications for BP treatment.

In our study, we found no relationship between baseline BP, change in BP or control of BP over the initial 24 hours and the subsequent development of perihematoma DWI lesions. This is consistent with the results of a recent randomized controlled trial of 2 BP treatment targets demonstrating that perihematoma hypoperfusion is not exacerbated by acute BP reduction.²² Nonetheless, we cannot exclude the possibility that perihematoma DWI lesions are related to aggressive BP reduction. One potential implication may be that larger hematomas should be treated more conservatively with respect to BP reduction, but this requires verification in larger clinical studies.

More recent MRI studies have raised concerns related to sub-acute ischemic injury in regions remote from the hematoma.⁶⁻¹¹ Among various variables shown to be associated with DWI lesions, the most concerning is the association with BP lowering.^{6, 7, 11} Garg et al completed a relatively large study (n=95), where remote DWI lesions were seen in 41% of patients. They showed that patients with DWI lesions had a greater mean decrease from baseline BP values within 96 hours from symptom onset.¹¹ In our study, we did not find an association between remote DWI lesions and any measure of BP change or control over the first 24 hours. This may be related to the relatively modest decrease in BP over 24 hours in our patients. Given that admission SBP was below the current guideline-recommended target for BP reduction (<180 mmHg) in a significant proportion of patients in our study, it is possible that some patients were less likely to receive aggressive BP treatment. We have previously shown that BP targets are rarely

achieved in a timely fashion in patients treated outside of clinical trials.²³ Indeed, we found median SBP changes over 24 hours ranged from -5 to -35 mmHg, in contrast to the more precipitous drop (-55 to -70 mmHg) seen in patients with DWI lesions in Garg et al. Thus, it is possible that a larger decline in SBP is associated with higher rates of acute DWI lesion formation. Two other studies reported an association between MAP decline >40% and DWI lesion formation.^{6,7} However, these results were based on BP values obtained at few time-points (baseline, lowest to highest values before MRI, and BP at one month), and therefore may not reflect true BP control during the acute phase of ICH. In our study, we included several time-points within the first 24 hours after ICH, a period where BP change is the most dramatic. Furthermore, we attempted to assess global BP control over 24 hours by assessing the weighted average BP over 24 hours.

Nonetheless, the relationship between BP reduction and DWI lesion formation can only be effectively addressed using a randomized trial design and an MRI endpoint. In addition to differences in DWI lesion frequency with respect to BP targets, it may be of interest to analyze the relationship between the likelihood of DWI lesion development and the magnitude of BP drop over time in ongoing and future trials.

The etiology of remote DWI lesions in sub-acute ICH remains unknown. We found correlations between remote DWI lesion and previous antiplatelet use, antihypertensive use and leukoaraiosis volumes, which is consistent with previous investigations.^{8,9} These findings suggest that an underlying microangiopathy may play a role in DWI lesion formation in ICH. An ischemic “stroke-prone” prothrombotic state in ICH has been previously hypothesized.²⁴ Anti-platelet withdrawal at the time of ICH presentation may contribute to remote DWI lesion formation, particularly in the presence

of an underlying vasculopathy.

The fact that patients with remote DWI lesions had higher rates of prior ICH and lobar ICH location also raises the possibility that these are related to amyloid angiopathy. Indeed, previous studies have demonstrated an association between DWI lesions and cerebral microbleed burden.^{8, 10} Although we did not find an association between DWI lesions and cerebral microbleeds, our relatively small study with heterogenous T2* imaging for microbleed detection (SWI and GRE) certainly does not exclude a relationship between the two.

Finally, we did observe potential embolic sources in several patients with remote DWI lesions. Three patients with remote DWI lesions underwent cerebral angiography prior to MRI. Distal embolization is a known complication of cerebral angiography, which is often included in the etiological workup of ICH. Although such patients were excluded from our predictive modelling analyses, they are part of the spectrum of etiologies which may be associated with DWI lesion formation in ICH.

Cardioembolic sources of DWI lesion formation are also possible in ICH. In our study, we observed a trend between a diagnosis of atrial fibrillation and remote DWI lesions. Given that paroxysmal atrial fibrillation is found in approximately 25% of patients >85 years of age and oral anticoagulation is sometimes associated with ICH, including 8.5% of our patients, a cardioembolic source is a plausible mechanism of DWI lesion development in at least some ICH patients. Hence, all potential sources of embolization need to be considered in ICH patients with DWI lesions.

Due to its retrospective design, selection bias is possible in our patient population. Indeed, there is a higher than expected proportion of lobar ICH in our sample, reflecting

the fact these patients are more likely to undergo MR imaging to rule out a secondary cause of ICH. Similarly, patients with early declaration of poor prognosis and withdrawal of care were systematically excluded from our study. It is possible that perihematoma and remote DWI lesions are even more common in these patients, most of whom would have larger hematoma volumes. Furthermore, BP analysis was limited to the clinical data recorded, and ideally, shorter intervals between BP measurements would better represent BP changes in the first 24 hours. Nevertheless, our study included more time points in the acute phase of ICH than previous studies. Finally, it is possible that variable time to MRI may have resulted in an underestimation of the frequency of remote and perihematoma DWI lesions, particularly at later imaging time points (>7 days), as most DWI lesions are small and may not result in visible permanent T2/FLAIR lesions once they resolve.

Conclusion

Small ischemic lesions are common in the perihematoma region and remote from the hematoma in patients with primary ICH. DWI lesion formation in ICH appears to be multifactorial, including the effects of the hematoma itself, the presence of an underlying microangiopathy (hypertensive and/or amyloid), or possibly sources of distal embolization. We could find no relationship between BP reduction in the first 24 hours and DWI lesion formation in any location. These data do not support a hemodynamic etiology of DWI lesion development. Nonetheless, a randomized study with an MR imaging endpoint will be needed to definitively determine if BP reduction is causally related to ischemic lesion development after ICH.

References

1. Broderick JP, Brott TG, Duldner JE, Tomsick T, Huster G. Volume of intracerebral hemorrhage. A powerful and easy-to-use predictor of 30-day mortality. *Stroke*. 1993;24:987-993.
2. Davis SM, Broderick J, Hennerici M, Brun NC, Diringer MN, Mayer SA et al. Hematoma growth is a determinant of mortality and poor outcome after intracerebral hemorrhage. *Neurology*. 2006;66:1175-1181.
3. Willmot M, Leonardi-Bee J, Bath PM. High blood pressure in acute stroke and subsequent outcome: A systematic review. *Hypertension*. 2004;43:18-24.
4. Anderson CS, Huang Y, Wang JG, Arima H, Neal B, Peng B et al. Intensive blood pressure reduction in acute cerebral haemorrhage trial (INTERACT): A randomised pilot trial. *Lancet Neurol*. 2008;7:391-399.
5. Anderson CS, Heeley E, Huang Y, Wang J, Stapf C, Delcourt C, et al. Rapid blood-pressure lowering in patients with acute intracerebral hemorrhage. *N Engl J Med*. 2013;368:2355-2365.
6. Prabhakaran S, Gupta R, Ouyang B, John S, Temes RE, Mohammad Y, et al. Acute brain infarcts after spontaneous intracerebral hemorrhage: A Diffusion-Weighted imaging study. *Stroke*. 2010;41:89-94.
7. Menon RS, Burgess RE, Wing JJ, Gibbons MC, Shara NM, Fernandez S, et al. Predictors of highly prevalent brain ischemia in intracerebral hemorrhage. *Ann Neurol*. 2012;71:199-205.
8. Kang DW, Han MK, Kim HJ, Yun SC, Jeon SB, Bae HJ, et al. New ischemic lesions coexisting with acute intracerebral hemorrhage. *Neurology*. 2012;79:848-855.
9. Gregoire SM, Charidimou A, Gadapa N, Dolan E, Antoun N, Peeters A, et al. Acute ischaemic brain lesions in intracerebral haemorrhage: Multicentre cross-sectional magnetic resonance imaging study. *Brain*. 2011;134:2376-2386.
10. Kimberly WT, Gilson A, Rost NS, Rosand J, Viswanathan A, Smith EE, et al. Silent ischemic infarcts are associated with hemorrhage burden in cerebral amyloid angiopathy. *Neurology*. 2009;72:1230-1235.
11. Garg RK, Liebling SM, Maas MB, Nemeth AJ, Russell EJ, Naidech AM. Blood pressure reduction, decreased diffusion on mri, and outcomes after intracerebral hemorrhage. *Stroke*. 2012;43:67-71.
12. Aslanyan S, Fazekas F, Weir CJ, Horner S, Lees KR; for the GAIN International Steering Committee and Investigators. Effect of blood pressure during the acute period of ischemic stroke on stroke outcome: A tertiary analysis of the gain international trial. *Stroke*. 2003;34:2420-2425.
13. Robb RA. The biomedical imaging resource at Mayo Clinic. *IEEE transactions on medical imaging*. 2001;5:227-233.
14. Butcher KS, Baird T, MacGregor L, Desmond P, Tress B, Davis S. Perihematoma edema in primary intracerebral hemorrhage is plasma derived. *Stroke*. 2004;35:1879-1885.
15. Carhuapoma JR, Wang PY, Beauchamp NJ, Keyl PM, Hanley DF, Barker PB. Diffusion-Weighted MRI and Proton MR Spectroscopic Imaging in the Study of

- Secondary Neuronal Injury After Intracerebral Hemorrhage. *Stroke* 2000;31:726-732.
16. Olivot JM, Mlynash M, Kleinman JT, Straka M, Venkatasubramanian C, Bammer R, et al. MRI profile of the perihematomal region in acute intracerebral hemorrhage. *Stroke*. 2010;41:2681-2683.
 17. Schellinger PD, Fiebach JB, Hoffmann K, Becker K, Orakcioglu B, Kollmar R, et al. Stroke MRI in intracerebral hemorrhage: Is there a perihemorrhagic penumbra? *Stroke*. 2003;34:1674-1679.
 18. Kidwell CS, Saver JL, Mattiello J, Warach S, Liebeskind DS, Starkman S, et al. Diffusion-perfusion mr evaluation of perihematomal injury in hyperacute intracerebral hemorrhage. *Neurology*. 2001;57:1611-1617.
 19. Cordonnier C, Potter GM, Jackson CA, Doubal F, Keir S, Sudlow CL, et al. Improving Interrayer Agreement About Brain Microbleeds: Development of the Brain Observer Microbleed Scale (BOMBS). *Stroke* 2009;40:94-99.
 20. Fazekas F, Barkhof F, Wahlund LO, Pantoni L, Erkinjuntti T, Scheltens P, et al. CT and MRI rating of white matter lesions. *Cerebrovasc Dis* 2002;13 Suppl 2:31-36.
 21. Xi G, Keep RF, Hoff JT. Mechanisms of brain injury after intracerebral haemorrhage. *Lancet Neurology*. 2006;5:53-63.
 22. Butcher KS, Jeerakathil T, Hill M, Demchuk AM, Dowlatshahi D, Coutts SB, et al. The intracerebral hemorrhage acutely decreasing arterial pressure trial. *Stroke*. 2013;44:620-626.
 23. Manawadu D, Jeerakathil T, Roy A, Orwaard-Wong K, Butcher K. Blood pressure management in acute intracerebral haemorrhage guidelines are poorly implemented in clinical practice. *Clin Neurol Neurosurg*. 2010;112:858-864
 24. Prabhakaran S, Naidech AM. Ischemic Brain Injury After Intracerebral Hemorrhage: A Critical Review. *Stroke* 2012;43:2258-2263.

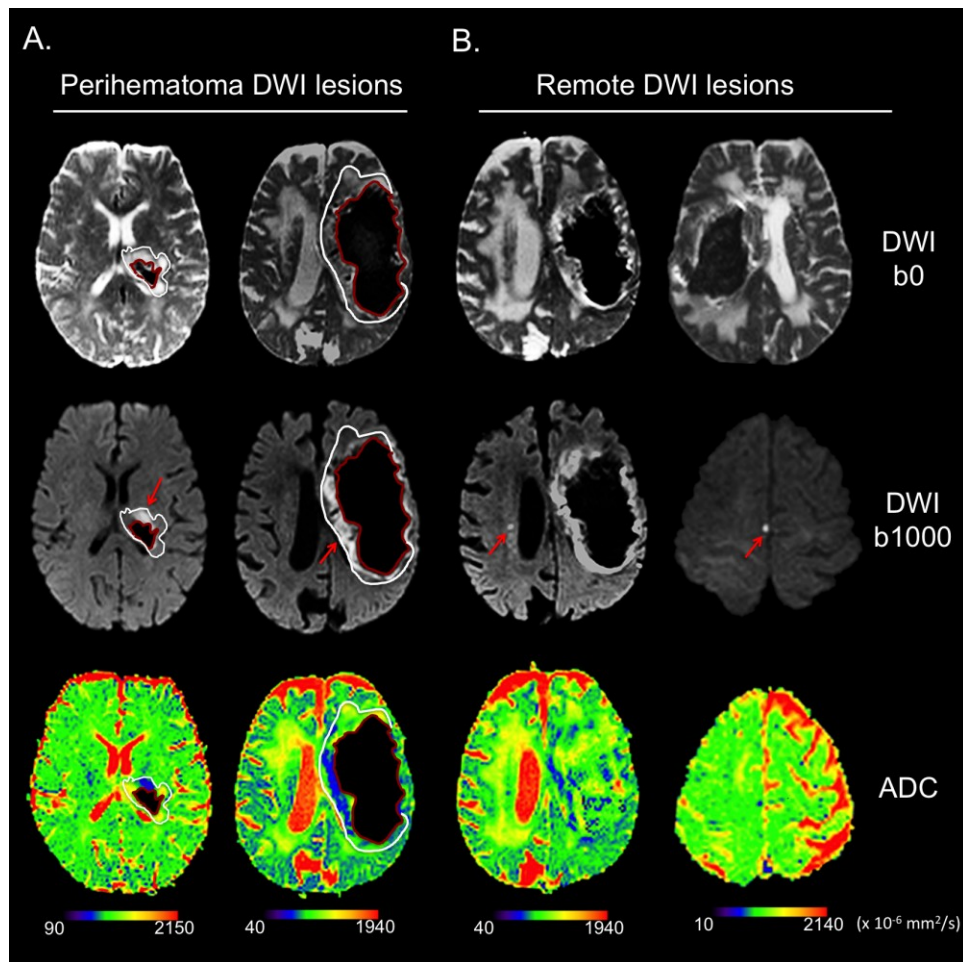
Table 1. Baseline Clinical And Imaging Characteristics And Perihematoma DWI Lesions.

	Perihematoma DWI lesions (n=38)	No perihematoma DWI lesions (n=79)	p-value
Age (mean±SD)	66.9±13.9	65.2±13.3	0.41
Sex (n, %male)	18 (47.3)	43 (54.4)	0.47
Clinical characteristics			
Baseline GCS (median (IQR))	15 (12-15)	15 (14.5-15)	0.12
Baseline NIHSS	7 (4-15)	4 (2-9)	0.045
Hypertension	23 (60.5)	54 (68.3)	0.45
Previous TIA/ischemic stroke	3 (7.9)	8 (10.1)	0.67
Previous ICH	3 (7.9)	3 (3.8)	0.39
Atrial fibrillation	6 (15.7)	8 (10.1)	0.30
Dementia	0	2 (2.5)	1
Antiplatelet use	9 (23.7)	20 (25.3)	0.86
Anticoagulant use	5 (13.2)	5 (6.3)	0.29
Antihypertensive use	15 (39.5)	37 (46.8)	0.49
Statin use	10 (26.3)	20 (25.3)	0.87
Imaging characteristics			
Hematoma volume,ml	23.0 (12.1-49.5)	5.3 (2.1-15.5)	<0.001
Perihematoma edema volume,ml	14.4 (6.3-24.7)	5.7 (2.6-12.7)	0.006
ICH Location			0.27
Lobar	19 (50)	32 (40.5)	
Deep	16 (42.1)	32 (40.5)	
Infratentorial	3 (7.9)	15 (18.9)	
LA volume, ml	5.9 (1.7-16.4)	6.9 (1.5-18.1)	0.82
IVH extension	10 (26.3)	17 (21.5)	0.56
Subarachnoid extension	11 (28.9)	8 (10.1)	0.01
Time to MRI (days)	2.6±2.3	4.0±3.7	0.17

Table 2. Baseline Clinical And Imaging Characteristics And Remote DWI Lesions

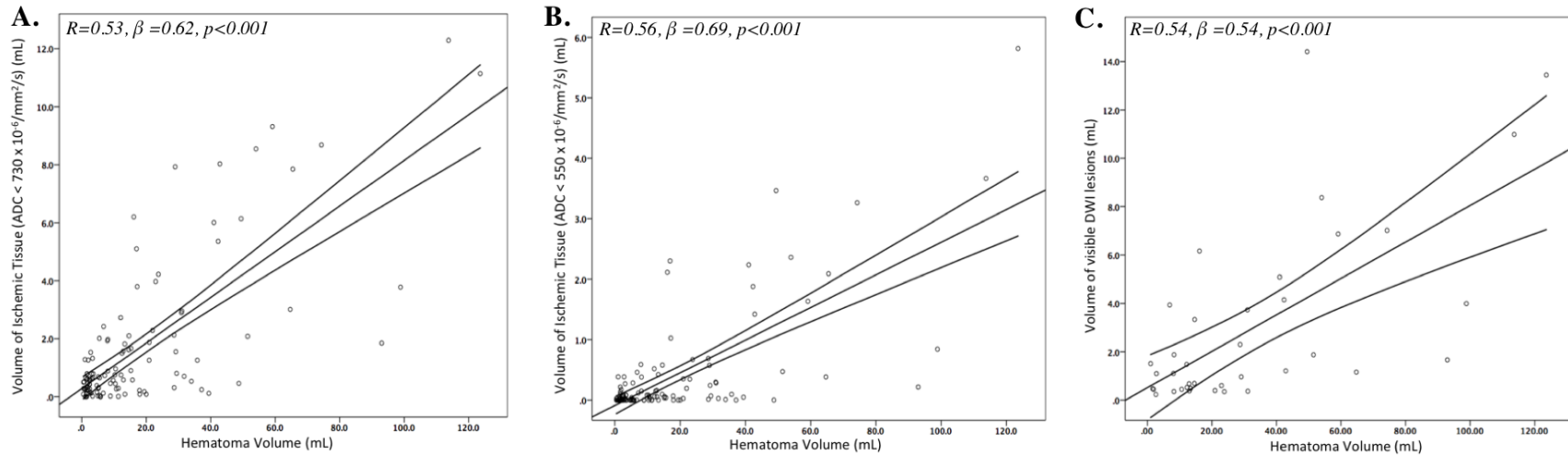
	Remote DWI lesions (n=14)	No remote DWI lesions (n=100)	p-value
Age, years (mean±SD)	69.2±10.8	65.4±14.0	0.36
Sex (n, %male)	9 (64.2)	52 (52)	0.57
Clinical Characteristics			
Baseline GCS (median (IQR))	15 (12-15)	15 (14-15)	0.97
Baseline NIHSS	2 (2-9)	5 (3-11)	0.36
Hypertension (n,%)	12 (85.7)	64 (64)	0.22
Previous TIA/ischemic stroke	2 (14.2)	9 (9)	0.75
Previous ICH	3 (21.4)	3 (3)	0.03
Atrial fibrillation	4 (28.5)	10 (10)	0.08
Antiplatelet use	8 (57.1)	21 (21)	0.01
Anticoagulant use	1 (7.1)	9 (9)	>0.99
Antihypertensive use	10 (71.4)	41 (41)	0.03
Statin use	4 (28.5)	26 (26)	0.75
Imaging Characteristics			
Hematoma volume, ml (median (IQR))	16.2 (5.1-65.5)	8.6 (2.5-22.0)	0.06
Perihem. edema volume, ml	12.5 (7.2-23.8)	6.8 (2.9-17.5)	0.22
Perihematoma ADC (x10 ⁻⁶ mm ² /s)	1326.0±153	1254.8±110	0.13
Perihematoma DWI lesions	6 (47.0)	30 (30)	0.33
ICH Location			0.04
Lobar	10 (71.4)	41 (41.0)	
Deep/infratentorial	4 (28.5)	59 (59)	
LA volume, ml	17.4 (9.6-46.5)	5.3 (0.5-16.9)	0.02
LA, periventricular, Fazekas grade			0.35
0	2 (14.2)	29 (29)	
1	3 (21.4)	32 (32)	
2	6 (42.9)	25 (25)	
3	3 (21.4)	14 (14)	
LA deep white matter, Fazekas grade			0.046
0	1 (7.1)	39 (39)	
1	6 (42.9)	40 (40)	
2	6 (42.9)	16 (16)	
3	1 (7.1)	5 (5)	
IVH extension	5 (35.7)	22 (21.5)	0.24
Subarachnoid extension	3 (21.4)	16 (15.6)	0.59
Time to MRI, days	3.3 ± 3.0	3.6 ± 3.4	0.84

Figure 1.



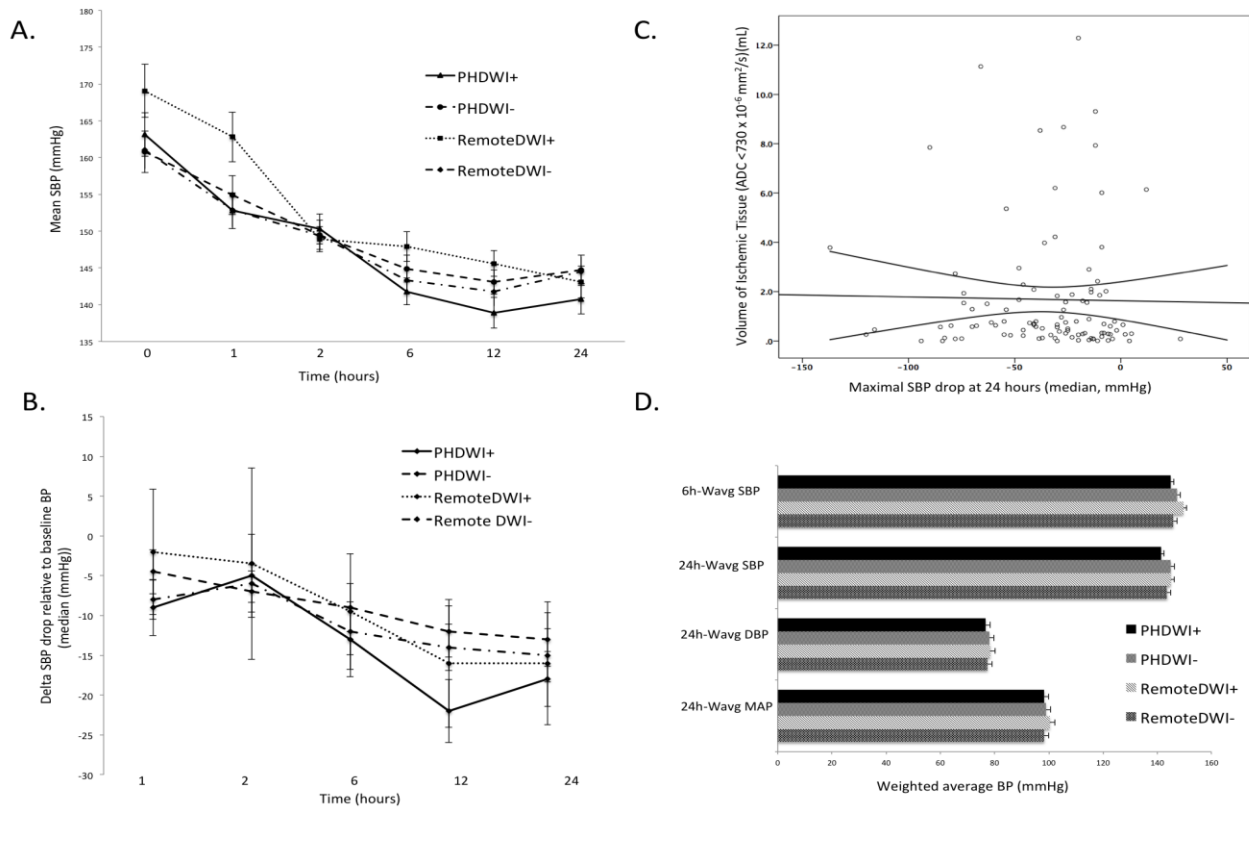
Examples of Diffusion-Weighted Imaging (DWI) lesions in the perihematoma region and more remotely in patients with ICH. A) Perihematoma DWI lesions as seen on DWI b=0 and b=1000 sequences and ADC maps with corresponding regions of interest (red=hematoma boundary/ white=perihematoma edema boundary). High intensity on DWI b=1000 and low ADC values (depicted in blue) represent diffusion restriction. B. Examples of DWI lesions in regions remote to the perihematoma region as seen on DWI b0, b1000, and ADC maps.

Figure 2.



Relationship between perihematoma tissue volumes reaching ischemic thresholds and hematoma volume. A: Correlation between the volume of perihematoma tissue with ADC below the moderate ischemia threshold ($<730 \times 10^{-6} \text{ mm}^2/\text{s}$) and severe ischemia ($<550 \times 10^{-6} \text{ mm}^2/\text{s}$) (B). C: Correlation between the volume of visible DWI lesions and hematoma volume. Correlation coefficients calculated using Spearman rank correlation

Figure 3.



The relationship between BP change over the first 24 hours and DWI lesions. A) Mean SBP values over 24 hours according to presence/absence of perihematoma (PHDWI) or remote DWI lesions. Error bars represent Standard Error. All p-values >0.05. B) The median SBP drop at all time points relative to admission BP across patient groups, all p-values >0.05. C) Scatter plot of the correlation between the volume of perihematoma tissue reaching moderate ischemic thresholds and the maximal SBP drop at 24 hours. D) Weighted average blood pressures over 6 and 24 hours across patient groups. All p-values >0.05

CHAPTER 3.

Analysis Of The Relationship Between Cerebral Blood Flow And Remote DWI Lesions In Patients With Acute Intracerebral Hemorrhage

Introduction

Hyperintensities suggestive of ischemia on diffusion-weighted imaging (DWI) sequences on MRI have been frequently observed (14-40%) in patients with intracerebral hemorrhage (ICH). (1-6) Although many clinical factors have been shown to be associated with DWI lesions in ICH, data is conflicting regarding the relationship between DWI lesion formation and acute BP reduction. Recent randomized controlled trials have shown the safety of acute BP reduction in acute ICH. (7-8) Clinicians remain reluctant, however, to aggressively treat elevated BP in acute ICH for fear of precipitating or exacerbating cerebral hypoperfusion. Studies have shown that cerebral autoregulation is lost in the setting of acute cerebral insults such as ICH, and therefore cerebral blood flow (CBF) is thought to become linearly associated with systemic blood pressure (BP) (9). Accordingly, cerebral hypoperfusion following intensive BP reduction is a plausible mechanism of DWI lesion formation in acute ICH.

Although several perfusion studies have shown that hypoperfusion exists within the perihematoma region (10-13), its nature is debated given evidence that perihematoma hypoperfusion is consistent decreased metabolism rather than ischemia (11). Furthermore, a recent phase II randomized clinical trial of two different BP management strategies on perihematoma CBF in acute ICH showed that while mean

absolute perihematoma CBF was lower than contralateral homologous regions, it remained above ischemic thresholds. (14) Furthermore, perihematoma relative CBF (rCBF) was not exacerbated by acute BP reduction nor was there an increase of tissue reaching ischemic thresholds in the vascular borderzone regions. (15)

On the other hand, the relationship between cerebral hypoperfusion and DWI lesion formation in ICH has not been described. It therefore remains unknown whether DWI lesions remote to the hematoma are associated with hypoperfusion in the perilesional area or more extensively in the borderzone regions or in the ipsilateral hemisphere. If aggressive BP reduction is causal in DWI lesion formation in ICH, it is hypothesized that this may be due to hypoperfusion (compromised CBF) in the perilesional region of remote DWI lesions or more globally.

The aim of this study was to determine whether remote DWI lesions are associated with decreased perilesional CBF on dynamic susceptibility contrast MRI (DSC-MRI). We tested the hypothesis that remote DWI lesions are independent of hypoperfusion within the perilesional area surrounding DWI lesions.

Methods

Patients

Patients with spontaneous ICH admitted at the University of Alberta Hospital were prospectively screened and enrolled in one of two ICH research studies using MRI (the ICHADAPT II clinical trial or the TIAMISO observational study) according to the eligibility criteria of each study. Research MRIs were performed according to pre-defined study protocols: (ICHADAPT II: at 48 hours, 7 days, and 30

days after ICH onset; TIAMISO: within 3 days of ICH, 7 days, and 90 days after ICH onset).

Imaging Sequences and Analyses

Patients were imaged using either a single or 8-channel phased array radiofrequency head coil on a 1.5-T whole-body Siemens Sonata MRI scanner. MRI sequences included a T1-weighted sagittal localizer, axial T1 and T2-weighted images, Fluid-Attenuated Inversion Recovery (FLAIR), Gradient Recalled Echo (GRE)/Susceptibility Weighted Imaging (SWI), diffusion-weighted (DWI) and perfusion-weighted images (PWI). Single shot Echoplanar (EPI) DWI images were obtained using diffusion gradient strengths (b values) between 0 s/mm², equivalent to a T2-weighted image, and 1000 s/mm², applied in 3 orthogonal planes. These were combined to form isotropic (trace) diffusion images and Apparent Diffusion Coefficient (ADC) maps were generated from these raw data. DWI acquisition parameters were: repetition time (TR) of 3 s, spin echo time (TE) of 86 ms, 8 averages, 128x128 matrix base resolution zero filled to 256x256, 22 cm field-of-view, and 1396 Hz/pixel acquisition bandwidth. The entire brain was imaged using 19-24 contiguous axial slices each 5 mm in thickness, with a 1.5 mm inter-slice gap.

Perfusion images were derived from the concentration-time curve obtained after the administration of intravenous gadolinium (gadopentate (MagnevistTM) 0.5 mmol/ml, 15 ml; 5 ml/sec power injection via an 18 g angiocatheter in an antecubital vein, followed by 20 ml saline flush at the same rate) with EPI gradient-echo (T2*) images acquired every 1.2 seconds for 80 seconds (19 axial slices at each time point).

PWI was not performed in patients with estimated Glomerular Filtration Rate (eGFR) <30 ml/min (Cockcroft-Gault equation). In patients with moderate renal impairment (estimated eGFR 30-60 ml/min), a lower volume of concentrated gadolinium (gadobutrol (GadovistTM), 1.0 mmol/ml, 7.5 ml) was used.

Source PWI images were then post-processed using the semi-automated Mistar imaging software (Apollo Medical Imaging Technology, Melbourne). The arterial input function (AIF) was chosen automatically at the M2 branch of the middle cerebral artery contralateral to the hematoma. Processed CBF and cerebral blood volume (CBV) maps were normalized using normal-appearing white matter in the contralateral hemisphere (verified on FLAIR sequences at either the centrum semiovale or anterior limb of the internal capsule) to generate calibrated CBF and CBV maps.

Hematoma boundaries were defined on PWI source images due to its susceptibility-weighted properties, and were used to calculate hematoma volumes. Regions of interest (ROIs) for hematoma, perihematoma (defined as 1 cm perimeter around the hematoma) and contralateral homologous regions were outlined using semi-automated planimetric techniques on Analyse 13.0 software package (Biomedical Imaging Resource, Mayo Clinic). ROIs were then co-registered to post-processed perfusion maps to calculate perihematoma CBF and CBV.

Remote DWI lesions were identified as hyperintense lesions on B-1000 images with corresponding hypointensities on ADC maps. Perilesional ROIs were outlined as one-centimeter perimeters around DWI hyperintensities and in the contralateral homologous normal-appearing cerebral tissue. Perilesional ROIs were

then co-registered to post-processed CBF and CBV maps. Bilateral internal and external borderzones ROIs were outlined as previously described (15) (Figure 1). All voxels containing blood vessels ($CBF > 100 \text{ mL}/100 \text{ g}/\text{min}$ or $CBV > 8 \text{ mL}/100 \text{ g}$) were removed from ROI using intensity thresholds. In cases where the hematoma itself involved a borderzone, the latter was not outlined.

Statistical Analysis

All statistical analyses were performed using the Statistical Package for Social Sciences version 21.0.0 (IBM SPSS Statistics Inc, 2013, Armonk, NY, USA). Differences in imaging data between patients with and without DWI lesions were assessed using independent t-tests or Mann-Whitney tests, for parametric and non-parametric data respectively. Pearson Chi-square or Fisher's exact tests were used to compare the frequencies of clinical and imaging characteristics between patients with and without DWI lesions.

Results

Nineteen patients were enrolled from January 2013 to summer 2015, after which the research MR magnet used for these studies was permanently shutdown. Twelve patients (63%) had a deep ICH, six (32%) had a lobar ICH, and one patient suffered an infratentorial ICH (Table 1). The median (IQR) hematoma volume on PWI source images was 50.4 (54.6) ml and the median time from symptom onset to PWI was 48 (24) hours.

On baseline MRI, 3 remote DWI hyperintensities were found in 2 patients and 1 subsequent remote DWI hyperintensity was found in one patient on day 7 MRI. Remote DWI lesions were located in the ipsilateral hemisphere in 50% and the majority of DWI lesions were subcortical (n=3, 75%). The median remote DWI lesion volume was 0.24 (0.17) ml. Median hematoma volumes were larger in patients with remote DWI lesions (60.4 (68.1) ml) than patients without DWI lesions (50.4 (50.5) ml, p=0.58).

Perilesional CBF (primary endpoint)

The mean absolute perilesional CBF was 37.6 ± 17.2 ml/100g/min and the CBF in the contralateral homologous normal-appearing cerebral tissue was 35.3 ± 17.4 ml/100g per minute, with a perilesional rCBF of 1.1 ± 0.1 .

Relationship between DWI lesions and perihematoma CBF

Mean (\pm SD) absolute CBF in the perihematoma region was 36.7 ± 8.2 ml/100g/min and 39.9 ± 8.5 ml/100g per minute in the contralateral homologous regions (p=0.25), corresponding to a perihematoma rCBF of 0.94 ± 0.18 (Table 2). Both absolute (32.8 ± 11.4 vs. 37.5 ± 7.4 ml/100g per minute, p=0.37) and relative perihematoma CBF (0.84 ± 0.1 vs. 0.95 ± 0.19 ml/100g per minute, p=0.33) were slightly lower in patients with DWI lesions when compared to those without, respectively. Conversely, mean absolute and relative perihematoma CBV were similar in DWI positive and DWI negative patients (Table 1).

Relationship between DWI lesions and Borderzone CBF

Mean absolute CBF in the internal borderzone (BZ) region was 22.2 ± 7.5 ml/100g (n=16, not calculated in 3 patients on account of hematoma presence in the internal BZ in 3 patients (1 DWI positive and 2 DWI negative patients)). Absolute internal borderzone CBF was slightly lower in patients with DWI lesions (18.8 ± 1.8 ml/100g per minute) than patients without DWI lesions (22.6 ± 8.0 ml/100g, $p=0.29$); however, mean rCBF in the internal BZ regions did not differ between groups (0.96 ± 0.01 and 1.0 ± 0.2 , respectively, $p=0.37$).

In the external borderzone regions, mean absolute CBF was 34.5 ± 7.2 ml/100g per minute in all patients, with an rCBF of 0.97 ± 0.1 . Mean absolute external BZ CBF was similar in patients with DWI lesions (35.3 ± 2.3 ml/100g per minute) and without DWI lesions (34.3 ± 7.5 ml/100g per minute, $p=0.83$). Similar results were observed with respect to rCBF in the external BZ region in both groups (1.1 ± 0.2 vs. 0.95 ± 0.1 , $p=0.91$ respectively).

Relationship between DWI lesions and Hemispheric CBF

Mean absolute ipsilateral hemispheric CBF was 35.7 ± 6.8 ml/100g per minute in all patients with rCBF of 0.96 ± 0.07 . Mean absolute hemispheric CBF did not differ in patients with DWI lesions (39.8 ± 0.9 ml/100g per minute) when compared to patients without DWI lesions (34.9 ± 7.1 ml/100g per minute, $p=0.24$). Similarly, ipsilateral rCBF did not differ between groups (0.98 ± 0.03 vs. 0.96 ± 0.07 , $p=0.60$ respectively).

Discussion

In a small sample of prospectively enrolled spontaneous ICH patients undergoing diffusion-weighted and perfusion-weighted MR imaging, we found no direct evidence for hypoperfusion in the perilesional region of remote DWI hyperintensities. Perihematoma CBF was slightly lower in patients with DWI lesions when compared to those without. Similarly, mean absolute ipsilateral internal borderzone CBF was slightly lower in patients with DWI lesions; however, internal borderzone relative CBF remained similar in patients with and without DWI lesions. No relationship was found between remote DWI lesions and hypoperfusion in the external borderzone regions or hemispherically.

Perihematoma Hypoperfusion in ICH

Perihematoma hypoperfusion has been well documented in several observational studies using MRI, PET and SPECT imaging modalities, as well as in the interventional clinical study ICH ADAPT trial using CTP. These studies have also demonstrated, however, that the nature of perihematoma hypoperfusion is more consistent with a state of reduced metabolism rather than ischemia (through evidence of decreased oxygen extraction rather than increased oxygen extraction as expected in ischemia). Furthermore, we recently showed that DWI lesions within the perihematoma region were independently predicted by larger ICH volumes, possible due bioenergetic compromise secondary to mechanical compression of the tissue, and/or neurotoxicity related to hematoma formation and/or degradation.(16) In our study, perihematoma CBF was slightly lower in patients with remote DWI lesions.

One possible explanation for this finding may be due to the presence of larger hematoma volumes found in patients with DWI lesions. Previous studies have shown that remote DWI lesions were associated with larger ICH volumes.(2)

DWI lesions and Perilesional Hypoperfusion in ICH

To our knowledge, this is the first study to describe the relationship, or lack thereof, between hypoperfusion and remote DWI lesions in ICH. Previous studies have shown that DWI lesion development after transient ischemic attack or acute ischemic stroke was associated with an underlying perfusion deficit. (17,18) Given that DWI lesions are frequently seen after acute ICH, it is therefore plausible that DWI lesions are associated with hypoperfusion, partly in response to a hemodynamic effect of acute BP reduction. (19) We did not find, however, evidence of hypoperfusion in the perilesional area of DWI lesions since perilesional CBF was similar to the CBF in contralateral homologous areas with normal-appearing cerebral tissue.

DWI lesions and Borderzone Hypoperfusion in ICH

To further explore whether regional hypoperfusion may be present in patients with DWI lesions, we analysed perfusion parameters in the vascular borderzone (or watershed) regions, given that these regions are considered to be vulnerable to hemodynamic compromise.(20) Situated between in areas of junction between two vascular beds: internal (between anterior cerebral artery (ACA) and middle cerebral artery (MCA) territories), and the external borderzone (between ACA and MCA, and

between MCA and posterior cerebral artery (PCA) territories), it is thought that vascular borderzone regions are highly dependent on adequate cerebral perfusion. Accordingly, if hypoperfusion is a contributing factor in DWI lesion formation in ICH, changes compatible with hypoperfusion would be anticipated within the vascular borderzone regions.

In this study, we observed a lower mean absolute internal borderzone CBF of 22 ml/100g/min in all ICH patients, particularly in patients with DWI lesions (18.8 ml/100g/min). These findings contrast previous studies which have reported a mean absolute internal borderzone CBF values of 32-35 ml/100g/min in ICH patients.(15) The discrepancy between our finding and prior studies is of unclear significance, but may result from the small number of patients included in this study, the presence of underlying white matter hyperintensities that may confound perfusion analyses, and differences in perfusion imaging techniques (CT perfusion and DSC-MRI perfusion), particularly since quantification of absolute CBF values may not be reliable, particularly with DSC-MRI . Nonetheless, although the absolute internal borderzone CBF observed in our study is lower than previous studies, it remained within the range of normal CBF values for cerebral white matter published in the literature.

(21,22)

Limitations

The recognizably small sample size of our study precludes any firm conclusions based on our findings. Nonetheless, the primary purpose of this study was an exploratory analysis of the relationship between remote DWI lesions and

hypoperfusion in ICH. Secondly, our study is limited by very few numbers of patients (n=3) with DWI lesions, thereby limiting the comparison of perfusion parameters between patients with and without DWI lesions. Thirdly, the presence of larger hematoma volumes affected the outlining of ROIs and subsequently perfusion analyses in some patients. Lastly, analyses of mean transit time and delay time perfusion maps were not possible due to substantial artefacts in these maps rendering them non-interpretable.

Conclusion

In this small prospective study of ICH patients who underwent perfusion-weighted MRI, we did not find evidence of hypoperfusion in the perilesional region of remote DWI lesions. Although mean absolute ipsilateral internal borderzone CBF was slightly lower in patients with DWI lesions, this finding is of unclear significance and requires replication in larger prospective studies.

References

1. Prabhakaran S, Gupta R, Ouyang B, John S, Temes RE, Mohammad Y, et al. Acute brain infarcts after spontaneous intracerebral hemorrhage: A Diffusion-Weighted imaging study. *Stroke*. 2010;41:89-94.
2. Menon RS, Burgess RE, Wing JJ, Gibbons MC, Shara NM, Fernandez S, et al. Predictors of highly prevalent brain ischemia in intracerebral hemorrhage. *Ann Neurol*. 2012;71:199-205.
3. Kang DW, Han MK, Kim HJ, Yun SC, Jeon SB, Bae HJ, et al. New ischemic lesions coexisting with acute intracerebral hemorrhage. *Neurology*. 2012;79:848-855.
4. Gregoire SM, Charidimou A, Gadapa N, Dolan E, Antoun N, Peeters A, et al. Acute ischaemic brain lesions in intracerebral haemorrhage: Multicentre cross-sectional magnetic resonance imaging study. *Brain*. 2011;134:2376-2386.
5. Kimberly WT, Gilson A, Rost NS, Rosand J, Viswanathan A, Smith EE, et al. Silent ischemic infarcts are associated with hemorrhage burden in cerebral amyloid angiopathy. *Neurology*. 2009;72:1230-1235.
6. Garg RK, Liebling SM, Maas MB, Nemeth AJ, Russell EJ, Naidech AM. Blood pressure reduction, decreased diffusion on mri, and outcomes after intracerebral hemorrhage. *Stroke*. 2012;43:67-71.
7. Anderson CS, Heeley E, Huang Y, Wang J, Stapf C, Delcourt C, et al. Rapid blood-pressure lowering in patients with acute intracerebral hemorrhage. *N Engl J Med*. 2013;368:2355-65.
8. Qureshi AI, Palesch YY, Suarez JJ. Intensive Blood-Pressure Lowering in Patients with Acute Cerebral Hemorrhage. *N Engl J Med*. 2016;375(11):1033-43.
9. Paulson OB, Waldemar G, Schmidt JF, Strandgaard S. Cerebral circulation under normal and pathologic conditions. *Am J Cardiol*. 1989 Feb 2;63(6):2C-5C.
10. Mayer SA, Lignelli A, Fink ME, Kessler DB, Thomas CE, Swarup R, et al. Perilesional blood flow and edema formation in acute intracerebral hemorrhage: a SPECT study. *Stroke*. 1998;29:1791-8.

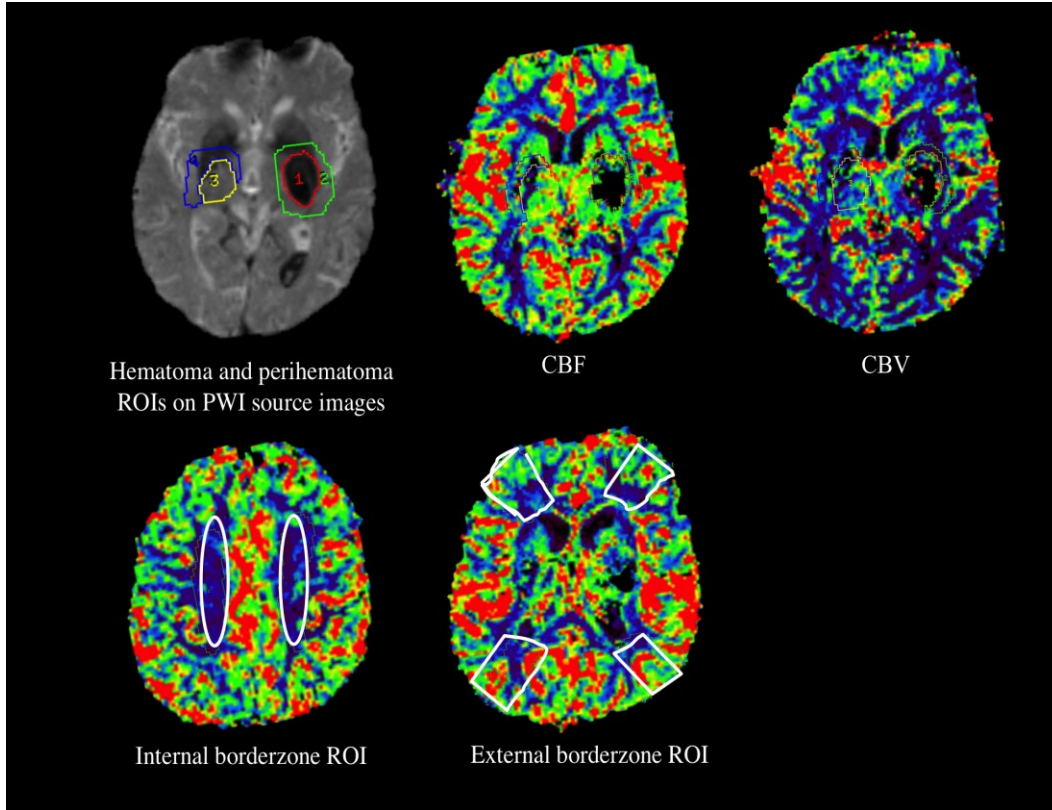
11. Zazulia AR, Diringer MN, Videen TO, Adams RE, Yundt K, Aiyagari V, et al. Hypoperfusion without ischemia surrounding acute intracerebral hemorrhage. *J Cereb Blood Flow Metab.* 2001;21:804–10.
12. Schellinger PD, Fiebich JB, Hoffmann K, Becker K, Orakcioglu B, Kollmar R, et al. Stroke MRI in intracerebral hemorrhage: Is there a perihemorrhagic penumbra? *Stroke.* 2003;34:1674–9.
13. Butcher KS, Baird T, MacGregor L, Desmond P, Tress B, Davis S. Perihematomal edema in primary intracerebral hemorrhage is plasma derived. *Stroke.* 2004;35:1879–85.
14. Butcher KS, Jeerakathil T, Hill M, Demchuk AM, Dowlatsahi D, Coutts SB, et al. The intracerebral hemorrhage acutely decreasing arterial pressure trial. *Stroke.* 2013;44:620–6.
15. Gould B, McCourt R, Gioia LC, Kate M, Hill MD, Asdaghi N, et al. Acute blood pressure reduction in patients with intracerebral hemorrhage does not result in borderzone region hypoperfusion. *Stroke.* 2014 Oct;45(10):2894–9.
16. Gioia LC, Kate M, Choi V, Sivakumar L, Jeerakathil T, Kosior J, Emery D, Butcher K. Ischemia in intracerebral hemorrhage is associated with leukoaraiosis and hematoma volume, not blood pressure reduction. *Stroke.* 2015;46:1541-7.
17. Asdaghi N, Hameed B, Saini M, Jeerakathil T, Emery D, Butcher K. Acute perfusion and diffusion abnormalities predict early new MRI lesions 1 week after minor stroke and transient ischemic attack. *Stroke.* 2011;42:2191-5.
18. Prabhakaran S, Patel SK, Samuels J, McClenathan B, Monhammad Y, Lee VH. Perfusion Computer Tomography in Transient ischemic attack. *Arch Neurol* 2011;68:85-89.
19. Prabhakaran S, Naidech A. Ischemic Brain Injury After Intracerebral Hemorrhage. A Critical Review. *Stroke* 2012; 43:2258-2263.
20. Mangla R1, Kolar B, Almast J, Ekholm SE. Border zone infarcts: pathophysiologic and imaging characteristics. *Radiographics.* 2011 Sep-Oct;31(5):1201-14. doi: 10.1148/rg.315105014.
21. Murphy BD, Fox AJ, Lee DH, Sahlas DJ, Black S, Hogan MJ, et al. White Matter Thresholds for Ischemic Penumbra and Infarct Core in Patients with Acute Stroke: CT Perfusion Study. *Radiology* 2008 247:3, 818-825.

22. WU WC, Lin S-C, Wang DJ, Chen K-L, Li Y-D. Measurement of Cerebral White Matter Perfusion Using Pseudocontinuous Arterial Spin Labeling 3T Magnetic Resonance Imaging – an Experimental and Theoretical Investigation of Feasibility. PLoS ONE 2013;8: e82679.

Table 1. Cerebral Perfusion Analyses In Patients With And Without Remote DWI Lesions.

	All patients (n=19)	DWI positive (n=3)	DWI negative (n=16)
<i>Perihematoma region</i>			
Perihematoma CBF (absolute) (mean±SD)	36.7±8.2	32.8±11.4	37.5±7.4
Contralateral perihematoma CBF absolute) (mean±SD)	39.9±8.5	39.0±13.2	40.0±7.9
Perihematoma rCBF	0.94±0.18	0.84±0.1	0.95±0.19
Perihematoma CBV	2.9±1.0	3.2±1.1	2.8±0.9
Perihematoma rCBV	1.0±0.3	1.1±0.8	0.98±0.2
<i>Borderzone regions (BZ)</i>			
Internal BZ CBF (absolute) (ml/100g/min)	22.2±7.5	18.8±1.8	22.6±8.0
Contralateral internal BZ CBF (absolute) (ml/100g/min)	22.2±6.6	19.7±2.1	22.6±7.0
Internal BZ rCBF	1.0±0.17	0.96±0.01	1.0±0.2
Internal BZ CBV (absolute) (ml/100g)	1.5±0.8	1.3±0.1	1.7±0.8
Internal BZ rCBV	1.1±0.3	1.1±0.1	1.1±0.3
External BZ CBF (absolute) (ml/100g/min)	34.5±7.2	35.3±2.3	34.3±7.5
External BZ rCBF	0.97±0.1	1.1±0.2	0.95±0.1
External BZ CBV (absolute) (ml/100g)	1.9±0.6	2.1±0.1	2.0±0.7
External BZ rCBV	1.0±0.2	1.2±0.5	0.99±0.1
<i>Hemispheric</i>			
Ipsilateral hemispheric CBF (ml/100g/min) (absolute) (mean±SD)	35.7±6.8	39.8±0.9	34.9±7.1
Ipsilateral hemispheric rCBF	0.96±0.07	0.98±0.03	0.96±0.07

Figure 1.



Example of perihematoma and borderzone regions of interest (ROI) in perfusion-weighted MRI in patients with intracerebral hemorrhage (ICH). Perihematoma region and contralateral homologous regions (top left) with co-registering of ROI to calibrated cerebral blood flow (CBF) (top middle) and cerebral blood volume (CBV) maps (top right), as well as internal borderzone ROI (bottom left) and external borderzone ROIs (bottom right).

Chapter 4.

Conclusions

Despite advances in acute stroke treatment in recent years, intracerebral haemorrhage (ICH) remains a devastating disease with high rates of morbidity and mortality. Furthermore, few treatment options currently exist for acute ICH. Recent clinical trials have shown that acute BP reduction to SBP <140 mmHg is safe in ICH patients, but does not influence clinical outcomes. Recent observations that DWI lesions are common after acute ICH have renewed concern for aggressive BP reduction in ICH patients. The overall aims of the work described in this thesis were to 1) study the clinical and imaging factors associated with lesions suggestive of ischemia on diffusion-weighted sequences (DWI) on MRI in patients with acute ICH and 2) determine whether DWI lesions are associated with BP reduction within the acute phase of ICH or hypoperfusion on DSC-MRI.

In this thesis, we have shown that DWI lesions are common within and outside the perihematoma region. Similar to previous studies, we found that these lesions are associated with prior antiplatelet use, lobar ICH location and larger leukoaraiosis volumes; factors which are suggestive of a microvascular arteriopathy that is probably related to the underlying pathogenesis of ICH itself. Contrary to previous studies, however, we were unable to show an association between BP reduction within the first 24 hours of ICH and DWI lesions. As mentioned previously, the discrepancy between our findings and previous studies may be in part due to the inclusion of several time points within the first 24 hours after ICH.

We further explored whether DWI lesions were associated with an underlying hypoperfusion in the second substudy of this thesis. Although the study is limited by its small sample size, we did not find any direct evidence of hypoperfusion in the perilesional area or more globally in the vascular borderzone regions. Although there was some data suggestive of lower internal borderzone CBF in patients with DWI lesions, this is of unclear significance and requires replication in larger prospective studies.

Strengths and Limitations

The work represented by this thesis has a number of strengths and limitations. The strengths of these studies include a novel analysis of the association between DWI lesion formation and BP reduction within the first 24 hours of acute ICH, as well as the first exploratory analysis of the relationship between DWI lesions and perilesional or regional hypoperfusion on PWI-MRI.

These studies, however, are limited to the retrospective design of the first substudy and a small sample size in the second substudy. Ideally, all consecutive ICH patients would be prospectively enrolled and undergo MRI with PWI sequences in the acute phase of ICH. Conducting MRI research in acute ICH patients, however, was seemingly difficult on account of the medical instability in a large number of ICH patients, often precluding them from undergoing MRI/PWI imaging for research purposes. As a result, the studies represented here are inherently biased toward less severe ICH patients.

Future directions

Although the data represented here argue against a hemodynamic mechanism with respect to DWI lesion formation in ICH, this issue can only be properly addressed with a randomized clinical trial of different BP strategies and pre-specified MR imaging. The ICH ADAPT II trial with a 48-hour MRI endpoint is currently ongoing and will help to elucidate the role of BP reduction and DWI formation in the acute phase of ICH.

Secondly, prospective perfusion imaging studies using arterial-spin labeling (ASL) due to the use of an endogenous tracer (arterial blood water protons) could help increase the likelihood of acquiring perfusion imaging in ICH patients irrespective of kidney function. The use of ASL could also facilitate serial perfusion imaging in these patients.

Closing Remarks

The work included in this thesis provides evidence to suggest that DWI lesion formation is independent from BP reduction in ICH patients, but rather associated with an underlying vasculopathy rather than hemodynamic compromise. Ultimately, these findings may help support further clinical trials to determine the safety and efficacy of aggressive BP reduction in the acute phase of ICH management.

Bibliography

1. Qureshi AI, Ezzeddine MA, Nasar A, Suri MFK, Kirmani JF, Hussein HM, et al. Prevalence of elevated blood pressure in 563,704 adult patients with stroke presenting to the ED in the United States. *Am J Emerg Med.* 2007;25:32–8.
2. Britton M, Carlsson A de FU. Blood pressure course in patients with acute stroke and matched controls. *Stroke.* 1986 [cited 2014 Nov 6]. p. 17:861–864.
3. Fischer U, Cooney MT, Bull LM, Silver LE, Chalmers J, Anderson CS, et al. Acute post-stroke blood pressure relative to premorbid levels in intracerebral haemorrhage versus major ischaemic stroke: A population-based study. *Lancet Neurol.* 2014;13:374–84.
4. Dandapani BK, Suzuki S, Kelley RE, Reyes-Iglesias Y, Duncan RC. Relation Between Blood Pressure and Outcome in Intracerebral Hemorrhage. *Stroke.* 1995. p. 21–4.
5. Fogelholm R, Avikainen S, Murros K. Prognostic value and determinants of first-day mean arterial pressure in spontaneous supratentorial intracerebral hemorrhage. *Stroke.* 1997;28:1396–400.
6. Vemmos KN, Tsivgoulis G, Spengos K, Zakopoulos N, Synetos A, Manios E, et al. U-shaped relationship between mortality and admission blood pressure in patients with acute stroke. *J Intern Med.* 2004;255:257–65.
7. Ohwaki K, Yano E, Nagashima H, Hirata M. Blood Pressure Management in Acute Intracerebral Hemorrhage Relationship Between Elevated Blood pressure and hematoma enlargement. *Stroke.* 2004;35:1364-7.
8. Kazui S, Minematsu K, Yamamoto H, Sawada T, Yamaguchi T. Predisposing factors to enlargement of spontaneous intracerebral hematoma. *Stroke.* 1997;28:2370–5.
9. Broderick JP, Brott TG, Duldner JE, Tomsick T, Huster G. Volume of intracerebral hemorrhage. A powerful and easy-to-use predictor of 30-day mortality. *Stroke.* 1993;24:987–93.

10. Davis SM, Broderick J, Hennerici M, Brun NC, Diringner MN, Mayer SA, et al. Hematoma growth is a determinant of mortality and poor outcome after intracerebral hemorrhage. *Neurology*. 2006;66:1175–81.
11. Koch S, Romano JG, Forteza A, Otero CM, Rabinstein A. Rapid blood pressure reduction in acute intracerebral hemorrhage: feasibility and safety. *Neurocrit Care*. 2008 Jan;8(3):316–21.
12. Anderson CS, Huang Y, Wang JG, Arima H, Neal B, Peng B, et al. Intensive blood pressure reduction in acute cerebral haemorrhage trial (INTERACT): a randomised pilot trial. *Lancet Neurol*. 2008;7:391–9.
13. Anderson CS, Heeley E, Huang Y, Wang J, Stapf C, Delcourt C, et al. Rapid blood-pressure lowering in patients with acute intracerebral hemorrhage. *N Engl J Med*. 2013;368:2355–65.
14. Qureshi AI. Antihypertensive treatment of acute cerebral hemorrhage. *Crit Care Med*. 2010;38:637–48.
15. Qureshi AI, Palesch YY. Antihypertensive treatment of acute cerebral hemorrhage (ATACH) II: Design, methods, and rationale. *Neurocrit Care*. 2011;15:559–76.
16. Butcher KS, Jeerakathil T, Hill M, Demchuk AM, Dowlatshahi D, Coutts SB, et al. The intracerebral hemorrhage acutely decreasing arterial pressure trial. *Stroke*. 2013;44:620–6.
17. The Intracerebral Hemorrhage Acutely Decreasing Arterial Pressure Trial II (ICHADAPT II). NCT 02281838. www.ClinicalTrials.gov.
18. Mayer SA, Lignelli A, Fink ME, Kessler DB, Thomas CE, Swarup R, et al. Perilesional blood flow and edema formation in acute intracerebral hemorrhage: a SPECT study. *Stroke*. 1998;29:1791–8.
19. Zazulia AR, Diringner MN, Videen TO, Adams RE, Yundt K, Aiyagari V, et al. Hypoperfusion without ischemia surrounding acute intracerebral hemorrhage. *J Cereb Blood Flow Metab*. 2001;21:804–10.

20. Schellinger PD, Fiebach JB, Hoffmann K, Becker K, Orakcioglu B, Kollmar R, et al. Stroke MRI in intracerebral hemorrhage: Is there a perihemorrhagic penumbra? *Stroke*. 2003;34:1674–9.
21. Butcher KS, Baird T, MacGregor L, Desmond P, Tress B, Davis S. Perihematoma edema in primary intracerebral hemorrhage is plasma derived. *Stroke*. 2004;35:1879–85.
22. Powers WJ, Zazulia a. R, Videen TO, Adams RE, Yundt KD, Aiyagari V, et al. Autoregulation of cerebral blood flow surrounding acute (6 to 22 hours) intracerebral hemorrhage. *Neurology*. 2001 Jul 10;57(1):18–24.
22. Astrup J, Siesjo BK SL. Thresholds in Cerebral Ischemia - the Ischemic Penumbra. *Stroke*. 1981 [cited 2014 Oct 16]. p. 723–5.
24. Gould B, McCourt R, Gioia LC, Kate M, Hill MD, Asdaghi N, et al. Acute blood pressure reduction in patients with intracerebral hemorrhage does not result in borderzone region hypoperfusion. *Stroke*. 2014 Oct;45(10):2894–9.
25. Gould B, McCourt R, Asdaghi N, Dowlatshahi D, Jeerakathil T, Kate M, et al. Autoregulation of cerebral blood flow is preserved in primary intracerebral hemorrhage. *Stroke*. 2013 Jun;44(6):1726–8.
26. Kate MP, Hansen MB, Mouridsen K, Ostergaard L, Choi V, Gould BE, et al. Blood pressure reduction does not reduce perihematoma oxygenation: a CT perfusion study. *J Cereb Blood Flow Metab*. 2014;34:81–6.
27. McCourt R, Gould B, Gioia L, Kate M, Coutts SB, Dowlatshahi D, et al. Cerebral perfusion and blood pressure do not affect perihematoma edema growth in acute intracerebral hemorrhage. *Stroke*. 2014;45:1292–8.
28. Jusufovic M, Sandset EC, Bath PMW, Berge E. Blood Pressure-Lowering Treatment With Candesartan in Patients With Acute Hemorrhagic Stroke. *Stroke*. 2014 Sep 25;
29. Arima H, Anderson CS, Wang JG, Huang Y, Heeley E, Neal B, et al. Lower treatment blood pressure is associated with greatest reduction in hematoma growth after acute intracerebral hemorrhage. *Hypertension*. 2010;56:852–8.

30. Delcourt C, Huang Y, Wang J, Heeley E, Lindley R, Stapf C, et al. The second (main) phase of an open, randomised, multicentre study to investigate the effectiveness of an intensive blood pressure reduction in acute cerebral haemorrhage trial (INTERACT2). *Int J Stroke*. 2010 Apr;5(2):110–6.
31. Brott T, Broderick J, Kothari R, Barsan W, Tomsick T, Sauerbeck L, et al. Early hemorrhage growth in patients with intracerebral hemorrhage. *Stroke*. 1997 Jan;28(1):1–5.
32. Wada R, Aviv RI, Fox AJ, Sahlas DJ, Gladstone DJ, Tomlinson G, et al. CT angiography “spot sign” predicts hematoma expansion in acute intracerebral hemorrhage. *Stroke*. 2007 Apr;38(4):1257–62.
33. Demchuk AM, Dowlatshahi D, Rodriguez-Luna D, Molina CA, Blas YS, Dzialowski I, et al. Prediction of haematoma growth and outcome in patients with intracerebral haemorrhage using the CT-angiography spot sign (PREDICT): A prospective observational study. *Lancet Neurol*. 2012;11:307–14.
34. Dowlatshahi D, Smith EE, Flaherty ML, Ali M, Lyden P, Demchuk AM. Small intracerebral haemorrhages are associated with less haematoma expansion and better outcomes. *Int J Stroke*. 2011;6:201–6.
35. Okumura K, Ohya Y, Maehara A, Wakugami K, Iseki K, Takishita S. Effects of blood pressure levels on case fatality after acute stroke. *J Hypertens* 2005;23:1217-23.
36. Stapf C, Heeley E, Delcourt C, Arima H, Chalmers J, Anderson CS. Abstract 180: The Relation of Timing and Degree of Blood Pressure Control with Hematoma Growth - Secondary Analysis of The Interact2 Trial. *Stroke*. 2014 Feb 1;45(Suppl_1):A180–.
37. Tsivgoulis G, Katsanos AH, Butcher KS, Boviatsis E, Triantafyllou N, Rizos I, et al. Intensive blood pressure reduction in acute intracerebral hemorrhage: A meta-analysis. *Neurology*. 2014 Sep 19;83(17):1523–9.



38. Qureshi AI, Palesch YY, Martin R, Novitzke J, Cruz-Flores S, Ehtisham A, et al. Effect of systolic blood pressure reduction on hematoma expansion, perihematomal edema, and 3-month outcome among patients with intracerebral hemorrhage: results from the antihypertensive treatment of acute cerebral hemorrhage study. *Arch Neurol*. 2010 May;67(5):570–6.
39. Saver JL, Eckstein M, Stratton S, Pratt F, Hamilton S, Conwit R, et al. Abstract 214: The Field Administration of Stroke Therapy - Magnesium (FAST-MAG) Phase 3 Trial: Primary Results. *Stroke*. 2014 Feb 1;45(Suppl_1):A214–.
40. Ankolekar S, Fuller M, Cross I, Renton C, Cox P, Sprigg N, et al. Feasibility of an ambulance-based stroke trial, and safety of glyceryl trinitrate in ultra-acute stroke: the rapid intervention with glyceryl trinitrate in Hypertensive Stroke Trial (RIGHT, ISRCTN66434824). *Stroke*. 2013 Nov;44(11):3120–8.
41. Field Administration of Stroke Therapy-Blood Pressure Lowering (FAST-BP). NCT 01811693. www.ClinicalTrials.gov.
42. Garg RK, Liebling SM, Maas MB, Nemeth AJ, Russell EJ, Naidech AM. Blood pressure reduction, decreased diffusion on MRI, and outcomes after intracerebral hemorrhage. *Stroke*. 2012;43:67–71.
43. Menon RS, Burgess RE, Wing JJ, Gibbons MC, Shara NM, Fernandez S, et al. Predictors of highly prevalent brain ischemia in intracerebral hemorrhage. *Ann Neurol*. 2012;71:199–205.
44. Gregoire SM, Charidimou A, Gadapa N, Dolan E, Antoun N, Peeters A, et al. Acute ischaemic brain lesions in intracerebral haemorrhage: multicentre cross-sectional magnetic resonance imaging study. *Brain*. 2011;134:2376–86.
45. Kimberly WT, Gilson A, Rost NS, Rosand J, Viswanathan A, Smith EE, et al. Silent ischemic infarcts are associated with hemorrhage burden in cerebral amyloid angiopathy. *Neurology*. 2009;72:1230–5.


46. Prabhakaran S, Gupta R, Ouyang B, John S, Temes RE, Mohammad Y, et al. Acute brain infarcts after spontaneous intracerebral hemorrhage: a diffusion-weighted imaging study. *Stroke*. 2010;41:89–94.
47. Kang DW, Han MK, Kim HJ, Yun SC, Jeon SB, Bae HJ, et al. New ischemic lesions coexisting with acute intracerebral hemorrhage. *Neurology*. 2012;79:848–55.
48. Gioia LC, Choi V, Kate M, Emery D, Butcher K. Abstract W P258: Magnitude of Acute Blood Pressure Decrease Does Not Predict the Presence of Diffusion-Restricted Lesions in Patients With Intracerebral Hemorrhage. *Stroke*. 2014 Feb 1;45(Suppl_1):AWP258–.
49. Willmot M, Leonardi-Bee J, Bath PM. High blood pressure in acute stroke and subsequent outcome: A systematic review. *Hypertension*. 2004;43:18-24.
50. Aslanyan S, Fazekas F, Weir CJ, Horner S, Lees KR; for the GAIN International Steering Committee and Investigators. Effect of blood pressure during the acute period of ischemic stroke on stroke outcome: A tertiary analysis of the gain international trial. *Stroke*. 2003;34:2420-2425.
51. Robb RA. The biomedical imaging resource at Mayo Clinic. *IEEE transactions on medical imaging*. 2001;5:227-233.
52. Carhuapoma JR, Wang PY, Beauchamp NJ, Keyl PM, Hanley DF, Barker PB. Diffusion-Weighted MRI and Proton MR Spectroscopic Imaging in the Study of Secondary Neuronal Injury After Intracerebral Hemorrhage. *Stroke* 2000;31:726-732.
53. Olivot JM, Mlynash M, Kleinman JT, Straka M, Venkatasubramanian C, Bammer R, et al. MRI profile of the perihematoma region in acute intracerebral hemorrhage. *Stroke*. 2010;41:2681-2683.
54. Kidwell CS, Saver JL, Mattiello J, Warach S, Liebeskind DS, Starkman S, et al. Diffusion-perfusion mr evaluation of perihematoma injury in hyperacute intracerebral hemorrhage. *Neurology*. 2001;57:1611-1617.

55. Cordonnier C, Potter GM, Jackson CA, Doubal F, Keir S, Sudlow CL, et al. Improving Interrater Agreement About Brain Microbleeds: Development of the Brain Observer Microbleed Scale (BOMBS). *Stroke* 2009;40:94-99.
56. Fazekas F, Barkhof F, Wahlund LO, Pantoni L, Erkinjuntti T, Scheltens P, et al. CT and MRI rating of white matter lesions. *Cerebrovasc Dis* 2002;13 Suppl 2:31-36.
57. Xi G, Keep RF, Hoff JT. Mechanisms of brain injury after intracerebral haemorrhage. *Lancet Neurology*. 2006;5:53-63.
58. Manawadu D, Jeerakathil T, Roy A, Orwaard-Wong K, Butcher K. Blood pressure management in acute intracerebral haemorrhage guidelines are poorly implemented in clinical practice. *Clin Neurol Neurosurg*. 2010;112:858-864
59. Prabhakaran S, Naidech AM. Ischemic Brain Injury After Intracerebral Hemorrhage: A Critical Review. *Stroke* 2012;43:2258-2263.
60. Qureshi AI, Palesch YY, Suarez JJ. Intensive Blood-Pressure Lowering in Patients with Acute Cerebral Hemorrhage. *N Engl J Med*. 2016;375(11):1033-43.
61. Paulson OB, Waldemar G, Schmidt JF, Strandgaard S. Cerebral circulation under normal and pathologic conditions. *Am J Cardiol*. 1989 Feb 2;63(6):2C-5C.
62. Gioia LC, Kate M, Choi V, Sivakumar L, Jeerakathil T, Kosior J, Emery D, Butcher K. Ischemia in intracerebral hemorrhage is associated with leukoaraiosis and hematoma volume, not blood pressure reduction. *Stroke*. 2015;46:1541-7.
63. Asdaghi N, Hameed B, Saini M, Jeerakathil T, Emery D, Butcher K. Acute perfusion and diffusion abnormalities predict early new MRI lesions 1 week after minor stroke and transient ischemic attack. *Stroke*. 2011;42:2191-5.
64. Prabhakaran S, Patel SK, Samuels J, McClenathan B, Monhammad Y, Lee VH. Perfusion Computer Tomography in Transient ischemic attack. *Arch Neurol* 2011;68:85-89.

65. Mangla R1, Kolar B, Almast J, Ekholm SE. Border zone infarcts: pathophysiologic and imaging characteristics. *Radiographics*. 2011 Sep-Oct;31(5):1201-14. doi: 10.1148/rg.315105014.
66. Murphy BD, Fox AJ, Lee DH, Sahlas DJ, Black S, Hogan MJ, et al. White Matter Thresholds for Ischemic Penumbra and Infarct Core in Patients with Acute Stroke: CT Perfusion Study. *Radiology* 2008 247:3, 818-825.
67. WU WC, Lin S-C, Wang DJ, Chen K-L, Li Y-D. Measurement of Cerebral White Matter Perfusion Using Pseudocontinuous Arterial Spin Labeling 3T Magnetic Resonance Imaging – an Experimental and Theoretical Investigation of Feasibility. *PLoS ONE* 2013;8: e82679.

APPENDIX A. Granted Request Permissions For Reproduction

 **RightsLink**[®] [Home](#) [Create Account](#) [Help](#) 

 **Wolters Kluwer**

Title: Blood pressure management in acute intracerebral hemorrhage: current evidence and ongoing controversies

Author: Laura Gioia, Mahesh Kate, Dar Dowlatshahi, et al

Publication: Current Opinion in Critical Care

Publisher: Wolters Kluwer Health, Inc.

Date: Jan 1, 2015

Copyright © 2015, Copyright (C) 2015 YEAR Wolters Kluwer Health, Inc. All rights reserved.

LOGIN
If you're a **copyright.com** user, you can login to RightsLink using your copyright.com credentials. Already a **RightsLink user** or want to [learn more?](#)



Request Denied


This request is granted gratis and no formal license is required from Wolters Kluwer. Please note that modifications are not permitted. Please use the following citation format: author(s), title of article, title of journal, volume number, issue number, inclusive pages and website URL to the journal page.

[BACK](#)

[CLOSE WINDOW](#)

Copyright © 2017 [Copyright Clearance Center, Inc.](#) All Rights Reserved. [Privacy statement.](#) [Terms and Conditions.](#) Comments? We would like to hear from you. E-mail us at customercare@copyright.com

 **RightsLink**[®] [Home](#) [Create Account](#) [Help](#) 

 **Wolters Kluwer**

Title: Ischemia in Intracerebral Hemorrhage Is Associated With Leukoaraiosis and Hematoma Volume, Not Blood Pressure Reduction

Author: Laura C. Gioia, Mahesh Kate, Victor Choi, Leka Sivakumar, Thomas Jeerakathil, Jayme Kosior, Derek Emery, Ken Butcher

Publication: Stroke

Publisher: Wolters Kluwer Health, Inc.

Date: Jun 1, 2015

Copyright © 2015, American Heart Association, Inc.

LOGIN
If you're a **copyright.com** user, you can login to RightsLink using your copyright.com credentials. Already a **RightsLink user** or want to [learn more?](#)

Request Denied

This request is granted gratis and no formal license is required from Wolters Kluwer. Please note that modifications are not permitted. Please use the following citation format: author(s), title of article, title of journal, volume number, issue number, inclusive pages and website URL to the journal page.

[BACK](#)

[CLOSE WINDOW](#)

Copyright © 2017 [Copyright Clearance Center, Inc.](#) All Rights Reserved. [Privacy statement.](#) [Terms and Conditions.](#) Comments? We would like to hear from you. E-mail us at customercare@copyright.com