

Impact of Bisphosphonate Bone Burden on Orthodontic Tooth Movement

by

Neelambar Reddy Kaipatur

A thesis submitted in partial fulfillment of the requirements for the degree of

Doctor of Philosophy

in

Medical Sciences - Orthodontics

University of Alberta

© Neelambar Reddy Kaipatur, 2014

Abstract

Bisphosphonate (BP) drugs have been extensively used to prevent and treat osteoporosis and are shown to decrease the incidence of osteoporotic fractures in humans. Recent evidence has demonstrated that long term use of bisphosphonates is associated with atypical fractures of the spine, femoral head and vertebrae, and osteonecrosis of the jaw due to their effect on inhibiting osteoclast-mediated bone remodeling. Bone remodeling is important to not only maintain skeleton in natural remodeling state but also in active remodeling - such as associated with orthodontic tooth movement (OTM) and the rate of bone turnover has a direct impact on the rate and amount of OTM. As BP drugs affect the rate of bone turnover by preserving bone mass, they are evidenced to slow down tooth movement. Current research using animal models on the influence of bisphosphonate drugs on tooth movement was focused on using the drug concurrent with tooth movement. The clinical scenario that presents to an orthodontist is that of an adult male or female on years of bisphosphonate drugs to prevent or treat osteoporosis or similar disorders requiring orthodontic care for straightening teeth and improving smile esthetics. To date, there are no published studies that have investigated the effect of long term use of bisphosphonate drugs (BP burden) on OTM. We hypothesized that the bone burden of BP drugs would slow down tooth movement. Our secondary goal was also to investigate accelerators of tooth movement, to reverse the inhibitory effect of BP burden. Although many invasive and non-invasive methods to accelerate tooth movement have been attempted to date; corticotomy is the most effective and reliable method to accelerate tooth movement in both animals and human studies. The objective of the study was to investigate the bone burden effect of long term use of alendronate sodium; the most commonly used BP drug on orthodontic tooth movement and also to explore the consequence of accelerating tooth movement in BP burdened alveolar bone in a rodent model. A novel tooth movement model was developed using rat TSADs (Temporary skeletal anchorage devices) and NiTi coil springs. Finite Element analysis of TSAD stability as anchorage during tooth movement was performed. Three month-old Sprague-Dawley female rats were used as

the animal model for the entire study. *In vivo* microcomputed tomography imaging was performed at baseline (0 week) 4 and 8 weeks for measuring tooth movement. At the experimental end point (8 weeks) all animals were euthanized using CO₂ inhalation and processed for histology and Electron Probe Micro-analysis (EPMA) imaging. While concurrent dosing of alendronate drug during tooth movement showed a 56% and 65% reduction compared to control animals; the impact of bone burden on tooth movement was significant with 77% and 86% reduction in tooth movement at 4 and 8 weeks respectively in the bisphosphonate burden group compared to controls. Selective alveolar decortication surgery (SADc) did not have a substantial impact on accelerating tooth movement in control animals with only a 2% and 6% increase at 4 and 8 weeks respectively. The effect of SADc in bisphosphonate burden group was significant at 4 weeks with a 113% increase in tooth movement compared to BP burden group alone. This acceleration of tooth movement was transient with only a modest 10% increase from 4 to 8 weeks. EPMA imaging showed lack of dynamic labeling of Strontium (Sr²⁺ acts as surrogate for Ca²⁺ and gets deposited in areas of newly formed bone) in the BP burdened animals due to lack of active bone remodeling while the control animals showed robust remodeling with increase in dynamic labeling of Strontium. SADc surgery did increase tooth movement in bisphosphonate burden animals but the increase was not evident long term and was associated with areas of necrotic bone with osteolysis, accompanied by pyknotic nuclei and/or lost osteocytes with empty lacunae along with bacterial infiltration and severe buccal and interproximal bone loss.

In summary, burdening of alveolar bone with BP drugs did substantially slow down tooth movement and an attempt to accelerate tooth movement in this BP burdened bone using selective alveolar decortication surgery led to a short term increase in tooth movement for 4 weeks but was associated with severe bone loss with histological evidence of bone osteonecrosis.

Preface

This thesis is an original work by Neelambar Kaipatur. The research project, of which this thesis is a part, received research ethics approval from the University of Alberta Animal Research Ethics Board, Project Name Titled “Effects of Bisphosphonate drugs on Orthodontic Tooth Movement in Rats”, Protocol No. 596/06/11ID, Dated: October 26, 2009.

Chapter 3 of this thesis has been accepted for publication: Kaipatur N, Wu Y, Adeeb S, Stevenson T, Major P and Doschak M, “A Novel Rat Model of Orthodontic Tooth Movement using Temporary skeletal anchorage devices: 3-D Finite element Analysis and In-vivo Validation,” International Journal of Dentistry; Volume 2014 (2014), Article ID 917535, 11 pages. I was responsible for the design concept of the animal model, animal surgeries, data collection and analysis as well as the manuscript composition. Y. Wu contributed to the FE part of the study including FE model design, execution and data collection and contributed to manuscript edits.

Dedicated to my father and my beloved sister

Acknowledgements

I would like to express my utmost gratitude to my supervisors Dr. Paul Major and Dr. Michael Doschak; for all the support and guidance they provided throughout the entire program, from financial stability to guiding me every step in my research. I would not have done this without them.

I also would like to show my appreciation and thank my committee members; Dr. Samer Adeeb, Dr. Tom Stevenson and Dr. Dan Pehowich for their guidance with individual projects and the overall study.

My sincere thanks and indebtedness to my lab mates Yuchin and Arash for those countless hours of late evening brain storming regarding research, dinners together, and interesting discussions about life in general. I will not forget the contribution of Nghe who had been a friend, confidant and hotel room sharing partner at conferences during my entire graduate studies. They all have been a real source of inspiration throughout my graduate program. Special thanks to Jillian and Imran for help with micro CT imaging, Tracy for assistance with animal surgeries, and to all the lab colleagues from Dr. Doschak lab who have helped me along the way in making this project successful.

In addition, I would like to thank McIntyre research fund for funding the research.

Lastly, I am forever grateful to my family who stood by me throughout this stretch of countless hours of not being there for them; understanding and allowing me to fulfil my dream.

Table of Contents

CHAPTER 1	INTRODUCTION	1
	<i>1.1.</i> SCOPE OF DISSERTATION.....	2
	<i>1.2.</i> GENERAL HYPOTHESES AND SPECIFIC OBJECTIVES.....	3
	<i>1.2.1.</i> SPECIFIC OBJECTIVE #1.....	4
	<i>1.2.2.</i> SPECIFIC OBJECTIVE #2.....	4
	<i>1.2.3.</i> SPECIFIC OBJECTIVE #3.....	4
	<i>1.3.</i> REFERENCES	6
CHAPTER 2	LITERATURE REVIEW	9
	<i>2.1.</i> ORTHODONTIC TOOTH MOVEMENT	10
	<i>2.2.</i> BIOLOGY OF OTM.....	11
	<i>2.3.</i> ANIMAL MODEL OF OTM.....	12
	<i>2.4.</i> TSAD ANCHORAGE IN OTM.....	13
	<i>2.5.</i> FINITE ELEMENT ANALYSIS OF TSAD ANCHORAGE.....	14
	<i>2.6.</i> DRUGS IN OTM.....	15
	<i>2.7.</i> OSTEOPOROSIS.....	16
	<i>2.8.</i> BISPHOSPHONATES.....	19
	<i>2.8.1</i> HISTORY AND CLASSIFICATION.....	19
	<i>2.8.2</i> MECHANISM OF ACTION.....	20
	<i>2.8.3</i> PHARMACOKINETIC/PHARMACODYNAMIC PROFILE OF BISPHOSPHONATE....	23
	<i>2.8.4</i> CONCERNS WITH CURRENT PHARMACOKINETIC PROFILE OF BISPHOSPHONATES.....	26
	<i>2.8.5</i> METABOLITES OF BISPHOSPHONATES.....	27
	<i>2.8.6</i> PHARMACOGENETICS OF BISPHOSPHONATES.....	28
	<i>2.8.7</i> EXCRETION OF BISPHOSPHONATES.....	29
	<i>2.9.</i> BISPHOSPHONATES AND OSTEONECROSIS OF THE JAW.....	30
	<i>2.10.</i> BISPHOSPHONATES AND OTM.....	33
	<i>2.11.</i> ACCLERATORS OF OTM.....	34

2.12. REFERENCES.....	37
------------------------------	-----------

CHAPTER 3	A NOVEL RAT MODEL OF ORTHODONTIC TOOTH MOVEMENT USING TEMPORARY SKELETAL ANCHORAGE DEVICES: 3-D FINITE ELEMENT ANALYSIS AND IN-VIVO VALIDATION.....	53
------------------	--	-----------

3.1. ABSTRACT.....	54
3.2. INTRODUCTION	55
3.3. MATERIALS AND METHODS	57
3.4. RESULTS.....	63
3.5. DISCUSSION.....	70
3.6. CONCLUSIONS.....	74
3.7. REFERENCES.....	75

CHAPTER 4	IMPACT OF BISPHOSPHONATE DRUG BONE BURDEN DURING ORTHODONTIC TOOTH MOVEMENT IN A RAT MODEL: A PILOT STUDY.....	80
------------------	---	-----------

4.1. ABSTRACT.....	81
4.2. INTRODUCTION	82
4.3. MATERIALS AND METHODS	84
4.4. RESULTS.....	91
4.5. DISCUSSION.....	96
4.6. CONCLUSION	101
4.7. REFERENCES	102

CHAPTER 5	IMPACT OF SELECTIVE ALVEOLAR DECORTICATION ON BISPHOSPHONATE BURDENED ALVEOLAR BONE DURING ORTHODONTIC TOOTH MOVEMENT.....	107
------------------	---	------------

5.1. ABSTRACT.....	108
5.2. INTRODUCTION	109

5.3.	MATERIALS AND METHODS	111
5.4.	RESULTS.....	118
5.5.	DISCUSSION	129
5.6.	CONCLUSION	135
5.7.	REFERENCES	136
CHAPTER 6	GENERAL DISCUSSION AND CONCLUSION.....	142
6.1	DISCUSSION	143
6.2	CONCLUSION.....	148
6.3	POTENTIAL IMPACT.....	149
6.4	LIMITATIONS.....	150
6.5	FUTURE DIRECTION.....	151
6.6	REFERENCES	152

List of Tables

Table 4-1 Mean changes in the animal weight, force levels and tooth movement measured at 4, 8 weeks respectively compared to baseline (0 weeks) in all four groups.....	93
Table 5-1 Mean amount of tooth movement measured at 4 and 8 weeks and histomorphometric measurement of bone area and bone perimeter in all 4 groups with left side acting as intra-animal control in bone burdened and control animals. OTM = Orthodontic Tooth Movement; TM = Tooth movement; SADc = Selective Alveolar Decortication; BP = Bisphosphonate burden; SD = Standard Deviation.....	119

List of Figures

Figure 2-1 Schematic drawing of a tooth, the periodontal ligament with cells and bone. (a) An external force is applied (arrow). (b) At the apposition side, fibers are stretched. Compression of fibers takes place at the resorption side. (c) After prolonged force application, bone formation by the osteoblasts can be found at the apposition side and osteoclasts resorb the bone at the resorption side.....	11
Figure 2-2 Chemical structure of common bisphosphonates.....	21
Figure 2-3 Mechanism of action of bisphosphonates.....	22
Figure 2-4 Binding affinities and inhibition of FPPS of four different types of bisphosphonates.....	24
Figure 3-1 Computer modeling of TSAD placement into the rat maxilla 3D model of hemi-maxillae in A. a sagittal view and B. Transverse view C. 3D model of the hemi-maxillae showing the direction of force applied during FE analysis D, E. Fine mesh of the TSAD and the surrounding maxillary bone.....	59
Figure 3-2 Orthodontic appliance in the right maxilla for tooth movement using TSAD and NiTi closed coil spring. Inset: μ CT 3D rendered cross-section model of rat maxilla with appliance.....	60
Figure 3-3 von Mises stress and displacements at A. 0 gms, B. 30 gms C. 60 gms and D. 140 gms of force. The warmer colors depict increase in the amount and distribution of the stress and displacement and shows stresses concentrated at the apex of the TSAD and at the coronal contact area between the TSAD and the bone.....	64
Figure 3-4 Von Mises stress localization in the cortical bone surrounding the TSAD. Dark blue color represents minimal von Mises stress and red color represents maximum von Mises stress localization around the TSAD.....	65
Figure 3-5 Three-dimensional microcomputed tomography –rendered images showing the amount of tooth movement of the right first permanent molar at 4 and 8 weeks. (M1, Right permanent first molar; M2, right permanent second molar; M3, right permanent third molar.....	66
Figure 3-6 (a) Mean (\pm SE) amount of orthodontic tooth movement and implant displacement at 4 and 8 weeks. (Significance level * $p < 0.05$	67
Figure 3-6 (b) Mean rate of orthodontic tooth movement and implant displacement at 0 4, and 8 weeks.....	67
Figure 3-7 Sagittal (a) and cross-sectional (e) backscattered images and electron microprobe mapping of calcium (b, f); phosphorus (c, g); Strontium (d, h) composition of the alveolar bone surrounding the micro-TSAD. No evidence of recognizable difference in the calcium or phosphorus levels of bone immediately around the micro-TSAD and the surrounding preexisting bone (♣). (d, h) shows no strontium deposition in the alveolar bone immediately surrounding the micro-TSAD. Lack of strontium deposition confirms no active bone remodeling and excellent micro-TSAD stability. * TSAD cavity. Scale bars = 1 mm in (a-h).....	68

Figure 3-8 Electron microprobe mapping of strontium (a, d) calcium (b, e); phosphorus (c, f) composition of the alveolar bone surrounding the upper left (control) and right first permanent molar (OTM) respectively. Panel d, shows increased Strontium deposition (*) surrounding the roots of right first permanent molar where OTM occurred. Evidence of increased strontium deposition indicates increased bone remodeling on the tension side of OTM. No difference in the Ca (b, e) and P (c, f) composition could be seen between control and OTM side. OTM-Orthodontic Tooth Movement. Indicates direction of tooth movement. Scale bars = 2 mm in (a-c); 5 mm in (d-f).....69

Figure 3-9 Histologic hematoxylin and eosin stained paraffin sections of the maxillary left (a) and right (b) first permanent molar area. While normal bone remodeling occurs on the control side with no gap between the first and second molar (a) increased separation between the first and second permanent molars (tooth movement) and increased bone remodeling is evident on the tension side of OTM (b). (c) Higher magnification of boxed area in (b) with stretched PDL fibers (Inset). (d) Alveolar bone surrounding the micro-TSAD. (arrows) with part of TSAD inadvertently into PDL space surrounding the tooth root. * denotes micro-TSAD space; scale bars = 1 mm.....70

Figure 4-1 Experimental design and time schedules for (A) BP concurrent-dosed and (B) BP pre-dosed groups and their respective controls. Alendronate sodium or saline dosing was started 1 week prior to and concurrent with OTM for 8 weeks and in-vivo μ CT scanning was done at 0, 4, 8 weeks of OTM with a strontium 10 day pulse prior to euthanasia. (A) Alendronate or saline dosing started 12 weeks prior to OTM and OTM was continued for 8 weeks with μ CT scanning at 0, 4, 8 weeks of OTM and a strontium 10 day pulse prior to euthanasia (B).....85

Figure 4-2 Orthodontic appliance in the right maxilla for tooth movement using micro-implant and NiTi closed coil spring.....87

Figure 4-3 Image of μ CT rendered 2D scan viewed with Data Viewer software for measuring tooth movement. Once the image was centered in three planes of space, the linear distance between the most convex contact area between the upper right second and first permanent molar was measured and recorded at 0, 4 and 8 weeks and the amount of tooth movement was estimated by measuring the difference in tooth movement at 4, 8 weeks compared to baseline (0 weeks).....89

Figure 4-4 Loading and unloading curves of NiTi closed coil springs measured using Instron universal testing machine with a load cell +/- 1kN. Loading and unloading curves were generated by applying a constant displacement of 2.5 mm/min up to 12 mm of displacement.....92

Figure 4-5 3D μ CT rendered model showing difference in tooth movement in control and BP pre-dosed rats at 0, 4 and 8 weeks. (M1, right first permanent molar; M2, right second permanent molar; M3, right third permanent molar).....93

Figure 4-6 Mean amount of tooth movement measured at 4 and 8 weeks in all four groups. (Significance level set at 0.016: *; > 0.0016: **; > 0.00016: ***).....94

Figure 4-7 EPMA rendered images of upper right first molar region of (A) control and (B) BP drug burden group depicting increased strontium deposition in the control group (*) and negligible strontium deposition in the BP burden group (♣) The warmer color (light blue) indicates strontium deposition (*) wherein the strontium molecule replaces calcium during new bone deposition at the tension side of the tooth following tooth movement. Due to negligible tooth movement and lack of alveolar bone remodeling very limited to none strontium deposition is seen in the BP drug group as shown (♣) (MP-mesiopalatal; DP-distopalatal).....95

Figure 4-8 Histologic H & E stained sections of upper right first molar area in (A) control and (B) BP burden group showing decreased tooth movement in the BP burdened group. (magnification 2.5x) While the control animals showed normal features of alveolar bone remodeling following tooth movement including stretching of the gingival and periodontal ligament fibers (*) and increased bone remodeling (♣), the BP dosed animals showed lack of active bone remodeling. Lower panels (C and D) show higher magnification of the interseptal bone in the first molar area. (Magnification 10x) Panel C shows active bone remodeling with cement lines (arrows) depicting areas of new bone formation whereas the BP burden group showed presence of bony islands (♣) due to lack of active remodeling, lesser vascular channels and greater fibrotic component with regular and round shaped osteoclasts lacking ruffled border (arrows- Inset panel D) (MP-mesiopalatal).....96

Figure 5-1 Experimental design and time schedules for experimental groups and their respective controls: A, BP burden group. B, BP burden + SADc group and their respective controls.....112

Figure 5-2 Histomorphometric analysis was performed for bone parameters with construction of the black and white image mask. (A) A region of interest was selected from a Hematoxylin and eosin stained section obtained at 5x magnification (B) The captured image was then opened in Adobe Photoshop® to prepare the black and white mask. Within the selected region of interest, bone was identified and represented in black (C) and the remaining non-bone area was selected as white. (D).....116

Figure 5-3 3D µCT rendered model showing difference in tooth movement in A, TM; B, TM+SADc; C, BP+TM and D, BP+TM+SADc rats at 0, 4 and 8 weeks. TM = Tooth Movement; SADc = Selective Alveolar Decortication; BP = Bisphosphonate burden; M1 = Upper right first permanent molar; M2 = Upper right second permanent molar; M3 = Upper right third permanent molar.118

Figure 5-4 Kruskal Wallis non parametric test shows significant difference in the mean amount of tooth movement among all four groups at 4 weeks (p~0.001) and 8 weeks (p~0.0001).....120

Figure 5-5 Mean amount of orthodontic tooth movement measured at 4 and 8 weeks in all four groups (significance level: *p<0.05, **p<0.005, ***p<0.0005, NS = Non Significant.....121

Figure 5-6 Panel (A-F) show µCT rendered sagittal images depicting alveolar bone remodeling between upper right first and second molar area. Panel (G) thru (L) Hematoxylin and eosin stained sections of the area of interest (□) original magnification 5x. While normal remodeling occurs in control animals; BP burdened animals show either lack of remodeling in BP burdened alveolar bone when tooth movement alone was attempted (panel (E) and (K) or severe interproximal alveolar bone loss ((Arrows (F) and (L)) as a result of tissue injury from selective alveolar decortication. C = Control; TM = Tooth Movement; SADc = Selective Alveolar Decortication; BP = Bisphosphonate burden; M1 = Upper right first permanent molar; M2 = Upper right second permanent molar123

Figure 5-7 Panel (A) Micro-CT rendered coronal images showing areas of necrotic bone (□) detached from the rest of the alveolar and basal bone. Panel (B) Hematoxylin and eosin stained sections of the area of interest (□) with osteonecrotic bone associated with bacterial infiltration (black arrows), inflammatory cell infiltrate surrounding the necrotic bone and presence of pyknotic osteocytes in the area of necrotic bone (yellow arrows). (Panel C) DB = Disto Buccal; MP = Mesio Palatal; MB = Mesio Buccal; M1 = Upper right first permanent molar; M2 = Upper right second permanent molar; NB = Necrotic Bone. Panel B original magnification 10x; panel C original magnification 20x.....124

Figure 5-8 Histopathology and histomorphometric analysis of tissue response to selective alveolar decortication in control and bisphosphonate burdened animals. Kruskal-Wallis non parametric test showed no significant difference among the groups in trabecular bone area ($p \sim 0.846$) while a significant difference in the bone perimeter was found among groups ($p \sim 0.038$). In the control animals the left contralateral control site (A) has significantly more trabecular bone compared to right experimental side in TM group (B) and TM+SADc group (C). Although robust remodeling was associated with SADc there was no significant difference in the bone area ($p \sim 0.818$) or perimeter ($p \sim 0.065$) between TM+SADc group (C) compared to TM group alone. (B) In the bisphosphonate burdened animals no changes in the architecture was evident between the left contralateral side (D) and right tooth movement side (E). The bisphosphonate burdened animals in both D and E show dense trabecular bone with decrease in vasculature compared to normal bone (A). The effect of selective alveolar decortication injury in bisphosphonate burdened animals coupled with tooth movement (F) showed severe buccal bone loss (arrows) with lack of active bone remodeling usually associated with corticotomy surgery. Mean \pm S.D. of trabecular bone surface area (G) and trabecular bone perimeter (H) in different groups at the end of experimental time point (8 weeks). (Hematoxylin and eosin; original magnification: A-F x5.) M = Mesial; MP = Mesio Palatal; MB = Mesial Buccal; DB= Disto Buccal; DP = Disto Palatal; TB = Trabecular Bone; C = Control; TM = Tooth Movement; SADc = Selective Alveolar Decortication; BP = Bisphosphonate burden.....125

Figure 5-9 Histologic H & E stained sections of upper right first molar area in (A) SADc, (B) Control, (C) BP burden + SADc and (D) BP burden group showing more tooth movement in the BP burden + SADc group when compared to BP burdened group. While the control animals (A & B) showed normal features of alveolar bone remodeling following tooth movement including stretching of the gingival and periodontal ligament fibers (*) and increased bone remodeling (♣), the BP dosed animals showed lack of active bone remodeling with severe interproximal bone loss (arrows) in the BP burden + SADc group. (Hematoxylin and eosin; original magnification: A-D x2.5). SADc = Selective Alveolar Decortication; BP = Bisphosphonate; MP = Mesio Palatal.127

Figure 5-10 Electron-probe micro analyzer rendered images of maxillary molar region of (A), contralateral left control side with limited remodeling activity in comparison to right molar region of (B), TM group and (C) TM+SADc groups; showing increased strontium deposition in both the groups (*) In contrast the BP burdened tissues show lack of appreciable remodeling with no strontium uptake and activity in (D) control left side; (E) BP+TM group and (F) BP+TM+SADc group. (♣). The warmer colors in both the TM and TM+SADc group as shown by red asterisk (*) demonstrates increased bone remodeling due to high tissue turnover; that is apparently lacking in the bisphosphonate laden bone in BP+TM and BP+TM+SADc groups. Also there is evidence of severe buccal and interproximal bone loss in BP+TM+SADc group. (arrows) MP = Mesio Palatal; DP = Disto Palatal; TM = Tooth Movement; SADc = Selective Alveolar Decortication; BP = Bisphosphonate burden129

List of Symbols, Nomenclature, or Abbreviations

2D	two dimensional
3D	three dimensional
ALN	alendronate sodium
BP	bisphosphonate
BPs	bisphosphonates
BRON	bisphosphonate related osteonecrosis
BRONJ	bisphosphonate related osteonecrosis of jaw
Ca ²⁺	calcium
CO	carbon dioxide
CT	computed tomography
DB	disto buccal
DP	disto palatal
E	Young's modulus
EPMA	electron probe micro analysis
FE	finite element
FEA	finite element analysis
FPPS	farnesyl pyrophosphate synthase
H & E	hematoxylin and eosin
kN	kilo newton
Micro-CT	micro-computed tomography
M1	first permanent molar
M2	second permanent molar
M3	third permanent molar
min	minute
mm	millimeters
MB	mesio buccal
MP	mesio palatal
NB	necrotic bone
NiTi	nickel titanium
NS	non-significant
OP	osteoporosis
OTM	orthodontic tooth movement
PDL	periodontal ligament
PBS	phosphate buffered saline
RANKL	receptor activator of nuclear factor kappa β
ROI	region of interest
SADc	selective alveolar decortication
SD	standard deviation
SE	standard error
Sr ²⁺	Strontium
TSAD	Temporary skeletal anchorage device
TM	tooth movement
v	Poisson's ratio
μ CT	microcomputed tomography

Chapter 1 Introduction

1.1 Scope of the dissertation

Several current drugs have profound effect on the outcomes of orthodontic tooth movement, (OTM)¹ which is mediated through controlled application of mechanical forces to teeth. One such drug class is the bisphosphonates (BPs) that are taken by patients to manage conditions of bone loss, such as Osteoporosis (OP). Despite serious concerns about their long-term safety in patients, due to their incorporation into bone, and recent reports of severe adverse patient reactions to certain BPs, such as osteonecrosis of the jaw,³⁻⁴ BP antiresorptive drugs have become the first line of therapy for OP due to the recent demise of hormone replacement therapy for treating osteoporosis.² Hence, there is a critical need for orthodontists to understand the influence and consequence of BP drug action upon OTM and/or surgical treatment plans, as currently, those drug effects are virtually unknown. BP drug antiresorptive activity will result in reduced osteoclastogenesis/bone resorption and delay tooth movement.⁵ The wide ranging side-effects of BP drug use upon dental health, include the retardation of OTM treatment plans and potentially BP-related osteonecrosis (BRON) of the jaw.³⁻⁵ Yet, there is an increasing incidence of mature-age patient population currently seeking orthodontic care⁶, and many of these patients may have been on BP drug regimens for OP management for many years. Hence, the aim of this dissertation is to better understand the influence of BP drug action upon OTM treatment plans, and how to neutralize and/or reverse those effects by using accelerators of tooth movement.

Several accelerators of tooth movement are being used to shorten treatment time including; corticotomy,⁷⁻¹¹ low level laser therapy,^{12, 13} mechanical vibration,¹⁴ pulsed electromagnetic therapy,¹⁵ electrical currents¹⁶ and distraction osteogenesis.¹⁷⁻¹⁹ Also biologic approach to accelerate tooth movement have been attempted through invitro²⁰ and *in vivo* localized RANKL

gene therapy.²¹ A recent systematic review by Long et al.²² showed that corticotomy is an effective modality to accelerate tooth movement and is relatively safe compared to any other method.

Thus, during bone healing, or during the “linear phase” of OTM, where activated bone cells orchestrate the resorption of mineralized bone, the cells will encounter BP drug molecules that have become trapped in the matrix of the bone due to their affinity for calcium ions and mineralized tissues. When this “bone burden” of incorporated BP drug is released into the local microenvironment, it will interfere with bone cell activity, resulting in cell death and the retardation of remodeling, OTM and/or bone healing.

The objective of this dissertation is to examine and define the effects of BP drug therapy in a controlled rat model of OTM, and further assess the potential of selective alveolar decortication facilitated acceleration of OTM, in normal and BP-dosed alveolar bone. The prime impetus for our study is that our current understanding of the impact of BP drug bone burden upon planned OTM or oral surgery is not satisfactory. The results of our study will assist orthodontists and dental surgeons in developing appropriate dental treatment plans based on patient BP drug history, to effectively conduct oral surgery and/or the clinical movement of teeth in an effort to avoid causing harm to the biology of the tooth and jaw.

1.2 General Hypothesis and Specific Objectives

Our *general hypothesis* is that: **BP drug therapy will retard OTM, and the local targeted alveolar decortication surgery will result in an increase in osteoclast activity, thereby accelerating and correcting the delayed OTM.**

1.2.1 Specific Objective #1: To develop a novel model of OTM with Temporary skeletal anchorage devices (TSADs) using Finite Element (FE) method and to validate the effectiveness of TSADs *in vivo* as direct anchorage using NiTi coil springs for efficient tooth movement in a rodent model of OTM.

A Stryker 1.2x3 mm TSAD was placed in the rat maxilla and implant stability was assessed using FE analysis with ABAQUS software. A rodent model was used for OTM using TSADs and NiTi coil springs. OTM measurements were obtained at 0, 4, and 8 weeks using *in vivo* μ CT. Tissues were also analyzed with histology and dynamic labeling of bone turnover

1.2.2 Specific Objective #2: To determine the effect of concurrent and pre-dosing (bone burden) of BP drug therapy on orthodontic tooth movement in rats

In brief, four groups of rats were aged in-house, the first two groups being pretreated for 1 week twice daily (0.015 mg/kg *s.c.*) with the BP drug alendronate sodium or saline, followed by twice a week concurrent dosing during OTM (BP concurrent-dosed), whilst the third and fourth group were pre-treated for 3 months with alendronate sodium twice a week (0.015mg/kg *s.c.*) or saline injections and drug stoppage prior to OTM. (BP pre-dosed) All rats underwent OTM for 8 weeks using TSADs and NITI coil springs as shown in specific objective #1. Tooth movement measurements were measured in each animal (at 0, 4, and 8 wk) using high resolution *in vivo* μ CT imager. Histological and EPMA qualitative bone remodelling analysis were performed.

1.2.3 Specific Objective #3: To test the effectiveness of selective alveolar decortication as an accelerator of OTM *in vivo* in both normal and BP burdened rats.

In brief, four groups of rats were aged in-house, two groups were pretreated for three months with alendronate sodium (BP+TM+SADc and BP+TM group) and two groups were given saline (TM+SADc and TM group) as in specific objective #2. Selective alveolar decortication surgery was performed on day 1 of appliance insertion. All rats underwent OTM for 8 weeks using TSADs and NITI coil springs as shown in specific objective #1. OTM measurements were obtained at 0, 4, and 8 weeks using in-vivo μ CT. Tissues were also analyzed with histology and dynamic labeling of bone turnover and histomorphometric quantitative analysis was performed.

1.3 *References*

1. Bartzela T, Türp JC, Motschall E, Maltha JC. Medication effects on the rate of orthodontic tooth movement: a systematic literature review. *Am J Orthod Dentofacial Orthop.* 2009;135(1):16-26.
2. Nelson HD, Haney EM, Chou R, Dana T, Fu R, Bougatsos C. screening for Osteoporosis: Systematic Review to Update the 2002 U.S. Preventive Services Task Force Recommendation [Internet]. Rockville (MD): Agency for Healthcare Research and Quality (US); 2010 Jul. Report No.: 10-05145-EF-1. U.S. Preventive Services Task Force Evidence Syntheses, formerly Systematic Evidence Reviews.
3. Chamizo Carmona E, Gallego Flores A, Loza Santamaría E, Herrero Olea A, Rosario Lozano MP Systematic literature review of bisphosphonates and osteonecrosis of the jaw in patients with osteoporosis. *Reumatol Clin.* 2013 May-Jun;9(3):172-7. doi: 10.1016/j.reuma.2012.05.005. Epub 2012 Jul 10. Review. English, Spanish.
4. Ruggiero SL. Bisphosphonate-related osteonecrosis of the jaw: an overview. *Ann N Y Acad Sci.* 2011 Feb;1218:38-46. doi: 10.1111/j.1749-6632.2010.05768.x. Epub 2010 Sep 28. Review.
5. Iglesias-Linares A, Yáñez-Vico RM, Solano-Reina E, Torres-Lagares D, González Moles MA. Influence of bisphosphonates in orthodontic therapy: Systematic review. *J Dent.* 2010 Aug;38(8):603-11. doi: 10.1016/j.jdent.2010.05.012. Epub 2010 Jun 8. Review.
6. Nattrass C, Sandy JR. Adult orthodontics – a review. *Br J Orthod.* 1995;22:331-7.

7. Iino S, Sakoda S, Ito G, Nishimori T, Ikeda T, Miyawaki S. Acceleration of orthodontic tooth movement by alveolar corticotomy in the dog. *Am J Orthod Dentofacial Orthop.* 2007;131(4):448.e1-8.
8. Wang L, Lee W, Lei DL, Liu YP, Yamashita DD, Yen SL. Tissue responses in corticotomy- and osteotomy-assisted tooth movements in rats: histology and immunostaining. *Am J Orthod Dentofacial Orthop.* 2009;136(6):770.e1-11.
9. Hassan AH, Al-Fraidi AA, Al-Saeed SH. Corticotomy-assisted orthodontic treatment: review. *Open Dent J.* 2010;4:159-64
10. Baloul SS, Gerstenfeld LC, Morgan EF, Carvalho RS, Van Dyke TE, Kantarci A. Mechanism of action and morphologic changes in the alveolar bone in response to selective alveolar decortication-facilitated tooth movement. *Am J Orthod Dentofacial Orthop.* 2011;139(4 Suppl):S83-101.
11. Cano J, Campo J, Bonilla E, Colmenero C. Corticotomy-assisted orthodontics. *J Clin Exp Dent.* 2012;4(1):e54-9.
12. Cruz DR, Kohara EK, Ribeiro MS, Wetter NU. Effects of low-intensity laser therapy on the orthodontic movement velocity of human teeth: a preliminary study. *Lasers Surg Med.* 2004;35:117-120.
13. Yamaguchi M, Hayashi M, Fujita S. Low-energy laser irradiation facilitates the velocity of tooth movement and the expressions of matrix metalloproteinase-9, cathepsin K, and alpha(v) beta(3) integrin in rats. *Eur J Orthod.* 2010;32:131-139.
14. Nishimura M, Chiba M, Ohashi T. Periodontal tissue activation by vibration: Intermittent stimulation by resonance vibration accelerates experimental tooth movement in rats. *Am J Orthod Dentofacial Orthop.* 2008;133:572-583.

15. Showkatbakhsh R, Jamilian A, Showkatbakhsh M. The effect of pulsed electromagnetic fields on the acceleration of tooth movement. *World J Orthod.* 201;11:e52-e56.
16. Kim DH, Park YG, Kang SG. The effects of electrical current from a micro-electrical device on tooth movement. *Korean J Orthod.* 2008;38:337-346.
17. Liou EJ, Huang CS. Rapid canine retraction through distraction of the periodontal ligament. *Am J Orthod Dentofacial Orthop.* 1998;114:372-82.
18. Sayin S, Bengi AO, Gurton AU, Ortakoglu K. Rapid canine distalization using distraction of the periodontal ligament. a preliminary clinical validation of the original technique. *Angle Orthod.* 2004;74:304-315.
19. Iseri H, Kisinisci R, Bzizi N, Tuz H. Rapid canine retraction and orthodontic treatment with dentoalveolar distraction osteogenesis. *Am J Orthod Dentofacial Orthop.* 2005;127:533-541.
20. Iglesias-Linares A, Moreno-Fernandez AM, Yañez-Vico R, Mendoza-Mendoza A, Gonzalez-Moles M, Solano-Reina E. The use of gene therapy vs. corticotomy surgery in accelerating orthodontic tooth movement. *Orthod Craniofac Res.* 2001;14(3):138-48.
21. Kanzaki H, Chiba M, Arai K, Takahashi I, Haruyama N, Nishimura M, Mitani H. Local RANKL gene transfer to the periodontal tissues accelerates orthodontic tooth movement. *Gene Ther.* 2006;13(8):678-85.
22. Long H, Pyakurel U, Wang Y, Liao L, Zhou Y, Lai W. Interventions for accelerating orthodontic tooth movement. *Angle Orthod.* 2013;83(1):164-171.

Chapter 2 Literature Review

2.1 Orthodontic Tooth Movement:

Orthodontic tooth movement (OTM) occurs through controlled application of mechanical forces on teeth and surrounding biologic tissues.¹ Three phases delineate tooth movement; the first phase leads to displacement of the tooth within the periodontal ligament followed by a lag phase where no tooth movement occurs and a linear phase of continuous tooth movement with the application of light continuous forces.² During the initial phase, stresses on the tooth lead to compression of collagen fibers of the periodontal ligament (PDL) and increase in cellular activity on the compression side. Compression of PDL results in avascular necrosis and leads to resorption under the influence of macrophages and inflammatory cytokines thus facilitating the initial tooth displacement within the alveolar socket.³ Further tooth movement occurs by osteoclast recruitment at the bone-PDL interface⁴ and activation of RANK/RANKL/OPG axis⁵ resulting in alveolar bone resorption on the compression side and formation on the tension side. Early markers of tooth movement are indeed secreted by the PDL cells by active increase in RANKL protein as early as 3 hours after force application on the compression side⁶ followed by increase in nitric oxide synthase production by the PDL cells⁷ as opposed to the previous knowledge that cells involved in tooth movement are actually recruited by the osteocytes within the bone matrix⁸. Interestingly, Brooks et al.⁶ showed KI-67-positive cell increase in the areas of PDL compression more than in areas of tension. The lag phase usually starts around the 3rd day until the 10th day of OTM during which the hyalinized and necrotic area in the PDL is removed by phagocytic cells such as macrophages, foreign body giant cells and osteoclasts.⁹

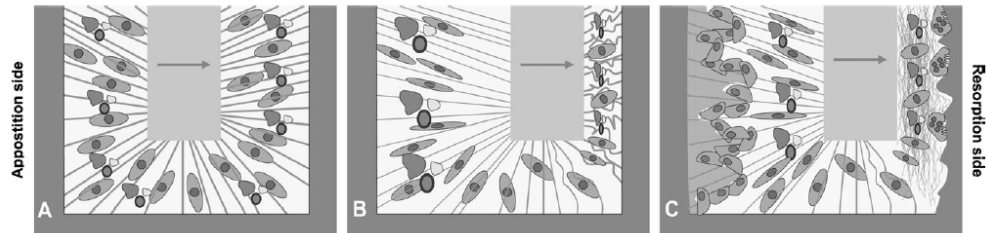


Figure 2-1. Schematic drawing of a tooth, the periodontal ligament with cells and alveolar bone. (a) An external force is applied (arrow). (b) At the apposition side, fibers are stretched. Compression of fibers takes place at the resorption side. (c) After prolonged force application, bone formation by the osteoblasts can be found at the apposition side and osteoclasts resorb the bone at the resorption side.¹⁰

2.2 *Biology of OTM:*

Numerous extensive reviews have been published on the biology of orthodontic tooth movement.^{10,11,12,13} Mechanical forces on the tooth evoke a biologic response in the surrounding paradental tissues including the gingival, PDL, alveolar bone, cellular elements, neural elements etc. and all act in unison to facilitate tooth movement. Stress on the teeth to be moved initially results in increase in strains in the PDL causing fluid flow within the PDL. This increase in strain rate leads to relaxation of stresses on the compression side and increase in stresses on the tension side.¹⁰ The strain depends on the material properties of the PDL and the type of stress applied. This stress distribution leads to viscoelastic changes in the PDL thus triggering the early events of orthodontic tooth movement.¹⁰ Once the initial changes occur in the PDL, the external forces leads to changes in the fluid flow causing shear stress within the surrounding alveolar bone brought about by the canaliculi connecting the osteocytes. It has been shown that the increase in fluid flow within the canaliculi lead to increase recruitment of cells of osteoblastic lineage on the apposition side resulting in matrix deposition, whereas folding of the PDL on the compression side leads to, for reasons unknown decrease in a fluid flow within the canaliculi of the alveolar

bone. This decrease in fluid flow actually leads to apoptosis of the osteocytes thereby recruiting osteoclasts to the area and facilitating bone resorption. The cells in the parodontal tissues act as mechanosensors, and mechanical stimuli can trigger numerous mechanosensors, thus transmitting signals for further downstream cellular events. According to tensigrity model of Ingber, the cells have physiological pre-existing tensile stress; and a stiffer cytoskeleton with an internal stress would sense the mechanical stimuli better than a relaxed cytoskeleton. Cell-adhesion molecules in the cytoskeleton transmit these external stresses into the cell cytoplasm and then to the nucleus thereby converting mechanical stimuli to biochemical and/or electrical stimuli. Signal transduction occurs in the nucleus with release of information back to cytoplasm of the cell involved and then to the extracellular matrix. The outcome of the entire chain of events leads to inflammatory response, cell death/apoptosis, recruitment, proliferation, migration and matrix deposition orchestrating the events of orthodontic tooth movement. These mechanosensing events in the cells involved and inflammatory events of tissue remodeling can be accelerated or retarded by various physical, chemical, pharmaceutical, physiological and surgical stimuli, thereby controlling the rate of orthodontic tooth movement.

2.3 *Animal Model of OTM*

Experimental studies of orthodontic tooth movement have been performed using different animal models including rats, mice, rabbits, dogs, cats, and pigs; but most of the studies have been on rats due to the lower costs associated with breeding and maintenance. One of the important considerations in a rat model is that there are morphological and physiological differences between rat and human alveolar bone and PDL.¹⁴ The alveolar bone in rats is denser than that in humans, lacking osteons and marrow spaces.¹⁴ Current rat models of orthodontic tooth

movement (for molar mesialization) utilize the maxillary incisors for anchorage and employ a NiTi closed coil spring attached to the molar tooth to deliver a specific magnitude of force.¹⁵⁻¹⁹ This model has advantages of easy accessibility to secure the appliance, but has several disadvantages including; decrease in normal eruption process of incisor,²⁰ loss of pulp vitality in the incisor^{17,19,20} and changes in force vector as a result of continuous incisor eruption that is unique to rats, with subsequent loss of anchorage.¹⁴ Hence, it would be advantageous to develop a stable anchorage device that is easily inserted, provides stable anchorage and maintains a constant force delivery without the undesirable side effects mentioned.

2.4 *TSAD Anchorage in OTM*

Mini-implants have been used extensively as stable anchorage devices, to achieve predictable tooth movement.^{21,22,23} The advantages of mini-implants include enhanced anchorage options, reducing patient compliance in the wear of removable appliances or elastics and increase in treatment possibilities.²⁴ For a mini-implant to be successful in any application, primary stability of the implant in the bone is critical.²⁵ That depends upon the bone quality, implant design and preparation of the implant site.²⁶ Insertion torque is considered to be the single main factor affecting the primary stability and excessive insertion torques and pre-drilling force²⁷ along with varying insertion angle²⁸ have been shown to cause implant failure.^{29,30} Although there are numerous commercial systems available for use in humans, mini-implants remain too large for application to the rat, as they are not small enough to place in critical locations, especially in between roots and in palatal bone without compromising deeper anatomical structures (such as the nasal turbinaires). An alternative approach is to use micro-implants, as they can be placed in

practically any location and are similar to the ones used for osteotomy fixation during orthognathic surgery and facial reconstructions.³¹⁻³³

In the current study, we used a Stryker titanium micro-implant (1.2 x 3 mm in diameter) because of its smaller size and ready availability. We followed on from the work of Viera-Negron (2008), who placed micro-implant in the rat maxillary bone and investigated implant stability with bisphosphonate treatment.³⁴ However, our study is the first to use a Stryker titanium micro-implant in rat maxillary bone as an anchor to facilitate orthodontic tooth movement. The only other study available in literature using a mini-screw for tooth movement in a rat model lacks evidence as it did not clearly discuss the use of mini-screw an anchorage device.¹⁴⁴ In order for the micro-implant to withstand forces of magnitude large enough to cause tooth movement, it would likely result in loading of surrounding cortical and cancellous bone in which it is inserted. The effect of micro-implant placement and anchorage during subsequent tooth movement upon the surrounding alveolar bone has not been studied extensively and the influence of those stresses on bone remodeling remains unanswered. Thus, we chose to employ Finite Element Method (FEM) as a tool to define stress concentrations on the surrounding bone during post insertion anchorage for tooth movement.

2.5 *Finite Element Analysis of TSAD Anchorage*

FEM is a numerical method of analyzing stresses and deformations in any structure of a given geometry. The geometry of the structure (precise or imprecise) is discretized into so called “finite elements” connected to each other by nodes. The type, arrangement and total number of elements affect the accuracy of the result. FEM has become the most used computational and analysis tool since 1960’s and was first used in implant dentistry in 1976.³⁵ It is postulated that

an implant inserted into alveolar bone, changes the local stress state of the bone and induces an adaptive phenomena. Stress distribution depends on many assumptions including, geometry of the model studied, material properties of the bone and the implant, boundary conditions and load applied; along with contact status between the implant and surrounding cortical bone using a carefully planned algorithm.³⁶ Currently, with the advent of advanced imaging techniques and improvement in mathematical computation methods, a precise geometric representation of the actual model can be considered along with the anisotropic and non-homogenous nature of the materials for near accurate results.³⁷ The geometry of the bone-implant interface has well-defined stress concentration areas and FEM can predict those areas for better treatment planning. Furthermore, this simulation can subsequently be validated *in vivo*, using an experimental model of tooth movement.

2.6 *Drugs in OTM*

Orthodontic treatment is primarily undertaken in adolescents, but, there is a growing number of adult patients seeking orthodontic treatment,³⁸⁻⁴⁰ (10-45% of any orthodontic practice patients are adults) Many of these adults have some sort of pharmacological intervention for a systemic and/or a local health problem, and drugs are used in adolescents too for treatment of systemic illness. These medications can affect the dental and paradental tissues like any other cell/tissue in the body.⁴¹ Despite the clinical precision of orthodontic mechanics to facilitate the required tooth movement, drugs aimed at targeting the skeletal, immune, vascular systems can reach the target cells in the mechanically stressed PDL and modify the reaction of these cellular elements to the applied orthodontic force. The cellular element that is critical to OTM is the osteoclast, which in tandem with osteoblast, the bone forming cell regulate bone remodeling in the human skeleton.

Either of the cells, each govern the activity of the other as in normal remodeling or accelerated bone remodeling during OTM. Osteoclasts are polykaryotic multinucleated cells derived from the monocyte-macrophage lineage with a short life span of 10-23 days during which time they attach to the bone surface, often in depressions called Howship's lacunae in the trabecular bone or within the marrow spaces in the cortical bone. Osteoclasts resorb bone by attaching to bone surface, creating a sealed-off microenvironment between the cell and the bone surface. The sealing zone also called the clear zone occurs by attachment of cell surface receptor proteins called integrins to the bone surface. During active resorption, cell signaling within the osteoclasts occur by a process called protein prenylation that would provide the impetus for the cell surface receptor integrins to reach the surface and form the clear sealing zone. Any disturbance in this process of protein prenylation would result in lack of formation of the sealing zone thus stopping the bone resorption process by the osteoclasts. Some pharmacological agents such as bisphosphonate (BP) drugs commonly used to prevent and treat osteoporosis, a bone disease, can alter OTM when trapped in bone in sufficient concentration by preventing the protein prenylation required for survival and function of osteoclasts resulting in premature apoptosis and inhibition of bone resorption.

2.7 *Osteoporosis*

Osteoporosis (OP) is a global public health problem affecting more than 200 million people worldwide and is the fourth largest disease and number one metabolic bone disease affecting mankind. It is characterized by low bone mass and deterioration of bone micro architecture resulting in poor bone quality and can lead to fragility fractures especially of the hip, spine and wrist.^{42,43} Almost 2 million Canadians are living with osteoporosis, with 1 in 3 women and 1 in 5

men over the age of 50 being affected by the disease costing the Canadian health care system 1.9 billion dollars each year.⁴⁴ Osteoporosis is broadly classified into primary osteoporosis and secondary osteoporosis. Primary osteoporosis is sub-divided based on its occurrence in post-menopausal women around the age of 50 or senile/age-associated osteoporosis occurring in men and women above age 70. Secondary osteoporosis does occur secondary to medications, inflammatory and endocrine disorders.⁴⁵

Bone mineral density (BMD) was considered the best available indicator of osteoporosis and osteoporotic fracture risk. A T-score of -1 S.D. from the peak bone mass of normal healthy young adult was considered osteopenic, and -2.5 S.D. provided a diagnosis of osteoporosis in both males and females. DXA (Dual Energy X-ray Absorptiometry) is considered the optimal practical method to measure BMD in the clinics and the measurement from DXA was used to predict lifetime osteoporotic fracture risk which was related to peak bone mass.⁴⁶ Although the prevalence of osteoporosis in Canada is 6%, the population at increased risk of fracture may be larger when additional risk factors such as age, ethnicity, family history, alcohol, smoking, steroid use and menopause were included.⁴⁷ 80% of fractures in people above the age of 50 are associated with osteoporosis. Osteoporotic patients have a 45% and a 20% lifetime risk of developing fractures in women and men respectively.⁴⁸ Evidence of presence of osteoporotic fracture is a major risk factor for subsequent fractures irrespective of bone mineral density and should be diagnosed effectively.⁴⁹⁻⁵¹ Even though 20% of patients experience a new fracture within 1 year of a fracture occurrence⁵² prevalent vertebral fractures are largely under-recognized by both radiologists and general internists with a diagnosing rate of only 46%⁵³ and 60%.⁵⁴ Hence there is greater need for educating the physicians in identifying fractures on chest and lumbar spine radiographs and treating them.⁵³ The 2010 clinical practice guidelines for the

diagnosis and management of osteoporosis in Canada acknowledge that there is a huge care gap and indicates that “Despite the high prevalence of fragility fractures in the Canadian population and the knowledge that fracture predicts future fractures, fewer than 20% of women and 10% of men receive therapies to prevent further fractures.”⁵⁵

Pharmacologic intervention should be aimed at patients with high absolute fracture risk. Although daily exercise improves the quality of life and calcium and vitamin D supplements helped increased bone mass in osteoporotic patients, the level of evidence to prevent osteoporotic fractures was lacking.^{56,57} It is still recommended to use calcium and vitamin D supplements and the dose was highly related to absolute risk of developing fractures.⁵⁸ The most common pharmacological therapeutic agents in Canada are antiresorptive (bisphosphonates, RANKL inhibitor, SERMs, HRT and calcitonin) agents and anabolic (teriparatide) agents and each have shown to effectively reduce fracture risk in osteoporosis patients. HRT can be used if osteoporotic patients have associated vasomotor symptoms. Bisphosphonates (alendronate, risedronate and zoledronate) can be used as first line of therapy for osteoporotic men in the prevention of vertebral, non-vertebral and hip fractures.⁵⁵ Recent evaluation of the absolute risk of developing fracture with a T score of -1 was 10.9%⁶⁰ compared to 5.7%⁶¹ probably due to inclusion of HRT treated healthy women cohort by Kanis et al. group. The bisphosphonates (BPs) are a simple small molecule family of drugs. They specifically adhere to bone surfaces, which is their ultimate site of action. Osteoclast cells that degrade the bone surface coated with BP will consume a toxic amount of the drug, and bone resorption will cease. BPs inhibits osteoclast-mediated bone resorption by several routes, most of which involve inactivation of osteoclast cell function.^{62,63} BPs have become the first line drug therapy for conditions of excessive osteoclast activity leading to low bone mass, notably, Osteoporosis and Paget’s disease. They are also used to

treat patients with Rheumatoid Arthritis, Ankylosing Spondylarthropathies, Osteogenesis Imperfecta, and osteopenic bone disease secondary to prescription drug use.^{64,65} Clearly, a great proportion of middle aged individuals in our current society will be exposed to BP drug therapy, and will resultantly incorporate and trap BP drug in the mineral phase of alveolar bone. Due to the low turnover rate of BP-laden bone, that bone burden of BP drug may well interfere with subsequent attempts at OTM and dental procedures in general, retarding bone remodelling and prolonging OTM treatment duration.

2.8 Bisphosphonates

2.8.1 History and classification:

Bisphosphonates are non-hydrolyzable analogues of pyrophosphate and were synthesized in the 19th century by German chemists. They are structurally similar to inorganic pyrophosphates. Inorganic pyrophosphate has high binding affinity to calcium crystals and impairs their formation and dissolution in vitro and inhibits pathological calcification in vivo. Rapid metabolism of pyrophosphates has led to new class of drugs called bisphosphonates that resemble pyrophosphate, but are resistant to biological degradation. Bisphosphonates are very poorly absorbed by the intestine when given orally as only 1% of the drug is absorbed and rest is eliminated unchanged in the urine. 50% of the drug that is absorbed gets selectively adsorbed on to the bone surface attaching to the hydroxyapatite crystals in the areas of active bone remodeling. Most treatment regimes of bisphosphonates for Osteoporosis are based on pharmacodynamic properties as there is lack of data based on pharmacokinetic properties due to challenges in accurately determining concentrations in serum and urine.

Bisphosphonates are divided into nitrogen and non-nitrogen containing bisphosphonates and their structure is provided below. (Fig1.) In all bisphosphonates, the oxygen atom that forms the P-O-P bond in pyrophosphate is replaced by carbon atom and forms a P-C-P bond. The P-C-P bond resists biological degradation and gives a stable structure for pharmacological properties and mechanism of action. Bisphosphonates also have two additional side-chains termed R1 and R2 attached to central carbon atom. Hydroxyl substitution at R1 enhances the affinity of BPs for calcium crystals, while the presence of nitrogen atom in R2 enhances their potency and determines their mechanism of action.⁶⁶

2.8.2 Mechanism of Action:

Bisphosphonates (BP) are taken up by the skeleton, at active remodeling sites, and bind strongly to the mineral. Hydroxyl substitution at R1 site, increases the binding affinity of BPs due to tridentate binding of OH substituted BP to calcium ions. BP with a different R1 substitution like Cl^- or H^+ will have significantly lower binding affinities as in clodronate and tiludronate. Nancollas et al.⁶⁷ compared the binding affinities of various BPs to bone using the potentiostatic method and ranked the BPs on the basis of highest binding affinities to lowest as follows: zolendronate > alendronate > ibandronate > risendronate > etidronate > clodronate. Although the binding affinity of BPs to bone was established, it did not substantiate the anti-resorptive properties of BPs. Studies showed that BPs that were bound to bone were released in the presence of acidic environment in the resorption lacunae during active bone turnover and are ingested by osteoclasts by fluid-phase endocytosis.

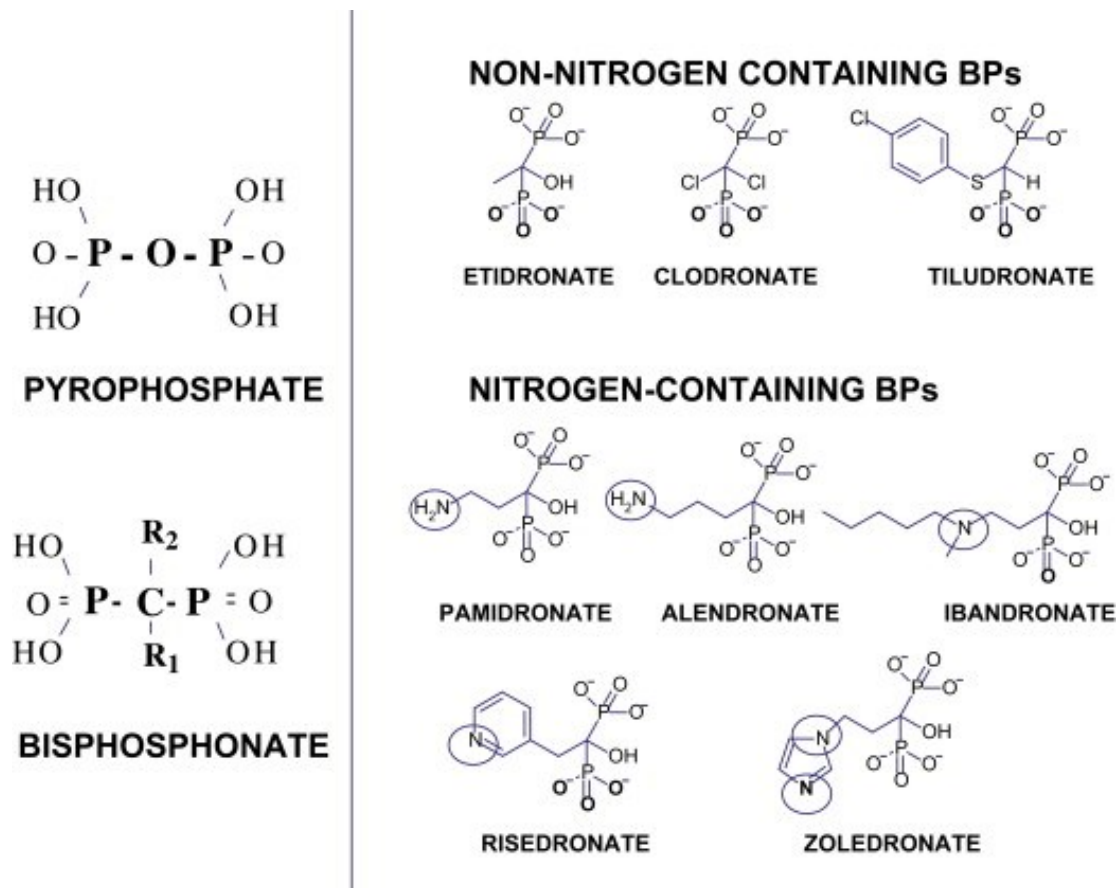


Figure 2-2. Chemical structure of common bisphosphonates⁶⁶

The type of uptake and action on osteoclasts is different for nitrogen and non-nitrogen containing bisphosphonates. While non-nitrogen bisphosphonates act by incorporating into ATP and causing cell apoptosis, nitrogen BPs induce changes in the cytoskeleton of osteoclasts such as loss of ruffled border, disruption of actin rings and altered vascular trafficking and ultimately leading cellular apoptosis.⁶⁶

Bisphosphonate mechanism of action is by inhibiting the Farnesyl pyrophosphate synthase. (FPPS) This is accomplished by inhibiting osteoclast action. Farnesyl pyrophosphate synthase (FPPS), an enzyme of the mevalonate biosynthetic pathway, plays a role in the synthesis of

cholesterol and other sterols. FPPS forms isoprenoid metabolites required for the prenylation of small GTPases that are important for the survival of osteoclasts. The action is mainly due to accumulation of unprenylated GTPases rather than loss of prenylated proteins. Small GTPases such as Rac, Ras, Rho are signaling proteins, that, when activated, positively regulate several structural properties and processes important for osteoclast function, including morphology, cytoskeletal arrangement, vesicular trafficking and membrane ruffling. Vesicular trafficking in osteoclasts is responsible for concentrating and transporting enzymes involved in bone resorption. The key aspect in the structure of various BPs is the orientation of nitrogen atom relative to the phosphate group in the hydroxyapatite crystals that explains the differences in the anti-resorptive properties.⁶⁸

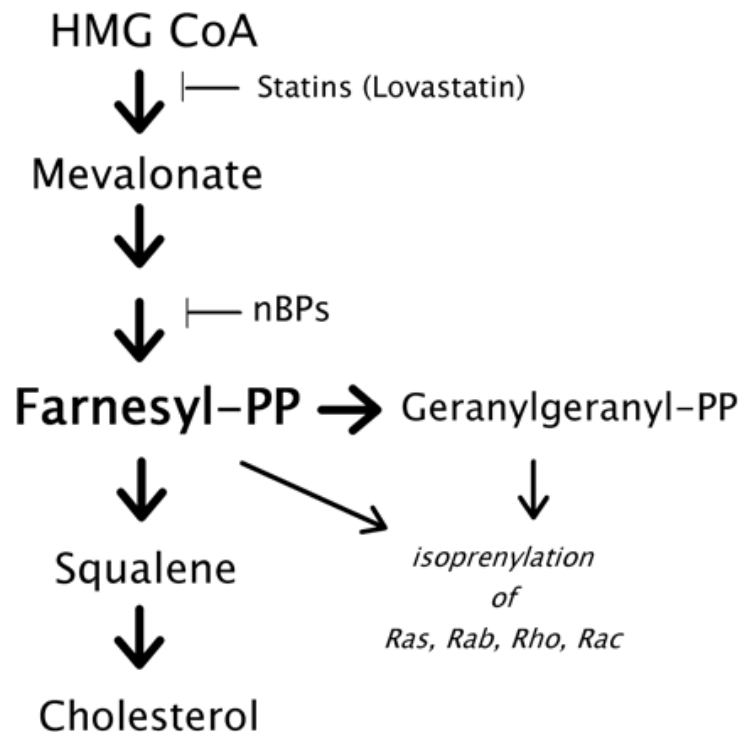


Figure 2-3. Mechanism of action of bisphosphonates⁶⁹

Another mechanism of action where the bisphosphonates form metabolites is by inhibition of FPPS which leads to accumulation of isopentenyl pyrophosphate (IPP) in turn reacts with AMP, leading to production of new metabolite, Apppl, which induces osteoclast apoptosis.⁶⁶

In conclusion, BPs inhibit FPP in three different ways:

1. At low concentration, fundamental activities of the cytoskeleton such as vesicular trafficking and membrane ruffling are inhibited.
2. At higher concentration, osteoclast differentiation is inhibited.
3. At concentration of 100 μ M which is relatively very high concentration, osteoclast apoptosis is induced.

2.8.3 Pharmacokinetic/Pharmacodynamic profile of bisphosphonates:

Bisphosphonates have a unique pharmacokinetic profile in that once they enter the circulation they are rapidly excreted by the kidneys and are not metabolized by the body enzymes. Hence recently bisphosphonates have been conjugated with various polymers to improve their absorption and bioavailability and to create active metabolites. Bisphosphonates absorbed into the human body is partitioned between the skeleton and kidneys. Whether given intravenously or orally, bisphosphonates are eliminated quickly from the circulation, independent of the agent. The portion reaching the kidneys is eliminated through the urine, unmetabolized within a few hours. The remainder, also unmetabolized, is deposited in the skeleton. Only a small percent 0.6% is attracted by the skeleton and its uptake by the skeletal tissues is dependent on renal function, prevalence rate of bone turnover, and the affinity of the specific BP for bone mineral.

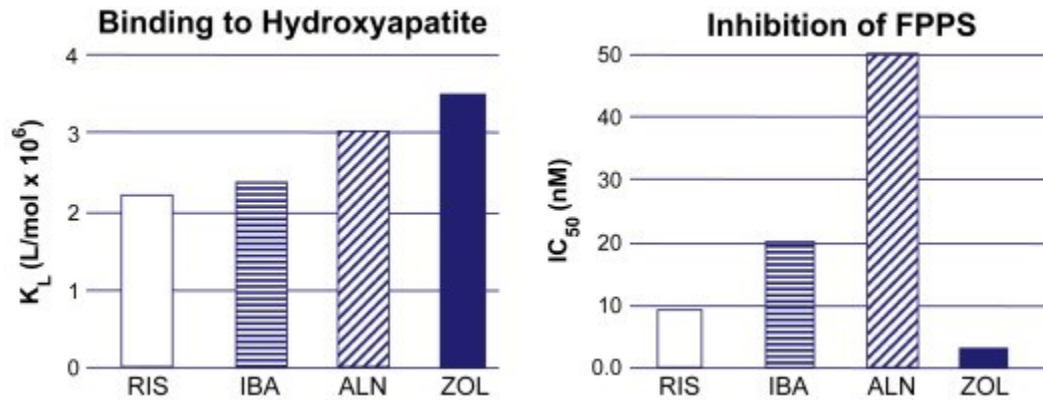


Figure 2-4. Binding affinities and inhibition of FPPS of four different types of bisphosphonates⁶⁶

Numerous bone binding sites are available for bisphosphonate binding and sites will not practically be saturated by the dose level of BPs given for osteoporosis which is 70mg/weekly for treatment and 35mg/weekly for prevention of osteoporosis by alendronate, a common nitrogen containing bisphosphonate. The nBP deposited at the resting surface is bound loosely. The surface-to-fluid concentration gradient equilibrium favors net movement of nBP from the resting surface into the body fluids and then into blood, into which the nBP is eventually recycled. The removal of BP's occurs within days to weeks, with essentially full removal from resorbing surfaces and liberation to the blood, from where the nBP is recycled again across the kidney and skeleton as before. The first measurable effect of BP treatment is the decrease in the rate of bone resorption followed by a slower decrease in the rate of bone formation due to coupling of the two processes and synthesis of a new steady state of lower rate of bone turnover. The rate is maintained for the whole duration of 10 years for most bisphosphonates.⁶⁹

Pharmacokinetic studies are best evaluated by measuring the skeletal half-life of any drug and for bisphosphonates too. Alendronate has a skeletal half-life of 10.9 years, although most of the pharmacokinetic studies involving bisphosphonates were done only for a month which will not

provide us with a true appreciation of skeletal retention of bisphosphonates. These one month studies, although short, do not give true appreciation of retention rates. However they give us an insight into long-term retention of BPs and show that all BPs have similar retention rates but differ in the long-term suppression of bone remodeling which is an important parameter in assessing the clinical efficacy of bisphosphonates.⁶²

Christiansen et al. (2003) did a comparative study of labeled alendronate 70 mg once-weekly or risedronate 35 mg once-weekly and found that at 24 h retention was 54.5% and 51% and 51.8% and 45.5% at 72 h and 45.9% and 33.8% at 27 days for alendronate and risedronate respectively. The release of BPs from the bone is very slow and another study showed pamidronate was detected in urine of young patients up to 8.5 years after cessation of treatment.⁷⁰

Pharmacodynamic results of BP's long term effect on bone showed that BPs have a gradual increase in biochemical markers of bone turnover after cessation of treatment, but the markers did not reach the pre treatment levels. Also it can be hypothesized that resumption of bone remodeling after stopping treatment with BPs leads to release of resident BPs in to active turnover surface there by leading to further decrease in bone resorption and consequently maintaining bone mass and increased BMD. Speed of reversal of the effect of all BPs on bone following cessation of treatment is slow and is dependent on the rate of bone turnover as in normal remodeling or accelerated remodeling of OTM and is different from other anti-resorptive treatments such as estrogens and raloxifene.⁷¹

In summary, BP administration leads to a large portion reaching the skeleton, initially deposited at the resting and resorbing surface, is recycled and released within days into the blood for

excretion through the kidney and redistribution across the bone surfaces. BP is secured in bone tissue at sites of formation, released when osteoclasts resorb bone in that region. Bone buried BPs even when released do not exert anti-resorptive properties and most of the resorption is facilitated by newly dosed BPs and the effect on bone-buried BPs only comes into play when high doses of BPs given in cases of IV administration leads to increased retention in bone which when released will be substantial enough to cause bone resorption than at lower doses.

2.8.4 Concerns with current pharmacokinetic profile of bisphosphonates:

Most of the published pharmacokinetic studies on bisphosphonates do not coincide with the actual pharmacokinetics of patients with bisphosphonates. Studies have shown that the turn-over rate of BP treated skeleton is 3 times higher than non-BP treated one. Again BP treated skeleton has less sites of bone formation than non-BP and the bone:kidney BP ratio of distribution is significantly lower in BP treated skeleton than non-BP skeleton. So if the current pharmacokinetic studies are true then the rate at which the BP is distributed and accumulated, the bone resorption rate will continue to decline indefinitely, but the known fact is bone resorption rate declines 70% in the first three months, then never goes any lower.⁷²

The pharmacokinetic challenges of patients on long-term oral BPs are as follows:

1. BPs are a type of metabolic auto-inducer; that is, their own pharmacodynamic effects influence both their skeletal distribution and retention. This is very commonly observed in drug pharmacokinetics where the drug influences an enzyme in its metabolic pathway that is responsible for its breakdown. BPs uniquely influence their half-life by changing the deposition pattern and release rates.

2. A single efficacious dose of BPs is not sufficient enough to assay and determine the half-life and most studies in order to evaluate this had given BPs doses that were much higher than efficacious doses and showed more anti-resorptive action than observed by if regular doses of alendronate (70mg/week) for osteoporosis treatment were given.
3. The collection and retention of BPs is not constant with 70-80% within first few days especially at the trabecular and endocortical surfaces and the rest from newly dosed BPs.⁶⁹

2.8.5 Metabolites of bisphosphonates:

Early non-nitrogen bisphosphonates studies done on amoebae showed that mammalian cells convert bisphosphonates and metabolizes them into methylene-containing (AppCp type) analogues of ATP. These AppCp-type metabolites accumulate to high concentrations in the cytosol of osteoclasts and other cell types that can effectively internalize bisphosphonates. AppCCl₂p metabolite of clodronate accumulation in osteoclasts *in vitro* inhibits bone resorption. This is done by inducing osteoclast apoptosis, by inhibiting ATP-dependent enzymes, such as the adenine nucleotide translocase, a component of the mitochondrial permeability transition pore. Induction of osteoclast apoptosis seems to be the primary mechanism by which the simple bisphosphonates inhibit bone resorption because the ability of clodronate and etidronate to inhibit resorption *in vitro* can be overcome when osteoclast apoptosis is prevented using a caspase inhibitor.⁷¹

Nitrogen bisphosphonates as mentioned before prevent FPPS and its downstream metabolite geranylgeranyl diphosphate. These isoprenoid lipids are the building blocks for the production of

a variety of metabolites, such as dolichol and ubiquinone, but are also required for post-translational modification (prenylation) of proteins, including small GTPases such as Rac, Rho and Ras. Risedronate almost completely inhibits protein prenylation in J774 cells at a concentration of 10 $\mu\text{mol/L}$, which is similar to the concentration that affects osteoclast viability *in vitro* and has been predicted to be achieved within the osteoclast resorption lacuna *in vivo*. Similar results were obtained by studies done on zoledronate. The inhibitory effect of N-BPs on the mevalonate pathway can be shown by detecting accumulation of the unprenylated form of the small GTPase Rap1A, which acts as a surrogate marker for inhibition of FPP synthase and which accumulates in cells exposed to N-BPs.⁷¹

2.8.6 Pharmacogenetics of bisphosphonates:

Genetic factors play an important role in drug metabolism and action. Pharmacogenetics also play a vital role in bisphosphonate related treatment of osteoporosis. Palomba et al. showed that patients on alendronate and hormone replacement therapy (HRT) treatments, the b allele of the VDR BsmI polymorphism exhibited a greater increase in BMD than those carriers of the B allele. However, by contrast, those patients on raloxifene the B allele carriers had a greater increase in BMD than the b allele carriers. As a result of these opposing effects, among those on combined alendronate and raloxifene, there was no significant association between VDR polymorphisms and BMD change. These results strongly support the concept of an interaction between VDR polymorphisms and antiresorptive drug therapies in BMD change.

Polymorphism of the collagen I alpha 1 (COL1A1) gene has also been shown to be associated with response to anti osteoporosis therapy in terms of BMD change. In a study on 108

perimenopausal women with osteopenia, randomized to receive either cyclical etidronate (a bisphosphonate drug) or placebo, femoral neck BMD was increased in carriers of the Sp1 (dbSNP rs1800012) SS genotype (~64% in the population) but was decreased in those carrying the s allele (Ss and ss genotypes). Individuals with the SS genotype required a higher subcutaneous dose than those with the ss genotype.

The risk of bisphosphonate-related ONJ has also been associated with genetic factors. In a study on 22 cases of ONJ and 65 age-matched controls, screening of more than 500 000 SNPs, the authors found four SNPs (rs1934951, rs1934980, rs1341162, and rs17110453) mapped within the cytochrome P450-2C gene (CYP2C8) to be associated with risk of ONJ. The relative risk of ONJ associated with each of the SNPs ranged between 10 and 13.⁷³

2.8.7 Excretion of Bisphosphonates:

Bisphosphonates are excreted by the kidney both by glomerular filtration and by proximal tubular secretion. As such, bisphosphonates should not be administered in patients with severe renal disease such as stage 4-5 chronic renal disease with GFR rates of <30-35 mL/min. Most of this data is obtained from rat studies on from patients on IV bisphosphonates. In spite of its toxic effects studies have shown that the safety and efficacy of risedronate and alendronate for 2-3 years in chronic renal disease patients warrants their use. In stage 5 chronic renal failure patients use of bisphosphonates should only be considered after carefully evaluating the bone condition, if it's due to osteoporosis or any other bone disorders such as renal osteodystrophy. IV bisphosphonates should be used with caution although they have been used in patients with diabetes, hypertension and renal disease. Caution should be in that the infusion rates should be

slow in these patients when using zoledronate or ibandronate, although no head to head studies have been done to prove that.⁷⁴

2.9. Bisphosphonates and osteonecrosis of the jaw

Long term bisphosphonate use has been associated with among many adverse effects such as osteonecrosis of the jaw (ONJ). ONJ occurs when there is stripping of the oral mucosa in any area of the jaws leading to exposure of the bone which in turn results in delayed healing and bone necrosis.⁷⁵ This significant complication was first reported in 2003 by Marx et al.⁷⁶ who described an intraoral lesion of exposed bone in individuals on bisphosphonate therapy. This was followed by many case reports and case series showing evidence of exposed bone and associated osteonecrosis isolated to the jaw.^{75, 77, 78, 79, 80, 81} Finally, in 2007, a task force by American association of bone and mineral research (ASBMR)⁸² and American Association of Oral and Maxillofacial surgeons (AAMOS)⁸³ put forth a clinical definition of ONJ and updated in 2009.⁸⁴ They adopted a universal acronym for this entity: Bisphosphonate-Related Osteonecrosis of the Jaw (BRONJ) and mentioned three characteristics that should be present to consider a lesion to be BRONJ related as quoted in Ruggiero⁸⁵ :

1. Current or previous treatment with a bisphosphonate.
2. Exposed, necrotic bone in the maxillofacial region that has persisted for more than eight weeks.
3. No history of radiation therapy of the jaws.

Various working hypothesis have been proposed to describe this disease process. The most common one proposed involves profound inhibition of osteoclast function due to their ability to be internalized by the osteoclasts and affect the melavonate pathway causing premature

apoptosis of the osteoclasts rendering them inactive,⁶² followed by any insult to the bone such as mechanical trauma from dental extractions, implant placement to the alveolar bone; which eventually leads to local micro damage that cannot be repaired due to non-functioning osteoclasts that in turn leads to bone necrosis.⁸⁶ Other theories include, local micro trauma to the area, which releases enough bisphosphonates that are laden in the bone, to a point that it causes toxicity to the adjacent oral mucosa leading to mucosal fenestration and ultimately bone exposure which is the hallmark of BRONJ.⁸⁷ Various risk factors have been identified by many researchers to cause this bone necrosis and quoted by Ruggiero.⁸⁵ They include a history of dentoalveolar trauma, duration of bisphosphonate exposure,⁸⁸ type of bisphosphonate used,⁸⁹ and history of inflammatory dental disease like periodontal or alveolar abscess, implant placement.⁷⁵ Current incidence of BRONJ ranges from 0.8% to 12% in North America,⁸⁴ 1.7% to 15% in Europe⁸⁹⁻⁹³ for cancer therapy using IV bisphosphonates. The incidence of ONJ in breast cancer is lower than in multiple myeloma.⁹⁴ In Australia the incidence was 0.01-0.04% and 0.09-0.34% using oral bisphosphonates without or with extraction therapy respectively.⁹⁵

A clinical staging system was developed by Ruggiero in 2006⁹⁶ and updated by AAOMS in 2009⁸⁴ and was divided into 5 categories as quoted by Ruggiero (2011)⁸⁵ and presented below

At risk Category	No apparent exposed/necrotic bone in patients who have been treated with either oral or IV bisphosphonates
Stage 0	Nonspecific clinical findings and symptoms such as jaw pain or osteosclerosis but no clinical evidence of exposed bone
Stage 1	Exposed/necrotic bone in patients who are asymptomatic and have no evidence of

	infection
Stage 2	Exposed/necrotic bone associated with infection as evidenced by pain and erythema in the region of the exposed bone with or without purulent drainage
Stage 3	Exposed/necrotic bone in patients with pain, infection, and one or more of following: pathologic fracture, extra-oral fistula, or osteolysis extending to the inferior border or sinus floor

Several animal models of BRONJ have been studied to have a better understanding of the disease process for effective treatment strategies. Although BRONJ lesion typically should have exposed bone for 8 weeks as described by the AAOMS⁸³ and ASBMR⁸² task force; accurate diagnosis of the disease in animals is difficult due to lack of subjective symptomatic data and evidence of non-exposed variant of the disease in humans.⁹⁷ So studies on bisphosphonate induced ONJ in animals should demonstrate radiologic and histological evidence of bone and soft tissue necrosis. Radiographic presentation includes sequestration as evidenced by irregular radiopacity surrounded by erosive radiolucent zone,^{98,99} periosteal bone deposition, alveolar bone expansion,⁹⁹ severe bone loss, osteolytic areas around the bone defects. Histological features of BRONJ like lesions in an animal model is shown to have evidence of increase in bone density, reduced vascular spaces,¹⁰⁰⁻¹⁰³ increased fibrosis, presence of devitalized bone that is devoid of typical bone cells^{100, 104} necrotic sequestered bone with loss of osteocytes from the lacunae as evidenced by basic fuschin staining and confocal microscopy,^{86,98,99,102,104-107} apoptotic cells, severe bone loss/resorption,^{99,101,106,107} decreased rate of mineral apposition as shown by tetracycline and alizarin red staining, mucosal ulceration with incomplete epithelial healing with

inflammatory cell infiltrate,^{98,99,101,102,106,108} and evidence of bacterial infiltration especially with *Actinomyces* species.¹⁰³

2.10. Bisphosphonates and OTM

Despite the efficacy of clinical orthodontics, drugs can play a role in OTM and can have a profound short term and long term effect on the outcome of OTM. Earlier studies on the role of bisphosphonates in orthodontics were very promising. Due to its potential role in preventing bone resorption, the focus was to apply this concept to prevent undesirable movement of the anchor teeth or to prevent relapse following tooth movement. BP drugs with concurrent dosing systemically or locally during OTM has shown to inhibit orthodontic tooth movement.^{15,109-114} Igarashi (1994)¹¹³ systemically administering AHuBP and Adachi (1994)¹¹⁴ locally delivering risedronate, a nitrogen containing bisphosphonate showed a dose-dependent decrease in tooth movement and prevented relapse. Altali (1996)¹¹⁵ showed that bisphosphonates inhibit formation of acellular cementum which in turn will cause more root resorption, the opposite effect of preventing bone resorption contradicted by Igarashi (1996).¹¹² Kim (1999)¹¹⁶ confirmed earlier findings of the role of bisphosphonates (pamidronate) in preventing bone resorption. Most of the studies done so far used nitrogen containing bisphosphonates but Liu (2004)¹¹⁰ showed that clodronate a non-nitrogen containing bisphosphonate also prevents bone resorption and inhibits tooth movement. Recently Karras et al. (2009)¹⁵ investigated the effect of alendronate sodium on orthodontic tooth movement and showed the decrease in tooth movement with alendronate group to be 75% less at 2 weeks in comparison to 58% less at 4 weeks.

With emerging evidence that bisphosphonates can precipitate osteonecrosis of the jaw bones in sites of active and increased bone remodeling such as in extraction sites, implant placements,

periodontal disease,⁸³ the orthodontist is faced with the dilemma of relative risk of BRONJ (Bisphosphonate Related Osteonecrosis of Jaw) occurrence in this group of patients. Although the risk of BRONJ in osteoporotic patients is rare (incidence of 0.09 to 0.38%)⁹⁵ the constant remodeling needed during OTM along with bacterial colonization in the oral cavity can be a risk for BRONJ that has not been researched upon. Furthermore, a more potent form of IV bisphosphonates are used in children to treat osteopenia, Pagets' disease, osteogenesis imperfecta, hypercalcemia of malignancy etc, and these young patients who might present to the orthodontist for treatment may have a higher risk for osteonecrosis. Previous studies show evidence of BRONJ occurrence from 6%⁸⁸ to 28%¹¹⁷ in IV bisphosphonate patients during dental treatment such as extractions and implant therapy. Hence it is imperative to investigate in more detail the effect of bisphosphonates on the jaw bones during active orthodontic treatment and associated bone remodeling.

2.11 Accelerators of OTM

The rate and amount of tooth movement is affected by the rate of bone turnover.¹¹⁸ Methods to increase the rate of bone turnover are known to accelerate tooth movement. To date, various treatment modalities have been investigated to accelerate tooth movement including; corticotomy,¹¹⁹⁻¹²³ low level laser therapy,^{124,125} mechanical vibration,¹²⁶ pulsed electromagnetic therapy,¹²⁷ electrical currents¹²⁸ and distraction osteogenesis.¹²⁹⁻¹³¹ Even biologic approach to accelerate tooth movement have been attempted through localized RANKL gene therapy.¹³² A recent systematic review by Long et al.¹³³ showed that corticotomy is an effective modality to accelerate tooth movement and is relatively safe compared to any other method.

Historically, corticotomy facilitated orthodontics was reported as early as 1893, but the technique was not popular until it was reintroduced by Köle in 1959.¹³⁴ Köle's procedure involved making vertical cuts in the cortical bone adjacent to the teeth to be moved, and by leaving the cancellous bone intact avoided the adverse effects of earlier bony block resection techniques.¹³⁴ Corticotomy is a surgical procedure to accelerate rate of orthodontic tooth movement by causing localized osteopenia and accelerated bone metabolism as a result of controlled surgical damage. Frost (1983)¹³⁵ coined the term "Regional Acceleratory Phenomenon (RAP)" to explain this tissue response. RAP is usually seen following a fracture to long bones and involves recruitment, proliferation and activation of progenitor cells necessary for wound healing. The tissue response during RAP involves decreased bone mineral density and accelerated bone turnover.¹³⁶ The sequence of events during RAP associated tissue injury include; initiation within a few days of injury, peaking at 1-2 months and effects typically lasting 4 months.^{137, 138} Many animal^{119, 138-140} and human studies¹⁴¹ have demonstrated the phenomenon of reversible osteopenia and accelerated tooth movement using corticotomy. Ren et al.¹³⁹ showed accelerated tooth movement without associated root resorption and pulpal damage in beagle dogs and Mostafa et al.¹⁴⁰ showed doubled rate of tooth movement in dogs. Wilcko patented a technique called Periodontally accelerated osteogenic orthodontics (PAOO) wherein mucoperiosteal flap is raised and osteotomy cuts in the cortical bone is performed alongside tooth roots accompanied by small perforations into the alveolar bone, and a resorbable bone graft placed to augment bone. This is followed by faster activation of orthodontic appliance with every two week intervals to accelerate tooth movement.¹⁴²

A rat model demonstrated the actual biological response to corticotmy induced tissue damage. The authors showed that the increased turnover rate in alveolar bone is a result of anabolic and

catabolic modeling which increases by third week of tissue injury with decrease to normal remodeling levels by seventh week and stabilization by eleventh week of alveolar decortication surgery.¹⁴³

2.12 References

1. Krishnan V, Davidovitch Z. Cellular, molecular, and tissue-level reactions to orthodontic force. *Am J Orthod Dentofacial Orthop* 2006;129:469 e461-432.
2. Tomizuka R, Shimizu Y, Kanetaka H, Suzuki A, Urayama S, Kikuchi M et al. Histological evaluation of the effects of initially light and gradually increasing force on orthodontic tooth movement. *Angle Orthod* 2007;77:410-416.
3. Lekic P, McCulloch CA. Periodontal ligament cell population: the central role of fibroblasts in creating a unique tissue. *Anat Rec* 1996;245:327-341.
4. Rody WJ, Jr., King GJ, Gu G. Osteoclast recruitment to sites of compression in orthodontic tooth movement. *Am J Orthod Dentofacial Orthop* 2001;120:477-489.
5. Yamaguchi M. RANK/RANKL/OPG during orthodontic tooth movement. *Orthod Craniofac Res* 2009;12:113-119.
6. Brooks PJ, Nilforoushan D, Manolson MF, Simmons CA, Gong SG. Molecular markers of early orthodontic tooth movement. *Angle Orthod* 2009;79:1108-1113.
7. Nilforoushan D, Manolson MF. Expression of nitric oxide synthases in orthodontic tooth movement. *Angle Orthod* 2009;79:502-508.
8. Vatsa A, Smit TH, Klein-Nulend J. Extracellular NO signalling from a mechanically stimulated osteocyte. *J Biomech* 2007;40 Suppl 1:S89-95.
9. Nakamura K, Sahara N, Deguchi T. Temporal changes in the distribution and number of macrophage-lineage cells in the periodontal membrane of the rat molar in response to experimental tooth movement. *Archives of Oral Biology* 2001;46:593-607.
10. Henneman S, Von den Hoff JW, Maltha JC. Mechanobiology of tooth movement. *Eur J Orthod* 2008;30:299-306.

11. Wise GE, King GJ. Mechanisms of tooth eruption and orthodontic tooth movement. *J Dent Res* 2008;87:414-434.
12. Krishnan V, Davidovitch Z. On a path to unfolding the biological mechanisms of orthodontic tooth movement. *J Dent Res* 2009;88:597-608.
13. Masella RS, Meister M. Current concepts in the biology of orthodontic tooth movement. *Am J Orthod Dentofacial Orthop* 2006;129:458-468.
14. Ren Y, Maltha JC, Kuijpers-Jagtman AM. The rat as a model for orthodontic tooth movement--a critical review and a proposed solution. *Eur J Orthod* 2004;26:483-490.
15. Karras JC, Miller JR, Hodges JS, Beyer JP, Larson BE. Effect of alendronate on orthodontic tooth movement in rats. *Am J Orthod Dentofacial Orthop* 2009;136:843-847.
16. Fujita S, Yamaguchi M, Utsunomiya T, Yamamoto H, Kasai K. Low-energy laser stimulates tooth movement velocity via expression of RANK and RANKL. *Orthod Craniofac Res* 2008;11:143-155.
17. Gonzales C, Hotokezaka H, Yoshimatsu M, Yozgatian JH, Darendeliler MA, Yoshida N. Force magnitude and duration effects on amount of tooth movement and root resorption in the rat molar. *Angle Orthod* 2008;78:502-509.
18. Dunn MD, Park CH, Kostenuik PJ, Kapila S, Giannobile WV. Local delivery of osteoprotegerin inhibits mechanically mediated bone modeling in orthodontic tooth movement. *Bone* 2007;41:446-455.
19. Penolazzi L, Magri E, Lambertini E, Calo G, Cozzani M, Siciliani G et al. Local in vivo administration of a decoy oligonucleotide targeting NF-kappaB induces apoptosis of osteoclasts after application of orthodontic forces to rat teeth. *Int J Mol Med* 2006;18:807-811.

20. Drevensek M, Volk J, Sprogar S, Drevensek G. Orthodontic force decreases the eruption rate of rat incisors. *Eur J Orthod* 2009;31:46-50.
21. Costa A, Raffainl M, Melsen B. Miniscrews as orthodontic anchorage: a preliminary report. *Int J Adult Orthodon Orthognath Surg* 1998;13:201-209.
22. Park HS, Kyung HM, Sung JH. A simple method of molar uprighting with micro-implant anchorage. *J Clin Orthod* 2002;36:592-596.
23. Miyawaki S, Koyama I, Inoue M, Mishima K, Sugahara T, Takano-Yamamoto T. Factors associated with the stability of titanium screws placed in the posterior region for orthodontic anchorage. *Am J Orthod Dentofacial Orthop* 2003;124:373-378.
24. Heymann GC, Tulloch JF. Implantable devices as orthodontic anchorage: a review of current treatment modalities. *J Esthet Restor Dent* 2006;18:68-79; discussion 80.
25. Lioubavina-Hack N, Lang NP, Karring T. Significance of primary stability for osseointegration of dental implants. *Clin Oral Implants Res* 2006;17:244-250.
26. Wilmes B, Rademacher C, Olthoff G, Drescher D. Parameters affecting primary stability of orthodontic mini-implants. *J Orofac Orthop* 2006;67:162-174.
27. Wilmes B, Su YY, Sadigh L, Drescher D. Pre-drilling force and insertion torques during orthodontic mini-implant insertion in relation to root contact. *J Orofac Orthop* 2008;69:51-58.
28. Wilmes B, Su YY, Drescher D. Insertion angle impact on primary stability of orthodontic mini-implants. *Angle Orthod* 2008;78:1065-1070.
29. Okazaki J, Komasa Y, Sakai D, Kamada A, Ikeo T, Toda I et al. A torque removal study on the primary stability of orthodontic titanium screw mini-implants in the cortical bone of dog femurs. *Int J Oral Maxillofac Surg* 2008;37:647-650.

30. Wawrzinek C, Sommer T, Fischer-Brandies H. Microdamage in cortical bone due to the overtightening of orthodontic microscrews. *J Orofac Orthop* 2008;69:121-134.
31. Ylikontiola L, Sundqvist K, Sandor GK, Tormala P, Ashammakhi N. Self-reinforced bioresorbable poly-L/DL-lactide [SR-P(L/DL)LA] 70/30 miniplates and miniscrews are reliable for fixation of anterior mandibular fractures: a pilot study. *Oral Surg Oral Med Oral Pathol Oral Radiol Endod* 2004;97:312-317.
32. Mimura H. Treatment of severe bimaxillary protrusion with miniscrew anchorage: treatment and complications. *Aust Orthod J* 2008;24:156-163.
33. Seres L, Kocsis A. Closure of severe skeletal anterior open bite with zygomatic anchorage. *J Craniofac Surg* 2009;20:478-482.
34. Viera-Negron YE, Ruan WH, Winger JN, Hou X, Sharawy MM, Borke JL. Effect of ovariectomy and alendronate on implant osseointegration in rat maxillary bone. *J Oral Implantol* 2008;34:76-82.
35. Weinstein AM, Klawitter JJ, Anand SC, Schuessler R. Stress analysis of porous rooted dental implants. *J Dent Res* 1976;55:772-777.
36. Assuncao WG, Gomes EA, Barao VA, de Sousa EA. Stress analysis in simulation models with or without implant threads representation. *Int J Oral Maxillofac Implants* 2009;24:1040-1044.
37. Geng JP, Tan KB, Liu GR. Application of finite element analysis in implant dentistry: a review of the literature. *J Prosthet Dent* 2001;85:585-598.
38. Cedro MK, Moles DR, Hodges SJ. Adult orthodontics--who's doing what? *J Orthod*;37:107-117.
39. Nattrass C, Sandy JR. Adult orthodontics--a review. *Br J Orthod* 1995;22:331-337.

40. Buttke TM, Proffit WR. Referring adult patients for orthodontic treatment. *J Am Dent Assoc* 1999;130:73-79.
41. Paunovich ED, Sadowsky JM, Carter P. The most frequently prescribed medications in the elderly and their impact on dental treatment. *Dent Clin North Am* 1997;41:699-726.
42. NIH Consensus Development Panel on Osteoporosis Prevention, Diagnosis, and Therapy, March 7-29, 2000: highlights of the conference. *South Med J* 2001;94:569-573.
43. Osteoporosis prevention, diagnosis, and therapy. *JAMA* 2001;285:785-795.
44. http://www.osteoporosis.ca/index.php/ci_id/8867/la_id/1.htm - Osteoporosis Canada.
45. Galsworthy TD. Osteoporosis: statistics, intervention, and prevention. *Ann N Y Acad Sci* 1994;736:158-164.
46. Sturtridge W, Lentle B, Hanley DA. Prevention and management of osteoporosis: consensus statements from the Scientific Advisory Board of the Osteoporosis Society of Canada. 2. The use of bone density measurement in the diagnosis and management of osteoporosis. *CMAJ* 1996;155:924-929.
47. Geusens P, Hochberg MC, van der Voort DJ, Pols H, van der Klift M, Siris E et al. Performance of risk indices for identifying low bone density in postmenopausal women. *Mayo Clin Proc* 2002;77:629-637.
48. Kanis JA, Johnell O, Oden A, Sembo I, Redlund-Johnell I, Dawson A et al. Long-term risk of osteoporotic fracture in Malmo. *Osteoporos Int* 2000;11:669-674.
49. Kanis JA, Johnell O, De Laet C, Johansson H, Oden A, Delmas P et al. A meta-analysis of previous fracture and subsequent fracture risk. *Bone* 2004;35:375-382.

50. Klotzbuecher CM, Ross PD, Landsman PB, Abbott TA, 3rd, Berger M. Patients with prior fractures have an increased risk of future fractures: a summary of the literature and statistical synthesis. *J Bone Miner Res* 2000;15:721-739.
51. Ross PD, Genant HK, Davis JW, Miller PD, Wasnich RD. Predicting vertebral fracture incidence from prevalent fractures and bone density among non-black, osteoporotic women. *Osteoporos Int* 1993;3:120-126.
52. Lindsay R, Silverman SL, Cooper C, Hanley DA, Barton I, Broy SB et al. Risk of new vertebral fracture in the year following a fracture. *JAMA* 2001;285:320-323.
53. Casez P, Uebelhart B, Gaspoz JM, Ferrari S, Louis-Simonet M, Rizzoli R. Targeted education improves the very low recognition of vertebral fractures and osteoporosis management by general internists. *Osteoporos Int* 2006;17:965-970.
54. Majumdar SR, Kim N, Colman I, Chahal AM, Raymond G, Jen H et al. Incidental vertebral fractures discovered with chest radiography in the emergency department: prevalence, recognition, and osteoporosis management in a cohort of elderly patients. *Arch Intern Med* 2005;165:905-909.
55. Papaioannou A, Morin S, Cheung AM, Atkinson S, Brown JP, Feldman S et al. 2010 clinical practice guidelines for the diagnosis and management of osteoporosis in Canada: summary. *CMAJ*;182:1864-1873.
56. Reid IR, Bolland MJ, Grey A. Effect of calcium supplementation on hip fractures. *Osteoporos Int* 2008;19:1119-1123.
57. Tang BM, Eslick GD, Nowson C, Smith C, Bensoussan A. Use of calcium or calcium in combination with vitamin D supplementation to prevent fractures and bone loss in people aged 50 years and older: a meta-analysis. *Lancet* 2007;370:657-666.

58. Hanley DA, Cranney A, Jones G, Whiting SJ, Leslie WD, Cole DE et al. Vitamin D in adult health and disease: a review and guideline statement from Osteoporosis Canada. *CMAJ*;182:E610-618.
59. MacLean C, Newberry S, Maglione M, McMahon M, Ranganath V, Suttorp M et al. Systematic review: comparative effectiveness of treatments to prevent fractures in men and women with low bone density or osteoporosis. *Ann Intern Med* 2008;148:197-213.
60. Abrahamsen B, Vestergaard P, Rud B, Barenholdt O, Jensen JE, Nielsen SP et al. Ten-year absolute risk of osteoporotic fractures according to BMD T score at menopause: the Danish Osteoporosis Prevention Study. *J Bone Miner Res* 2006;21:796-800.
61. Kanis JA, Johnell O, Oden A, Dawson A, De Laet C, Jonsson B. Ten year probabilities of osteoporotic fractures according to BMD and diagnostic thresholds. *Osteoporos Int* 2001;12:989-995.
62. Russell RG, Watts NB, Ebtino FH, Rogers MJ. Mechanisms of action of bisphosphonates: similarities and differences and their potential influence on clinical efficacy. *Osteoporos Int* 2008;19:733-759.
63. Manolagas SC. Birth and death of bone cells: basic regulatory mechanisms and implications for the pathogenesis and treatment of osteoporosis. *Endocr Rev* 2000;21:115-137.
64. Rodan GA, Martin TJ. Therapeutic approaches to bone diseases. *Science* 2000;289:1508-1514.
65. DiPiro JT[Ed] TR, Yee, GC, Matzke GR, Wells BG, Posey LM. *Pharmacotherapy: A Pathophysiologic Approach*, 6th edition. (McGraw Hill, Toronto, 1999). 1999.

66. Papapoulos SE, Schimmer RC. Changes in bone remodelling and antifracture efficacy of intermittent bisphosphonate therapy: implications from clinical studies with ibandronate. *Postgrad Med J* 2008;84:307-312.
67. Nancollas GH, Tang R, Phipps RJ, Henneman Z, Gulde S, Wu W et al. Novel insights into actions of bisphosphonates on bone: differences in interactions with hydroxyapatite. *Bone* 2006;38:617-627.
68. Rodan GA. Mechanisms of action of bisphosphonates. *Annu Rev Pharmacol Toxicol* 1998;38:375-388.
69. Kimmel DB. Mechanism of action, pharmacokinetic and pharmacodynamic profile, and clinical applications of nitrogen-containing bisphosphonates. *J Dent Res* 2007;86:1022-1033.
70. Christiansen C, Tanko LB, Warming L, Moelgaard A, Christgau S, Qvist P et al. Dose dependent effects on bone resorption and formation of intermittently administered intravenous ibandronate. *Osteoporos Int* 2003;14:609-613.
71. Russell RG, Rogers MJ. Bisphosphonates: from the laboratory to the clinic and back again. *Bone* 1999;25:97-106.
72. Coxon FP, Thompson K, Rogers MJ. Recent advances in understanding the mechanism of action of bisphosphonates. *Curr Opin Pharmacol* 2006;6:307-312.
73. Sarasquete ME, Garcia-Sanz R, Marin L, Alcoceba M, Chillon MC, Balanzategui A et al. Bisphosphonate-related osteonecrosis of the jaw is associated with polymorphisms of the cytochrome P450 CYP2C8 in multiple myeloma: a genome-wide single nucleotide polymorphism analysis. *Blood* 2008;112:2709-2712.

74. Miller PD, Ward P, Pfister T, Leigh C, Body JJ. Renal tolerability of intermittent intravenous ibandronate treatment for patients with postmenopausal osteoporosis: a review. *Clin Exp Rheumatol* 2008;26:1125-1133.
75. Marx R, Sawatari Y, Fortin M. Bisphosphonate-induced exposed bone (Osteonecrosis/Osteopetrosis) of the jaws: risk factors, recognition, prevention and treatment. *J. Oral Maxillofac. Surg.* 2005;63:1567-1575
76. Marx RE. Pamidronate (Aredia) and zoledronate (Zometa) induced avascular necrosis of the jaws: a growing epidemic. *J Oral Maxillofac Surg.* 2003;61:1115-1117
77. Ruggiero SL, Mehrotra B, Rosenberg TJ, Engroff SL. Osteonecrosis of the jaws associated with the use of bisphosphonates: a review of 63 cases. *J Oral Maxillofac Surg.* 2004;62:527-534
78. Mehrotra B, Ruggiero S. Bisphosphonate related osteonecrosis (BRON) of the jaw: single institutional update. *J Am Dent Assoc.* 2005;136:1675-81.
79. Gibbs S, O'Grady J, Seymour J. Bisphosphonate-induced osteonecrosis of the jaws requires early detection and intervention. *Med J Austr.* 2005;183:549-50.
80. Melo M, Obeid G. Osteonecrosis of the jaws in patients with a history of receiving bisphosphonate therapy. *J Am Dent Assoc.* 2005;136:1675-81.
81. Migliorati C, Schubert M, Petersen D. Bisphosphonate-associated osteonecrosis of mandibular and maxillary bone. An emerging oral complication of supportive cancer therapy. *Cancer* 2005;104:83-93.
82. Khosla S, Burr D, Cauley J et al. for the American Society for Bone and Mineral Research. Bisphosphonate-associated osteonecrosis of the jaw: report of a task force of the American Society for Bone and Mineral Research. *J Bone Miner Res* 2007;22:1479-91.

83. American Association of Oral and Maxillofacial Surgeons position paper on bisphosphonate-related osteonecrosis of the jaws. *J Oral Maxillofac Surg* 2007;65:369-376.
84. Ruggiero S. American Association of Oral and Maxillofacial surgeons position paper on bisphosphonate-related osteonecrosis of the jaws: 2009 update. *J Oral Maxillofac Surg* 2009;67:2-12.
85. Ruggiero SL. Bisphosphonate-related osteonecrosis of the jaw: an overview. *Ann N Y Acad Sci.* 2011;1218:38-46.
86. Allen M and Burr D. Mandible matrix necrosis in beagle dogs following 3 years of daily oral bisphosphonate treatment. *J Oral Maxillofac Surg* 2008;66:987-994.
87. Landesberg R et al. Inhibition of oral mucosal cell wound healing by bisphosphonates. *J Oral Maxillofac Surg.* 2008;66:839-847
88. Hoff AO, Toth BB, Altundag K, Johnson MM, Warneke CL, Hu M et al. Frequency and risk factors associated with osteonecrosis of the jaw in cancer patients treated with intravenous bisphosphonates. *J Bone Miner Res* 2008;23:826-836.
89. Bamias A, Kastiris E, Barnia C et al. ONJ in cancer after treatment with bisphosphonates: incidence and risk factors. *J Clin Oncol* 2005;23:8580-87.
90. Tosi P, Zamagni E, Cangini D. ONJs in newly diagnosed multiple myeloma patients treated with zoledronic acid and thalidomide-dexamethasone. *Blood* 2006;108:3951-62.
91. Kraj M, Ryszard P, Stanislaw M et al. The incidence of jaw osteonecrosis in multiple myeloma patients treated with bisphosphonates. *Acta Pol Pharm* 2006;63:450-452.
92. Zervas K, Verrou E, Teleioudis Z. Incidence, risk factors and management of ONJ in patients with multiple myeloma: a single-centre experience in 303 patients. *Br J Haematol* 2006;134:620-623.

93. Pozzi S, Marcheselli R, Sacchi S et al. Bisphosphonate-associated ONJ: a review of 35 cases and an evaluation of its frequency in multiple myeloma patients. *Leuk Lymphoma* 2007;48:56-64.
94. Hoff AO, Toth B, Hu M, Hortobagyi GN, Gagel RF. Epidemiology and risk factors for osteonecrosis of the jaw in cancer patients. *Ann N Y Acad Sci* 2011;1218:47-54.
95. Mavrokokki T, Cheng A, Stein B, Goss A. Nature and frequency of bisphosphonate-associated osteonecrosis of the jaws in Australia. *J Oral Maxillofac Surg* 2007;65:415-423.
96. Ruggiero S, Fantasia J, Carlson E. Bisphosphonate-related osteonecrosis of the jaw: background and guidelines for diagnosis, staging and management. *Oral Surg Oral Med Oral Pathol Oral Radiol Endod* 2006;102:433-441.
97. Fedele S, Porter SR, D'Aiuto F, Aljohani S, Vescovi P, Manfredi M, et al. Nonexposed variant of bisphosphonate-associated osteonecrosis of the jaw: a case series. *Am J Med* 2010;123:1060-4.
98. Biasotto M, Chiandussi S, Zacchigna S et al. A novel animal model to study non-spontaneous bisphosphonate osteonecrosis of the jaw. *J Oral Pathol Med* 2010; 39:390-96.
99. Aghaloo T, Kang B, Sung E et al. Periodontal disease and bisphosphonate induce osteonecrosis of the jaws in the rat. *J Bone and Miner Res* 2011;26(8):1871-82.
100. Gotcher JE, Jee WS. The progress of the periodontal syndrome in the rice rat II. The effects of a diphosphonate on the periodontium. *J Periodontal Res* 1981;16:441-455.
101. Kobayashi Y, Hiraga T, Ueda A et al. Zoledronic acid delays wound healing of the tooth extraction socket, inhibits-oral epithelial cell migration, and promotes proliferation and adhesion of hydroxyapatite of oral bacteria, without causing osteonecrosis of the jaws in mice. *J Bone Miner Metab* 2010;28:165-75.

102. López-Jornet P, Camacho-Alonso F, Vicente-Ortega V et al. An experimental study of bisphosphonate-induced jaws osteonecrosis in Sprague-Dawley rats. *J oral Pathol Med* 2011;39:697-702.
103. Ali-Erdem M, Burak-Cankaya A, Cemil-Isler S et al. Extraction socket healing in rats treated with bisphosphonate: animal model for bisphosphonate related osteonecrosis of jaws in multiple myeloma patients. *Med Oral Patol Oral Cir Bucal* 2011;16:e879-883.
104. Sonis ST, Watkins BA, Lyng GD, Lerman MA, Anderseon KC. Bony changes in the jaws of rats treated with zoledronic acid and dexamethasone before dental extractions mimic bisphosphonate-related osteonecrosis in cancer patients. 2009;45:164-172.
105. Marino KL, Zakhary I, Abdelsayed RA et al. Development of a rat model of bisphosphonate-related osteonecrosis of the jaw (BRONJ). *J Oral Implantol* 2012;38:511-518.
106. Abtahi J, Agholme F, Sandberg O, Aspenberg P. Bisphosphonate-induced osteonecrosis of the jaw in a rat model arises first after the bone has become exposed. No primary necrosis in unexposed bone. *J Oral Pathol Med* 2012;41:494-499.
107. Pautke C, Kreutzer K, Weitz J et al. Bisphosphonate related osteonecrosis of the jaw: a minipig large animal model. *Bone* 2012;51:592-99.
108. Senel FC, KadiogluDuman M, Muci E et al. Jaw bone changes in rats after treatment with zoledronate and pamidronate. *Oral Surg Oral Med Oral Pathol Oral Radiol Endod* 2010;109:385-91.
109. Keles A, Grunes B, Difuria C, Gagari E, Srinivasan V, Darendeliler MA et al. Inhibition of tooth movement by osteoprotegerin vs. pamidronate under conditions of constant orthodontic force. *Eur J Oral Sci* 2007;115:131-136.

110. Liu L, Igarashi K, Haruyama N, Saeki S, Shinoda H, Mitani H. Effects of local administration of clodronate on orthodontic tooth movement and root resorption in rats. *Eur J Orthod* 2004;26:469-473.
111. Sato Y, Sakai H, Kobayashi Y, Shibasaki Y, Sasaki T. Bisphosphonate administration alters subcellular localization of vacuolar-type H(+)-ATPase and cathepsin K in osteoclasts during experimental movement of rat molars. *Anat Rec* 2000;260:72-80.
112. Igarashi K, Adachi H, Mitani H, Shinoda H. Inhibitory effect of the topical administration of a bisphosphonate (risedronate) on root resorption incident to orthodontic tooth movement in rats. *J Dent Res* 1996;75:1644-1649.
113. Igarashi K, Mitani H, Adachi H, Shinoda H. Anchorage and retentive effects of a bisphosphonate (AHBuBP) on tooth movements in rats. *Am J Orthod Dentofacial Orthop* 1994;106:279-289.
114. Adachi H, Igarashi K, Mitani H, Shinoda H. Effects of topical administration of a bisphosphonate (risedronate) on orthodontic tooth movements in rats. *J Dent Res* 1994;73:1478-1486.
115. Alatli I, Hellsing E, Hammarstrom L. Orthodontically induced root resorption in rat molars after 1-hydroxyethylidene-1,1-bisphosphonate injection. *Acta Odontol Scand* 1996;54:102-108.
116. Kim TW, Yoshida Y, Yokoya K, Sasaki T. An ultrastructural study of the effects of bisphosphonate administration on osteoclastic bone resorption during relapse of experimentally moved rat molars. *Am J Orthod Dentofacial Orthop* 1999;115:645-653.
117. Boonyapakorn T, Schirmer I, Reichart PA, Sturm I, Massenkeil G. Bisphosphonate-induced osteonecrosis of the jaws: prospective study of 80 patients with multiple myeloma and other malignancies. *Oral Oncol* 2008;44:857-869.

118. Verna C, Dalstra M, Melsen B. The rate and the type of orthodontic tooth movement is influenced by bone turnover in a rat model. *Eur J Orthod.* 2000;22(4):343-52.
119. Iino S, Sakoda S, Ito G, Nishimori T, Ikeda T, Miyawaki S. Acceleration of orthodontic tooth movement by alveolar corticotomy in the dog. *Am J Orthod Dentofacial Orthop.* 2007;131(4):448.e1-8.
120. Wang L, Lee W, Lei DL, Liu YP, Yamashita DD, Yen SL. Tissue responses in corticotomy- and osteotomy-assisted tooth movements in rats: histology and immunostaining. *Am J Orthod Dentofacial Orthop.* 2009;136(6):770.e1-11.
121. Hassan AH, Al-Fraidi AA, Al-Saeed SH. Corticotomy-assisted orthodontic treatment: review. *Open Dent J.* 2010;4:159-64
122. Baloul SS, Gerstenfeld LC, Morgan EF, Carvalho RS, Van Dyke TE, Kantarci A. Mechanism of action and morphologic changes in the alveolar bone in response to selective alveolar decortication-facilitated tooth movement. *Am J Orthod Dentofacial Orthop.* 2011;139(4 Suppl):S83-101.
123. Cano J, Campo J, Bonilla E, Colmenero C. Corticotomy-assisted orthodontics. *J Clin Exp Dent.* 2012;4(1):e54-9.
124. Cruz DR, Kohara EK, Ribeiro MS, Wetter NU. Effects of low-intensity laser therapy on the orthodontic movement velocity of human teeth: a preliminary study. *Lasers Surg Med.* 2004;35:117-120.
125. Yamaguchi M, Hayashi M, Fujita S. Low-energy laser irradiation facilitates the velocity of tooth movement and the expressions of matrix metalloproteinase-9, cathepsin K, and alpha(v) beta(3) integrin in rats. *Eur J Orthod.* 2010;32:131-139.

126. Nishimura M, Chiba M, Ohashi T. Periodontal tissue activation by vibration: Intermittent stimulation by resonance vibration accelerates experimental tooth movement in rats. *Am J Orthod Dentofacial Orthop.* 2008;133:572-583.
127. Showkatbakhsh R, Jamilian A, Showkatbakhsh M. The effect of pulsed electromagnetic fields on the acceleration of tooth movement. *World J Orthod.* 2011;11:e52-e56.
128. Kim DH, Park YG, Kang SG. The effects of electrical current from a micro-electrical device on tooth movement. *Korean J Orthod.* 2008;38:337-346.
129. Liou EJ, Huang CS. Rapid canine retraction through distraction of the periodontal ligament. *Am J Orthod Dentofacial Orthop.* 1998;114:372-82.
130. Sayin S, Bengi AO, Gurton AU, Ortakoglu K. Rapid canine distalization using distraction of the periodontal ligament. a preliminary clinical validation of the original technique. *Angle Orthod.* 2004;74:304-315.
131. Iseri H, Kisnisci R, Bzizi N, Tuz H. Rapid canine retraction and orthodontic treatment with dentoalveolar distraction osteogenesis. *Am J Orthod Dentofacial Orthop.* 2005;127:533-541.
132. Kanzaki H, Chiba M, Arai K, Takahashi I, Haruyama N, Nishimura M, Mitani H. Local RANKL gene transfer to the periodontal tissues accelerates orthodontic tooth movement. *Gene Ther.* 2006;13(8):678-85.
133. Long H, Pyakurel U, Wang Y, Liao L, Zhou Y, Lai W. Interventions for accelerating orthodontic tooth movement. *Angle Orthod.* 2013;83(1):164-171.
134. Köle H. Surgical operations on the alveolar ridge to correct occlusal abnormalities. *Oral Surg Med Pathol.* 1959;12:515-529.
135. Frost HM. The regional acceleratory phenomenon: a review. *Henry Ford Hosp Med J.* 1983;31(1):3-9.

136. Schilling T, Müller M, Minne HW, Ziegler R. Influence of inflammation-mediated osteopenia on the regional acceleratory phenomenon and the systemic acceleratory phenomenon during healing of a bone defect in the rat. *Calcif Tissue Int.* 1998;63(2):160-6.
137. Wilcko W, Wilcko MT. Accelerating tooth movement: the case for corticotomy-induced orthodontics. *Am J Orthod Dentofacial Orthop.* 2013;144(1):4-12.
138. Duker J. Experimental animal research into segmental alveolar movement after corticotomy. *J Maxillofac Surg.* 1975;3:81-84.
139. Ren A, Lv T, Kang N, Zhao B, Chen Y, Bai D. Rapid orthodontic tooth movement aided by alveolar surgery in beagles. *Am J Orthod Dentofacial Orthop.* 2007;131:61-8.
140. Mostafa YA, Mohamed Salah Fayed M, Mehanni S, ElBokle NN, Heider AM. Comparisons of corticotomy-facilitated vs standard tooth-movement techniques in dogs with miniscrews as anchor units. *Am J Orthod Dentofacial Orthop.* 2009;136(4):570-7.
141. Wilcko MT, Wilcko WM, Pulver JJ, Bissada NF, Bouquot JE. Accelerated osteogenic orthodontics technique: a 1-stage surgically facilitated rapid orthodontic technique with alveolar augmentation. *J Oral Maxillofac Surg.* 2009;67(10):2149-59.
142. Murphy KG, Wilcko MT, Wilcko WM, Ferguson DJ. Periodontal accelerated osteogenic orthodontics: a description of the surgical technique. *J Oral Maxillofac Surg.* 2009;67(10):2160-6.
143. Sebaoun JD, Kantarci A, Turner JW, Carvalho RS, Van Dyke TE, Ferguson DJ. Modeling of trabecular bone and lamina dura following selective alveolar decortication in rats. *J Peridontol.* 2008;79(9):1679-88.
144. Inubushi T, Tanaka E, Rego EB, Ohtani J, Kawazoe A, Tanne K, Miyauchi M, Takata T. Ultrasound stimulation attenuates resorption of tooth root induced by experimental force application. *Bone.* 2013 Apr;53(2):497-506.

**Chapter 3 A Novel Rat Model of Orthodontic Tooth Movement
using Temporary skeletal anchorage devices: 3-D Finite element
Analysis and In-vivo Validation**

3.1 Abstract

The aim of this animal study was to develop a model of orthodontic tooth movement using a micro-implant as a Temporary skeletal anchorage device (TSAD) in rodents. A finite element model of the TSAD in alveolar bone was built using μ CT images of rat maxilla to determine the von-Mises stresses and displacement in the alveolar bone surrounding the TSAD. For In-vivo validation of the FE model, Sprague-Dawley rats (n=25) were used and a Stryker 1.2 x 3 mm micro-implant was inserted in the right maxilla and was used to protract the right first permanent molar using a NiTi closed coil spring. Tooth movement measurements were taken at baseline and at 4 and 8 weeks by μ CT imaging. At 8 weeks, all animals were euthanized and tissues analyzed by routine histology and dynamic bone labeling using electron probe micro-analysis (EPMA). Finite element modeling showed maximum von Mises stress of 45 Mpa near the apex of TSAD but the average von Mises stress was under 25 Mpa. Appreciable tooth movement of 0.62 ± 0.04 mm at 4 weeks and 1.99 ± 0.14 mm at 8 weeks of tooth movement was obtained. Histological and EPMA results demonstrated no active bone remodeling around the TSAD at 8 weeks depicting good secondary stability. This study provided evidence that protracted tooth movement could be achieved in small animals using TSADs.

Keywords: Orthodontic tooth movement, rat model, micro-implant, Temporary skeletal anchorage device, finite element method, microcomputed tomography.

3.2 Introduction

Orthodontic tooth movement (OTM) occurs through controlled application of mechanical forces on teeth and surrounding biologic tissues.¹ Current rat models of OTM (for molar mesialization) utilize the maxillary incisors for anchorage and employ a NiTi closed coil spring attached to the molar tooth to deliver a specific magnitude of force.²⁻⁴ This model is currently used in rodent research due to easy accessibility to secure the appliance, but has several disadvantages including; retardation in normal eruption process of incisor,⁵ loss of pulp vitality of the incisor^{3,5} and change in force vector due to continuous incisor eruption that occurs in rats, with subsequent loss of anchorage.⁶ Hence, it would be advantageous to develop an anchorage device that is easily inserted, provides stable anchorage and maintains a constant force delivery without the undesirable side effects mentioned above.

Mini-implants have been used extensively as stable anchorage devices to achieve predictable tooth movement.⁷⁻⁹ Although there are numerous commercial mini-implant systems available for use in humans, they remain too large for application to the rat. An alternative approach is to use micro-implants, as their miniature size allows them to be placed in practically any location and are similar to those used for osteotomy fixation during orthognathic surgery and facial reconstructions.¹⁰⁻¹²

In the current study, we used a Stryker titanium micro-implant (1.2 x 3 mm in diameter) (Stryker-Leibinger Inc., Hamilton, ON, Canada) as a Temporary skeletal anchorage device (TSAD) because of its smaller size and availability. In order for the TSAD to withstand forces of magnitude large enough to cause tooth movement, it would likely result in loading of surrounding cortical and cancellous bone in which it is inserted. The effects upon surrounding

alveolar bone during TSAD placement and subsequent anchorage for tooth movement have not been studied extensively and the effect of those stresses on bone remodeling remains unanswered. Thus, we chose to employ the Finite Element Method (FEM) as a tool to define stress concentrations on the surrounding bone during post insertion anchorage for tooth movement.

FEM is a numerical method of analyzing stresses and deformations in any structure of a given geometry. The structure geometry (precise or imprecise) is discretized into so called “finite elements” connected to each other by nodes. The type, arrangement and total number of elements affect the accuracy of the results. FEM has become the most used computational and analysis tool since the 1960’s and was first used in implant dentistry in 1976.¹³ It is postulated that an TSAD inserted into the alveolar bone changes the local stress state of the bone and induces an adaptive phenomena. Stress distribution depends on many assumptions including: geometry of the model studied, material properties of the bone and the TSAD, boundary conditions and load applied; along with contact status between the TSAD and surrounding cortical bone using a carefully planned algorithm.¹⁴ Currently, with the advent of advanced imaging techniques and improvement in mathematical computation methods, a precise geometric representation of the actual model can be considered for near accurate results.¹⁵

An ideal animal model for OTM should include a force system with constant magnitude of force in the desired direction and provide sufficient anchorage to trigger tooth movement without any undesirable side-effects. Therefore, the objective of the present study was to develop an FE model of a TSAD in the rat maxilla to estimate the stress distribution in the surrounding cortical

bone and the TSAD stability at different force levels followed by in-vivo validation using a rodent model of OTM.

3.3 *Materials and Methods*

3.3.1 *Building an FE model:*

The FEM was built as follows: Micro-computed Tomography (μ CT) images of the rat maxilla were obtained from scanned data using Skyscan 1076 imager for small animals. (SkyScan 1076, Kontich, Belgium) The images were imported into Mimics (Mimics 13.1, Leuven, Belgium) to segment the maxilla by Hounsfield values and manual mask segmentation. Three-dimensional geometry files were created for each mask and saved as Stereolithography (STL) files. Computer Assisted Design (CAD) software (Geomagic 12.0, Research Triangle Park, NC, USA) was used for extracting surfaces and solids from STL files. Triangle and intersection fixing techniques were performed and then Standard for the Exchange of Product model data (STEP) files were created and exported for the maxilla and molar teeth separately into ABAQUS. ABAQUS, FE modeling software (ABAQUS 6.9.1, Providence, RI, USA) with CAE and Solver modules, was used for pre/post processing and analysis calculation. The geometry of the TSAD was created in ProE (Pro/Engineer Needham, MA, USA) according to exact dimensions of the actual Stryker 1.2 x 3 mm micro-implant and imported into ABAQUS. The TSAD was registered at the desired location on the rat maxilla based on the amount of bone present and insertion depth required. The inserted depth of the TSAD was approximately 1.5 mm from the cortical surface of the bone to the bottom tip of the TSAD. This depth of 1.5 mm was based on the thickness of the maxillary bone in the proposed location of TSAD placement as measured by μ CT.

Material properties of the rat maxillary bone [Young's modulus (E) – 20.0 Gpa; Poisson's ratio (ν) – 0.3] was obtained from literature.¹⁶ The TSAD was modeled as a rigid body as it was assumed that the titanium implant with a high Young's modulus would not undergo any measurable deformation at the force level applied in this study. A reference point (RP) was defined just anterior to the TSAD to represent the motion of the rigid body. The maxilla was meshed as 10-node tetrahedron elements, C3D10M, for proper contact performance and to model the threads of the TSAD appropriately, a smaller element size (0.1 mm) was used to model them locally. Contact was set between the TSAD and the maxilla, so that small sliding was allowed between the contact surfaces. Contact between the TSAD and alveolar bone was considered friction affected and friction coefficient was set at 0.2.¹⁶ Constraints (boundary conditions) were applied to the maxilla on the mesial end to allow for bone bending and displacement in the direction of the load. Once the material properties and boundary conditions were assigned, the force was applied on RP in the direction the first permanent molar to mimic the direction of force applied during actual tooth movement and results analyzed. These different models were analyzed by ABAQUS processor and post-processing results were displayed in the form of color-coded maps of von Mises stresses and displacements of the alveolar bone around the TSAD. (Fig. 1)

3.3.2 Animal model of OTM:

Ethics approval was obtained from the animal care and use committee of the University of Alberta. Three month-old female Sprague-Dawley rats ($n = 25$) were obtained from Biosciences, University of Alberta and caged in animal housing with 12 hours dark and light cycles and fed a soft diet *ad libitum*. Rats were sedated using general anesthesia 2% Isoflurane/L oxygen (Forane,

Baxter, Deerfield, IL, USA) and placed supine in a custom designed surgical jig (i.e., respiratory plenum). To insert the Temporary skeletal anchorage device, a 4 mm semi-lunar incision was made from the disto-palatal gingival margin of the maxillary right incisor posteriorly with a No.15 surgical blade.

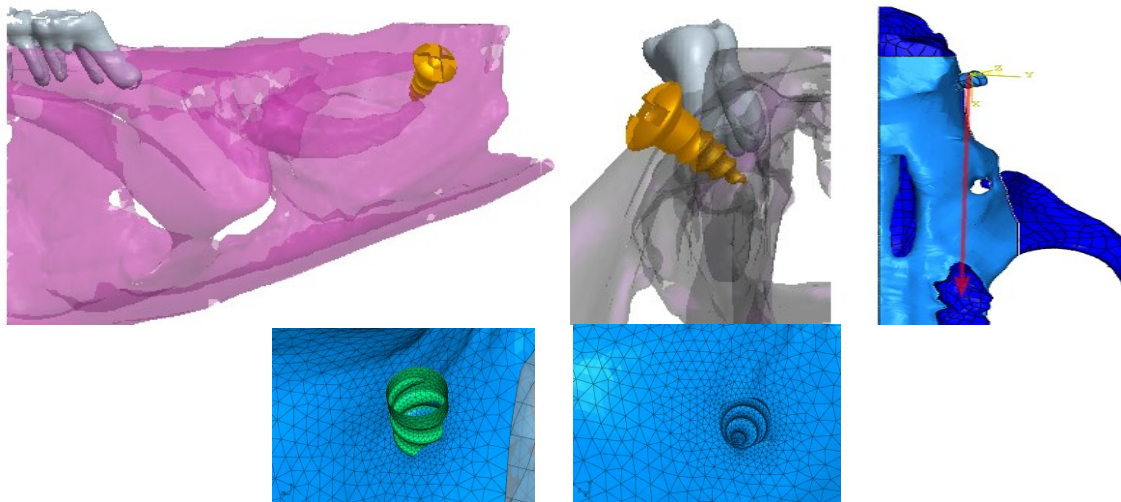


Figure 3-1. Computer modeling of TSAD placement into the rat maxilla 3D model of hemimaxillae in A. a sagittal view and B. Transverse view C. 3D model of the hemimaxillae showing the direction of force applied during FE analysis D, E. Fine mesh of the TSAD and the surrounding maxillary bone

After achieving adequate hemostasis, a pilot hole was drilled in the maxillary bone at a 45° angle using a 0.5 mm round bur attached to a NSK slow speed electric dental handpiece. (NSK; Brassler, Savannah, GA, USA) A self-threading Stryker 1.2 x 3 mm titanium TSAD (Stryker-Leibinger, Hamilton, ON, Canada) was inserted to a depth of 1.5 mm into the alveolar bone about 12 to 14 mm distance from the mesial aspect of the right first permanent molar. The fit and primary stability of the TSAD into the alveolar bone was verified by finger pressure, using a side-to-side and in-and-out motion. A stainless steel ligature wire was placed around the neck of the right first permanent molar and secured in position by tightening. A 9 mm closed coil NiTi

spring (GAC International, Bohemia, NY, USA), was secured to the posterior molar and the TSAD neck anteriorly with 0.010 inches stainless steel ligature. The appliance was left in place for 8 weeks to achieve appreciable tooth movement, as measured by μ CT imaging (described below). The left side acted as an intra-animal control with no appliance. (Fig. 2)

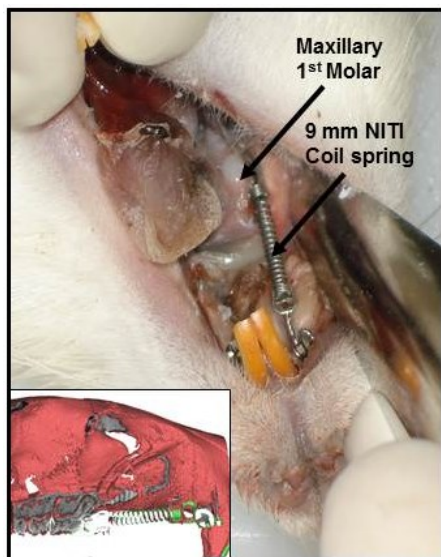


Figure 3-2: Orthodontic appliance in the right maxilla for tooth movement using TSAD and NiTi closed coil spring. Inset: μ CT 3D rendered cross-section model of rat maxilla with appliance

3.3.3 μ CT analysis of OTM:

All rats underwent baseline *in vivo* μ CT scan (Skyscan 1076 “in-vivo” μ CT, Skyscan NV, Kontich, Belgium) of the alveolar bone surrounding the first molar and extending anteriorly to the maxillary incisors. The scans were repeated *in vivo* after 4 weeks and 8 weeks of appliance placement and tooth movement was accurately measured from μ CT projections using bundled vendor analysis software (DataViewer, Skyscan, Kontich BE). For all μ CT imaging, scans were conducted at 100 kV and 100 mA current through 180° with a rotation step of 0.5° to produce serial projectional images of isotropic 18- μ m³ voxels. All image data was processed using commercial software bundled with the μ CT system in our laboratory. The acquired data was

Gaussian filtered and underwent global thresholding to extract the mineralized phase representing the 3D tooth movement and bone architecture. Measurements were made between the furcations of both the first and second right maxillary molars at 0, 4, 8 weeks.

3.3.4 Measurement of Tooth movement and TSAD displacement:

The measurement of amount of tooth movement and TSAD displacement was accomplished as follows: Briefly, microcomputed tomography-rendered 2-dimensional scans were reconstructed as .bmp files and viewed using Data Viewer software (DataViewer, Skyscan, Kontich BE). The 2-dimensional slices displayed as 3 orthogonal sections in the x, y, and z planes of space were centered at the desired point inside the reconstructed space. Once the image was centered in all 3 planes, the linear distance from the most convex contact area between the maxillary right first and second molars was measured and recorded for the amount of tooth movement. For the TSAD displacement, the linear distance from the TSAD head to centre of the right third permanent molar was measured and recorded. Measurements were recorded at 0, 4, and 8 weeks, and the amount of tooth movement and TSAD displacement was obtained by subtracting the distances at 4 and 8 weeks from the baseline. Measurements were obtained by the primary author (N.K.) in a blinded fashion and repeated for reliability one week apart. ($r=0.96$)

3.3.5 Electron Probe Micro-Analysis (EPMA):

All animals were given a brief 10-day pulse of elemental strontium (Strontium ranelate, PROTOS; Servier Laboratories, Hawthorn, Victoria, Australia; 308 mg/kg/day body weight – sub-therapeutic dosage at lower limit of therapeutic index) by gavage 10 days prior to euthanization. Strontium has been shown as an excellent dynamic label for bone turnover and

can readily be detected by EPMA at high spatial resolution.¹⁷ EPMA was performed on the palatal half of the right first permanent molar and around the TSAD for spatially mapping the location and distribution of elemental, Sr, Ca, and Phosphate (P). Briefly, the first molar sagittal sections and cross-sectional and sagittal sections of alveolar bone surrounding the TSAD were defatted in acetone, embedded in epoxy resin, progressively polished (~ 0.5 µm) and scanned at 2 and 5 µm resolution to analyze the Ca, Sr and P content on the alveolar bone surrounding the TSAD, control left molar and orthodontically moved right permanent molar.

3.3.6 Histological assessment:

At the experiment end point (8weeks), all animals were euthanized using isoflurane followed by CO₂ inhalation to effect, and the right and left maxilla were immediately dissected, stored in 4% paraformaldehyde (Sigma-Aldrich Canada, Oakville, ON, Canada) and fixed for 1 week with frequent changes. Following fixation, each hemi-maxilla was cut sagittal at the level of first permanent molar. The palatal half was processed for spatial mapping of bone turnover using EPMA (Electron-Probe Microanalysis) and the buccal half was processed for routine histology. The alveolar bone surrounding the TSAD was also processed. All samples processed for histology were rinsed with PBS (Phosphated Buffered Saline) wash buffer (pH 7.3) and immersed in 4.13% EDTA (Disodium Ethylene Diamine Tetra Acetic acid; Sigma-Aldrich Canada, Oakville, ON, Canada) decalcifying solution for 3 weeks. The tissue was checked and further decalcified if inadequate decalcification was observed. Following decalcification, samples were processed for routine histology by paraffin embedding. Sagittal sections (6 µm) were cut and stained with hematoxylin and eosin for routine histology.

3.4 Statistical Analysis

SPSS statistical software (version 16.0; SPSS, Chicago, IL, USA) was used to analyze the data. OTM measurements and TSAD displacement obtained from age-matched cohorts were used for statistical analyses. All quantitative data were expressed as mean \pm standard error (SE). To compare the mean amount of tooth movement and mean TSAD displacement at 4 and 8 weeks, repeated measures ANOVA were performed with the significance level set at 95% ($\alpha=0.05$). A bonferroni post-hoc comparison was performed within groups to see individual variation. Since the results of FE analysis were individual results without a statistical spread, we reported outcome of von Mises stress and displacement at different force levels without performing any statistical comparison to test level of significance.

3.5 Results

3.5.1 FE analysis:

The FE method was used to predict the von Mises stresses in the cortical bone surrounding the TSADs. The von Mises stress distribution and the resultant displacement of the bone surrounding the TSAD at different force levels are presented in Fig. 3. The dark blue color represents areas with minimal von Mises stress and minimal displacement and red color represents area with maximum von Mises stress and maximum displacement with gradient of colors in between. Understanding the limitation of this FE model, with the assigned material properties, friction coefficient, contact and boundary conditions, the maximum von Mises stresses on the contact surface of bone was 45.7 MPa, near the apex of the TSAD, but the majority of the stresses throughout were under 25 MPa. Finite element analysis revealed that the rat maxillary bone

could withstand stress of up to 140 gms force traction on the TSAD toward the molar which was below the stresses needed to cause permanent deformation of rat alveolar bone, with possibly higher stress at the thread edge due to local stress concentration. The micro-motion of the TSAD under 140 gms of force was only -0.89 to 0.136 μm along the TSAD axis and 2.29 μm along the force direction. The maximum displacement of the bone was 0.64 μm . (Fig. 4)

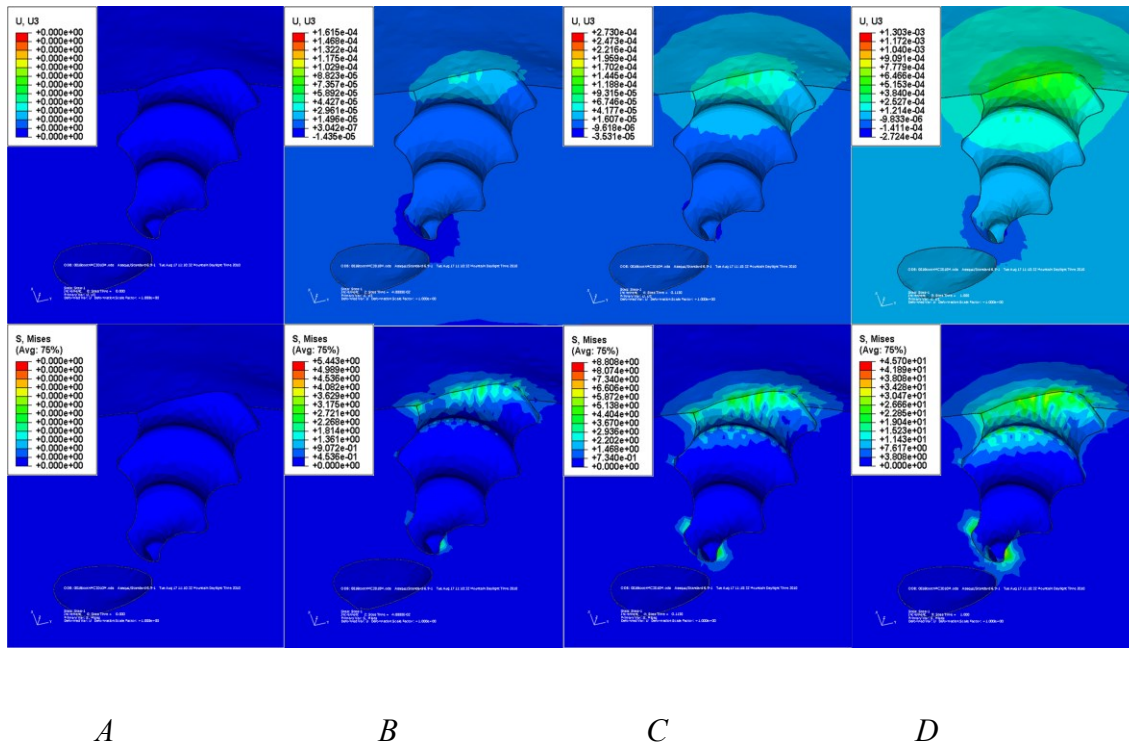


Figure 3-3. Displacements and von Mises stress at A. 0 gms, B. 30 gms C. 60 gms and D. 140 gms of force. The warmer colors depict increase in the amount and distribution of the stress and displacement and shows stresses concentrated at the apex of the TSAD and at the coronal contact area between the TSAD and the bone.

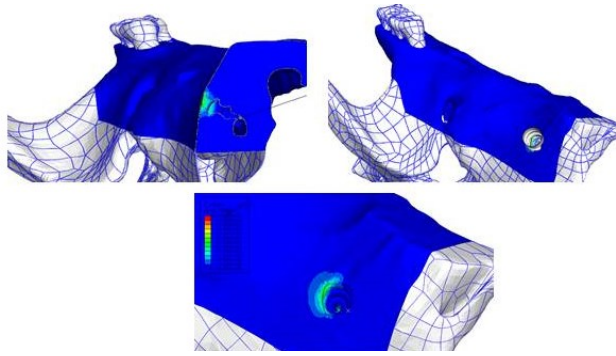


Figure 3-4: Von Mises stress localization in the cortical bone surrounding the TSAD. Dark blue color represents minimal von Mises stress and red color represents maximum von Mises stress localization around the TSAD

3.5.2 OTM and TSAD stability:

All animals were healthy and gained weight steadily during the entire treatment time with no evidence of significant weight loss. The survival rate of TSADs was 92% at four weeks and 80% at 8 weeks. This was due to loosening of two TSADs between 0 and 4 weeks and three TSADs between 4 and 8 weeks. These animals were removed from the study. Results of tooth movement at 0, 4, and 8 weeks can be seen in the μ CT images in Fig. 5.

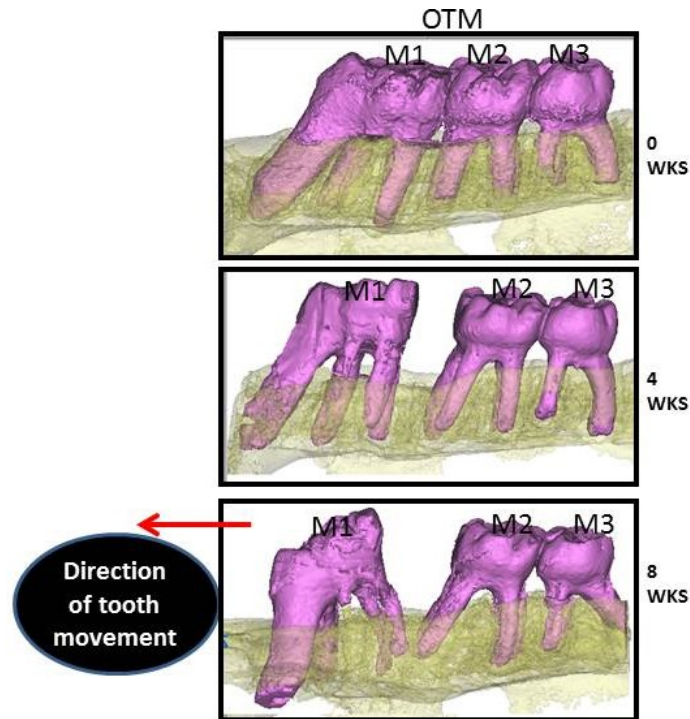


Figure 3-5: Three-dimensional microcomputed tomography –rendered images showing the amount of tooth movement of the right first permanent molar at 4 and 8 weeks. (M1, Right permanent first molar; M2, right permanent second molar; M3, right permanent third molar)

Kolgomorov-Smirnov test for normality and Levene’s test for equal variance were satisfied. In terms of measured distance, there was substantial tooth movement, both translation and tipping, at 4 weeks (0.62 ± 0.04) and 8 weeks (1.99 ± 0.14). (Fig. 6a) Repeated measures ANOVA showed a high statistically significant tooth movement with a *p*-value of .0003. Pairwise comparisons at both 4 and 8 weeks compared to baseline showed statistically significant tooth movement ($p \sim 0.0003$). The rate of tooth movement was 0.022 mm/day from zero to 4 weeks with a steady increase to 0.048 mm/day from 4 to 8 weeks with statistically significance ($p \sim 0.0001$) TSAD displacement was measured to be $0.42 \text{ mm} \pm 0.14 \text{ mm}$ at 4 weeks and $0.94 \text{ mm} \pm 0.17 \text{ mm}$ at 8 weeks. The rate of TSAD displacement was 0.014 mm/day from zero to 4 weeks and remained constant with very minimal increase in rate from 4 to 8 weeks (0.018

mm/day) (Fig. 6b). There was no statistically significant difference in TSAD displacement from baseline to 4 weeks ($p \sim 0.057$) but from 4 weeks to 8 weeks, the amount of TSAD displacement was significant ($p \sim 0.016$). The rate of TSAD displacement was not significant at 4 and 8 weeks. (Fig. 6a).

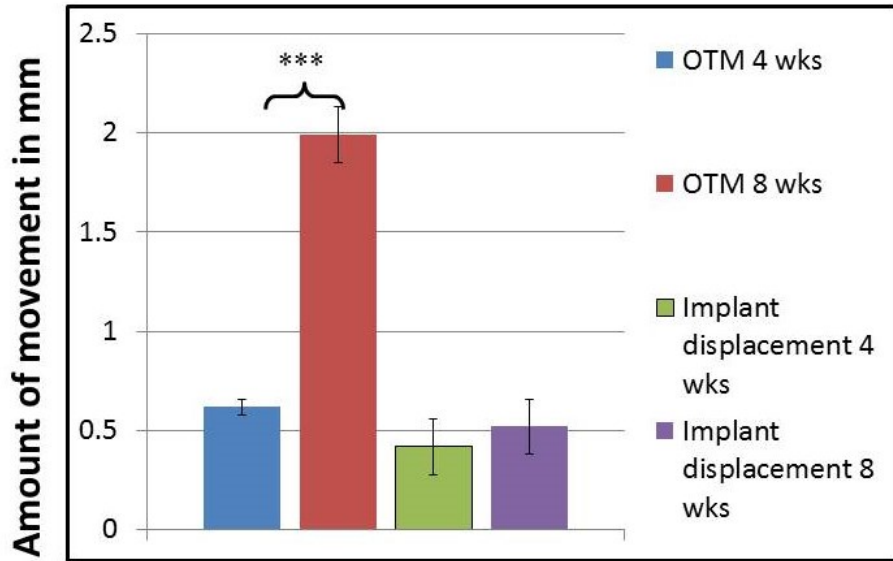


Figure 3- 6a: Mean (\pm S.E) amount of orthodontic tooth movement and implant displacement measured at 4 and 8 weeks. (significance level: $*p < 0.05$)

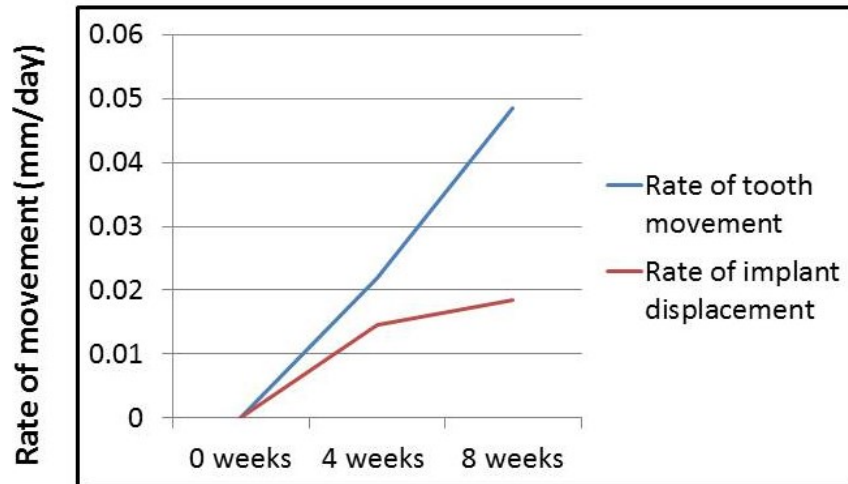


Figure 3-6b: Mean rate of orthodontic tooth movement and implant displacement measured at 0, 4 and 8 weeks

3.5.3 Elemental Mapping of Ca, P and Sr in the alveolar bone:

Fig. 7 shows EPMA mapped densities of Ca, P, Sr in the bone around the TSAD. No evidence of recognizable difference in the Ca density of bone immediately surrounding the TSAD to that of distant alveolar bone. (Fig. 7b,f) The concentration of P also demonstrated similar findings. (Fig. 7c,g). Fig. 7 (d,h) shows elemental Strontium was not readily detected in the alveolar bone immediately surrounding the TSAD indicating no active bone remodeling around the TSAD.

We detected increased elemental strontium deposition in newly mineralizing alveolar bone shown as warmer colors on the tension side of tooth movement around the roots of right first permanent molar (Fig. 8d) indicating robust alveolar bone remodeling associated with orthodontic tooth movement. Minimal or no deposition of Sr was seen on the control side. (Fig. 8a) There was no detectable difference in densities of Ca (Fig. 8b,e) and P (Fig. 8c,f) found between control and OTM side

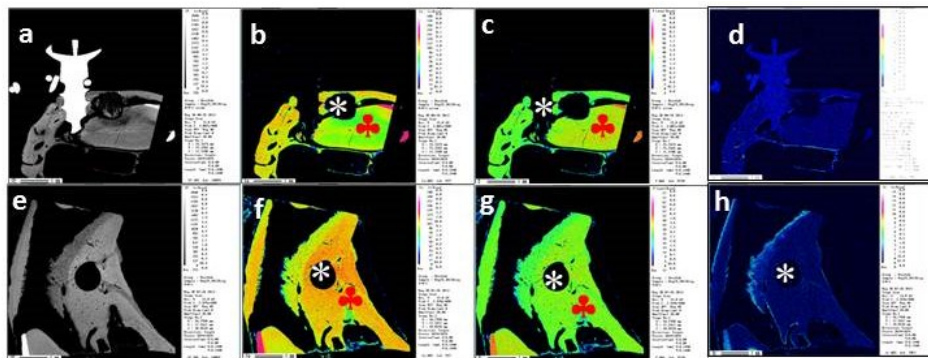


Figure 3-7: Sagittal (a) and cross-sectional (e) backscattered images and electron microprobe mapping of calcium (b, f); phosphorus (c, g); Strontium (d, h) composition of the alveolar bone surrounding the micro-TSAD. No evidence of recognizable difference in the calcium or phosphorus levels of bone immediately around the micro-TSAD and the surrounding preexisting bone (♣). (d, h) shows no strontium deposition in the alveolar bone immediately surrounding the micro-

TSAD. Lack of strontium deposition confirms no active bone remodeling and excellent micro-TSAD stability. * TSAD cavity. Scale bars = 1 mm in (a-h)

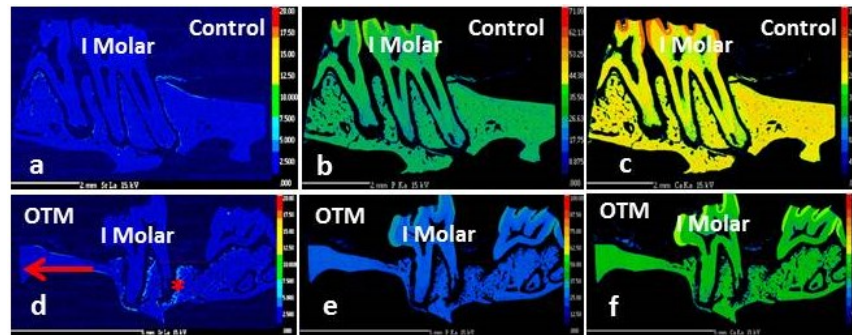


Figure 3- 8: Electron microprobe mapping of strontium (a, d) calcium (b, e); phosphorus (c, f) composition of the alveolar bone surrounding the upper left (control) and right first permanent molar (OTM) respectively. Panel d, shows increased Strontium deposition (*) surrounding the roots of right first permanent molar where OTM occurred. Evidence of increased strontium deposition indicates increased bone remodeling on the tension side of OTM. No difference in the Ca (b, e) and P (c, f) composition could be seen between control and OTM side. OTM=Orthodontic Tooth Movement. Scale bars = 2 mm in (a-c); 5 mm in (d-f)

3.5.4 Histological results:

Fig. 9 shows hematoxylin and eosin stained sections of rat maxilla at level of first molar (Fig. 9a,b) and TSAD. (Fig. 9d) While no active remodeling is seen on the control side, robust alveolar bone remodeling with stretching of PDL fibers, enlarged blood vessels is seen on the tension side of right first permanent molar. (Fig. 9c) The alveolar bone surrounding the TSAD had good bone-TSAD contact with no signs of cellular infiltrate. (Fig. 9d) Inadvertent infiltration and damage to the PDL was also seen with this tooth movement model.

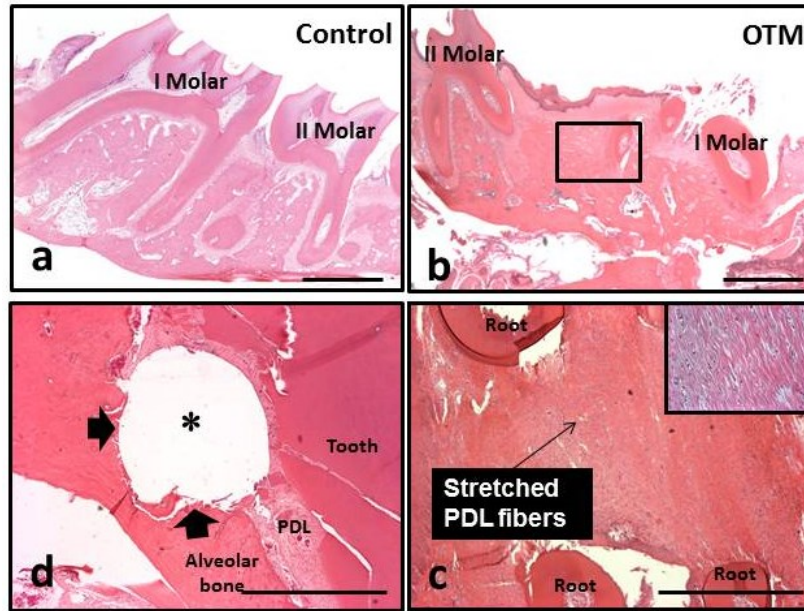


Figure 3-9: Histologic hematoxylin and eosin stained paraffin sections of the maxillary left (a) and right (b) first permanent molar area. While normal bone remodeling occurs on the control side with no gap between the first and second molar (a) increased separation between the first and second permanent molars (tooth movement) and increased bone remodeling is evident on the tension side of OTM (b). (c) Higher magnification of boxed area in (b) with stretched PDL fibers (Inset). (d) Alveolar bone surrounding the micro-TSAD. (arrows) with part of TSAD inadvertently into PDL space surrounding the tooth root. * denotes micro-TSAD space; scale bars = 1 mm

3.6 Discussion

Our study effectively used a TSAD as an anchorage device to facilitate OTM in rats. The results showed substantial tooth movement at 4 weeks (0.62 mm) and 8 weeks (1.99 mm) compared to baseline. With the exception of five TSADs (two failed between 0 and 4 weeks and three TSADs became loose between 4 and 8 weeks), the remaining twenty were stable and well integrated with the surrounding alveolar bone during the 8 week experimental period. Our success rate of 92% at 4 weeks and 80% at 8 weeks was comparable to a success rate of 83.6% reported in recent meta-analyses.^{18,19} Various factors affect TSAD stability during insertion and following loading and

can be broadly divided into factors affecting primary and secondary stability. Factors affecting primary stability play a role during the first month post insertion, after which factors affecting secondary stability take over. Thickness of overlying gingival tissue, TSAD design, diameter, length, pitch of screw and distance between threads and micro-motion during insertion all affect primary stability.^{20,21} High micro-motion coupled with early loading can lead to TSAD loosening and subsequent failure. Literature suggests a critical micro-motion level to be between 50 and 150 μm .²² Although our FE results showed a micro-motion of 0.136 μm , the micro-motion analyzed in our FE model was during load application and did not take into account micro-motion encountered during insertion. Excessive micro-motion due to increased insertion torques could lead to micro crack propagation in the alveolar bone resulting in accelerated bone turnover leading to TSAD loosening and failure. We hypothesize that loosening of two TSADs between week 0 and 4 was due to lack of primary stability from excessive micro-motion during insertion. The primary author found it very challenging to control insertion torque and minimize micro-motion due to the miniature size of the TSAD. Skeggs et al.²³ in their Cochrane review discussed that during TSAD placement, the surgeon should be aware of the depth of the TSAD into the actual bone and not the bone and soft tissue insertion. This is absolutely critical as a thick soft tissue biotype can deceive the clinician from achieving primary stability. In our study 1.5 mm insertion depth of the TSAD into the cortical bone was based on FE analysis wherein minimal displacement of the TSAD was observed (2.24 μm) even at 140 gms of force. The amount and type of force applied is critical for effective tooth movement to avoid critical failures. Bernhart et al.²⁴ showed that excessive force during orthodontic loading can lead to micro fractures and mobility, and light forces²⁵ can lead to adequate bone remodeling and accelerated stability.²⁶ Based on the FE results, 140 gms force was the amount that a rat maxillary bone ($\sigma=45.7$ MPa)

could tolerate without permanent deformation of the bone.²⁷ Although the maxillary bone could tolerate a force of 140 gms without permanent deformation, the loading force employed in our study using NiTi coil spring was ~ 30 gms as reported in literature³ as the amount of force need to protract a rat molar is very small. Miyawaki et al⁸ achieved 85% success rate of micro-screws and attributed the 15% failure rate to peri-implant inflammation. Freudenthaler et al.²⁸ and Roberts et al.²⁹ supported this view and showed the most important factors affecting TSAD stability was peri-implant inflammation rather than orthodontic loading. Based on FE results, less than 25 MPa von Mises stress and 0.64 μm displacement was observed, indicating ideal loading force for implant stability. Although we did not measure peri-implant inflammation, we hypothesize that peri-implant inflammation might cause accelerated bone turnover and TSAD loosening. Secondary stability of the TSAD starts about one month post TSAD insertion and depends on bone remodeling around the implant and amount of bone-to-implant contact. For bone remodeling to occur around the TSAD an optimal level of strain should be achieved not exceeding the critical limit of 4000 microstrain.³⁰ Our FE results showed maximal displacement of the alveolar bone around 0.64 μm . EPMA and histology showed adequate bone-to-implant contact with no signs of active bone turnover as evidenced by lack of Strontium deposition in the alveolar bone around the TSAD. Strontium is known to act as a surrogate to calcium during bone remodeling by replacing calcium in the newly forming bone. Lack of strontium deposition around the TSAD suggests no active bone remodeling indicating good secondary stability. (Fig. 7d,h) There were no changes in the densities of calcium and phosphorus of the bone immediately surrounding the TSAD in comparison to a distant but similar alveolar bone. (Fig. 7b,f,c,g) This was confirmed by histology with good implant-to-bone contact without any cellular infiltrate that would compromise secondary stability. (Fig. 9d) Although we were able to demonstrate no

active bone remodeling around the TSAD as evidenced by EPMA and histology, absolute anchorage with TSAD was not achieved. Literature shows evidence of 0-2.7 mm of TSAD displacement with maximum values upto 5.5 mm.^{31,32} Our results showed TSAD displacement of 0.42 mm at 4 weeks and 0.94 mm at 8 weeks. The rate of TSAD displacement was 0.014 mm/day from 0-4 weeks and 0.018 mm/day from 4-8 weeks. The rate and amount of TSAD displacement was not significant at 4 weeks. ($p \sim 0.057$) This failure to achieve absolute anchorage did not prevent using the TSAD as stable anchorage for tooth movement. Statistically significant tooth movement of the right first permanent molar was achieved with 0.62 mm and 1.99 mm of tooth movement at 4 and 8 weeks respectively. ($p \sim 0.0003$) The rate of tooth movement had an exponential increase from 0.022 mm/day by 4 weeks to 0.048 mm/day by 8 weeks. Both the amount and rate of tooth movement were comparable to published literature^{3,5,6,33} Bone remodeling with new bone formation on the tension side of first permanent molar was evident in EPMA analysis with increased strontium deposition (fig. 8d) and new bone formation with stretched PDL fibers on histological sections (Fig. 9b,c) indicating robust bone remodeling associated with orthodontic tooth movement.

Our study is the first to use TSADs as direct anchorage to facilitate tooth movement overcoming some of the inadequacies associated with previous rodent models of tooth movement. Many of the studies on orthodontic tooth movement in rats used inaccurate, unreliable and non-physiologic methods of tooth movement.²⁻⁵ We were able to show that TSADs could be used as a stable anchorage device with significant tooth movement at 4 and 8 weeks, adequate TSAD stability, maintenance of constant force levels and preventing harmful iatrogenic effects to both the maxillary and mandibular incisors teeth. In previous studies, maxillary incisors were used as anchorage to secure the appliance and to prevent appliance loosening during mastication and

physiologic eruption;⁵ the mandibular incisors were repeatedly ground down resulting in tooth fracture, pain, discomfort and occasional pulpal exposure of the incisors. Our study allowed for normal physiologic eruption of both the maxillary and mandibular incisors without any iatrogenic trauma and the orthodontic appliance using TSADs was stable enough to allow normal masticatory process. Most of the previous studies measured tooth movement from 2-4 weeks that did not provide clinically significant tooth movement to estimate the stability of the anchorage device.⁶ Our study was also able to provide evidence that TSADs could be used as direct anchorage to provide the optimal force levels to allow significant tooth movement of 2 mm up to 8 weeks. This amount of tooth movement was clinically significant along with statistical significance.

3.7 Conclusions

1. TSADs can be used as a stable anchorage device for OTM in rats.
2. Statistically significant amount of tooth movement was achieved with 0.62 mm at 4 weeks and 1.99 mm at 8 weeks.
3. Success rate of TSADs were 92% at 4 weeks and 80% at 8 weeks.
4. Absolute anchorage was not achieved with secondary TSAD displacement of 0.42 mm at 4 weeks and 0.094 mm at 8 weeks.

3.8 *References*

1. Krishnan V, Davidovitch Z. Cellular, molecular, and tissue-level reactions to orthodontic force. *Am J Orthod Dentofacial Orthop.* 2006;129:469 e461-432.
2. Karras JC, Miller JR, Hodges JS, Beyer JP, Larson BE. Effect of alendronate on orthodontic tooth movement in rats. *Am J Orthod Dentofacial Orthop.* 2009;136:843-847.
3. Gonzales C, Hotokezaka H, Yoshimatsu M, Yozgatian JH, Darendeliler MA, Yoshida N. Force magnitude and duration effects on amount of tooth movement and root resorption in the rat molar. *Angle Orthod.* 2008;78:502-509.
4. Dunn MD, Park CH, Kostenuik PJ, Kapila S, Giannobile WV. Local delivery of osteoprotegerin inhibits mechanically mediated bone modeling in orthodontic tooth movement. *Bone.* 2007;41:446-455.
5. Drevensek M, Volk J, Sprogar S, Drevensek G. Orthodontic force decreases the eruption rate of rat incisors. *Eur J Orthod.* 2009;31:46-50.
6. Ren Y, Maltha JC, Kuijpers-Jagtman AM. The rat as a model for orthodontic tooth movement--a critical review and a proposed solution. *Eur J Orthod.* 2004;26:483-490.
7. Costa A, Raffainl M, Melsen B. Miniscrews as orthodontic anchorage: a preliminary report. *Int J Adult Orthodon Orthognath Surg.* 1998;13:201-209.
8. Miyawaki S, Koyama I, Inoue M, Mishima K, Sugahara T, Takano-Yamamoto T. Factors associated with the stability of titanium screws placed in the posterior region for orthodontic anchorage. *Am J Orthod Dentofacial Orthop.* 2003;124:373-378.

9. Heymann GC, Tulloch JF. TSADable devices as orthodontic anchorage: a review of current treatment modalities. *J Esthet Restor Dent.* 2006;18:68-79; discussion 80.
10. Ylikontiola L, Sundqvist K, Sandor GK, Tormala P, Ashammakhi N. Self-reinforced bioresorbable poly-L/DL-lactide [SR-P(L/DL)LA] 70/30 miniplates and miniscrews are reliable for fixation of anterior mandibular fractures: a pilot study. *Oral Surg Oral Med Oral Pathol Oral Radiol Endod.* 2004;97:312-317.
11. Mimura H. Treatment of severe bimaxillary protrusion with miniscrew anchorage: treatment and complications. *Aust Orthod J.* 2008;24:156-163.
12. Seres L, Kocsis A. Closure of severe skeletal anterior open bite with zygomatic anchorage. *J Craniofac Surg.* 2009;20:478-482.
13. Weinstein AM, Klawitter JJ, Anand SC, Schuessler R. Stress analysis of porous rooted dental TSADs. *J Dent Res.* 1976;55:772-777.
14. Assunção WG, Gomes EA, Barão VA, de Sousa EA. Stress analysis in simulation models with or without TSAD threads representation. *Int J Oral Maxillofac TSADs.* 2009;24:1040-1044.
15. Geng JP, Tan KB, Liu GR. Application of finite element analysis in TSAD dentistry: a review of the literature. *J Prosthet Dent.* 2001;85:585-598.
16. Kavarizadeh A, Bourauel C, Jäger A. Experimental and numerical determination of initial tooth mobility and material properties of the periodontal ligament in rat molar specimens. *Eur J Orthod.* 2003;25:569-578.

17. Panahifar A, Maksymarych WP, Doschak MR. Potential mechanism of alendronate inhibition of osteophyte formation in the rat model of post-traumatic osteophyte: Evaluation of elemental strontium as a molecule tracer of bone formation. *Osteoarthritis Cartilage*. 2012;20:694-702.
18. Schätzle M, Männchen R, Zwahlen M, Lang NP. Survival and failure rates of orthodontic Temporary skeletal anchorage devices: a systematic review. *Clin Oral Implants Res*. 2009 Dec;20(12):1351-9
19. Crismani AG, Bertl MH, Celar AG, Bantleon HP, Burstone CJ. Miniscrews in orthodontic treatment: review and analysis of published clinical trials. *Am J Orthod Dentofacial Orthop*. 2010 Jan;137(1):108-13.
20. Park HS, Jeong SH, Kwon OW. Factors affecting the clinical success of screw implants used as orthodontic anchorage. *Am J Orthod Dentofacial Orthop*. 2006 Jul;130(1):18-25.
21. Kim JM, Kim SJ, Han I, Shin SW, Ryu JJ. A comparison of the implant stability among various implant systems: clinical study. *J Adv Prosthodont*. 2009 Mar;1(1):31-6.
23. Skeggs RM, Benson PE, Dyer F. Reinforcement of anchorage during orthodontic brace treatment with TSADs or other surgical methods. *Cochrane Database Syst Rev*. 2007:CD005098.
24. Bernhart T, Freudenthaler J, Dörtbudak O, Bantleon HP, Watzek G. Short epithetic TSADs for orthodontic anchorage in the paramedian region of the palate. A clinical study. *Clin Oral TSADs Res*. 2001;12:624-631.

25. Cheng SJ, Tseng IY, Lee JJ, Kok SH. A prospective study of the risk factors associated with failure of mini-TSADs used for orthodontic anchorage. *Int J Oral Maxillofac TSADs*. 2004;19:100-106.
26. Ohmae M, Saito S, Morohashi T, et al. A clinical and histological evaluation of titanium mini-TSADs as anchors for orthodontic intrusion in the beagle dog. *Am J Orthod Dentofacial Orthop*. 2001;119:489-497.
27. Mattila PT, Svanberg MJ, Jämsä T, Knuutila ML. Improved bone biomechanical properties in xylitol-fed aged rats. *Metabolism*. 2002;51:92-96.
28. Freudenthaler JW, Haas R, Bantleon HP. Bicortical titanium screws for critical orthodontic anchorage in the mandible: a preliminary report on clinical applications. *Clin Oral TSADs Res*. 2001;12:358-363.
29. Roberts WE, Marshall KJ, Mozsary PG. Rigid endosseous TSAD utilized as anchorage to protract molars and close an atrophic extraction site. *Angle Orthod*. 1990;60:135-152.
30. Frost HM. Wolff's Law and bone's structural adaptations to mechanical usage: an overview for clinicians. *Angle Orthod*. 1994;64(3):175-88. Review.
31. Lifshitz AB, Muñoz M. Evaluation of the stability of self-drilling mini-implants for maxillary anchorage under immediate loading. *World J Orthod*. 2010 Winter;11(4):352-6.
32. Hedayati Z, Hashemi SM, Zamiri B, Fattahi HR. Anchorage value of surgical titanium screws in orthodontic tooth movement. *Int J Oral Maxillofac Surg*. 2007 Jul;36(7):588-92.

33. Baloul SS, Gerstenfeld LC, Morgan EF, Carvalho RS, Van Dyke TE, Kantarci A.

Mechanism of action and morphologic changes in the alveolar bone in response to selective alveolar decortication-facilitated tooth movement. *Am J Orthod Dentofacial Orthop.* 2011 Apr;139(4 Suppl):S83-101.

**Chapter 4 Impact of Bisphosphonate Drug Bone Burden
during Orthodontic Tooth Movement in a Rat Model:
A Pilot Study**

4.1 Abstract

The purpose of this pilot study was to investigate the effect of long-term bisphosphonate drug use (bone burden) on orthodontic tooth movement in a rat model. **METHODS:** Sprague Dawley rats were used for orthodontic protraction of the maxillary first molars with nickel-titanium coil springs and Temporary skeletal anchorage devices as anchorage. Four groups of 5 rats each were included in the study; the first 2 groups were dosed with alendronate or a vehicle during concurrent orthodontic tooth movement. The third and fourth groups were pretreated for 3 months with alendronate or vehicle injections, and bisphosphonate drug treatment was discontinued before orthodontic tooth movement. Tooth movement measurements were obtained at 0, 4, and 8 weeks using high-resolution in-vivo microcomputed tomography, and the tissues were analyzed with histology and dynamic labeling of bone turnover. **RESULTS:** Appreciable tooth movement was achieved during the 8-week duration of this study with nickel-titanium coil springs and Temporary skeletal anchorage devices. Both bisphosphonate treatment groups exhibited reduced tooth movement compared with the vehicle-dosed controls with a tendency toward more severe reduction in the bisphosphonate predosed group. Concurrent dosing of the bisphosphonate drug resulted in 56% and 65% reductions in tooth protraction at the 4-week and 8-week times, respectively. The impact of bisphosphonate bone burden in retarding tooth movement was even greater, with 77% and 86% reductions in tooth movement at 4 and 8 weeks, respectively. **CONCLUSIONS:** In this study, we used a robust rat model of orthodontic tooth movement with Temporary skeletal anchorage devices. It has provided evidence that the bone burden of previous bisphosphonate use will significantly inhibit orthodontic tooth movement.

4.2 Introduction

Orthodontic tooth movement (OTM) occurs through the controlled application of mechanical forces creating a biologic response on teeth.¹ The resultant tooth movement is achieved through a myriad of events in the periodontal ligament (PDL) and surrounding alveolar bone.² Despite the clinical precision of orthodontic mechanics to facilitate the required tooth movement, some pharmacological agents such as bisphosphonate (BP) drugs commonly used to prevent and treat osteoporosis, a bone disease, can alter OTM when trapped in bone in sufficient concentration.³

BP drugs are structural non-hydrolyzable analogues of inorganic pyrophosphates⁴ and act by selective adsorption to bone mineral surfaces and subsequent inhibition of osteoclasts, the cells responsible for bone dissolution.⁵ BP drugs are extensively used for primary osteoporosis in adults along with glucocorticoid-induced secondary osteoporosis, Paget's disease of bone, hypercalcemia of malignancy and tumor-induced osteolysis.⁶ The nitrogen containing BP drugs exhibit greater antiresorptive potency due to their ability to interrupt the prenylation of cellular GTPases thus interfering with osteoclast survival and function.⁷ Alendronate, a nitrogen-containing BP, is one of the most common antiresorptive drugs used for the prevention and treatment of osteoporosis and has been shown to significantly reduce the incidence of new fragility fractures in osteoporotic women.⁸⁻¹⁰ Bone strength is determined by both stiffness (measure of toughness) and flexibility (measure of energy absorption), and optimal balance between bone quantity and quality is crucial to maintain health.^{11,12} Although BP drugs have been effective in the preservation of bone mass in patients with osteoporosis, recent studies question the effects of long term BP use. They show evidence of poor bone quality with decrease in energy-absorption capacity compared to normal bone.¹³ This sequelae predispose the bone to

atypical fractures especially in the femoral neck, lumbar spine and distal radius.^{14, 15} These drugs alter the material properties of the bone along with net changes in the mineral-matrix ratio, thereby leading to an increase in atypical fractures and/or osteonecrosis of the jaws^{16, 17} particularly in association with high-dose intravenous (IV) BP use.

Recent literature investigating the effect of various BP drugs on orthodontic tooth movement has to date been limited to rodent models and have used BP drugs either systemically or locally during OTM. They have shown BP drugs to significantly retard tooth movement in those rodent models.¹⁸⁻²⁴ In a recent study in rats, alendronate when administered concurrently with OTM inhibited tooth movement by 75% at 2 weeks and 58% at 4 weeks.¹⁸ 50% of alendronate drug that enters the blood stream following an oral dose gets preferentially bound to areas of high bone turnover.²⁵ Alveolar bone has 10-times more bone turnover than other bones, and correspondingly, the accumulation of BP drugs in alveolar bone is significantly higher.²⁶ The incorporation of BP drug during long term bisphosphonate use to treat osteoporosis can lead to substantial accumulation of the drug into bone. That continued accumulation (loading) of the drug over a prolonged period of time in effect serves to burden the normal bone remodeling process and we have coined the term “bone burden” to describe that phenomenon. Once incorporated, the BP drug would be released slowly during physiologic bone turnover and to a greater degree during accelerated remodeling processes associated with orthodontic tooth movement. This will likely have adverse outcomes on bone turnover during attempts to move the tooth roots into BP loaded bone, due to the drug’s ability to interfere with osteoclastic activity.

There is limited scientific evidence currently available on the actual consequence of accomplishing orthodontic tooth movement in patients undergoing, or who have undergone, a regimen of BP drug therapy (a clinical scenario of an individual taking long term bisphosphonate

drugs to treat Osteoporosis and interested in orthodontic alignment of his/her dentition). This bone burden effect which can result from bisphosphonates remaining attached to the bone tissue from previous BP use and being released during active remodeling process, such as in natural remodeling or OTM, can have adverse outcomes, and have not been investigated. Thus, particularly during bone healing or the linear phase of OTM, where activated bone cells orchestrate resorption of mineralized bone, cells will encounter BP drug molecules that have become trapped in the bone matrix due to their affinity for calcium ions and mineralized tissues. We hypothesized that, when this bone burden of incorporated BP drug was released into the local micro-environment, it will interfere with bone cell activity, resulting in cell death and retardation of remodeling, OTM and/or bone healing. The objective of this animal study was to evaluate and quantify the inhibition of tooth movement associated with long term alendronate use.

4.3 Methods

4.3.1 Experimental protocol and design of OTM appliance:

Twenty 12-wk old female Sprague Dawley rats were used in this study and were randomly assigned to 4 cohort groups (n=5/group); a) Control vehicle (saline) concurrent-dosed, b) BP concurrent-dosed (0.015 mg/kg s.c. dosed concurrently twice weekly during OTM for 8 weeks), c) Control vehicle (saline) pre-dosed for 12 weeks prior to, and subsequent OTM for 8 weeks, and d) BP pre-dosed (0.015 mg/kg s.c. pre-dosed for 12 weeks prior to, and subsequent OTM for 8 weeks). This antiresorptive twice-weekly sub-cutaneous dosing schedule for the BP drug alendronate has previously been used successfully in rats.^{27, 28} The 12 week predosing interval

was chosen to mimic an effective dose of bisphosphonate capable of blocking bone resorption over the 12 week period.

The Control group followed the same dosing schedule using saline vehicle instead of the active drug. The experimental design and dosing schedule is shown in Figure 1.

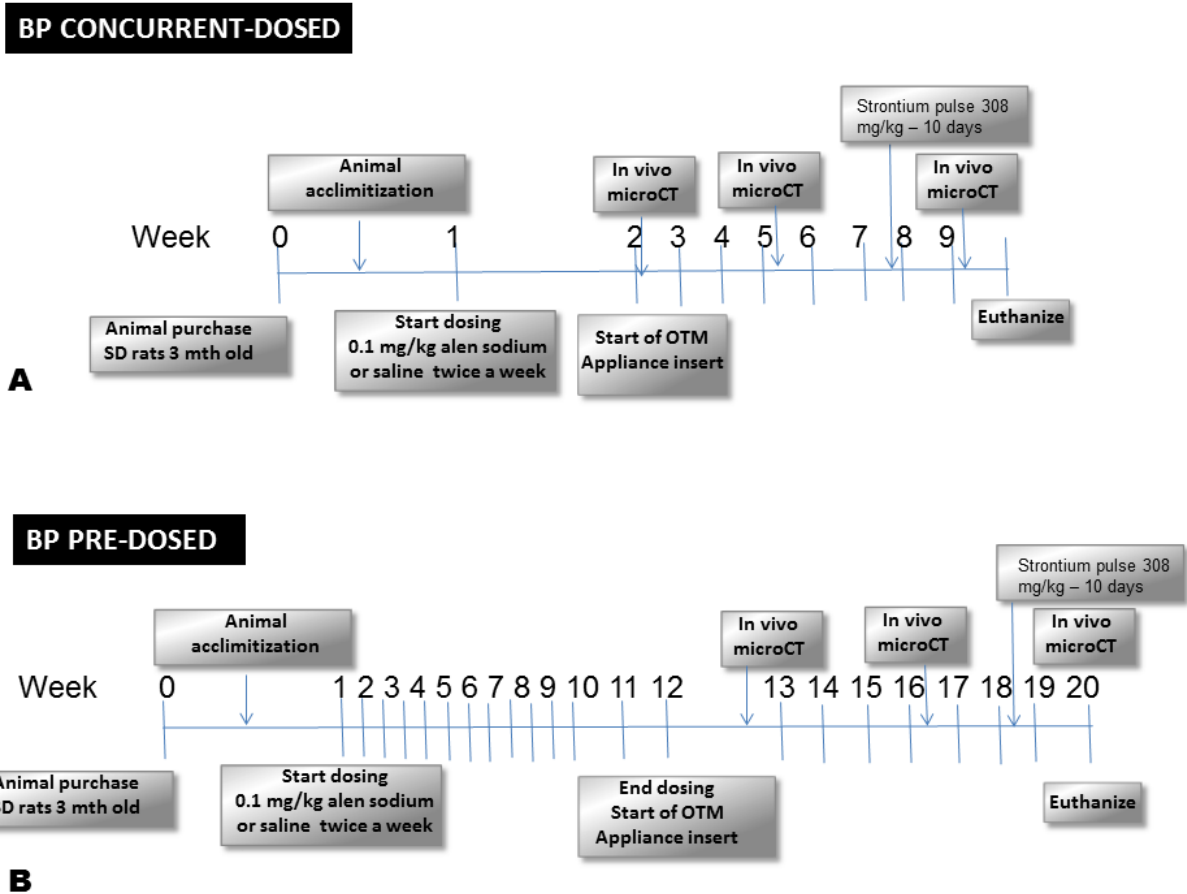


Figure 4-1: Experimental design and time schedules for (A) BP concurrent-dosed and (B) BP pre-dosed groups and their respective controls. Alendronate sodium or saline dosing was started 1 week prior to and concurrent with OTM for 8 weeks and in-vivo μ CT scanning was done at 0, 4, 8 weeks of OTM with a strontium 10 day pulse prior to euthanasia. (A) Alendronate or saline dosing started 12 weeks prior to OTM and OTM was continued for 8 weeks with μ CT scanning at 0, 4, 8 weeks of OTM and a strontium 10 day pulse prior to euthanasia (B)

Ethics approval was obtained from the University animal care and use committee. Animals were purchased from University biosciences, and housed with 12 hours dark and light cycles. All animals were fed standard lab soft diet *ad libitum*. To insert TSADs and coil springs, rats were anesthetized using 2% Isoflurane/L oxygen, (Forane[®], Baxter, Deerfield, IL) and placed supine in a custom designed surgical jig which maintained the rat's obligate nasal inhalation of anesthetic, while permitting retraction of the mandible to expose the maxilla and palate. A small 4 mm semi-lunar incision was made from the disto-palatal gingival margin of the maxillary right incisor posteriorly using a No.15 surgical blade. After achieving adequate hemostasis, a pilot hole was drilled in the maxillary bone at a 45° angle using a 1/2 mm round bur attached to an NSK slow speed electric dental handpiece (Brassler, Savannah, GA). A self-threading Stryker 1.2 x 3 mm titanium Temporary skeletal anchorage device (TSAD, Stryker-Leibinger Inc, Hamilton, ON) was inserted to a depth of 1.5 mm into the alveolar bone at about 12-14 mm distance from the mesial aspect of the right first permanent molar. The fit and stability of the TSAD into the alveolar bone was verified physically by finger pressure, using a side to side and in-out motion. A stainless steel ligature wire was placed around the neck of upper right first permanent molar and secured in position by tightening. A 9 mm closed coil NiTi spring (GAC International, Bohemia, NY) was secured to the right first permanent molar and the implant neck anteriorly with 0.010" stainless steel ligature. The appliance was left in place for 8 weeks to achieve appreciable tooth movement, as measured by μ CT imaging (described below). The left side acted as an intra-animal control with no appliance. The surgical TSAD placement and appliance insertion is shown in Figure 2.

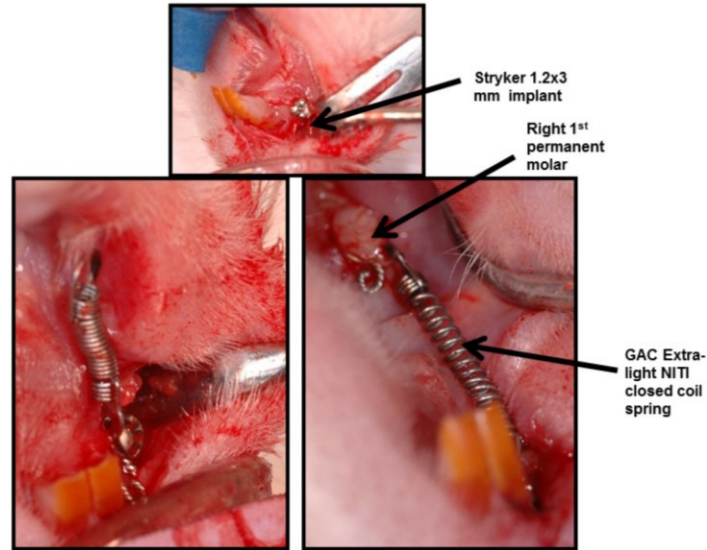


Figure 4-2: Orthodontic appliance in the right maxilla for tooth movement using micro-implant and NiTi closed coil spring.

4.3.2 Force-displacement measurements:

NiTi-closed coil springs (stated by the manufacturer GAC International to exert 50 g of force; GAC International, Bohemia, NY) were tested for force levels at different displacements using an Instron universal testing machine with load cell capacity +/- 1 kN. (Model No. 4443; Instron®, Norwood, MA) Briefly, an acrylic resin attached to a hook was glued on the lower platen and GAC light NiTi closed coil spring was attached from the hook to the upper loading crosshead. Loading and unloading curves were generated by applying a constant displacement of 2.5 mm/min up to 12 mm of displacement.

4.3.3 μ CT Assessment of OTM:

In-vivo μ CT imaging (SkyScan 1076 *in-vivo* imager, SkyScan NV, Kontich, Belgium) was performed on all animals at baseline (0 weeks), 4 and 8 weeks of OTM. All scans were conducted at 100 kV, 100 μ A through 180° with a rotation step of 0.5° to produce serial

projectional images of isotropic $18 \mu\text{m}^3$ voxels. All images were processed using bundled commercial software. Data was Gaussian filtered and globally threshold to extract the mineralized phase representing the 3D bone architecture. Visualization of the 3D architecture was generated to provide a qualitative assessment of bone structure. Measurements were made between the first and second right maxillary molars at all timepoints.

4.3.4 Measuring tooth movement using μCT :

Briefly, μCT rendered 2D scans were reconstructed as .bmp files and viewed using SkyScan Data Viewer software. (SkyScan NV, Kontich, Belgium) The 2D slices displayed as three orthogonal sections in X, Y, Z planes of space were centered at the desired point inside the reconstructed space. Once the image was centered in all three planes, the linear distance from the most convex contact area between the upper right first and second molar was measured and recorded. Measurements were recorded at 0, 4, 8 weeks and amount of tooth movement was obtained by subtracting the distance obtained at 4 and 8 weeks from baseline reading. Measurements were performed by the primary author (NK) in a blinded fashion, and repeated for reliability. ($r=0.93$) (Fig. 3)

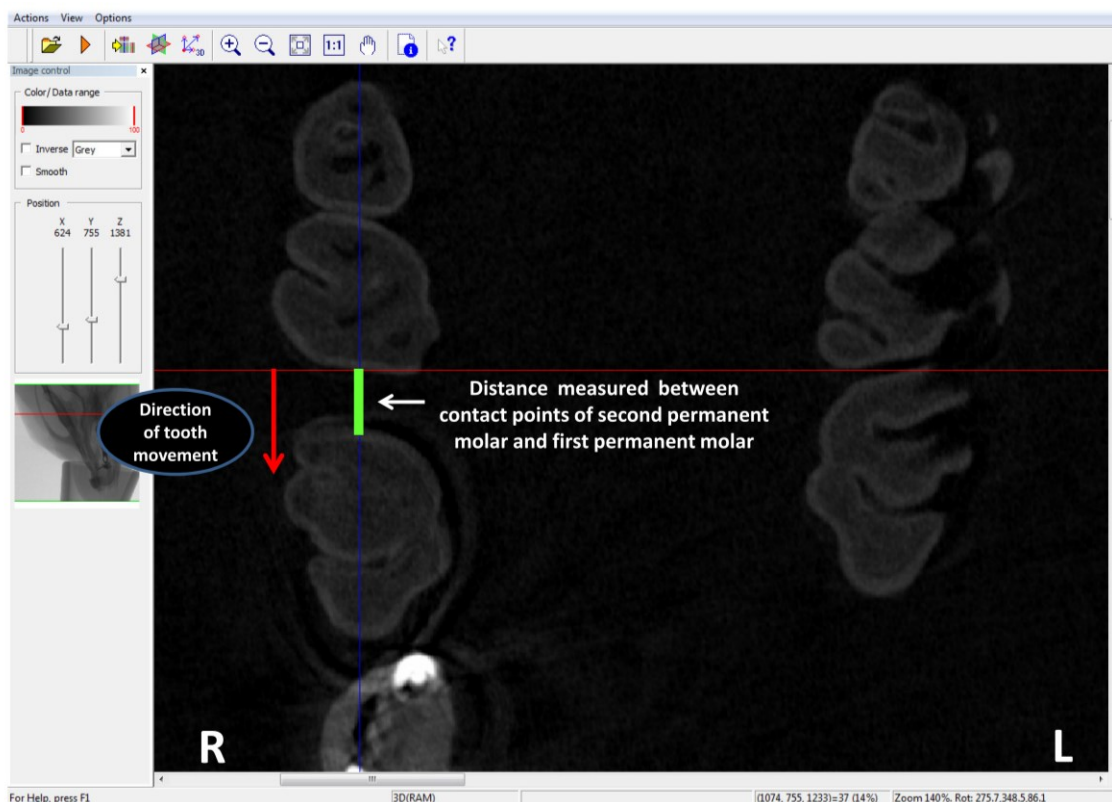


Figure 4-3: Image of μ CT rendered 2D scan viewed with Data Viewer software for measuring tooth movement. Once the image was centered in three planes of space, the linear distance between the most convex contact area between the upper right second and first permanent molar was measured and recorded at 0, 4 and 8 weeks and the amount of tooth movement was estimated by measuring the difference in tooth movement at 4, 8 weeks compared to baseline (0 weeks)

4.3.5 Histological assessment:

At the experiment end point (8 weeks) all animals were euthanized using isoflurane/ CO_2 to effect, and the right and left maxilla dissected, stored in 4% paraformaldehyde (Sigma-Aldrich Canada Co. Oakville, ON) and fixed for 1 week with frequent changes. Following fixation, each hemi maxillae was cut sagittally at the level of first permanent molar. The palatal half was processed for the spatial mapping of bone turnover using Electron-Probe Microanalysis (EPMA), with the buccal half being processed for routine histology. All samples processed for histology were rinsed and immersed in 4.13% EDTA (Disodium Ethylene Diamine Tetra Acetic acid - Sigma-Aldrich Canada Co. Oakville, ON) decalcifying

solution for 3 weeks. After decalcification, samples were paraffin embedded and sagittal sections (6 μm) were cut and stained with H&E for routine histological examination by light microscopy.

4.3.6 Electron probe microanalysis of dynamic Strontium label:

All animals were given a brief 10 day pulse of elemental Strontium (Strontium ranelate, PROTOS[®], Servier Laboratories, Australia, 308 mg/kg/day body weight) by gavage prior to being euthanized. We have previously shown, sub-therapeutic levels of elemental Strontium will serve as an exquisite dynamic tracer for bone turnover capable of detection by electron probe micro analyzer (Cameca SX-100, CAMECA Instruments, Inc. Madison WI) at very high resolution.²⁹ EPMA was performed on the palatal half of the right first permanent molar for spatially mapping the location and distribution of elemental Strontium. Briefly, the first molar sagittal section was defatted in acetone, embedded in epoxy resin, progressively polished ($\sim 0.5 \mu\text{m}$) and scanned to analyze the Ca, Sr and P content in both BP dosed group and controls.

4.4 Statistical Analysis

This pilot data (n=5/group) was not assumed to be normally distributed due to small sample size and a non-parametric approach was used for statistical analysis. To compare mean amount of tooth movement at 4 and 8 weeks respectively among the groups, a Kruskal-wallis H non-parametric test was performed with significance level set at 95% ($\alpha\sim 0.05$). The hypothesis of interest was whether the tooth movement was same regardless of the drug use, namely:

H_0 : Mean amount of tooth movement is the same among groups at 4, and 8 weeks

H_a : Mean amount of tooth movement is different among the groups at 4, and 8 weeks

SPSS 16.0 statistical software was used to analyze the data. OTM measurements, weight change in animals and force level change of the NiTi closed coil spring obtained from age-matched cohorts were used for statistical analyses. All quantitative data was expressed as the mean \pm standard deviation (S.D.). A value of $P < 0.05$ was considered statistically significant. Mann-Whitney U test was performed for individual comparison between groups with the p-value set at $\alpha \sim 0.016$.

4.5 Results

None of the animals encountered post-operative complications or infection, although some food impaction was observed around the implant site. All animals remained healthy and survived the experimental process without any statistically significant loss of weight in any of the four groups at 4 ($p \sim 0.262$) and 8 weeks ($p \sim 0.1$). Four animals (two in BP concurrent-dosed and two in control concurrent-dosed groups) exhibited spontaneous appliance loosening necessitating removal of the implant and removal of those animals from the study.

4.5.1 Force-displacement measurement:

Figure 4 shows the loading and unloading curves of all the NiTi springs used in the study. There was no difference in the mean force levels at 0 weeks between controls (29.5 ± 7.4) and BP dosed rats (30.6 ± 3.1). In addition, the experimental animal model showed no statistically significant changes in the force levels among different groups at 4 ($p \sim 0.76$) and 8 weeks ($p \sim .918$).

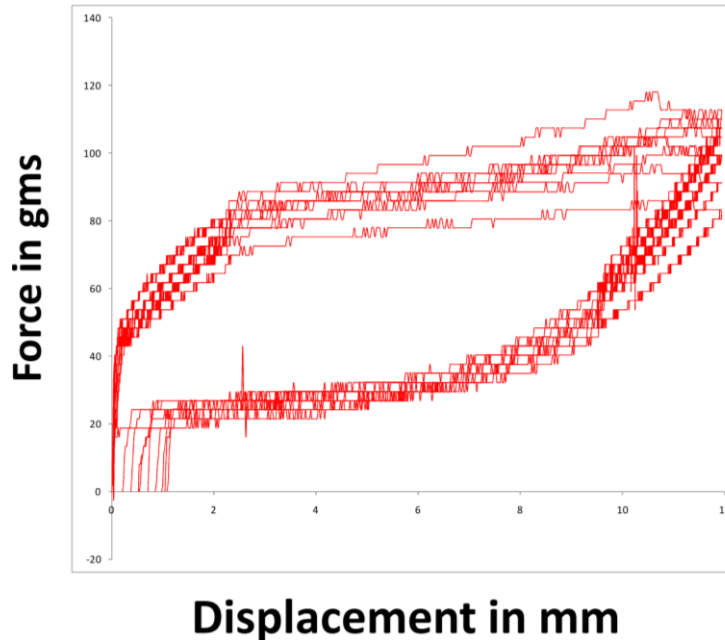


Figure 4- 4: Loading and unloading curves of NiTi closed coil springs measured using Instron universal testing machine with a load cell +/- 1kN. Loading and unloading curves were generated by applying a constant displacement of 2.5 mm/min up to 12 mm of displacement.

4.5.2 BP dosing with OTM:

Descriptive statistics of tooth movement between the groups at different time points are presented in Table 1. The difference in tooth protraction between control and the BP dosed groups was evident qualitatively upon examination of 3D μ CT renderings at 0, 4 and 8 weeks at the coronal level (Figures. 5). Non-parametric ANOVA showed statistically significant difference among all four groups at 4 weeks ($P \sim 0.008$) and at 8 weeks ($p \sim 0.008$). In terms of measured distance (in mm), results showed statistically significant reduction in tooth movement of 0.51 ± 0.1 mm (77% reduction) and 1.7 ± 0.1 mm (86% reduction) at 4 ($p \sim 0.009$) and 8 weeks ($p \sim 0.009$) respectively between BP pre-dosed and controls. As the significance level was set at $\alpha \sim 0.016$, the BP concurrent-dosed group showed non-significant reduction in tooth movement

compared to its respective control at 4 weeks ($p \sim 0.05$) and 8 weeks ($p \sim 0.05$) and the amount of reduction was only 0.48 ± 0.1 mm (56%) and 1.2 ± 0.2 mm (65%) at 4 and 8 weeks respectively as shown in figure 6. There was no significant difference between the treatment groups (BP pre-dosed group and BP concurrent-dosed group) at 4 weeks ($p \sim 0.053$) and 8 weeks. ($p \sim 0.297$)

GROUP	Mean weight change at 4 wks (Mean±S.D) in gms	Mean weight change at 8 wks (Mean±S.D) in gms	Mean force level change at 4 wks (Mean±S.D) in gms	Mean force level change at 8 wks (Mean±S.D) in gms	OTM at 4 wks (Mean±S.D) in mm	OTM at 8 wks (Mean±S.D) in mm	Mean diff OTM at 4 wks (Mean±S.D.) in mm	Mean diff OTM at 8 wks (Mean±S.D.) in mm
Control pre-dosed	41.5±56.4	59.8±49.9	-3.8±6	-4.9±6.5	0.6±0.2	1.9±0.3	0	0
BP pre-dosed	-0.6±20.5	10±14.3	-2.2± 2.3	-2.7±1.9	0.05±0.06	0.2±0.1	-0.5±0.2	-1.7±0.4
Control concurrent-dosed	23.8±11.5	29.4±9.2	-0.3±0.5	-1.4±1.5	0.7±0.2	1.7±0.0	0.2±0.2	-0.2±0.4
BP concurrent-dosed	24.1±19.3	32.1±15.4	-0.8± 0.6	-1.6±1.5	0.3±0.1	0.5±0.4	-0.3±0.2	-1.4±0.4

Table 4-1: Mean changes in the animal weight, force levels and tooth movement measured at 4, 8 weeks respectively compared to baseline (0 weeks) in all four groups.

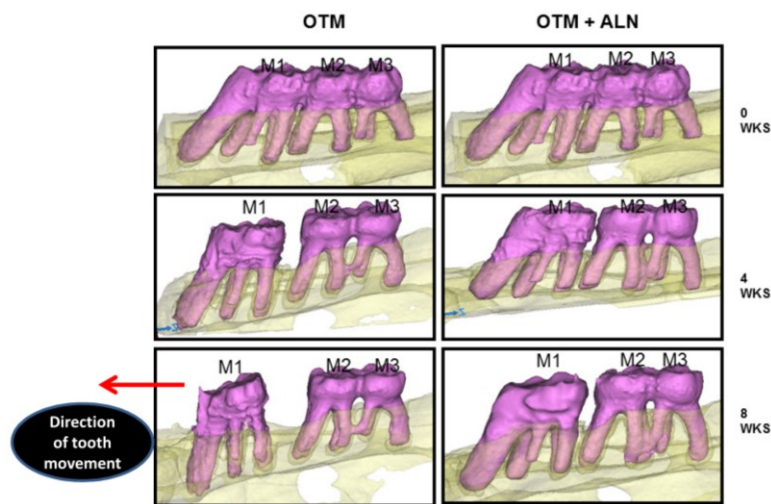


Figure 4-5: 3D μ CT rendered representative model showing difference in tooth movement in control and BP pre-dosed rats at 0, 4 and 8 weeks. (M1, right first permanent molar; M2, right second permanent molar; M3, right third permanent molar)

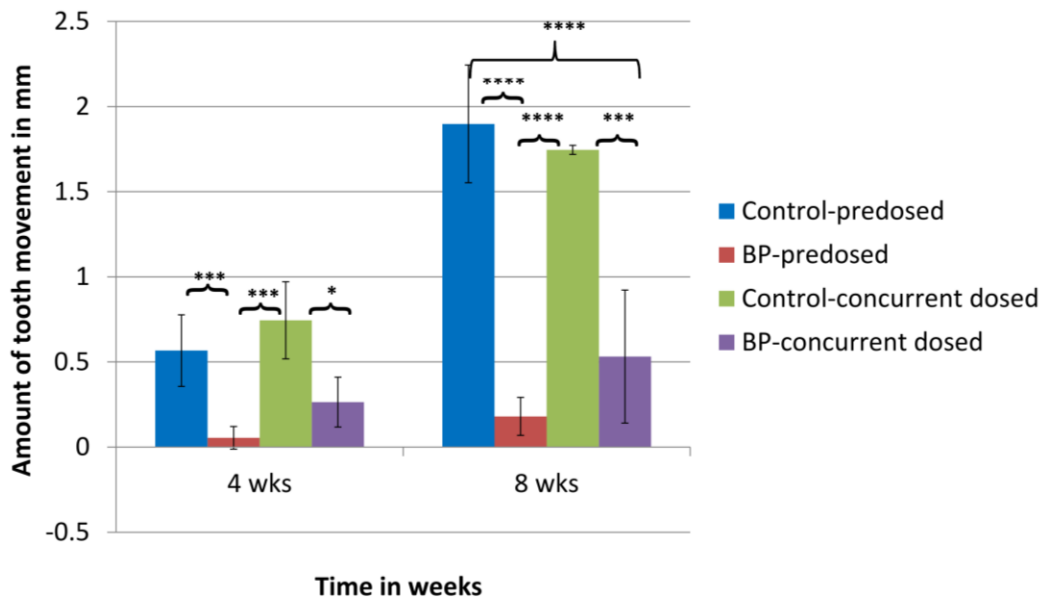


Figure 4-6: Mean amount of tooth movement measured at 4 and 8 weeks in all four groups. (Significance level set at 0.016: *; > 0.0016: **; > 0.00016: ***)

4.5.3 EPMA:

We readily detected elemental strontium deposition in newly mineralizing alveolar bone using EPMA, as a dynamic label of bone turnover in the final 10 days of orthodontically-induced tooth movement and subsequent bone remodeling. Results showed increased strontium deposition on the tension side of the tooth movement, (*) with minimal or no deposition on the compression (or pressure) side in control animals. BP dosed animals showed decreased strontium deposition (♣) both on the pressure and tension side of first permanent molar tooth (Fig. 7).




Figure 4-7: EPMA rendered images of upper right first molar region of (A) control and (B) BP drug burden group depicting increased strontium deposition in the control group (*) and negligible strontium deposition in the BP burden group (♣). The warmer color (light blue) indicates strontium deposition (*) wherein the strontium molecule replaces calcium during new bone deposition at the tension side of the tooth following tooth movement. Due to negligible tooth movement and lack of alveolar bone remodeling very limited to none strontium deposition is seen in the BP drug group as shown (♣) (MP-mesiopalatal; DP-distopalatal).

4.5.4 Histology:

Hematoxylin and eosin stained sections of rat maxilla at the level of first molar demonstrated evidence of tooth movement with increased bone resorption on the pressure side and increased bone formation on the tension side (sites of PDL fiber stretching and cement line formation). With respect to newly forming bone in the bisphosphonate laden group (pre-dosed

group), distinct morphological areas lacking bone remodeling was evident with decrease in bone remodeling and retraction of osteoclasts from the bone surface (Figure. 8).

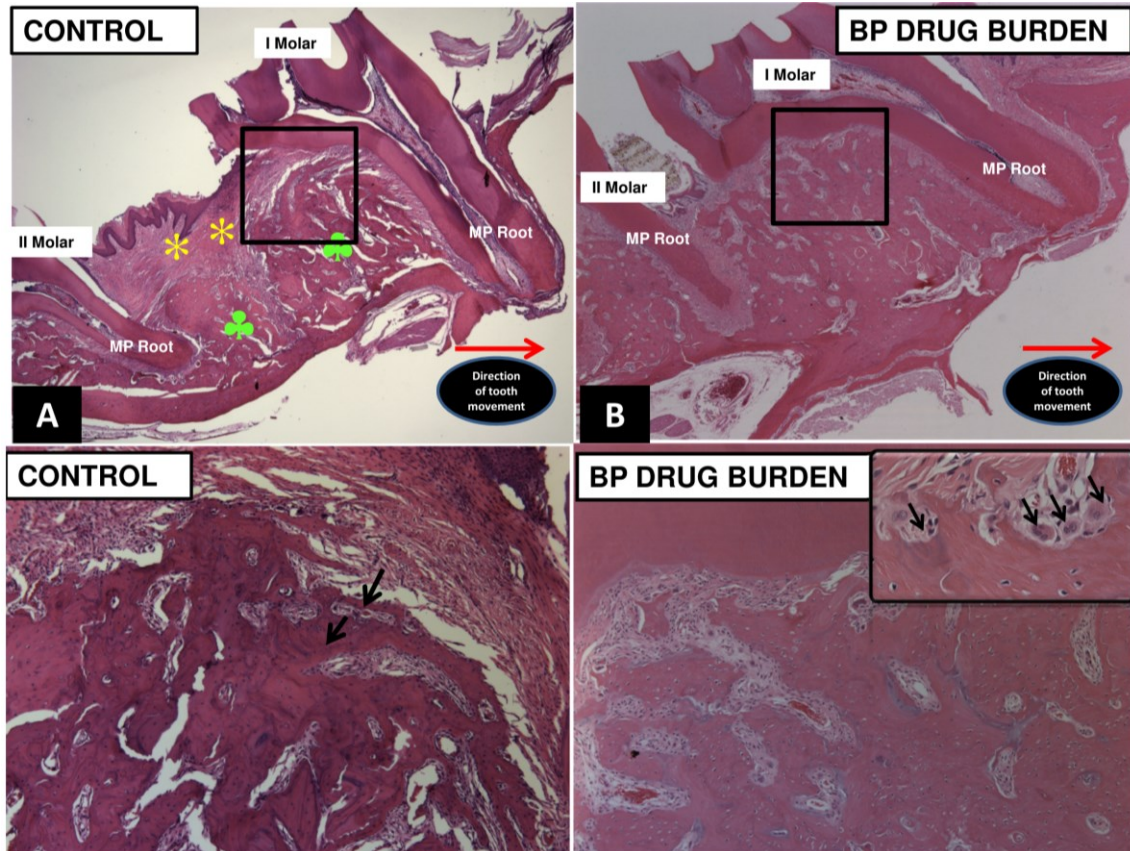


Figure 4-8: Histologic H & E stained sections of upper right first molar area in (A) control and (B) BP burden group showing decreased tooth movement in the BP burdened group. (magnification 2.5x) While the control animals showed normal features of alveolar bone remodeling following tooth movement including stretching of the gingival and periodontal ligament fibers (*), and increased bone remodeling (♣), the BP dosed animals showed lack of active bone remodeling. Lower panels (C and D) show higher magnification of the interseptal bone in the first molar area. (Magnification 10x) Panel C shows active bone remodeling with cement lines (arrows) depicting areas of new bone formation whereas the BP burden group showed presence of bony islands (♣) due to lack of active remodeling, lesser vascular channels and greater fibrotic component with regular and round shaped osteoclasts lacking ruffled border (arrows- Inset panel D) (MP-mesiopalatal).

4.6 Discussion

We used this novel model of OTM to investigate the effect of bone burden of a potent nitrogen-containing BP (alendronate sodium), a commonly used therapeutic bisphosphonate drug. It is important to note that several dental studies have been published on the potential benefits of BP drug use in orthodontics to confer tooth anchorage. In the earlier published literature, the aim was to prevent undesirable movement of anchor teeth or to prevent relapse following OTM.¹⁸⁻²⁴ However, there are no studies published to date that examined the effect of BP bone burden on tooth movement simulating the clinical situation, wherein a patient on long term bisphosphonate therapy would come into an orthodontic practice requesting orthodontic alignment of teeth and would be advised to stop the bisphosphonate drug as it would interfere with and inhibit orthodontic tooth movement. It is known that BP drugs can remain in the skeleton (especially the jaw bones) long after discontinuation of their use due to their long terminal half-life (e.g. alendronate sodium ~ 10 years). Resultantly, this burden of BP drug in bone can have significant impact during OTM treatment, as cells involved in the biologic process of tooth movement (such as osteoclasts) are modified by BP drugs and rendered inactive.

We demonstrated that prior BP drug use will significantly inhibit tooth movement by 77% and 86% after 4 and 8 weeks of tooth movement respectively (BP drug burden group), when compared to control rats. The 12 week predosing interval in the BP burden group was arbitrarily chosen to mimic prior long term bisphosphonate usage in light of the reduced life span of a Sprague Dawley rat (~ 2 yrs) in comparison to humans. It is impossible to compare our findings with previous scientific literature as this is the first study to look at the bone burden effect of bisphosphonate drugs. The only scientific literature currently available by Karras

(2009)¹⁸ showed 58% reduction in tooth movement at 4 weeks in the BP drug group, where in the drug treatment was started during OTM which was similar to findings in our study of 56% reduction at 4 weeks and 65% reduction in 8 weeks of tooth movement in BP concurrent-dosed group. Result from our investigation clearly demonstrates that long term BP drug use can have a significant inhibitory effect on orthodontic tooth movement. A recently published retrospective survey out of Washington State estimated 10% of females' age > 50 years that underwent orthodontic treatment had history of bisphosphonate use. They also concluded that extraction therapy in these patients resulted in longer treatment times with incomplete space closure and less than ideal root approximation.³⁰ Our finding is significant as it highlights the importance for the orthodontist in obtaining detailed health histories of current and previous medications, in order to assess the limitations in treatment planning decision making and potentially forsake an "ideal OTM result" in order to prevent risk of necrotic bone associated with slower tooth movement in BP laden bone. Although we were able to show at least 20% reduction in tooth movement in the BP bone burden group compared to BP concurrent-dosed group, we could not demonstrate statistically significant difference with $p \sim 0.053$ and $p \sim 0.297$ at 4 and 8 weeks respectively. This lack of statistical significance probably was due to loss of two animals from the BP concurrent dosed group due to appliance loosening which decreased the sample size in this drug group.

We used alendronate sodium (Fosamax) because Fosamax was the 19th most commonly prescribed medication in the United States in 2005³¹ when bisphosphonates were the drug of choice for post-menopausal osteoporosis. With emerging evidence about the long term retention of bisphosphonate drugs in the bone and their adverse effects, including, esophageal cancer, bone, muscle and joint pain, atypical fractures, acute phase reactions, atrial fibrillation,

hypocalcemia and potentially debilitating osteonecrosis of the jaw¹⁵ the orthodontist is faced with the dilemma of gauging the relative risk of BRONJ (Bisphosphonate Related Osteonecrosis of Jaw) occurrence in this patient population. Although the risk of BRONJ in osteoporosis patients is rare (incidence of 0.09 to 0.38%³²) the constant remodeling encountered during OTM along with bacterial colonization in the oral cavity can predispose the risk for BRONJ that has not been adequately determined. Furthermore, potent IV bisphosphonates are also used in children to treat osteopenia, Paget's disease, osteogenesis imperfecta, hypercalcemia of malignancy etc, and these young patients who might present to the orthodontist for treatment likely have a higher risk for BRONJ.³³ The dosing and the drug administration regime was based on previous studies who used subcutaneous administration of alendronate sodium in rats to achieve the desired therapeutic effect^{27,28} and was based on body-mass conversion factors used to simulate long term BP drug use to treat osteoporosis in humans. Although our effort was to closely duplicate a clinical scenario, our results obtained with this animal model should be interpreted with caution. The sub-cutaneous dosing helped us to bypass the stomach and prevent the side effects of upset stomach, gastrointestinal pain, dysphagia, inflammation and erosion of esophagus associated with oral dosing of bisphosphonate drugs.¹⁵ With the sub-cutaneous dosing we did not observe any side effects and the animal weight did not change significantly at different time points when compared to the control rats (p~0.262 at 4 weeks and p~0.094 at 8 weeks)

Our study further highlighted the utility of elemental strontium as a dynamic tracer of newly mineralizing bone, by acting as a surrogate for calcium in areas of active remodeling. As seen under EPMA, bisphosphonate laden bone showed a distinct absence of strontium deposition

on the tension side of tooth movement indicating significant inhibition of bone remodeling, in comparison to the warmer colors seen at the tension side of control animals with substantial strontium deposition in these animals indicating robust bone remodeling associated with orthodontic tooth movement (Figure 7). This lack of bone remodeling in BP burdened animals might make the bone susceptible to osteonecrosis. This “non-exposed” variant of osteonecrosis of the jaws has previously been reported in a case-series published by Fedele et al who showed 1/3 of the total patients screened in that study had an unexposed variant of osteonecrosis.³⁴ Clinicians need to be aware that this transient stage of osteonecrosis (or unexposed variant) can still result in severe jaw bone pain, sinus tracts and bone swelling prior to leading to necrotic bone exposure. Bisphosphonates inhibit bone remodeling by having a direct effect on osteoclasts. When the osteoclasts adhere to bone surface during bone turnover events, they encounter BP drug molecules which are then internalized by the osteoclasts. Once internalized the BP drug molecules interfere with melovonate pathway and prevent formation of GTPases needed for formation of ruffled border and cell adhesion of the osteoclasts and render them inactive and further causes apoptosis.⁷ Our histological data showed that osteoclasts in the BP burden group were round in shape, detached from the bone surface with lack of ruffled border further providing proof that BP laden group has enough bisphosphonate molecules that cause apoptosis of osteoclasts, the critical cell need for orthodontic bone remodeling. (Panel D, Figure 8).

In summary, despite orthodontic treatment being primarily undertaken in adolescents, a growing number of adult patients are seeking orthodontic care.³⁵⁻³⁷ A recent survey showed adults comprising 20% of all orthodontic patients and this number is on the rise.³⁸ This paradigm shift challenges our current understanding of the role of bisphosphonate drugs in orthodontics.⁴

Our current study has provided evidence that bisphosphonate bone burden can significantly inhibit orthodontic tooth movement and can prevent active bone remodeling. Thus, it is imperative that future studies investigate further, the effects of bisphosphonate bone burden during active orthodontic treatment and associated bone remodeling and develop treatment plans which avoid patient harm whilst achieving desired OTM treatment outcomes. Future studies should investigate the effect of drug holiday on the outcome of bisphosphonate drug induced inhibition of tooth movement and whether there would be substantial difference from the present study. We hypothesize that, due to long terminal half-life of the drug (~ 10 years) there would not be significant changes in the inhibitory effect of these drugs on orthodontic tooth movement even with a drug holiday.

4.7 Conclusion

1. This pilot study demonstrated that Alendronate sodium significantly inhibited tooth movement by 86% at 8 weeks and 77% at 4 weeks in the bone burden group versus age-matched control rats.
2. The reduction in tooth movement was 20% greater in the bone burden group than the BP concurrent-dosed group, although the difference was not statistically significant.
3. The inhibition of tooth movement and lack of bone remodeling as shown by EPMA should caution the Orthodontist in formulating ideal treatment plans to avoid longer treatment times and/or adverse orthodontic outcome

4.8 References

1. Krishnan V, Davidovitch Z. On a path to unfolding the biological mechanisms of orthodontic tooth movement. *J Dent Res* 2009;88:597-608.
2. Krishnan V, Davidovitch Z. Cellular, molecular, and tissue-level reactions to orthodontic force. *Am J Orthod Dentofacial Orthop* 2006;129:469 e1-32.
3. Krishnan V, Davidovitch Z. The effect of drugs on orthodontic tooth movement. *Orthod Craniofac Res* 2006;9:163-71.
4. Zahrowski JJ. Optimizing orthodontic treatment in patients taking bisphosphonates for osteoporosis. *Am J Orthod Dentofacial Orthop* 2009;135:361-74.
5. Russell RG. Bisphosphonates: mode of action and pharmacology. *Pediatrics* 2007;119 Suppl 2:S150-62.
6. Landesberg R, Eisig S, Fennoy I, Siris E. Alternative indications for bisphosphonate therapy. *J Oral Maxillofac Surg* 2009;67(5 Suppl):27-34.
7. Russell RG, Watts NB, Ebetino FH, Rogers MJ. Mechanisms of action of bisphosphonates: similarities and differences and their potential influence on clinical efficacy. *Osteoporos Int* 2008;19:733-59.
8. Liberman UA, Weiss SR, Broll J, Minne HW, Quan H, Bell NH, et al. Effect of oral alendronate on bone mineral density and the incidence of fractures in postmenopausal osteoporosis. The Alendronate Phase III Osteoporosis Treatment Study Group. *N Engl J Med* 1995;333:1437-43.

9. Black DM, Cummings SR, Karpf DB, Cauley JA, Thompson DE, Nevitt MC, et al. Randomised trial of effect of alendronate on risk of fracture in women with existing vertebral fractures. Fracture Intervention Trial Research Group. *Lancet* 1996;348:1535-41.
10. Cummings SR, Black DM, Thompson DE, Applegate WB, Barrett-Connor E, Musliner TA, et al. Effect of alendronate on risk of fracture in women with low bone density but without vertebral fractures: results from the Fracture Intervention Trial. *JAMA* 1998;280:2077-82.
11. J. Fritton, M.B. Schaffler. Bone quality. R. Marcus, D. Feldman, D. Nelson, C. Rosen (Eds.), *Osteoporosis* (3rd ed.), Academic Press, New York, NY 2007;625–641.
12. P. Chavassieux, E. Seeman, P.D. Delmas. Insights into material and structural basis of bone fragility from diseases associated with fractures: how determinants of the biomechanical properties of bone are compromised by disease. *Endocr Rev* 2007;28:151–164.
13. M. R. Allen, D. B. Burr. Changes in vertebral strength-density and energy absorption-density relationships following bisphosphonate treatment in beagle dogs. *Osteoporos Int.* 2008; Jan19(1):95-9.
14. Ing-Lorenzini K, Desmeules J, Plachta O, Suva D, Dayer P, Peter R. Low-energy femoral fractures associated with the long-term use of bisphosphonates: a case series from a Swiss university hospital. *Drug Saf* 2009;32:775-85.
15. Abrahamsen B. Adverse effects of bisphosphonates. *Calcif Tissue Int* 2010;86:421-35.
16. Cohen HV. Bisphosphonate-associated osteonecrosis of the jaw: patient care considerations: overview for the orthopaedic nursing healthcare professional. *Orthop Nurs* 2010;29:176-80.

17. Pazianas M, Miller P, Blumentals WA, Bernal M, Kothawala P. A review of the literature on osteonecrosis of the jaw in patients with osteoporosis treated with oral bisphosphonates: prevalence, risk factors, and clinical characteristics. *Clin Ther* 2007;29:1548-58.
18. Karras JC, Miller JR, Hodges JS, Beyer JP, Larson BE. Effect of alendronate on orthodontic tooth movement in rats. *Am J Orthod Dentofacial Orthop* 2009;136:843-7.
19. Keles A, Grunes B, Difuria C, Gagari E, Srinivasan V, Darendeliler MA, et al. Inhibition of tooth movement by osteoprotegerin vs. pamidronate under conditions of constant orthodontic force. *Eur J Oral Sci* 2007;115:131-6.
20. Liu L, Igarashi K, Haruyama N, Saeki S, Shinoda H, Mitani H. Effects of local administration of clodronate on orthodontic tooth movement and root resorption in rats. *Eur J Orthod* 2004;26:469-73.
21. Sato Y, Sakai H, Kobayashi Y, Shibasaki Y, Sasaki T. Bisphosphonate administration alters subcellular localization of vacuolar-type H(+)-ATPase and cathepsin K in osteoclasts during experimental movement of rat molars. *Anat Rec* 2000;260:72-80.
22. Igarashi K, Adachi H, Mitani H, Shinoda H. Inhibitory effect of the topical administration of a bisphosphonate (risedronate) on root resorption incident to orthodontic tooth movement in rats. *J Dent Res* 1996;75:1644-9.
23. Igarashi K, Mitani H, Adachi H, Shinoda H. Anchorage and retentive effects of a bisphosphonate (AHBuBP) on tooth movements in rats. *Am J Orthod Dentofacial Orthop* 1994;106:279-89.

24. Adachi H, Igarashi K, Mitani H, Shinoda H. Effects of topical administration of a bisphosphonate (risedronate) on orthodontic tooth movements in rats. *J Dent Res* 1994;73:1478-86.
25. Rogers MJ, Gordon S, Benford HL, Coxon FP, Luckman SP, Monkkonen J. Cellular and molecular mechanisms of action of bisphosphonates. *Cancer* 2000;88(12suppl):2961-78.
26. Dixon RB, Tricker ND, Garetto LP. Bone turnover in elderly canine mandible and tibia. *J Dent Res* 1997;76:336.
27. Hayami T, Pickarski M, Wesolowski GA, McLane J, Bone A, Destefano J, Rodan GA, Duong le T. The role of subchondral bone remodeling in osteoarthritis: reduction of cartilage degeneration and prevention of osteophyte formation by alendronate in the rat anterior cruciate ligament transection model. *Arthritis Rheum* 2004;50(4):1193-20630.
28. Campbell GM, Bernhardt R, Scharnweber D, Boyd SK. The bone architecture is enhanced with combined PTH and alendronate treatment compared to monotherapy while maintaining the state of surface mineralization in the OVX rat. *Bone* 2011;49(2):225-232
29. Panahifar A, Maksymowych WP, Doschak MR. Potential mechanism of alendronate inhibition of osteophyte formation in the rat model of post-traumatic osteoarthritis: evaluation of elemental strontium as a molecular tracer of bone formation. *Osteoarthritis Cartilage* 2012;20:694-702.
30. Lotwala RB, Greenlee GM, Ott SM, Hall SH, Huang GJ. Bisphosphonates as a risk factor for adverse orthodontic outcomes. A retrospective cohort study. *Am J Orthod Dentofacial Orthop* 2012;142:625-34

31. IMS Health Incorporated [Internet]. Parsippany, NJ; 2005 [accessed 2012 March 12]. Available from www.imshealth.com.
32. Mavrokokki T, Cheng A, Stein B, Goss A. Nature and frequency of bisphosphonate-associated osteonecrosis of the jaws in Australia. *J Oral Maxillofac Surg* 2007;65:415-23.
33. American Association of Oral and Maxillofacial Surgeons position paper on bisphosphonate-related osteonecrosis of the jaws. *J Oral Maxillofac Surg* 2007;65:369-76.
34. Fedele S, Porter SR, D'Aiuto F, Aljohani S, Vescovi P, Manfredi M, et al. Nonexposed variant of bisphosphonate-associated osteonecrosis of the jaw: a case series. *Am J Med* 2010;123:1060-4.
35. Cedro MK, Moles DR, Hodges SJ. Adult orthodontics--who's doing what? *J Orthod* 2010;37:107-17.
36. Nattrass C, Sandy JR. Adult orthodontics--a review. *Br J Orthod* 1995;22:331-7.
37. Buttke TM, Proffit WR. Referring adult patients for orthodontic treatment. *J Am Dent Assoc* 1999;130:73-9.
38. Keim R. Orthodontic practice study, Part I: trends. *J Clin Orthod* 2009;43:625-34.

**Chapter 5 Impact of Selective Alveolar Decortication on
Bisphosphonate Burdened Alveolar Bone during Orthodontic
Tooth Movement**

5.1 Abstract

The purpose of this study was to investigate the effect of Selective Alveolar Decortication (SADc) facilitated orthodontic tooth movement (OTM) on bisphosphonate burdened alveolar bone in a rodent model. OTM was accomplished by protraction of the maxillary right first molars. Four groups were included of which two groups were pretreated for three months with alendronate sodium (BP+TM+SADc and BP+TM group) and two groups were given saline (TM+SADc and TM group). Selective alveolar decortication surgery was performed on day 1 of appliance insertion. OTM measurements were obtained at 0, 4, and 8 weeks using in-vivo μ CT. Tissues were also analyzed with histology and dynamic labeling of bone turnover. Our results showed appreciable tooth movement of 0.39 mm and 0.75 mm in the BP+TM+SADc group at 4 and 8 weeks respectively with 113% increase in tooth movement compared to BP+TM group at 4 weeks and only 10% increase at 8 weeks. In comparison, SADc+TM group showed 0.63 mm and 2.1 mm of tooth movement at 4 weeks and 8 weeks respectively with only 6% increase at 4 weeks and 2% increase at 8 weeks compared to TM group. Severe interproximal and buccal bone loss around the first permanent molar in the BP+TM+SADc group was seen with μ CT imaging and histology. Some animals in BP+TM+SADc group histologically showed signs of osteonecrotic bone with irregular borders, loss of osteocytes and absence of osteocytic lacunae. This study demonstrated selective alveolar decortication accelerates tooth movement in a bisphosphonate burdened alveolar bone in the short term but the potential of such an invasive injury can be have adverse effects.

Key words: Orthodontic tooth movement, Bisphosphonate, Bone burden, Selective alveolar decortication, μ CT imaging, Electron probe microanalysis.

5.2 Introduction

Orthodontic tooth movement occurs as a result of orchestrated activity of bone cells (osteoclasts and osteoblasts) that remodel alveolar bone to facilitate the required tooth movement. The force system acting on the tooth generates strains in the surrounding periodontal ligament and the alveolar bone, producing areas of compression and tension that results in resorption on the side of pressure and bone formation on the tension side.¹ The rate and amount of tooth movement is affected by the rate of bone turnover.² To date, various treatment modalities have been investigated to accelerate tooth movement including; corticotomy,^{3,4,5,6,7} low level laser therapy,^{8,9} mechanical vibration,¹⁰ pulsed electromagnetic therapy,¹¹ electrical currents¹² and distraction osteogenesis.^{13,14,15} Even biologic approach to accelerate tooth movement have been attempted through invitro¹⁶ and *in vivo* localized RANKL gene therapy.¹⁷ A recent systematic review by Long et al.¹⁸ showed that corticotomy is an effective modality to accelerate tooth movement and is relatively safe compared to any other method.

Corticotomy is a surgical procedure to accelerate rate of orthodontic tooth movement by causing localized osteopenia and accelerated bone metabolism as a result of controlled surgical damage¹⁹. Frost (1983) coined the term “Regional Acceleratory Phenomenon (RAP)” to explain this tissue response.²⁰ RAP is usually seen following a fracture to long bones and involves recruitment, proliferation and activation of progenitor cells necessary for wound healing. The tissue response during RAP involves decreased bone mineral density and accelerated bone turnover.²¹ The sequence of events during RAP associated tissue injury include; initiation within a few days of injury, peaking at 1-2 months and effects typically lasting 4 months.^{21,22} Many animal^{3,23,24,25} and human studies²⁶ have demonstrated the phenomenon of reversible osteopenia

and accelerated tooth movement using corticotomy. Ren et al.²⁴ showed accelerated tooth movement without associated root resorption and pulpal damage in beagle dogs and Mostafa et al.²⁵ showed doubled rate of tooth movement in dogs. Wilcko and colleagues patented a technique called Periodontally accelerated osteogenic orthodontics (PAOO) wherein mucoperiosteal flap is raised and osteotomy cuts in the cortical bone is performed alongside tooth roots accompanied by small perforations into the alveolar bone, and a resorbable bone graft placed to augment bone. This is followed by faster activation of orthodontic appliance with every two week intervals to accelerate tooth movement.²⁷

A rat model²⁸ demonstrated the actual biological response to corticotomy induced tissue damage. The authors showed that the increased turnover rate in alveolar bone is a result of anabolic and catabolic modeling which increases by third week of tissue injury with decrease to normal remodeling levels by seventh week and stabilization by eleventh week of alveolar decortication surgery.²⁸ The same group using a rat model showed that selective alveolar decortication enhanced the total tooth displacement from 5.30 mm in the traditional tooth movement group to 6.94 mm in the combined SADc+TM group as a result of increase in osteoclastic and osteoblastic activity and alveolar bone remodeling.⁶

Wilcko et al.²² proposed that corticotomy accelerated tooth movement should be contraindicated in moving ankylosed teeth; and tooth movement in areas of devitalized bone such as with long term use of bisphosphonates or steroid therapy. Bisphosphonate drugs have been extensively used to prevent and treat primary osteoporosis, glucocorticoid-induced secondary osteoporosis, hypercalcemia of malignancy, tumor-induced osteolysis and paget's disease of bone.²⁹ The ability of bisphosphonate molecules to be trapped in large quantities in the bone and released

during normal and active bone remodeling, can lead to apoptosis of osteoclasts,³⁰ the cells needed for bone resorption associated with orthodontic tooth movement.³¹ Prolonged use of bisphosphonate drugs have been shown to cause atypical fractures of femur and spine³² and osteonecrosis of the jaws especially with invasive dental procedures such as tooth extractions and dental implant placement.^{33,34} We have recently shown that bisphosphonate burdened alveolar bone from long term bisphosphonate use can significantly inhibit the rate and amount of tooth movement in a rat model.³⁵ To date there has not been any published studies that looked at the effect of selective alveolar decortication on remodeling changes in bisphosphonate burdened alveolar bone and associated tooth movement. We hypothesize that selective alveolar decortication will accelerate OTM in BP-burdened rats but the beneficial effects of such an injury is questionable.

The objective of this animal study was to evaluate and quantify the acceleration of tooth movement associated with selective alveolar decortication in the alveolar bone of a bisphosphonate burdened rat model and to further investigate the tissue effects of such an invasive injury.

5.3 Materials and Methods

5.3.1. Research Design:

Ethics approval was obtained from the University of Alberta animal care and use committee. The study included 34 female Sprague-Dawley rats (age, 12 weeks) purchased from Biosciences, University of Alberta and randomly assigned to 4 cohort groups. The animals were housed with two in a cage with 12-hour dark-and-light cycles. All animals were fed a standard laboratory soft diet ad libitum. Two groups were pretreated for three months with Alendronate sodium (0.015

mg/kg subcutaneously) (BP+TM group (n=7) and BP+TM+SADc group (n=10)) and two groups were pretreated with saline (TM group (n=7) and TM +SADc group (n=10). The two groups with selective alveolar decortication surgery (SADc) had the surgical procedure completed at the time of orthodontic appliance insertion. The experimental design and dosing schedule are shown in **Figure 1**.

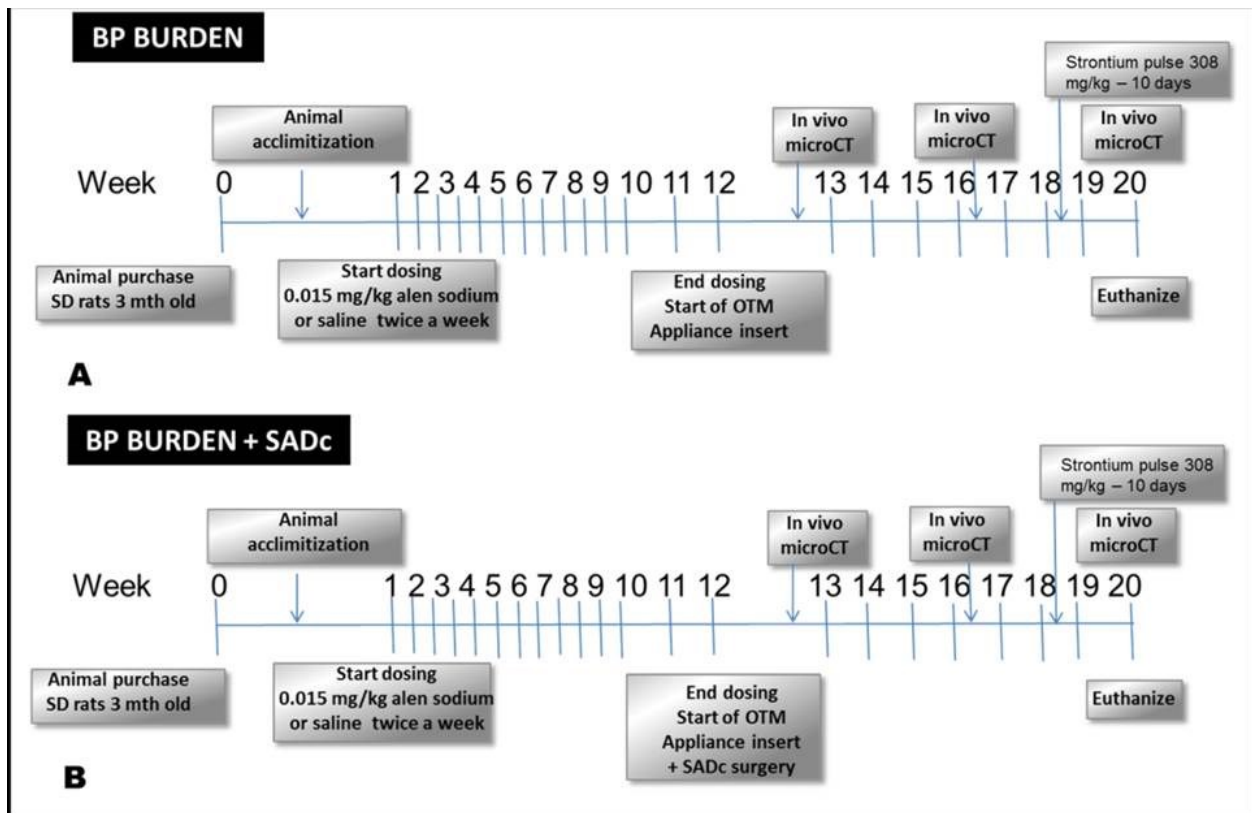


Figure 5-1: Experimental design and time schedules for experimental groups and their respective controls: A, BP burden group. B, BP burden + SADc group and their respective controls

5.3.2 Surgical Procedure and appliance insertion:

Selective alveolar decortication surgery was executed as per Baloul et al.⁶ Briefly, full thickness mucoperiosteal flap was raised following a sulcular incision made using a Bard Parker No. 15

blade around the sulcus of the maxillary first right permanent molar both buccally and palatally extending 5 mm mesially into the edentulous space. Five decortication indentations each; buccal and palatal of right first permanent molar 0.25x0.25 mm in diameter were made using No. ¼ round bur on a slow speed electric handpiece (NSK; Brassler, Savannah, GA). Flaps were sutured back using 6-0 Vicryl bioresorbable suture (Ethicon, Somerville NY) to obtain primary closure. Appliance insertion was similar to our previous study³⁶ using Temporary skeletal anchorage devices (Stryker-Leibinger, Hamilton, ON) and NiTi coil springs (GAC International, Bohemia, NY). In brief, the rats were anesthetized using 2% isoflurane/L oxygen (Forane; Baxter, Deerfield, Ill) and placed supinely in a custom-designed surgical jig that maintained the rat's obligate nasal inhalation of the anesthetic, while permitting retraction of the mandible to expose the maxilla and the palate. A small 4-mm semilunar incision was made from the distopalatal gingival margin of the maxillary right incisor posteriorly with a number 15 surgical bard parker blade. After achieving adequate hemostasis, a pilot hole was drilled in the maxillary bone at a 45° angle using a 0.5-mm round bur attached to slow-speed electric dental hand piece (NSK; Brassler, Savannah, GA). A self-threading 1.2x3 mm titanium Temporary skeletal anchorage device (Stryker-Leibinger, Hamilton, ON) was inserted to a depth of 1.5 mm into the alveolar bone about 12 to 14 mm from the mesial aspect of the right permanent first molar. The fit and stability of the Temporary skeletal anchorage device into the alveolar bone was verified by finger pressure, with a side-to-side and in-and-out motions. A stainless steel ligature wire was placed around the neck of the maxillary right permanent first molar and secured in position by tightening. A 9-mm closed-coil nickel-titanium spring (GAC International, Bohemia, NY) delivering ~25-30gms of force was secured to the right permanent first molar and the implant

neck anteriorly with a 0.010-in stainless steel ligature. The Appliance was left in place for 8 weeks to achieve appreciable tooth movement.

5.3.2 μ CT analysis of OTM:

In vivo μ CT scan (Skyscan 1076 “in-vivo” μ CT, Skyscan NV, Kontich, Belgium) of the alveolar bone surrounding the first molar and extending anteriorly to the maxillary incisors was performed at baseline (0 weeks) and repeated *in vivo* after 4 weeks and 8 weeks of appliance insertion. For all μ CT imaging, scans were conducted at 100 kV and 100 mA current through 180° with a rotation step of 0.5° to produce serial projectional images of isotropic 18- μm^3 voxels. All image data was processed using commercial software bundled with the μ CT system in our laboratory (DataViewer, Skyscan, Kontich BE). The acquired data was Gaussian filtered and underwent global thresholding to extract the mineralized phase representing the 3D tooth movement and bone architecture.

5.3.4 Measurement of Tooth movement:

The measurement of amount of tooth movement was accomplished as follows: In brief, microcomputed tomography-rendered 2-dimensional scans were reconstructed as .bmp files and viewed using Data Viewer software (DataViewer, Skyscan, Kontich BE). The 2-dimensional slices displayed as 3 orthogonal sections in the x, y, and z planes of space were centered at the desired point inside the reconstructed space. Once the image was centered in all 3 planes, the linear distance from the most convex contact area between the maxillary right first and second molars was measured and recorded for the amount of tooth movement. Measurements were obtained by the primary author (N.K.) in a blinded fashion and repeated for reliability one week apart. ($r=0.98$)

5.3.5 Histological assessment:

At the experiment end point (8weeks), all animals were euthanized using isoflurane followed by CO₂ inhalation to effect, and the right and left maxilla were immediately dissected, stored in 4% paraformaldehyde (Sigma-Aldrich Canada, Oakville, ON, Canada) and fixed for 1 week with frequent changes. Following fixation, one each hemi-maxillae of SADc and SADc + BP burden group were cut sagittally at the level of first permanent molar for qualitative histological and EPMA analysis. The palatal half was processed for spatial mapping of bone turnover using EPMA (Electron-Probe Microanalysis) and the buccal half was processed for routine histology. The rest of the animals were processed for quantitative histochemistry for alveolar bone surface area and surface perimeter changes. All samples processed for histology were rinsed with PBS (Phosphated Buffered Saline) wash buffer (pH 7.3) and immersed in 4.13% EDTA (Disodium Ethylene Diamine Tetra Acetic acid; Sigma-Aldrich Canada, Oakville, ON, Canada) decalcifying solution for 3 weeks. The tissue was checked and further decalcified if inadequate decalcification was observed. Following decalcification, samples were processed for routine histology by paraffin embedding. Sagittal sections (6 µm) were cut and stained with hematoxylin and eosin for routine histology.

5.3.6 Histomorphometric analysis:

For dynamic quantification of bone parameters; serial 6-µm thick cross sections were cut in the first molar area with a microtome every 100 µm and stained with hematoxylin and eosin. The sections were viewed using Leica light microscope (Leica Microsystems Inc., Concord, ON, Canada) and imaged using RS imaging software and CoolSNAP_{EZ} CCD camera (Photometrics, Tuscon, AZ, USA) at 5x original magnification. Histomorphometric analysis of bone parameters

was measured by sequentially analyzing the images using commercially available Adobe Photoshop® and Image J software as reported by Egan et al.³⁷ Briefly, the trabecular bone between all five roots of the first permanent molar was selected as a Region of Interest (ROI) consistent for all images (15 mm²); a black and white mask was created using Adobe Photoshop®, imported into Image J software and thresholded to measure bone area (BA) and perimeter and the results tabulated. (**Figure. 2**)

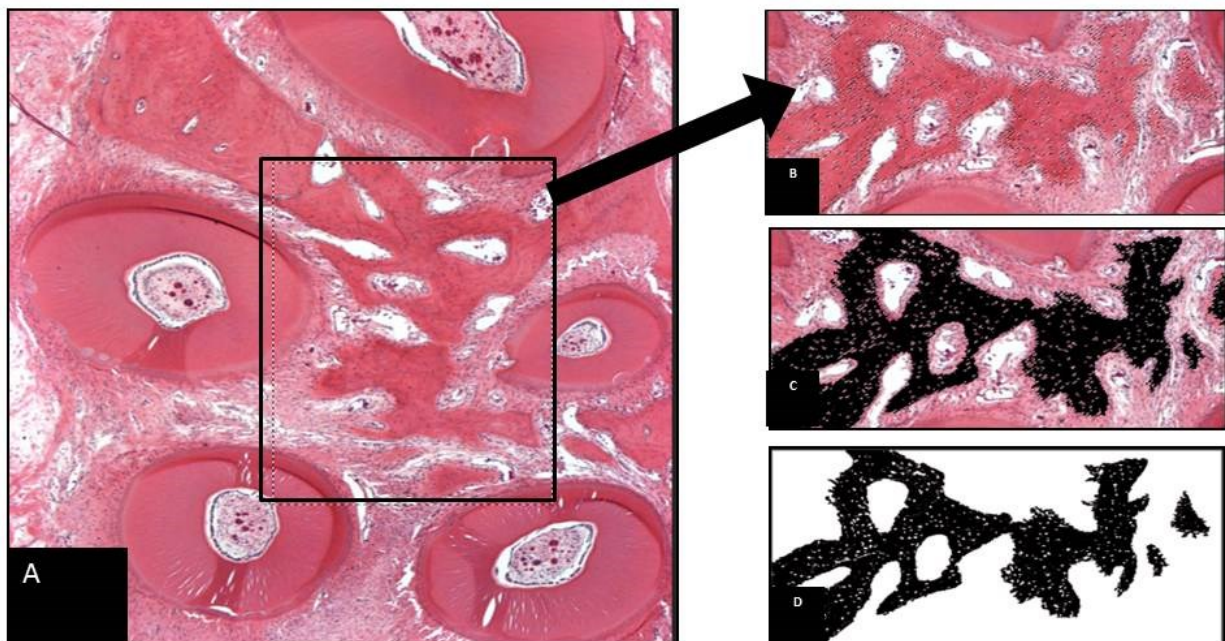


Figure 5-2: Histomorphometric analysis was performed for bone parameters with construction of the black and white image mask. (A) A region of interest was selected from a Hematoxylin and eosin stained section obtained at 5x magnification (B) The captured image was then opened in Adobe Photoshop® to prepare the black and white mask. Within the selected region of interest, bone was identified and represented in black (C) and the remaining non-bone area was selected as white. (D)

5.3.7 Electron Probe Micro-Analysis (EPMA):

Two animals from each group were randomly chosen and were given a brief 10-day pulse of elemental strontium (Strontium ranelate, PROTOS; Servier Laboratories, Hawthorn, Victoria, Australia; 308 mg/kg/day body weight – sub-therapeutic dosage at lower limit of therapeutic index) by gavage 10 days prior to euthanization. Strontium has been shown as an excellent dynamic label for bone turnover and can readily be detected by EPMA at high spatial resolution.³⁸ EPMA was performed on the palatal half of the right first permanent molar for spatially mapping the location and distribution of elemental, Sr, Ca, and Phosphate (P). Briefly, the first molar sagittal sections were defatted in acetone for 1 week, dried in a 40°C oven, embedded in epoxy resin (Epo-Kwick®, Beuhler Ltd., Lake Bluff, IL, USA), progressively polished (~ 0.5 µm) and scanned at 2 and 5 µm resolution and current set at 15kV and 30nA to analyze the Ca, Sr and P content of the alveolar bone surrounding the control left permanent first molar and orthodontically moved right first permanent molar using a Cameca SX100 electron probe (Cameca, Paris, France) and vendor supplied PeakSight 4.1 (Cameca, Paris, France) analysis software.

5.4 Statistical Analysis

SPSS statistical software (version 16.0; SPSS, Chicago, IL, USA) was used to analyze the data. Descriptive statistics were analyzed as Means ± S.D (mm). OTM measurements, histomorphometric bone area and bone perimeter results obtained from age-matched cohorts were used for statistical analyses. To compare the mean amount of tooth movement at 4 and 8 weeks, mean difference in bone area and bone perimeter a Kruskal-Wallis H nonparametric test

was performed with the significance level set at 95% ($\alpha = 0.05$). A Mann-Whitney U post-hoc comparison was performed within groups to see individual variation.

5.5 Results

All surgeries and appliance insertion were performed by the primary author. (NK) No post-operative complications were observed. Meloxicam (2mg/kg body weight) was used as an analgesic for post-operative pain management. No significant loss of weight was observed in any group throughout the experimental period. Four animals (2 in BP+TM+SADc group and 2 in TM+SADc group) had spontaneous loosening of the TSAD necessitating removal of the animals from the study.

5.5.1 Magnitude of tooth movement:

The effectiveness of selective alveolar decortication on tooth movement was analyzed using μ CT. Figure 3 shows representative 3D rendered microcomputed tomography images of tooth movement in all four groups. The difference in the amount of tooth movement is visually evident in the bisphosphonate burdened animals (Fig 3C & 3D) compared to the control groups. (Fig 3A & 3B)

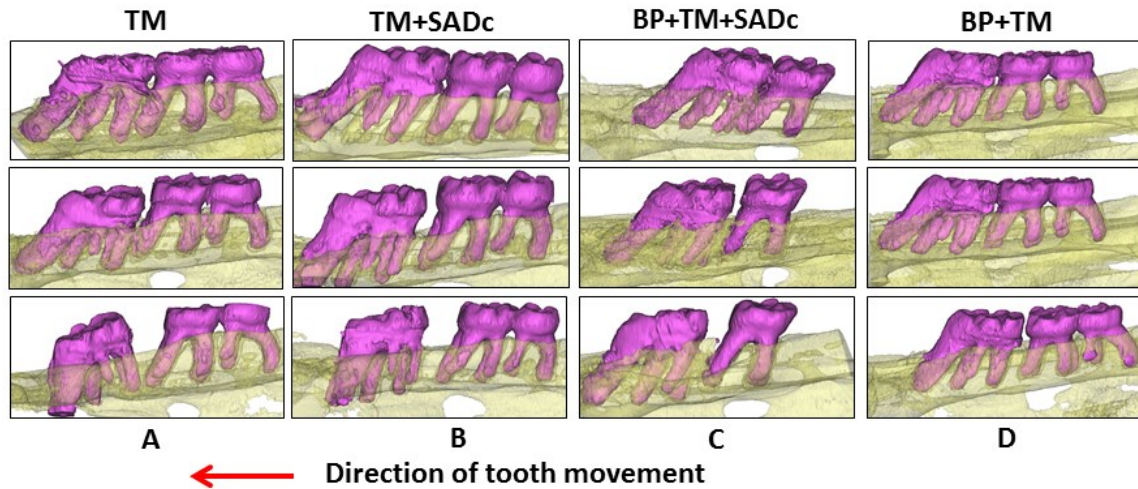


Figure 5-3: 3D μ CT rendered model showing difference in tooth movement in A, TM; B, TM+SADc; C, BP+TM and D, BP+TM+SADc rats at 0, 4 and 8 weeks. TM = Tooth Movement; SADc = Selective Alveolar Decortication; BP = Bisphosphonate burden; M1 = Upper right first permanent molar; M2 = Upper right second permanent molar; M3 = Upper right third permanent molar.

Table 1. shows the mean amount of tooth movement in all groups at 4 and 8 weeks.

Group	OTM at 4 weeks (Mean \pm SD) (mm)	OTM at 8 weeks (Mean \pm SD) (mm)	Mean Bone Area (Mean \pm SD) (mm ²)	Mean Bone Perimeter (Mean \pm SD) (mm)
Control	0.00 \pm 0.00	0.00 \pm 0.00	1.79 \pm 0.41	16.17 \pm 3.53
TM	0.57 \pm 0.21	1.9 \pm 0.35	1.48 \pm 0.62	20.98 \pm 3.07
TM+SADc	0.63 \pm 0.21	2.1 \pm 0.88	1.23 \pm 0.83	16.49 \pm 4.04
BP	0.00 \pm 0.00	0.00 \pm 0.00	1.63 \pm 0.19	15.95 \pm 0.69
BP+TM	0.07 \pm 0.05	0.18 \pm 0.11	1.62 \pm 0.5	16.39 \pm 2.25
BP+TM+SADc	0.39 \pm 0.1	0.75 \pm 0.014	1.69 \pm 0.21	14.41 \pm 2.69

Table 5-1. Mean amount of tooth movement measured at 4 and 8 weeks and histomorphometric measurement of bone area and bone perimeter in all 4 groups with left side acting as intra-animal control in bone burdened and control animals. OTM = Orthodontic Tooth Movement; TM = Tooth movement; SADc = Selective Alveolar Decortication; BP = Bisphosphonate burden; SD = Standard Deviation.

Kruskal-Wallis non-parametric test showed significant difference in the amount of tooth movement among all groups at 4 weeks ($p \sim 0.001$) and 8 weeks ($p \sim 0.0001$) (Fig 4).

Test Statistics ^{a,b}		
	fourweeks	eightweeks
Chi-Square	15.908	20.463
df	3	3
Asymp. Sig.	.001	.000

a. Kruskal Wallis Test
b. Grouping Variable: grouped

Figure 5-4: Kruskal Wallis non parametric test shows significant difference in the mean amount of tooth movement among all four groups at 4 weeks ($p \sim 0.001$) and 8 weeks ($p \sim 0.0001$)

To find out the individual variation, Mann-Whitney post-hoc test was done to test the actual difference between individual groups. At 4 and 8 weeks, there was a non-significant 6% and 2% increase in tooth movement respectively in TM+SADc group compared to TM group. (Fig 5)

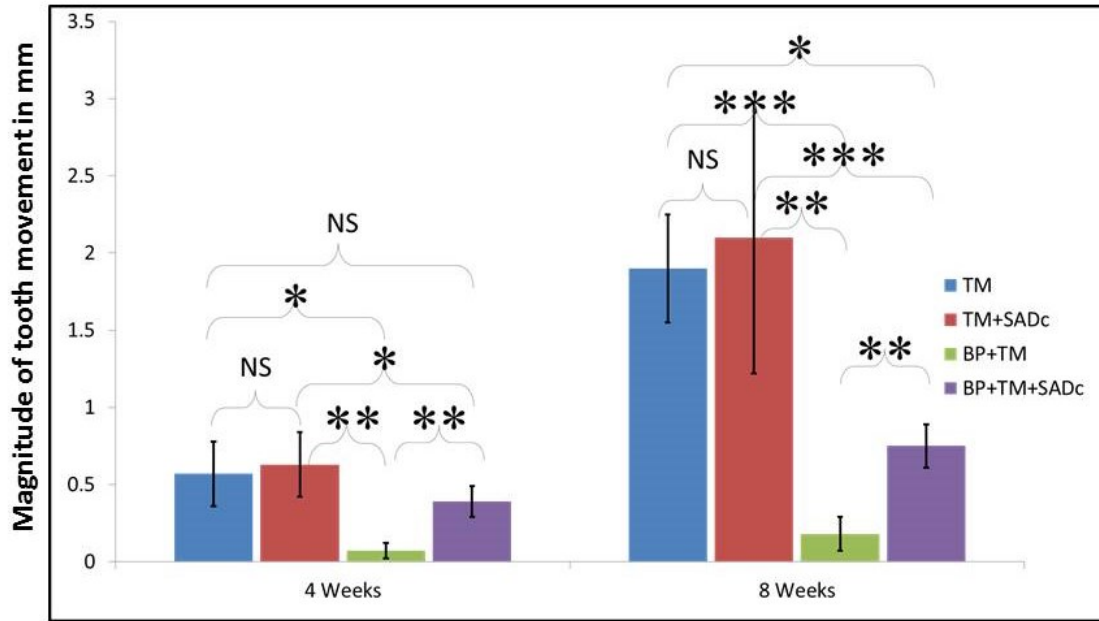


Figure 5-5: Mean amount of orthodontic tooth movement measured at 4 and 8 weeks in all four groups (significance level: * $p < 0.05$, ** $p < 0.005$, *** $p < 0.0005$, NS = Non Significant)

However, in the BP+TM+SADc group, selective alveolar decortication accelerated tooth movement by 113% at 4 weeks when compared to BP+TM group ($p \sim 0.003$). When compared to SADc+TM and TM groups, BP+TM+ SADc group showed only 22% ($p \sim 0.012$) and 15% ($p \sim 0.106$) reduced tooth movement at 4 weeks. This effect was not seen in 8 weeks with only a modest 10% increase in tooth movement from four to eight weeks in the BP+TM+SADc group compared to BP+TM group (Fig 6). BP burdened animals where only tooth movement was attempted had 77% ($p \sim 0.008$) and 86% ($p \sim 0.008$) reduction in tooth movement at 4 and 8 weeks respectively when compared to TM group.

5.5.2 Qualitative μ CT and histologic analysis:

Figure 6 (A-F) shows μ CT rendered sagittal images depicting alveolar bone remodeling between upper right first and second molar area. Figure 6G-L show hematoxylin and eosin stained sections of the area of interest (□). While normal robust remodeling occurs in control animals, with (Fig 6C) or without (Fig 6B) selective alveolar decortication with stretching of periodontal ligament fibers, increase in blood vessels and osteoblastic bone formation, BP burdened animals show either lack of remodeling in BP burdened alveolar bone when tooth movement alone was attempted (Fig 6E & 6K) or severe interproximal alveolar bone loss associated tooth movement (Fig 6F & 6L) as a result of tissue injury from selective alveolar decortication. Some animals in BP+TM+SADc group that underwent selective alveolar decortication and has the bisphosphonate burden in the alveolar bone showed radiographic features of necrotic bone seen as bony fragments with irregular borders that were separated from the remaining alveolar ridge. (Fig 7A) Histologic sections (Fig 7B & 7C) stained with hematoxylin and eosin of the area of interest (□) showed evidence of osteonecrotic bone associated with bacterial infiltration (black arrows), inflammatory cell infiltrate and presence of pyknotic and/or diffuse loss of osteocytes with confluent areas of empty lacunae in the area of necrotic bone (yellow arrows). Evidence of increased periosteal bone formation was also noticed in these animals. (Data not shown)

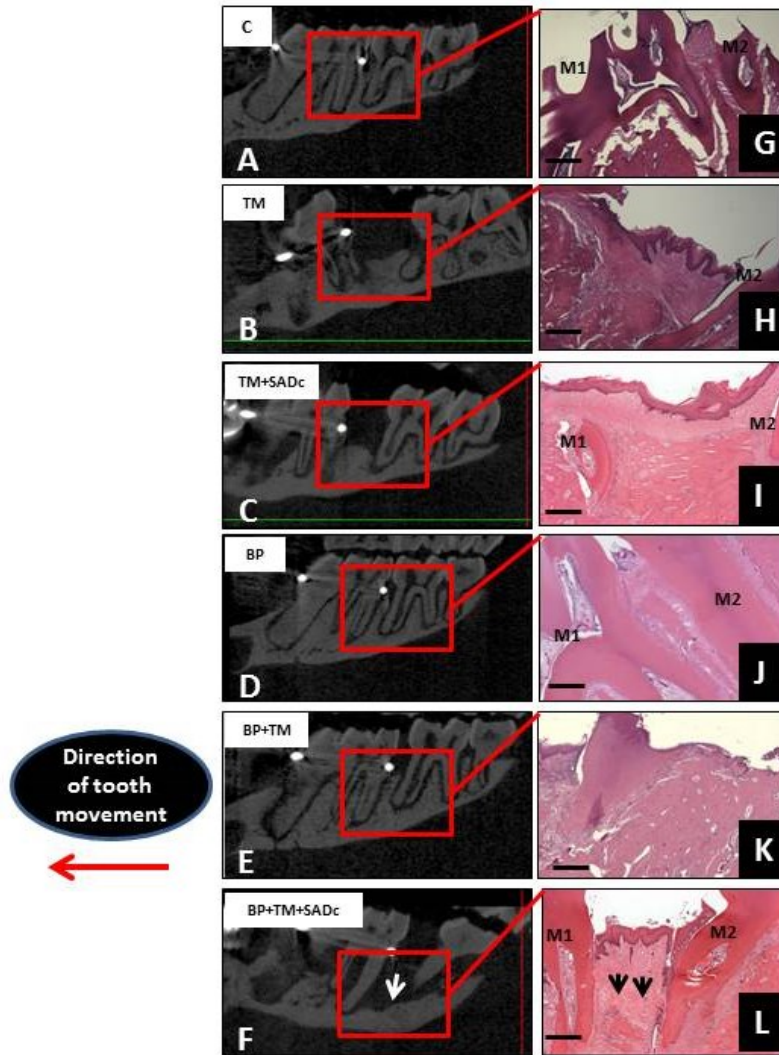


Figure 5-6. Panel (A-F) show μ CT rendered sagittal images depicting alveolar bone remodeling between upper right first and second molar area. Panel (G) thru (L) Hematoxylin and eosin stained sections of the area of interest (\square) original magnification 5x. While normal remodeling occurs in control animals; BP burdened animals show either lack of remodeling in BP burdened alveolar bone when tooth movement alone was attempted (panel (E) and (K) or severe interproximal alveolar bone loss ((Arrows (F) and (L)) as a result of tissue injury from selective alveolar decortication. C = Control; TM = Tooth Movement; SADc = Selective Alveolar Decortication; BP = Bisphosphonate burden; M1 = Upper right first permanent molar; M2 = Upper right second permanent molar

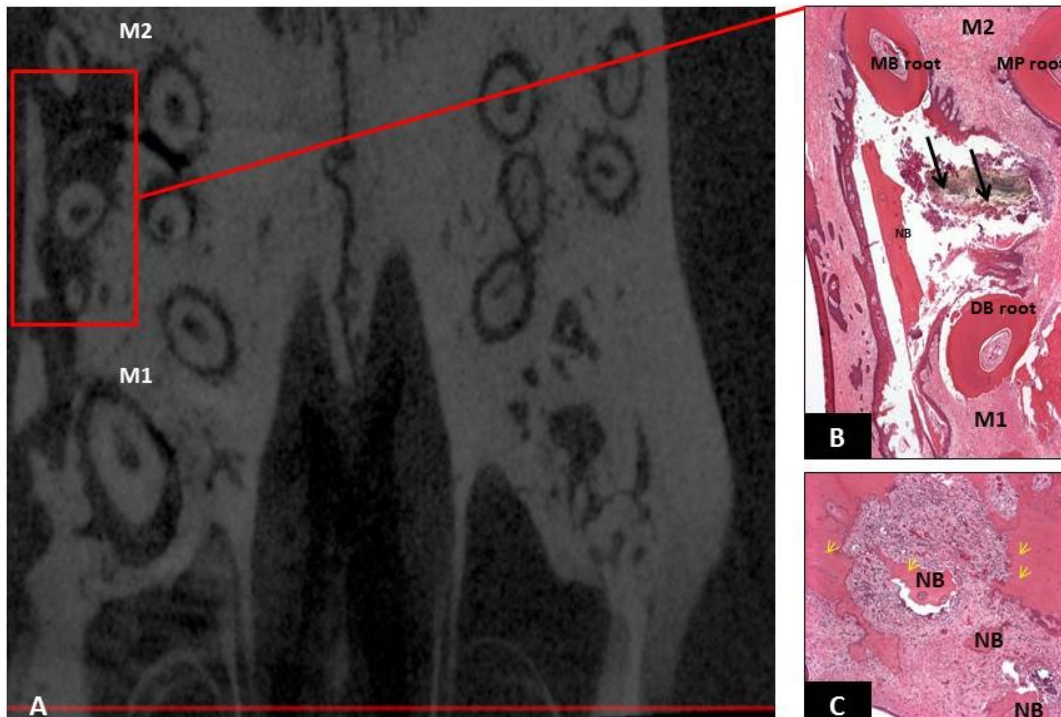


Figure 5-7: Panel (A) Micro-CT rendered coronal images showing areas of necrotic bone (□) detached from the rest of the alveolar and basal bone. Panel (B) Hematoxylin and eosin stained sections of the area of interest (□) with osteonecrotic bone associated with bacterial infiltration (black arrows), inflammatory cell infiltrate surrounding the necrotic bone and presence of pyknotic osteocytes in the area of necrotic bone (yellow arrows). (Panel C) DB = Disto Buccal; MP = Mesio Palatal; MB = Mesio Buccal; M1 = Upper right first permanent molar; M2 = Upper right second permanent molar; NB = Necrotic Bone. Panel B original magnification 10x; panel C original magnification 20x.

5.5.3 Quantitative histomorphometric analysis:

We further evaluated the histopathologic appearance and histomorphometric analysis of the alveolar bone in control and bisphosphonate burdened animals. (Fig. 8)

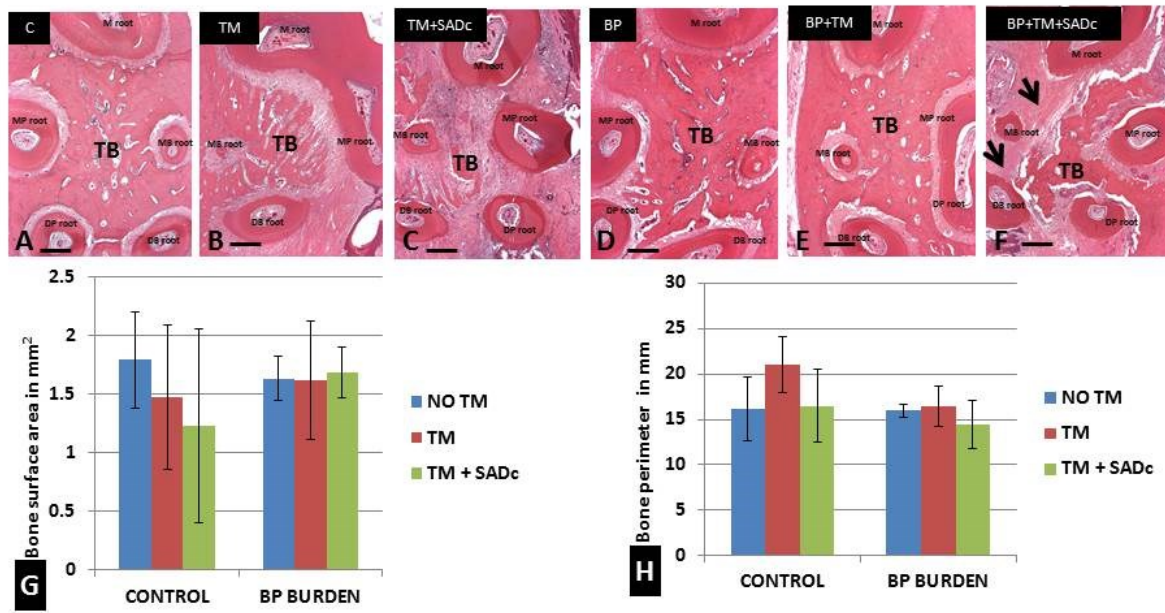


Figure 5-8: Histopathology and histomorphometric analysis of tissue response to selective alveolar decortication in control and bisphosphonate burdened animals. Kruskal-Wallis non parametric test showed no significant difference among the groups in trabecular bone area ($p \sim 0.846$) while a significant difference in the bone perimeter was found among groups ($p \sim 0.038$). In the control animals the left contralateral control site (A) has significantly more trabecular bone compared to right experimental side in TM group (B) and TM+SADc group (C). Although robust remodelling was associated with SADc there was no significant difference in the bone area ($p \sim 0.818$) or perimeter ($p \sim 0.065$) between TM+SADc group (C) compared to TM group alone. (B) In the bisphosphonate burdened animals no changes in the architecture was evident between the left contralateral side (D) and right tooth movement side (E). The bisphosphonate burdened animals in both D and E show dense trabecular bone with decrease in vasculature compared to normal bone (A). The effect of selective alveolar decortication injury in bisphosphonate burdened animals coupled with tooth movement (F) showed severe buccal bone loss (arrows) with lack of active bone remodelling usually associated with corticotomy surgery. Mean \pm S.D. of trabecular bone surface area (G) and trabecular bone perimeter (H) in different groups at the end of experimental time point (8 weeks). (Hematoxylin and eosin; original magnification : A-F x5.) M = Mesial; MP = Mesio Palatal; MB = Mesial Buccal; DB= Disto Buccal; DP = Disto Palatal; TB = Trabecular Bone; C = Control; TM = Tooth Movement; SADc = Selective Alveolar Decortication; BP = Bisphosphonate burden.

Figure 8 shows histopathology and histomorphometric analysis of tissue response to selective alveolar decortication in control and bisphosphonate burdened animals. Kruskal-Wallis non parametric test showed no significant difference among the groups in trabecular bone area ($p \sim 0.846$) while a significant difference in the bone perimeter was found among groups ($p \sim 0.038$). Although robust remodeling was associated with SADc there was no significant difference in the bone area ($p \sim 0.818$) or perimeter ($p \sim 0.065$) between TM+SADc group (Fig 8C) compared to TM group alone. (Fig 8B) In the bisphosphonate burdened animals no changes in the architecture was evident between the left contralateral side (Fig 8D) and right tooth movement side (Fig 8E & 9D). The bisphosphonate burdened animals show dense trabecular bone with decrease in vasculature compared to normal bone (Fig 8A, D, E & Fig 9D). The effect of selective alveolar decortication injury in bisphosphonate burdened animals coupled with tooth movement (Fig. 8F & 9C) showed severe buccal bone loss (arrows) with lack of transient osteopenia and active bone remodeling usually associated with corticotomy surgery. Figure 8 graphs show Mean \pm S.D. of trabecular bone surface area (Fig 8G) and trabecular bone perimeter (Fig 8H) in different groups at the end of experimental time point (8 weeks). Histopathologic evaluation of the cross sectional image of the trabecular interradicular bone demonstrated that there was no statistically significant difference in the trabecular bone area among the groups. ($p \sim 0.846$) Although the results showed lack of significance, there was a trend towards decrease in trabecular bone area in the BP+TM+SADc group ($1.23 \pm 0.83 \text{ mm}^2$) compared to TM group ($1.48 \pm 0.62 \text{ mm}^2$) or control side ($1.79 \pm 0.41 \text{ mm}^2$). No decrease in trabecular area was seen in BP burdened animals with bone area measuring $1.69 \pm 0.21 \text{ mm}^2$ in BP+TM+SADc group and $1.62 \pm 0.5 \text{ mm}^2$ in BP+TM group. (Fig 8G) There was a significant difference in the bone perimeter with $p \sim 0.038$ among the groups. (Fig 8H) The most significant increase in bone

perimeter was evident in TM group due to the robustness of the remodeling associated with tooth movement and associated alveolar bone changes. There was a significant increase in bone perimeter in the TM group (20.98 ± 3.07 mm) compared to control group with no tooth movement ($p \sim 0.013$) and compared to bisphosphonate burdened animals. (BP group = $p \sim 0.01$; BP+TM group = $p \sim 0.004$; BP+TM+SADc group = $p \sim 0.01$) There was no difference in bone perimeter between TM group and TM+SADc group ($p \sim 0.065$) indicating that active remodeling of the trabecular bone occurred in both groups with increase in trabecular bone changes which in turn increases the bone perimeter due to stretching of PDL fibers, angiogenesis and osteoblastic bone formation usually associated with tooth movement.

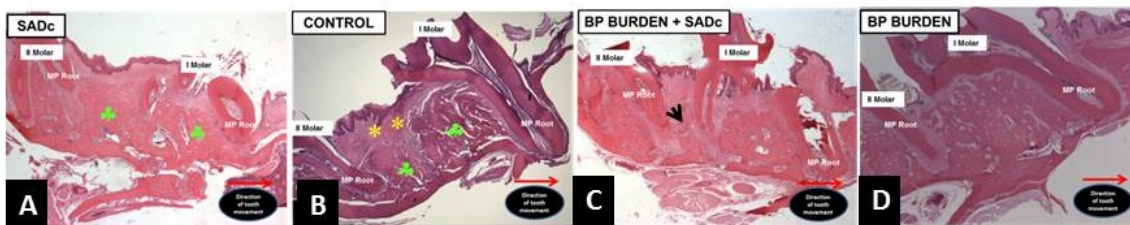


Figure 5- 9: Histologic H & E stained sections of upper right first molar area in (A) SADc, (B) Control, (C) BP burden + SADc and (D) BP burden group showing more tooth movement in the BP burden + SADc group when compared to BP burdened group. While the control animals (A & B) showed normal features of alveolar bone remodeling following tooth movement including stretching of the gingival and periodontal ligament fibers (*) and increased bone remodeling (♣), the BP dosed animals showed lack of active bone remodeling with severe interproximal bone loss (arrows) in the BP burden + SADc group. (Hematoxylin and eosin; original magnification: A-D x2.5). SADc = Selective Alveolar Decortication; BP = Bisphosphonate; MP = Mesio Palatal.

5.5.4 EPMA qualitative analysis:

We used elemental Sr as a surrogate for calcium and molecular tracer of alveolar bone remodeling at the mineralization front. Strontium was given to the animals as oral gavage (308

mg/kg/day) for the last 10 days of experimental tooth movement. EPMA maps show uniform dynamic labeling of strontium over the actively remodeling mineralization front on the tension side of experimental tooth movement in both TM group (Fig 10B) and TM+SADc group (Fig 10C). The warmer colors indicates Sr peaks with EPMA analysis (shown as asterisk *) in Figure 10B and 10C, demonstrating robust new bone formation in the TM and TM+SADc groups as a result of active bone remodeling wherein Sr has replaced Ca ions to form SrP crystals instead of hydroxyapatite crystals usually seen with bone formation. As expected, lack of Dynamic labeling of strontium was seen in the bisphosphonate burdened animals when tooth movement was attempted (shown as ♣) in Figure 10E due to lack of active bone remodeling associated with bisphosphonate burdened alveolar bone wherein the bisphosphonate drug will apoptose any new osteoclasts that forms in the vicinity to start the remodeling process. Interestingly BP+TM+SADc group also showed absence of Dynamic labeling of strontium on the tension side (Fig 10F ♣). This indicates that although tooth movement was more in BP+TM+SADc group at 8 weeks (0.75 ± 0.14 mm) compared to BP+TM group (0.018 ± 0.11) most of the tooth movement that occurred was not due to active remodeling process but due to loss of interproximal and furcal alveolar bone in these animals as shown in Fig 6F, 8F & 10F)

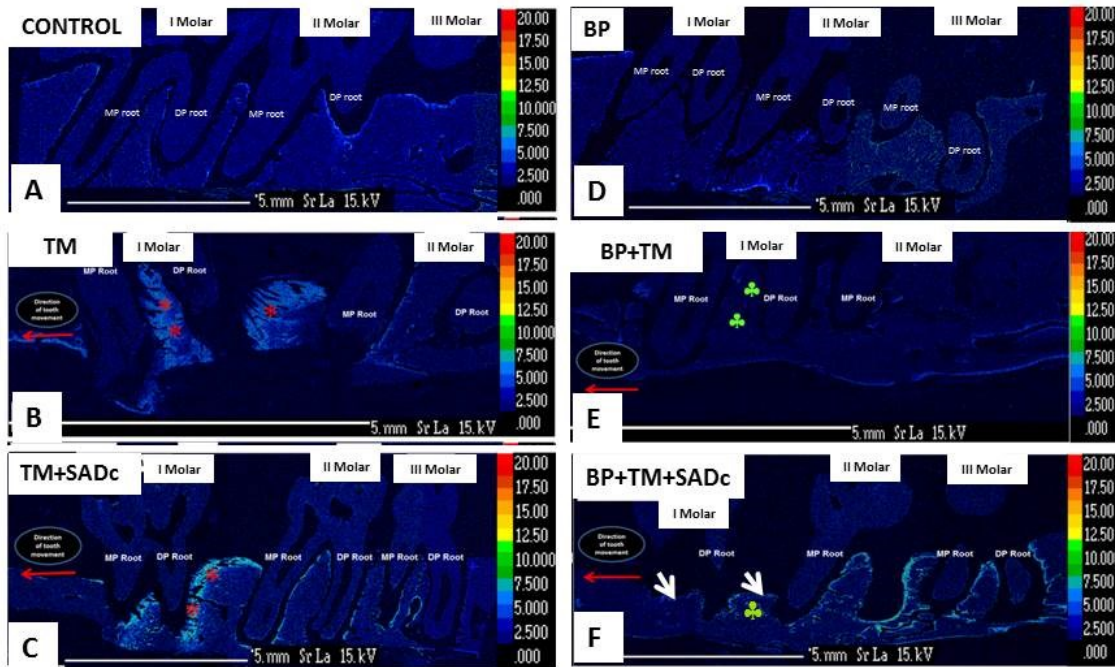


Figure 5-10: Electron-probe micro analyzer rendered images of maxillary molar region of (A), contralateral left control side with limited remodelling activity in comparison to right molar region of (B), TM group and (C) TM+SADc groups; showing increased strontium deposition in both the groups (*) In contrast the BP burdened tissues show lack of appreciable remodeling with no strontium uptake and activity in (D) control left side; (E) BP+TM group and (F) BP+TM+SADc group. (♣). The warmer colors in both the TM and TM+SADc group as shown by red asterisk (*) demonstrates increased bone remodeling due to high tissue turnover; that is apparently lacking in the bisphosphonate laden bone in BP+TM and BP+TM+SADc groups. Also there is evidence of severe buccal and interproximal bone loss in BP+TM+SADc group. (arrows) MP = Mesio Palatal; DP = Disto Palatal; TM = Tooth Movement; SADc = Selective Alveolar Decortication; BP = Bisphosphonate burden

5.6 Discussion

We demonstrated for the first time, the impact of selective alveolar decortication on bisphosphonate burdened alveolar bone during experimental tooth movement in rats. Selective alveolar decortication a variant of corticotomy surgery has been known to accelerate tooth movement in both humans and animal models.²³⁻²⁶ Localized injury to the alveolar bone leads to

anabolic and catabolic activity that result in accelerated bone remodeling²⁸ in turn increasing tooth movement.⁶ This accelerated tooth movement has been shown to peak in 21 days in a rat model and lasts about four months in humans.⁷ This is due to transitory localized osteopenia in the medullary bone leading to decreased resistance of alveolar bone to orthodontic force in turn preventing hyalinization usually seen during the “lag phase” where limited tooth movement occurs. This lag phase usually occurs between 7 and 21 days of initiation of tooth movement.³⁹ Our results showed that at 4 and 8 weeks, there was a non-significant 6% ($p\sim 0.947$) and 2% ($p\sim 0.947$) increase in tooth movement respectively in TM+SADc group compared to TM group. (Fig 6) The average rate velocity also showed no significant change with only a marginal increase of $2\mu\text{m}/\text{day}$ in TM+SADc group compared to TM group between 0 and 4 weeks. ($p\sim 0.739$) From 4 to 8 weeks the average rate velocity doubled in both the groups but the difference was only marginal with $5\mu\text{m}/\text{day}$ increase ($p\sim 0.739$) in TM+SADc group compared to TM group. (Fig 7) The results demonstrate that SADc surgery did not have a significant increase in both the rate and amount of tooth movement in non-bisphosphonate burdened animals. Our results are in agreement with Baloul et al.,⁶ who although demonstrated rapid tooth movement at earlier time points and hypothesized that the coupling mechanism of bone resorption and formation without any pathologic consequence to the alveolar bone was the science behind effective accelerated tooth movement; showed that the effectiveness of selective alveolar decortication was not sustained long term with no significant difference in both amount and rate of tooth movement at 4 ($p\sim 0.11$) and 6 ($p\sim 0.23$) weeks.

Long et al.¹⁸ concluded that corticotomy is an effective and safe modality to accelerate tooth movement but Wilcko et al.²² suggested that one of the contraindications against use of corticotomy surgery was in patients on long term bisphosphonate or steroid therapy. There is no

study published to date to demonstrate the effect of corticotomy surgery in bisphosphonate burdened alveolar bone that would help the clinician in making an evidence based decision on the effectiveness of corticotomy in bisphosphonate burdened individuals. We have previously demonstrated that bisphosphonate burdened alveolar bone inhibits tooth movement.³⁵ Hence research investigating attempts to reverse this inhibitory effect of bisphosphonate drug on orthodontic tooth movement would be useful for the clinician at the crossroads with his/her patient, who is on long term bisphosphonate use and requesting orthodontic services as an adjunctive therapy or as a definitive therapy for improving self-esteem. Our purpose was to investigate whether the transient osteopenia associated with selective alveolar decortication would open up the underlying marrow vascular spaces, to maintain a stable state of bone but at the same time leach out enough bisphosphonate drugs from the alveolar bone to allow for normal remodeling process to occur thereby increasing tooth movement without any adverse effects. We were able to demonstrate in BP+TM+SADc group, selective alveolar decortication accelerated tooth movement by 113% at 4 weeks at an average rate of 13.94 ± 3.6 $\mu\text{m}/\text{day}$ in BP+TM+SADc group as compared to 2.4 ± 1.8 $\mu\text{m}/\text{day}$ in BP+TM group ($p \sim 0.003$). The accelerated tooth movement could be attributed to occurrence of localized osteopenia near the surgical site resulting in leaching out of bisphosphonate drug from the cortical and cancellous bone into the blood stream. This unavailability of bisphosphonate drug to target the osteoclasts coupled with increase in osteoclastic recruitment and activity as a result of tissue injury, could have resulted in accelerated tooth movement even in a bisphosphonate burdened alveolar bone. But the effect did not last until 8 weeks with only a modest 10% increase in tooth movement from four to eight weeks in the BP+TM+SADc group compared to BP+TM group with the average rate velocity plateauing from 4 to 8 weeks (12 ± 6.7 $\mu\text{m}/\text{day}$). When compared to SADc+TM and TM control

groups, BP+TM+ SADc group showed only 22% ($p \sim 0.012$) and 15% ($p \sim 0.106$) reduced tooth movement at 4 weeks. BP burdened animals where only tooth movement was attempted (BP+TM group) had 77% ($p \sim 0.008$) and 86% ($p \sim 0.008$) reduction in tooth movement at 4 and 8 weeks respectively when compared to TM group and a very low rate of tooth movement from 0 to 4 weeks ($2.4 \pm 1.7 \mu\text{m/day}$) with continued low rate of tooth movement from 4 to 8 weeks ($4.09 \pm 2.9 \mu\text{m/day}$). These results demonstrate that although selective alveolar decortication increased tooth movement at 4 weeks by 113% it was still not effective to leach out the entire bisphosphonate drug to allow normal remodeling process. Once the effectiveness of the decortication surgery was diminished (one cycle of anabolic and catabolic activity associated with corticotomy type surgery in experimental rat model usually about 21 days in rats (Sebaoun et al., 2008²⁸)) the burden effect of the bisphosphonate drug on the alveolar bone prevented further tooth movement from 4 to 8 weeks reaching similar levels evident in BP+TM group. This lack of effective tooth movement and bone remodeling at 8 weeks was also seen by μCT and histology. While normal robust remodeling occurred in control animals, with (Fig 6C) or without (Fig 6B) selective alveolar decortication; demonstrating stretching of periodontal ligament fibers, increase in blood vessels and osteoblastic bone formation, BP burdened animals showed lack of active remodeling and was associated with severe interproximal and buccal alveolar bone loss associated tooth movement (Fig 6F & 6L) as a result of tissue injury from selective alveolar decortication. It could be argued that the increased tooth movement shown at 4 weeks in these animals is a result of bone loss and decrease in bone support rather than bone remodeling process associated with accelerated orthodontic tooth movement. Some animals in BP+TM+SADc group that underwent selective alveolar decortication and had the bisphosphonate burden in the alveolar bone showed radiographic features of necrotic bone seen as bony fragments with irregular

borders that were separated from the remaining alveolar ridge. (Fig 7A) Histologic sections (Fig 7B & 7C) stained with hematoxylin and eosin of the area of interest (□) showed evidence of osteonecrotic bone associated with bacterial infiltration (black arrows), inflammatory cell infiltrate and presence of pyknotic and/or diffuse loss of osteocytes with confluent areas of empty lacunae in the area of necrotic bone (yellow arrows). BP drugs have been shown to cause osteonecrosis of the jaws. This bisphosphonate induced osteonecrosis (BRONJ) is more prevalent in individual taking IV bisphosphonate drugs with a risk of 1-11%⁴⁰⁻⁴³ than oral bisphosphonates (0.001-0.1%).⁴⁴⁻⁴⁶ This risk of BRONJ occurrence is on the rise due to chronic oral BP use and increase in screening of BP patients.⁴⁶ Marx⁴⁷ demonstrated that 81% of BRONJ cases had an initiating event such as uncontrolled periodontal disease, tooth extraction either due to periodontitis or caries, periodontal surgery or apicoectomy. This establishes that extensive tissue trauma coupled with bacterial infection can be a predisposing factor in BRONJ occurrence. Allen and Burr (2009)⁴⁸ attempted to explain this occurrence and showed that altered bone remodeling, angiogenesis inhibition, constant microtrauma and bacterial infection could be hypothesized as initiating factors for BRONJ development. Long term bisphosphonate burden of alveolar bone in beagle dogs showed matrix necrosis of the alveolar bone.⁴⁹ Fedele et al. (2010)⁵⁰ showed that jaw pain, sinus tracts, bone enlargements and gingival enlargement are associated with non-exposed variant of BRONJ. Any additional tissue injury coupled with bacterial infection could lead signs and symptoms of clinically exposed BRONJ in these individuals. We previously demonstrated that long term use of alendronate in rats can lead to decreased tooth movement, atypical trabecular alveolar bone with decrease in blood vessels and lack of bone remodeling.³⁵ These animals did not show signs of necrotic bone. But additional trauma to the bisphosphonate burdened alveolar bone from decortication injury, lead to rapid bone loss and

associated bacterial infection and tissue inflammation that predisposed these animals to signs of BRONJ with necrotic and sequestered bone, severe bone loss and tissue inflammation. Histological examination confirmed the presence of necrotic bone with diffuse loss of osteocytes and empty lacunae, diagnostic of osteonecrosis and hallmark of BRONJ histopathology in humans.⁵¹ Aghaloo et al. (2011)⁵¹ proposed a model for BRONJ pathophysiology and demonstrated that when tissue trauma occurs to bisphosphonate burdened alveolar bone, due to diminished activity of osteoclasts; alveolar bone is not resorbed away from the inflammation areas, exposing the bone to environment rich in bacterial toxins, inflammatory cytokines, or oxidative stress. Such high toxicity results in rapid bone loss and osteonecrosis. Our finding of osteonecrotic bone with irregular borders associated with bacterial infiltration, inflammatory cell infiltrate and presence of pyknotic and/or diffuse loss of osteocytes with confluent areas of empty lacunae in the area of necrotic bone is similar to pathophysiology of BRONJ development proposed by Aghaloo et al. (2011)⁵¹ The histologic features of BRONJ like development, induced by selective alveolar decortication in BP burdened animals combined with lack of active bone remodeling as seen with absence of dynamic labeling of strontium in EPMA images in BP+TM+SADc group, (Fig 12F) should caution us from attempting acceleration of tooth movement in bisphosphonate burdened alveolar bone even if selective alveolar decortication accelerated tooth movement short term in this rodent model. This would predict that other invasive accelerators of tooth movement such as RANKL gene therapy, piezocision, osteotomy, distraction osteogenesis, corticotomy could, similar to selective alveolar decortication cause adverse effects to the alveolar bone predisposing individuals to osteonecrosis.

It would be interesting to investigate whether other non-invasive interventions to accelerate tooth movement such as low-level laser therapy, pulsed electromagnetic fields, electrical

currents, and mechanical vibrations would lead to same tissue response as found with selective alveolar decortication. Currently, there is lack of peer-reviewed scientific evidence; to demonstrate whether any of these supposedly non-invasive treatment modalities would accelerate tooth movement at all in normal alveolar bone, let alone in bisphosphonate burdened alveolar bone.

5.7 Conclusion

1. Selective alveolar decortication did not significantly increase amount of tooth movement in normal alveolar bone at 4 and 8 weeks respectively.
2. Selective alveolar decortication significantly accelerated tooth movement in bisphosphonate burdened alveolar bone by 113% at 4 weeks compared to tooth movement alone.
3. The tooth movement effect of selective alveolar decortication in bisphosphonate burdened alveolar bone was short term with only a modest (not significant) 10% increase in tooth movement from 4 to 8 weeks.
4. The increased tooth movement with selective alveolar decortification in bisphosphonate burdened alveolar bone was associated with severe interproximal and buccal bone loss, bacterial infiltration, inflammatory infiltrate. μ CT imaging and histology showed areas of necrotic bone with irregular borders, absence of osteocytes with empty lacunae.

5.8 References

1. Krishnan V, Davidovitch Z. Cellular, molecular, and tissue-level reactions to orthodontic force. *Am J Orthod Dentofacial Orthop.* 2006;129(4):469.e1-32.
2. Verna C, Dalstra M, Melsen B. The rate and the type of orthodontic tooth movement is influenced by bone turnover in a rat model. *Eur J Orthod.* 2000;22(4):343-52.
3. Iino S, Sakoda S, Ito G, Nishimori T, Ikeda T, Miyawaki S. Acceleration of orthodontic tooth movement by alveolar corticotomy in the dog. *Am J Orthod Dentofacial Orthop.* 2007;131(4):448.e1-8.
4. Wang L, Lee W, Lei DL, Liu YP, Yamashita DD, Yen SL. Tissue responses in corticotomy- and osteotomy-assisted tooth movements in rats: histology and immunostaining. *Am J Orthod Dentofacial Orthop.* 2009;136(6):770.e1-11.
5. Hassan AH, Al-Fraidi AA, Al-Saeed SH. Corticotomy-assisted orthodontic treatment: review. *Open Dent J.* 2010;4:159-64
6. Baloul SS, Gerstenfeld LC, Morgan EF, Carvalho RS, Van Dyke TE, Kantarci A. Mechanism of action and morphologic changes in the alveolar bone in response to selective alveolar decortication-facilitated tooth movement. *Am J Orthod Dentofacial Orthop.* 2011;139(4 Suppl):S83-101.
7. Cano J, Campo J, Bonilla E, Colmenero C. Corticotomy-assisted orthodontics. *J Clin Exp Dent.* 2012;4(1):e54-9.
8. Cruz DR, Kohara EK, Ribeiro MS, Wetter NU. Effects of low-intensity laser therapy on the orthodontic movement velocity of human teeth: a preliminary study. *Lasers Surg Med.* 2004;35:117-120.

9. Yamaguchi M, Hayashi M, Fujita S. Low-energy laser irradiation facilitates the velocity of tooth movement and the expressions of matrix metalloproteinase-9, cathepsin K, and alpha(v) beta(3) integrin in rats. *Eur J Orthod.* 2010;32:131-139.
10. Nishimura M, Chiba M, Ohashi T. Periodontal tissue activation by vibration: Intermittent stimulation by resonance vibration accelerates experimental tooth movement in rats. *Am J Orthod Dentofacial Orthop.* 2008;133:572-583.
11. Showkatbakhsh R, Jamilian A, Showkatbakhsh M. The effect of pulsed electromagnetic fields on the acceleration of tooth movement. *World J Orthod.* 2011;11:e52-e56.
12. Kim DH, Park YG, Kang SG. The effects of electrical current from a micro-electrical device on tooth movement. *Korean J Orthod.* 2008;38:337-346.
13. Liou EJ, Huang CS. Rapid canine retraction through distraction of the periodontal ligament. *Am J Orthod Dentofacial Orthop.* 1998;114:372-82.
14. Sayin S, Bengi AO, Gurton AU, Ortakoglu K. Rapid canine distalization using distraction of the periodontal ligament. a preliminary clinical validation of the original technique. *Angle Orthod.* 2004;74:304-315.
15. Iseri H, Kisnisci R, Bzizi N, Tuz H. Rapid canine retraction and orthodontic treatment with dentoalveolar distraction osteogenesis. *Am J Orthod Dentofacial Orthop.* 2005;127:533-541.
16. Iglesias-Linares A, Moreno-Fernandez AM, Yañez-Vico R, Mendoza-Mendoza A, Gonzalez-Moles M, Solano-Reina E. The use of gene therapy vs. corticotomy surgery in accelerating orthodontic tooth movement. *Orthod Craniofac Res.* 2001;14(3):138-48.
17. Kanzaki H, Chiba M, Arai K, Takahashi I, Haruyama N, Nishimura M, Mitani H. Local RANKL gene transfer to the periodontal tissues accelerates orthodontic tooth movement. *Gene Ther.* 2006;13(8):678-85.

18. Long H, Pyakurel U, Wang Y, Liao L, Zhou Y, Lai W. Interventions for accelerating orthodontic tooth movement. *Angle Orthod.* 2013;83(1):164-171.
19. Köle H. Surgical operations on the alveolar ridge to correct occlusal abnormalities. *Oral Surg Med Pathol.* 1959;12:515-529.
20. Frost HM. The regional acceleratory phenomenon: a review. *Henry Ford Hosp Med J.* 1983;31(1):3-9.
21. Schilling T, Müller M, Minne HW, Ziegler R. Influence of inflammation-mediated osteopenia on the regional acceleratory phenomenon and the systemic acceleratory phenomenon during healing of a bone defect in the rat. *Calcif Tissue Int.* 1998;63:160-6.
22. Wilcko W, Wilcko MT. Accelerating tooth movement: the case for corticotomy-induced orthodontics. *Am J Orthod Dentofacial Orthop.* 2013;144(1):4-12.
23. Duker J. Experimental animal research into segmental alveolar movement after corticotomy. *J Maxillofac Surg.* 1975;3:81-84.
24. Ren A, Lv T, Kang N, Zhao B, Chen Y, Bai D. Rapid orthodontic tooth movement aided by alveolar surgery in beagles. *Am J Orthod Dentofacial Orthop.* 2007;131:61-8.
25. Mostafa YA, Mohamed Salah Fayed M, Mehanni S, ElBokle NN, Heider AM. Comparisons of corticotomy-facilitated vs standard tooth-movement techniques in dogs with miniscrews as anchor units. *Am J Orthod Dentofacial Orthop.* 2009;136(4):570-7.
26. Wilcko MT, Wilcko WM, Pulver JJ, Bissada NF, Bouquot JE. Accelerated osteogenic orthodontics technique: a 1-stage surgically facilitated rapid orthodontic technique with alveolar augmentation. *J Oral Maxillofac Surg.* 2009;67(10):2149-59.
27. Murphy KG, Wilcko MT, Wilcko WM, Ferguson DJ. Periodontal accelerated osteogenic orthodontics: a description of the surgical technique. *J Oral Maxillofac Surg.* 2009;67(10):2160-6.

28. Sebaoun JD, Kantarci A, Turner JW, Carvalho RS, Van Dyke TE, Ferguson DJ. Modeling of trabecular bone and lamina dura following selective alveolar decortication in rats. *J Periodontol.* 2008;79(9):1679-88.
29. Landesberg R, Eisig S, Fennoy I, Siris E. Alternative indications for bisphosphonate therapy. *J Oral Maxillofac Surg.* 2009;67(5 Suppl):27-34.
30. Russell RG. Bisphosphonates: mode of action and pharmacology. *Pediatrics.* 2007;119(Suppl 2):S150-62.
31. Yamaguchi M. RANK/RANKL/OPG during orthodontic tooth movement. *Orthod Craniofac Res.* 2009;12(2):113-9.
32. Abrahamsen B. Bisphosphonate adverse effects, lessons from large databases. *Curr Opin Rheumatol.* 2010;22(4):404-9.
33. Ruggiero SL, Mehrotra B, Rosenberg TJ, Engroff SL. Osteonecrosis of the jaws associated with the use of bisphosphonates: a review of 63 cases. *J Oral Maxillofac Surg.* 2004;62(5):527-534.
34. Marx RE, Sawatari Y, Fortin M, Broumand V. Bisphosphonate-induced exposed bone (osteonecrosis/osteopetrosis) of the jaws: risk factors, recognition, prevention and management. *J Oral Maxillofac Surg.* 2005;63(11):1567-75.
35. Kaipatur N, Wu Y, Adeeb S, Stevenson T, Major P, Doschak M. Impact of bisphosphonate drug burden in alveolar bone during orthodontic tooth movement in a rat model: a pilot study. *Am J Orthod Dentofacial Orthop.* 2013;144(4):557-67.
36. Kaipatur N, Wu Y, Adeeb S, Stevenson T, Major P, Doschak M. A novel rat model of orthodontic tooth movement using temporary skeletal anchorage devices: 3D finite element analysis and in vivo validation. *International Journal of Dentistry.* 2014; Article ID 917535, 11 pages. <http://dx.doi.org/10.1155/2014/917535>.

37. Egan KP, Brenna TA, Pignolo RJ. Bone histomorphometry using free and commonly available software. *Histopathology*. 2012;61(6):1168-73.
38. Panihifar A, Maksymowych WP, Doschak MR. Potential mechanism of alendronate inhibition of osteophyte formation in the rat model of post-traumatic osteoarthritis: evaluation of elemental strontium as a molecular tracer of bone formation. *Osteoarthritis Cartilage*. 2012;20:694-702.
39. Reitan K. Clinical and histologic observations on tooth movement during and after orthodontic treatment. *Am J Orthod*. 1967;53(10):721-45.
40. Durie BG, Katz M, Crowley J. Osteonecrosis of the jaw and bisphosphonates. *N Engl J Med*. 2005;353(1):99-102.
41. Zervas K, Verrou E, Telejoudis Z, Vahtsevanos K, Banti A, Mihou D, Krikelis D, Terpos E. Incidence, risk factors and management of osteonecrosis of the jaw in patients with multiple myeloma: a single-centre experience in 303 patients. *Br J Haematol*. 2006;134(6):620-3.
42. Hoff AO, Toth BB, Altundag K, Johnson MM, Warneke CL, Hu M, Nooka A, Sayegh G, Guarneri V, Desrouleaux K, Cui J, Adamus A, Gagel RF, Hortobagyi GN. Frequency and risk factors associated with osteonecrosis of the jaw in cancer patients treated with intravenous bisphosphonates. *J Bone Miner Res*. 2008;23(^):826-36.
43. Walter C, Al-Nawas B, Grötz KA, Thomas C, Thüroff JW, Zinser V, Gamm H, Beck J, Wagner W. Prevalence and risk factors of bisphosphonate-associated osteonecrosis of the jaw in prostate cancer patients with advanced disease treated with zoledronate. *Eur Urol*. 2008;54(5):1066-72.
44. Khosla S, Burr D, Cauley J et al. Bisphosphonate-associated osteonecrosis of the jaw: report of a task force of the American Society for Bone and Mineral Research. *J Bone Miner Res*. 2007;22(10):1479-91.

45. Mavrokokki T, Cheng A, Stein B, Goss A. Nature and frequency of bisphosphonate-associated osteonecrosis of the jaws in Australia. *J Oral Maxillofac Surg.* 2007;65(3):415-23.
46. Lo JC, O’Ryan FS, Gordon NP et al. Prevalence of osteonecrosis of the jaw in patients with oral bisphosphonate exposure. *J Oral Maxillofac Surg.* 2010;68(2):243-53.
47. Marx R. Oral & Intravenous Bisphosphonate-Induced Osteonecrosis of the Jaws. Book Chapter. Quintessence Publishing Co.; Chicago:2007.
48. Allen MR, Burr DB. The pathogenesis of bisphosphonate-related osteonecrosis of the jaw: so many hypotheses, so few data. *J Oral Maxillofac Surg.* 2009;67(5 Suppl):61-70.
49. Allen MR, Burr DB. Mandible matrix necrosis in beagle dogs after 3 years of daily oral bisphosphonate treatment. *J Oral Maxillofac Surg.* 2008;66:987-994.
50. Fedele S, Porter SR, D’Aiuto F et al. Nonexposed variant of bisphosphonate-associated osteonecrosis of the jaw: a case series. *Am J Med.* 2010;123(11):1060-4.
51. Aghaloo TL, Kang B, Sung EC, Shoff M, Ronconi M, Gotcher JE, Bezouglaia O, Dry SM, Tetradis S. Periodontal Disease and Bisphosphonate Induce Osteonecrosis of the Jaws in the Rat. *J Bone Miner Res.* 2011;26(8):1871-82.

Chapter 6 General Discussion and Conclusions

6.1 Discussion

This dissertation showed for the first time the impact of long term use of BP drug burden on alveolar bone using a novel model of orthodontic tooth movement. In order to demonstrate a clinically significant effect of BP drug burden on OTM; we had to choose an animal model that would allow us to employ constant unloading force for efficient tooth movement without frequent manipulation of the device and allow us to measure clinically significant tooth movement reliably and accurately in real time. Many biomedical devices have been designed to initiate and trial the effects of OTM in laboratory animal models.¹ The most commonly used device to facilitate OTM remains stainless steel brackets and arch wires. Arch wire approaches in developing animal models of OTM are ideally suited to large animal species (e.g., dog, monkeys) with near equivalent sized teeth to that of humans. However, for smaller animal models (such as in the rat or mice), archwires are difficult to place, and custom fixtures are expensive to manufacture. As an alternative to archwires, nickel-titanium (NITI) springs and stainless steel ligature wires have been routinely used to induce OTM *in vivo* for smaller animal models.² With that approach, a coil spring is secured to the neck of the molar tooth using ligature wire, with the other end of the spring anchored by a ligature loop around the two incisor teeth. That approach is successful in the mesial tipping and protraction of the rat maxillary first permanent molar, and various rat models are in common usage in research worldwide.³⁻⁶ In those studies, external measurements need to be taken to determine tooth movement and often use handheld micrometers and the measurement is unreliable and imprecise. Furthermore, as rat incisor teeth are continuously growing, they are not ideal for anchorage as the plane of applied mechanical force is constantly changing. This can result in constant manipulation of the appliance, iatrogenic trauma to the incisors to prevent their eruption and appliance loosening.

TSADs have been used as anchorage devices in animal studies and have been effective to provide absolute anchorage. But TSADs have been tried for anchorage purposes only in large animals like dogs and pigs.¹

Our study for the first time effectively used TSAD as direct anchorage to facilitate tooth movement in a rat model. In development of a new tooth movement model using rat TSADs we used Stryker 1.2x3 mm micro-implant and attached a NiTi closed coil spring from the TSAD to right first permanent molar using a 0.010 inch stainless steel ligature wire to initiate tooth movement. FE modeling of the TSAD stability showed minimal displacement (2.24 μm) with average von Mises stress of 25 mPa. *In vivo* micro-CT measurement of tooth movement using the new model provided evidence for a clinically and statistically significant tooth movement of 0.62 mm at 4 weeks and 1.99 mm at 8 weeks compared to baseline. ($p \sim 0.0003$) The amount of tooth movement was comparable to previous rat models² without the deleterious effects of iatrogenic trauma to the incisors, pulpal damage, and change in force levels due to constant manipulation of the appliance.⁶⁻⁹ Also contrasting results regarding the velocity of tooth movement between 3-4 weeks demonstrates that clinically effective tooth movement measurements would be possible only if the experimental end point is more than 4 weeks. Hence our tooth movement model's experimental end point of 8 weeks was ideal to show clinically and statistically significant tooth movement to offset the controversies that exists in the literature.^{2, 10} Rats have natural eruption of their incisors to compensate for loss due to mastication induced abrasion. This natural development and spontaneous eruption of incisors can lead to significant change in force vector of the orthodontic appliance when the incisors are used as anchorage.³⁻⁸ Although the eruption velocity is minimal (0.3 mm/week) and decreases with application of orthodontic force overtime,^{9, 11} it still is a significant factor to affect the reliability of a research

design. Some others have applied cortical anchorage on the incisors to prevent their eruption but the effect is transient and impedes animal welfare.⁹ Hence the new proposed model using TSADs allowed for natural attrition, eruption and development of the incisors with significant tooth movement. We also showed that this model of tooth movement in rats is very predictable with only 8% failure rate at 4 weeks and 20% failure rate at 8 weeks. Although 100% success with TSADs is desired, the failure rate in our study is comparable to published in literature.^{12,13} The design of this new model of tooth movement in rats provided evidence that TSADs could be used as effective anchorage devices to provide optimal force levels for clinically and statistically significant tooth movement.

However precise and efficient the model is; the rate limiting step in achieving clinically significant tooth movement without deleterious effects depends on the rate of alveolar bone turnover which in turn could be manipulated by physical, chemical and surgical means.^{14,15} The rate of bone turnover is affected by many drugs that can retard or accelerate tooth movement.¹⁶ It is well established that BP drugs have deleterious effect on osteoclast-mediated bone resorption^{17, 18} and can remain in the skeleton long after discontinuation of their use due to their long terminal half-life. (e.g. alendronate sodium ~ 10 years) Resultantly, this burden of BP drug in bone can have significant impact during OTM; as cells involved in the biologic process of tooth movement (osteoclasts) are modified by BP drugs and rendered inactive.¹⁷ We hypothesized that, when this bone burden of incorporated BP drug was released into the local micro-environment, it will interfere with bone cell activity, resulting in cell death and retardation of remodeling, OTM and/or bone healing.

Most of the current orthodontic literature, as recent as year 2014 focused on using BP drugs concurrent with tooth movement^{19, 20} or performed tooth movement for a smaller period of

time; not to effectively demonstrate clinically significant inhibition of tooth movement.^{21, 22} Our study provided evidence that BP drug burden on alveolar bone due to long term BP use can result in clinically and statistically significant reduction in tooth movement of 0.55 ± 0.1 mm (77%) and 1.7 ± 0.2 mm (86%) at 4 and 8 weeks respectively while showing 56% and 65% reduction in tooth movement with concurrent dosing of BP drugs during OTM; which is in agreement with studies published in the literature.^{19, 23}

Our study for the first time highlighted the utility of elemental strontium as a dynamic tracer of newly mineralizing alveolar bone, by acting as a surrogate for calcium in areas of active bone remodeling. Strontium (308mg/kg/body weight) was given as oral gavage during the last 10 days of experimental tooth movement. This dose is below the therapeutic range of causing permanent change in bone mineral density as strontium is known for its bone seeking properties.²⁴ As seen under EPMA, bisphosphonate laden bone showed a distinct absence of strontium deposition on the tension side of tooth movement indicating significant inhibition of bone remodeling, in comparison to the warmer colors seen at the tension side of control animals with substantial strontium deposition in these animals indicating robust bone remodeling associated with orthodontic tooth movement. (Fig. 4-7)

Our next goal was to investigate whether any methods to accelerate tooth movement would be effective in BP burdened alveolar bone and the impact of such an acceleration attempt on the tissues. To date, various treatment modalities have been investigated to accelerate tooth movement including; corticotomy,²⁵⁻²⁹ low level laser therapy,^{30,31} mechanical vibration,³² pulsed electromagnetic therapy,³³ electrical currents³⁴ and distraction osteogenesis.³⁵⁻³⁷ Even biologic approach to accelerate tooth movement have been attempted through invitro³⁸ and *in vivo* localized RANKL gene therapy.³⁹ A recent systematic review by Long et al.⁴⁰ showed that

corticotomy is an effective modality to accelerate tooth movement and is relatively safe compared to any other method.

Corticotomy or selective alveolar decortication (SADc) has been shown to induce RAP (regional acceleratory phenomenon) effect due to localized osteopenia in the areas of medullary bone following tissue injury. This RAP effect can lead to accelerated catabolic and anabolic activity thereby enhancing the rate the alveolar bone remodeling⁴¹ and in turn increasing the rate of tooth movement.²⁸ We performed SADc surgery on both normal and BP burdened alveolar bone and induced tooth movement using our efficient model of OTM. There was 113% increase in tooth movement in the BP burdened bone as a result of SADc surgery at 4 weeks but the effectiveness of SADc surgery and subsequent increase in tooth movement was not evident by 8 weeks with only a modest 10% increase in tooth movement. In our study, SADc only showed 2% and 6% increase in tooth movement in the control animals. Recent literature on the effectiveness of corticotomy^{42,43} in humans or SADc²⁸ in rats showed effective increase in tooth movement during initial time points with diminishing effects over time.^{42,28} They showed that the effect of corticotomy surgery lasted only 4 months⁴² in humans and 21 days in rats.⁴¹ Similarly in our study, once the effectiveness of the decortication surgery was diminished (one cycle of anabolic and catabolic activity) the bone burden effect of the bisphosphonate drug on the alveolar bone prevented further tooth movement from 4 to 8 weeks and the amount of tooth movement was similar to BP burden animals that did not have SADc surgery.

The impact of SADc surgery on BP burdened alveolar bone showed signs of osteonecrosis with radiographic and histologic evidence of necrotic bone fragments with irregular borders, inflammatory cell infiltrate, bacterial infiltration, empty osteocyte canaliculi in

areas of necrotic bone associated with areas of severe interproximal and buccal bone loss. (Fig. 5-7)

6.2 Conclusions

1. TSADs can be used as a stable anchorage device for OTM in rats.
2. Statistically significant amount of tooth movement was achieved with 0.62 mm at 4 weeks and 1.99 mm at 8 weeks using this new model of OTM.
3. Success rate of TSADs were 92% at 4 weeks and 80% at 8 weeks.
4. Absolute anchorage was not achieved with secondary TSAD displacement of 0.42 mm at 4 weeks and 0.094 mm at 8 weeks.
5. The bone burden effect of BP drugs due to long term BP drug use was significant. Alendronate sodium significantly inhibited tooth movement by 86% at 8 weeks and 77% at 4 weeks in the bone burden group versus age-matched control rats.
6. The reduction in tooth movement was 20% greater in the bone burden group than the BP concurrent-dosed group, although the difference was not statistically significant.
7. The inhibition of tooth movement and lack of bone remodeling as shown by EPMA should caution the Orthodontist in formulating ideal treatment plans to avoid longer treatment times and/or adverse orthodontic outcome.
8. Selective alveolar decortication did not significantly increase amount of tooth movement in normal alveolar bone at 4 and 8 weeks respectively.
9. Selective alveolar decortication significantly accelerated tooth movement in bisphosphonate burdened alveolar bone by 113% at 4 weeks compared to tooth movement alone.

10. The tooth movement effect of selective alveolar decortication in bisphosphonate burdened alveolar bone was short term with only a modest (not significant) 10% increase in tooth movement from 4 to 8 weeks.
11. The increased tooth movement with selective alveolar decortication in bisphosphonate burdened alveolar bone was associated with severe interproximal and buccal bone loss, bacterial infiltration, inflammatory infiltrate. μ CT imaging and histology showed areas of necrotic bone with irregular borders, absence of osteocytes with empty lacunae.

6.3 Potential Impact

With emerging trend of increasing number of adults seeking orthodontic care, the orthodontist will come across patients who have been on long term oral bisphosphonate drug use for osteoporosis or similar disorder or IV bisphosphonates for osteolytic cancers. These baby boomers are at crossroads where in they effectively seek improving their quality of life and are actively seeking orthodontic care to straighten their teeth and smile esthetics and in turn have an impact on their self-esteem. Our current study has provided evidence that bisphosphonate bone burden can significantly inhibit orthodontic tooth movement and prevent active bone remodeling and any tissue injury to the BP burdened alveolar bone leads to deleterious effects of osteonecrosis. The impact of BP drugs on OTM and their deleterious effect on alveolar bone as shown by our study will caution the Orthodontist in obtaining detailed health histories in these potential patients and formulate treatment plans that would be less than ideal; but would have less harmful effects on the biology of the oral tissues. This study would also help the Orthodontist in showing evidence to the patients the potential harmful effects of attempting aggressive orthodontic treatment like extraction therapy that would mimic selective alveolar

decortication type injury and obtaining detailed informed consent in protecting themselves from litigation.

6.4 Limitations

The outcome of this research proves unequivocally the impact of BP drug burden on orthodontic tooth movement. But the results of our study should be interpreted with caution. The research was conducted in rats with evidence of normal alveolar bone. BP drugs are extensively used to prevent and treat osteoporosis and they have been shown to effectively reduce fragility fracture in osteoporotic bone. Although alveolar bone has been shown to be affected less than long bones by osteoporotic disease, the bone biology would still be different than an osteoporotic bone and should be investigated.

The rat model is an effective experimental model of tooth movement. It is a useful model due to less research costs, better animal handling, ability to do real time micro-CT imaging to 3-dimensionally and accurately measure tooth movement to less than $2/100^{\text{th}}$ of a millimeter. But the difference in the bone architecture and biology between a rat and human should caution the reader in extrapolation of the results to humans.

The goal of the research was to investigate the impact of BP drug burden on tooth movement. In order to demonstrate a clinically significant effect on tooth movement that experimental end point was 8 weeks. Although the experimental end point of 8 weeks did effectively show difference in tooth movement between normal and BP burdened animals, the experimental analysis we carried out using micro-CT, histology, histomorphometry and EPMA, was not enough to show the molecular level impact on BP drug on osteoclast, the cell necessary for OTM associated active bone remodeling. We would have shed more light on the molecular

mechanisms of bone remodeling by using experimental techniques of RT-PCR and immunohistochemistry at earlier time points like 3, 7 and 14 days.

6.5 Future Direction

This study has served as basis for potential future research in field of bone biology associated with BP drugs. The potential impact of BP bone burden in an osteoporotic animal model should be investigated. Also the role of other potential accelerators of tooth movement such as localized targeted delivery of RANKL peptides and low level laser therapy should be investigated. It would be interesting to study if these new treatment modalities will have the same deleterious effects as selective alveolar decortication in the BP burdened bone. Finally effectiveness of non-nitrogen containing first generation BP drugs on their ability to leach out nitrogen containing BP drug thereby counteracting the deleterious bone burden effect of nitrogen BP drugs during OTM should be investigated.

6.6 References

1. Gritsch K, Laroche N, Morgon L, Al-Hity R, Vico L, Colon P, Grosogeat B. A systematic review of methods for tissue analysis in animal studies on orthodontic mini-implants. *Orthod Craniofac Res.* 2012;15:135-47.
2. Ren Y, Maltha JC, Kuijpers-Jagtman AM. The rat as a model for orthodontic tooth movement- a critical review and a proposed solution. *Eur J Orthod.* 2004;26(5):483-90.
3. King GJ, Keeling SD, McCoy EA, Ward TH. Measuring dental drift and orthodontic tooth movement in response to various initial forces in adult rats. *Am J Orthod Dentofacial Orthop.* 1991 May;99(5):456-65.
4. Keeling SD, King GJ, McCoy EA, Valdez M. Serum and alveolar bone phosphatase changes reflect bone turnover during orthodontic tooth movement. *Am J Orthod Dentofacial Orthop.* 1993 Apr;103(4):320-6.
5. Gu G, Lemery SA, King GJ. Effect of appliance reactivation after decay of initial activation on osteoclasts, tooth movement, and root resorption. *Angle Orthod.* 1999 Dec;69(6):515-22.
6. Ren Y, Maltha JC, Kuijpers-Jagtman AM. Optimum force magnitude for orthodontic tooth movement: a systematic literature review. *Angle Orthod.* 2003 Feb;73(1):86-92.
7. Gonzales C, Hotokezaka H, Yoshimatsu M, Yozgatian JH, Darendeliler MA, Yoshida N. Force magnitude and duration effects on amount of tooth movement and root resorption in the rat molar. *Angle Orthod.* 2008;78:502-509.
8. Dunn MD, Park CH, Kostenuik PJ, Kapila S, Giannobile WV. Local delivery of osteoprotegerin inhibits mechanically mediated bone modeling in orthodontic tooth movement. *Bone.* 2007;41:446-455.

9. Drevensek M, Volk J, Sprogar S, Drevensek G. Orthodontic force decreases the eruption rate of rat incisors. *Eur J Orthod.* 2009;31:46-50.
10. Kirschneck C, Proff P, Fanghaenel J, Behr M, Wahlmann U, Roemer P. Differentiated analysis of orthodontic tooth movement in rats with an improved rat model and three-dimensional imaging. *Annals of Anatomy.* 2013;195:539-53.
11. Cuoghi OA, Tondelli PM, Sonoda CK, Aiello CA, de Mendonca MR, Costa SC. Induction of ankyloses in the incisor for orthodontic tooth movement in rats. *Dental Traumatol.* 2014 Apr;30(2):112-7.
12. Miyawaki S, Koyama I, Inoue M, Mishima K, Sugahara T, Takano-Yamamoto T. Factors associated with the stability of titanium screws placed in the posterior region for orthodontic anchorage. *Am J Orthod Dentofacial Orthop.* 2003;124:373-378.
13. Dalessandri D, Salgarello S, Dalessandri M, Lazzaroni E, Piancino M, Paganelli C, Maiorana C, Santoro F. Determinants for success rates of Temporary skeletal anchorage devices in orthodontics: a meta-analysis (n > 50). *Eur J Orthod.* 2014 Jun;36(3):303-13. doi: 10.1093/ejo/cjt049. Epub 2013 Jul 20.
14. Krishnan V, Davidovitch Z. On a path to unfolding the biological mechanisms of orthodontic tooth movement. *J Dent Res* 2009;88:597-608.
15. Verna C, Dalstra M, Melsen B. The rate and the type of orthodontic tooth movement is influenced by bone turnover in a rat model. *Eur J Orthod.* 2000;22(4):343-52.

16. Bartzela T, Türp JC, Motschall E, Maltha JC. Medication effects on the rate of orthodontic tooth movement: a systematic literature review. *Am J Orthod Dentofacial Orthop.* 2009;135(1):16-26.
17. Roelofs AJ, Thompson K, Ebetino FH, Rogers MJ, Coxon FP. Bisphosphonates: molecular mechanisms of action and effects on bone cells, monocytes and macrophages. *Curr Pharm Des.* 2010;16(27):2950-60.
18. Allen MR, Ruggiero SL. A review of pharmacological agents and oral bone health: how osteonecrosis of the jaw has affected the field. *Int J Oral Maxillofac Implants.* 2014;29(1):e45-57.
19. Iglesias-Linares A, Yáñez-Vico RM, Solano-Reina E, Torres-Lagares D, González Moles MA. Influence of bisphosphonates in orthodontic therapy: Systematic review. *J Dent.* 2010 Aug;38(8):603-11. doi: 10.1016/j.jdent.2010.05.012. Epub 2010 Jun 8. Review.
20. Venkataramana V, Chidambaram S, Reddy BV, Goud EV, Arafath M, Krishnan S. Impact of Bisphosphonate on Orthodontic tooth movement and osteoclastic count: An Animal Study. *J Int Oral Health.* 2014 Apr;6(2):1-8. Epub 2014 Apr 26.
21. Hashimoto M, Hotokezaka H, Sirisoontorn I, Nakano T, Arita K, Tanaka M, Yoshida N. The effect of bone morphometric changes on orthodontic tooth movement in an osteoporotic animal model. *Angle Orthod.* 2013 Sep;83(5):766-73. doi: 10.2319/111312-869.1. Epub 2013 Feb 27.
22. Sirisoontorn I, Hotokezaka H, Hashimoto M, Gonzales C, Luppapanornlarp S, Darendeliler MA, Yoshida N. Orthodontic tooth movement and root resorption in ovariectomized rats treated

- by systemic administration of zoledronic acid. *Am J Orthod Dentofacial Orthop.* 2012 May;141(5):563-73. doi: 10.1016/j.ajodo.2011.11.016.
23. Karras JC, Miller JR, Hodges JS, Beyer JP, Larson BE. Effect of alendronate on orthodontic tooth movement in rats. *Am J Orthod Dentofacial Orthop* 2009;136:843-7.
24. Panahifar A, Maksymowych WP, Doschak MR. Potential mechanism of alendronate inhibition of osteophyte formation in the rat model of post-traumatic osteoarthritis: evaluation of elemental strontium as a molecular tracer of bone formation. *Osteoarthritis Cartilage* 2012;20:694-702.
25. Iino S, Sakoda S, Ito G, Nishimori T, Ikeda T, Miyawaki S. Acceleration of orthodontic tooth movement by alveolar corticotomy in the dog. *Am J Orthod Dentofacial Orthop.* 2007;131(4):448.e1-8.
26. Wang L, Lee W, Lei DL, Liu YP, Yamashita DD, Yen SL. Tissue responses in corticotomy- and osteotomy-assisted tooth movements in rats: histology and immunostaining. *Am J Orthod Dentofacial Orthop.* 2009;136(6):770.e1-11.
27. Hassan AH, Al-Fraidi AA, Al-Saeed SH. Corticotomy-assisted orthodontic treatment: review. *Open Dent J.* 2010;4:159-64
28. Baloul SS, Gerstenfeld LC, Morgan EF, Carvalho RS, Van Dyke TE, Kantarci A. Mechanism of action and morphologic changes in the alveolar bone in response to selective alveolar decortication-facilitated tooth movement. *Am J Orthod Dentofacial Orthop.* 2011;139(4 Suppl):S83-101.

29. Cano J, Campo J, Bonilla E, Colmenero C. Corticotomy-assisted orthodontics. *J Clin Exp Dent.* 2012;4(1):e54-9.
30. Cruz DR, Kohara EK, Ribeiro MS, Wetter NU. Effects of low-intensity laser therapy on the orthodontic movement velocity of human teeth: a preliminary study. *Lasers Surg Med.* 2004;35:117-120.
31. Yamaguchi M, Hayashi M, Fujita S. Low-energy laser irradiation facilitates the velocity of tooth movement and the expressions of matrix metalloproteinase-9, cathepsin K, and alpha(v) beta(3) integrin in rats. *Eur J Orthod.* 2010;32:131-139.
32. Nishimura M, Chiba M, Ohashi T. Periodontal tissue activation by vibration: Intermittent stimulation by resonance vibration accelerates experimental tooth movement in rats. *Am J Orthod Dentofacial Orthop.* 2008;133:572-583.
33. Showkatbakhsh R, Jamilian A, Showkatbakhsh M. The effect of pulsed electromagnetic fields on the acceleration of tooth movement. *World J Orthod.* 2011;11:e52-e56.
34. Kim DH, Park YG, Kang SG. The effects of electrical current from a micro-electrical device on tooth movement. *Korean J Orthod.* 2008;38:337-346.
35. Liou EJ, Huang CS. Rapid canine retraction through distraction of the periodontal ligament. *Am J Orthod Dentofacial Orthop.* 1998;114:372-82.
36. Sayin S, Bengi AO, Gurton AU, Ortakoglu K. Rapid canine distalization using distraction of the periodontal ligament. a preliminary clinical validation of the original technique. *Angle Orthod.* 2004;74:304-315.

37. Iseri H, Kisanisci R, Bzizi N, Tuz H. Rapid canine retraction and orthodontic treatment with dentoalveolar distraction osteogenesis. *Am J Orthod Dentofacial Orthop.* 2005;127:533-541.
38. Iglesias-Linares A, Moreno-Fernandez AM, Yañez-Vico R, Mendoza-Mendoza A, Gonzalez-Moles M, Solano-Reina E. The use of gene therapy vs. corticotomy surgery in accelerating orthodontic tooth movement. *Orthod Craniofac Res.* 2001;14(3):138-48.
39. Kanzaki H, Chiba M, Arai K, Takahashi I, Haruyama N, Nishimura M, Mitani H. Local RANKL gene transfer to the periodontal tissues accelerates orthodontic tooth movement. *Gene Ther.* 2006;13(8):678-85.
40. Long H, Pyakurel U, Wang Y, Liao L, Zhou Y, Lai W. Interventions for accelerating orthodontic tooth movement. *Angle Orthod.* 2013;83(1):164-171.
41. Sebaoun JD, Kantarci A, Turner JW, Carvalho RS, Van Dyke TE, Ferguson DJ. Modeling of trabecular bone and lamina dura following selective alveolar decortication in rats. *J Periodontol.* 2008;79(9):1679-88.
42. Aboul-Ela SM, El-Beialy AR, El-Sayed KM, Selim EM, El-Mangoury NH, Mostafa YA. Miniscrew implant-supported canine retraction with and without corticotomy facilitated orthodontics. *Am J Orthod Dentofacial Orthop.* 2011;139:252-259.
43. Fischer TJ. Orthodontic treatment acceleration with corticotomy-assisted exposure of palatally impacted canines. *Angle Orthod.* 2007;77:417-420.

Bibliography:

1. Aboul-Ela SM, El-Beialy AR, El-Sayed KM, Selim EM, El-Mangoury NH, Mostafa YA. Miniscrew implant-supported canine retraction with and without corticotomy facilitated orthodontics. *Am J Orthod Dentofacial Orthop.* 2011;139:252-259.
2. Abrahamsen B. Adverse effects of bisphosphonates. *Calcif Tissue Int* 2010;86:421-35.
3. Abrahamsen B. Bisphosphonate adverse effects, lessons from large databases. *Curr Opin Rheumatol.* 2010;22(4):404-9.
4. Abrahamsen B, Vestergaard P, Rud B, Barenholdt O, Jensen JE, Nielsen SP et al. Ten-year absolute risk of osteoporotic fractures according to BMD T score at menopause: the Danish Osteoporosis Prevention Study. *J Bone Miner Res* 2006;21:796-800.
5. Abtahi J, Agholme F, Sandberg O, Aspenberg P. Bisphosphonate-induced osteonecrosis of the jaw in a rat model arises first after the bone has become exposed. No primary necrosis in unexposed bone. *J Oral Pathol Med* 2012;41:494-499.
6. Adachi H, Igarashi K, Mitani H, Shinoda H. Effects of topical administration of a bisphosphonate (risedronate) on orthodontic tooth movements in rats. *J Dent Res* 1994;73:1478-1486.
7. Aghaloo TL, Kang B, Sung EC, Shoff M, Ronconi M, Gotcher JE, Bezouglaia O, Dry SM, Tetradis S. Periodontal Disease and Bisphosphonate Induce Osteonecrosis of the Jaws in the Rat. *J Bone Miner Res.* 2011;26(8):1871-82.
8. Alatli I, Hellsing E, Hammarstrom L. Orthodontically induced root resorption in rat molars after 1-hydroxyethylidene-1,1-bisphosphonate injection. *Acta Odontol Scand* 1996;54:102-108.

9. Ali-Erdem M, Burak-Cankaya A, Cemil-Isler S et al. Extraction socket healing in rats treated with bisphosphonate: animal model for bisphosphonate related osteonecrosis of jaws in multiple myeloma patients. *Med Oral Patol Oral Cir Bucal* 2011;16:e879-883.
10. Allen MR, Ruggiero SL. A review of pharmacological agents and oral bone health: how osteonecrosis of the jaw has affected the field. *Int J Oral Maxillofac Implants*. 2014;29(1):e45-57.
11. Allen MR, Burr DB. The pathogenesis of bisphosphonate-related osteonecrosis of the jaw: so many hypotheses, so few data. *J Oral Maxillofac Surg*. 2009;67(5 Suppl):61-70.
12. Allen M and Burr D. Mandible matrix necrosis in beagle dogs following 3 years of daily oral bisphosphonate treatment. *J Oral Maxillofac Surg* 2008;66:987-994.
13. Allen MR, Burr DB. Changes in vertebral strength-density and energy absorption-density relationships following bisphosphonate treatment in beagle dogs. *Osteoporos Int*. 2008; Jan19(1):95-9.
14. American Association of Oral and Maxillofacial Surgeons position paper on bisphosphonate-related osteonecrosis of the jaws. *J Oral Maxillofac Surg* 2007;65:369-376.
15. Assuncao WG, Gomes EA, Barao VA, de Sousa EA. Stress analysis in simulation models with or without implant threads representation. *Int J Oral Maxillofac Implants* 2009;24:1040-1044.
16. Baloul SS, Gerstenfeld LC, Morgan EF, Carvalho RS, Van Dyke TE, Kantarci A. Mechanism of action and morphologic changes in the alveolar bone in response to selective alveolar decortication-facilitated tooth movement. *Am J Orthod Dentofacial Orthop*. 2011;139(4 Suppl):S83-101.

17. Bamias A, Kastritis E, Barnia C et al. ONJ in cancer after treatment with bisphosphonates: incidence and risk factors. *J Clin Oncol* 2005;23:8580-87.
18. Bartzela T, Türp JC, Motschall E, Maltha JC. Medication effects on the rate of orthodontic tooth movement: a systematic literature review. *Am J Orthod Dentofacial Orthop.* 2009;135(1):16-26.
19. Bernhart T, Freudenthaler J, Dörtbudak O, Bantleon HP, Watzek G. Short epithetic TSADs for orthodontic anchorage in the paramedian region of the palate. A clinical study. *Clin Oral TSADs Res.* 2001;12:624-631.
20. Biasotto M, Chiandussi S, Zacchigna S et al. A novel animal model to study non-spontaneous bisphosphonate osteonecrosis of the jaw. *J Oral Pathol Med* 2010; 39:390-96.
21. Black DM, Cummings SR, Karpf DB, Cauley JA, Thompson DE, Nevitt MC, et al. Randomised trial of effect of alendronate on risk of fracture in women with existing vertebral fractures. Fracture Intervention Trial Research Group. *Lancet* 1996;348:1535-41.
22. Boonyapakorn T, Schirmer I, Reichart PA, Sturm I, Massenkeil G. Bisphosphonate-induced osteonecrosis of the jaws: prospective study of 80 patients with multiple myeloma and other malignancies. *Oral Oncol* 2008;44:857-869.
23. Brooks PJ, Nilforoushan D, Manolson MF, Simmons CA, Gong SG. Molecular markers of early orthodontic tooth movement. *Angle Orthod* 2009;79:1108-1113.
24. Buttke TM, Proffit WR. Referring adult patients for orthodontic treatment. *J Am Dent Assoc* 1999;130:73-79.

25. Campbell GM, Bernhardt R, Scharnweber D, Boyd SK. The bone architecture is enhanced with combined PTH and alendronate treatment compared to monotherapy while maintaining the state of surface mineralization in the OVX rat. *Bone* 2011;49(2):225-232.
26. Cano J, Campo J, Bonilla E, Colmenero C. Corticotomy-assisted orthodontics. *J Clin Exp Dent*. 2012;4(1):e54-9.
27. Casez P, Uebelhart B, Gaspoz JM, Ferrari S, Louis-Simonet M, Rizzoli R. Targeted education improves the very low recognition of vertebral fractures and osteoporosis management by general internists. *Osteoporos Int* 2006;17:965-970.
28. Cedro MK, Moles DR, Hodges SJ. Adult orthodontics--who's doing what? *J Orthod*;37:107-117.
29. Chamizo Carmona E, Gallego Flores A, Loza Santamaría E, Herrero Olea A, Rosario Lozano MP Systematic literature review of bisphosphonates and osteonecrosis of the jaw in patients with osteoporosis. *Reumatol Clin*. 2013 May-Jun;9(3):172-7. doi: 10.1016/j.reuma.2012.05.005. Epub 2012 Jul 10. Review. English, Spanish.
30. Chavassieux P, E. Seeman, P.D. Delmas. Insights into material and structural basis of bone fragility from diseases associated with fractures: how determinants of the biomechanical properties of bone are compromised by disease. *Endocr Rev* 2007;28:151–164.
31. Cheng SJ, Tseng IY, Lee JJ, Kok SH. A prospective study of the risk factors associated with failure of mini-TSADs used for orthodontic anchorage. *Int J Oral Maxillofac TSADs*. 2004;19:100-106.

32. Christiansen C, Tanko LB, Warming L, Moelgaard A, Christgau S, Qvist P et al. Dose dependent effects on bone resorption and formation of intermittently administered intravenous ibandronate. *Osteoporos Int* 2003;14:609-613.
33. Cohen HV. Bisphosphonate-associated osteonecrosis of the jaw: patient care considerations: overview for the orthopaedic nursing healthcare professional. *Orthop Nurs* 2010;29:176-80.
34. Costa A, Raffainl M, Melsen B. Miniscrews as orthodontic anchorage: a preliminary report. *Int J Adult Orthodon Orthognath Surg* 1998;13:201-209.
35. Coxon FP, Thompson K, Rogers MJ. Recent advances in understanding the mechanism of action of bisphosphonates. *Curr Opin Pharmacol* 2006;6:307-312.
36. Crismani AG, Bertl MH, Celar AG, Bantleon HP, Burstone CJ. Miniscrews in orthodontic treatment: review and analysis of published clinical trials. *Am J Orthod Dentofacial Orthop*. 2010 Jan;137(1):108-13.
37. Cruz DR, Kohara EK, Ribeiro MS, Wetter NU. Effects of low-intensity laser therapy on the orthodontic movement velocity of human teeth: a preliminary study. *Lasers Surg Med*. 2004;35:117-120.
38. Cummings SR, Black DM, Thompson DE, Applegate WB, Barrett-Connor E, Musliner TA, et al. Effect of alendronate on risk of fracture in women with low bone density but without vertebral fractures: results from the Fracture Intervention Trial. *JAMA* 1998;280:2077-82.
39. Cuoghi OA, Tondelli PM, Sonoda CK, Aiello CA, de Mendonca MR, Costa SC. Induction of ankyloses in the incisor for orthodontic tooth movement in rats. *Dental Traumatol*. 2014 Apr;30(2):112-7.

40. Dalessandri D, Salgarello S, Dalessandri M, Lazzaroni E, Piancino M, Paganelli C, Maiorana C, Santoro F. Determinants for success rates of Temporary skeletal anchorage devices in orthodontics: a meta-analysis. *Eur J Orthod*. 2014 Jun;36(3):303-13. doi: 10.1093/ejo/cjt049. Epub 2013 Jul 20.
41. DiPiro JT[Ed] TR, Yee, GC, Matzke GR, Wells BG, Posey LM. *Pharmacotherapy: A Pathophysiologic Approach*, 6th edition. (McGraw Hill, Toronto, 1999). 1999.
42. Dixon RB, Tricker ND, Garetto LP. Bone turnover in elderly canine mandible and tibia. *J Dent Res* 1997;76:336.
43. Drevensek M, Volk J, Sprogar S, Drevensek G. Orthodontic force decreases the eruption rate of rat incisors. *Eur J Orthod* 2009;31:46-50.
44. Duker J. Experimental animal research into segmental alveolar movement after corticotomy. *J Maxillofac Surg*. 1975;3:81-84.
45. Dunn MD, Park CH, Kostenuik PJ, Kapila S, Giannobile WV. Local delivery of osteoprotegerin inhibits mechanically mediated bone modeling in orthodontic tooth movement. *Bone* 2007;41:446-455.
46. Durie BG, Katz M, Crowley J. Osteonecrosis of the jaw and bisphosphonates. *N Engl J Med*. 2005;353(1):99-102.
47. Egan KP, Brenna TA, Pignolo RJ. Bone histomorphometry using free and commonly available software. *Histopathology*. 2012;61(6):1168-73.
48. Fedele S, Porter SR, D'Aiuto F, Aljohani S, Vescovi P, Manfredi M, et al. Nonexposed variant of bisphosphonate-associated osteonecrosis of the jaw: a case series. *Am J Med* 2010;123:1060-4.

49. Fischer TJ. Orthodontic treatment acceleration with corticotomy-assisted exposure of palatally impacted canines. *Angle Orthod.* 2007;77:417-420.
50. Freudenthaler JW, Haas R, Bantleon HP. Bicortical titanium screws for critical orthodontic anchorage in the mandible: a preliminary report on clinical applications. *Clin Oral TSADs Res.* 2001;12:358-363.
51. Fritton J, M.B. Schaffler. Bone quality. R. Marcus, D. Feldman, D. Nelson, C. Rosen (Eds.), *Osteoporosis* (3rd ed.), Academic Press, New York, NY 2007;625–641.
52. Frost HM. Wolff's Law and bone's structural adaptations to mechanical usage: an overview for clinicians. *Angle Orthod.* 1994;64(3):175-88. Review.
53. Frost HM. The regional acceleratory phenomenon: a review. *Henry Ford Hosp Med J.* 1983;31(1):3-9.
54. Fujita S, Yamaguchi M, Utsunomiya T, Yamamoto H, Kasai K. Low-energy laser stimulates tooth movement velocity via expression of RANK and RANKL. *Orthod Craniofac Res* 2008;11:143-155.
55. Galsworthy TD. Osteoporosis: statistics, intervention, and prevention. *Ann N Y Acad Sci* 1994;736:158-164.
56. Geng JP, Tan KB, Liu GR. Application of finite element analysis in implant dentistry: a review of the literature. *J Prosthet Dent* 2001;85:585-598.
57. Geusens P, Hochberg MC, van der Voort DJ, Pols H, van der Klift M, Siris E et al. Performance of risk indices for identifying low bone density in postmenopausal women. *Mayo Clin Proc* 2002;77:629-637.

58. Gonzales C, Hotokezaka H, Yoshimatsu M, Yozgatian JH, Darendeliler MA, Yoshida N. Force magnitude and duration effects on amount of tooth movement and root resorption in the rat molar. *Angle Orthod* 2008;78:502-509.
59. Gotcher JE, Jee WS. The progress of the peridontal syndrome in the rice rat II. The effects of a diphosphonate on the periodontium. *J Periodontal Res* 1981;16:441-455.
60. Gritsch K, Laroche N, Morgon L, Al-Hity R, Vico L, Colon P, Grosogeat B. A systematic review of methods for tissue analysis in animal studies on orthodontic mini-implants. *Orthod Craniofac Res*. 2012;15:135-47.
61. Gu G, Lemery SA, King GJ. Effect of appliance reactivation after decay of initial activation on osteoclasts, tooth movement, and root resorption. *Angle Orthod*. 1999 Dec;69(6):515-22.
62. Hanley DA, Cranney A, Jones G, Whiting SJ, Leslie WD, Cole DE et al. Vitamin D in adult health and disease: a review and guideline statement from Osteoporosis Canada. *CMAJ* 2010;182:E610-618.
63. Hashimoto M, Hotokezaka H, Sirisoontorn I, Nakano T, Arita K, Tanaka M, Yoshida N. The effect of bone morphometric changes on orthodontic tooth movement in an osteoporotic animal model. *Angle Orthod*. 2013 Sep;83(5):766-73. doi: 10.2319/111312-869.1. Epub 2013 Feb 27.
64. Hassan AH, Al-Fraidi AA, Al-Saeed SH. Corticotomy-assisted orthodontic treatment: review. *Open Dent J*. 2010;4:159-64.
65. Hayami T, Pickarski M, Wesolowski GA, McLane J, Bone A, Destefano J, Rodan GA, Duong le T. The role of subchondral bone remodeling in osteoarthritis: reduction of

- cartilage degeneration and prevention of osteophyte formation by alendronate in the rat anterior cruciate ligament transection model. *Arthritis Rheum* 2004;50(4):1193-20630.
66. Hedayati Z, Hashemi SM, Zamiri B, Fattahi HR. Anchorage value of surgical titanium screws in orthodontic tooth movement. *Int J Oral Maxillofac Surg.* 2007 Jul;36(7):588-92.
67. Henneman S, Von den Hoff JW, Maltha JC. Mechanobiology of tooth movement. *Eur J Orthod* 2008;30:299-306.
68. Heymann GC, Tulloch JF. Implantable devices as orthodontic anchorage: a review of current treatment modalities. *J Esthet Restor Dent* 2006;18:68-79; discussion 80.
69. Hoff AO, Toth B, Hu M, Hortobagyi GN, Gagel RF. Epidemiology and risk factors for osteonecrosis of the jaw in cancer patients. *Ann N Y Acad Sci* 2011;1218:47-54.
70. Hoff AO, Toth BB, Altundag K, Johnson MM, Warneke CL, Hu M, Nooka A, Sayegh G, Guarneri V, Desrouleaux K, Cui J, Adamus A, Gagel RF, Hortobagyi GN. Frequency and risk factors associated with osteonecrosis of the jaw in cancer patients treated with intravenous bisphosphonates. *J Bone Miner Res.* 2008;23:826-36.
71. http://www.osteoporosis.ca/index.php/ci_id/8867/la_id/1.htm - Osteoporosis Canada.
72. Igarashi K, Adachi H, Mitani H, Shinoda H. Inhibitory effect of the topical administration of a bisphosphonate (risedronate) on root resorption incident to orthodontic tooth movement in rats. *J Dent Res* 1996;75:1644-1649.
73. Igarashi K, Mitani H, Adachi H, Shinoda H. Anchorage and retentive effects of a bisphosphonate (AHBuBP) on tooth movements in rats. *Am J Orthod Dentofacial Orthop* 1994;106:279-289.

74. Iglesias-Linares A, Yáñez-Vico RM, Solano-Reina E, Torres-Lagares D, González Moles MA. Influence of bisphosphonates in orthodontic therapy: Systematic review. *J Dent.* 2010 Aug;38(8):603-11. doi: 10.1016/j.jdent.2010.05.012. Epub 2010 Jun 8. Review.
75. Iglesias-Linares A, Moreno-Fernandez AM, Yáñez-Vico R, Mendoza-Mendoza A, Gonzalez-Moles M, Solano-Reina E. The use of gene therapy vs. corticotomy surgery in accelerating orthodontic tooth movement. *Orthod Craniofac Res.* 2001;14(3):138-48.
76. Iino S, Sakoda S, Ito G, Nishimori T, Ikeda T, Miyawaki S. Acceleration of orthodontic tooth movement by alveolar corticotomy in the dog. *Am J Orthod Dentofacial Orthop.* 2007;131(4):448.e1-8.
77. IMS Health Incorporated [Internet]. Parsippany, NJ; 2005 [accessed 2012 March 12]. Available from www.imshealth.com.
78. Ing-Lorenzini K, Desmeules J, Plachta O, Suva D, Dayer P, Peter R. Low-energy femoral fractures associated with the long-term use of bisphosphonates: a case series from a Swiss university hospital. *Drug Saf* 2009;32:775-85.
79. Inubushi T, Tanaka E, Rego EB, Ohtani J, Kawazoe A, Tanne K, Miyauchi M, Takata T. Ultrasound stimulation attenuates resorption of tooth root induced by experimental force application. *Bone.* 2013 Apr;53(2):497-506.
80. Iseri H, Kisnisci R, Bzizi N, Tuz H. Rapid canine retraction and orthodontic treatment with dentoalveolar distraction osteogenesis. *Am J Orthod Dentofacial Orthop.* 2005;127:533-541.
81. Kaipatur N, Wu Y, Adeeb S, Stevenson T, Major P, Doschak M. Impact of bisphosphonate drug burden in alveolar bone during orthodontic tooth movement in a rat model: a pilot study. *Am J Orthod Dentofacial Orthop.* 2013;144(4):557-67.

82. Kaipatur N, Wu Y, Adeeb S, Stevenson T, Major P, Doschak M. A novel rat model of orthodontic tooth movement using temporary skeletal anchorage devices: 3D finite element analysis and in vivo validation. *International Journal of Dentistry*. 2014; Article ID 917535, 11 pages. <http://dx.doi.org/10.1155/2014/917535>.
83. Kanis JA, Johnell O, De Laet C, Johansson H, Oden A, Delmas P et al. A meta-analysis of previous fracture and subsequent fracture risk. *Bone* 2004;35:375-382.
84. Kanis JA, Johnell O, Oden A, Dawson A, De Laet C, Jonsson B. Ten year probabilities of osteoporotic fractures according to BMD and diagnostic thresholds. *Osteoporos Int* 2001;12:989-995.
85. Kanis JA, Johnell O, Oden A, Sembo I, Redlund-Johnell I, Dawson A et al. Long-term risk of osteoporotic fracture in Malmo. *Osteoporos Int* 2000;11:669-674.
86. Kanzaki H, Chiba M, Arai K, Takahashi I, Haruyama N, Nishimura M, Mitani H. Local RANKL gene transfer to the periodontal tissues accelerates orthodontic tooth movement. *Gene Ther*. 2006;13(8):678-85.
87. Karras JC, Miller JR, Hodges JS, Beyer JP, Larson BE. Effect of alendronate on orthodontic tooth movement in rats. *Am J Orthod Dentofacial Orthop* 2009;136:843-847.
88. Kawarizadeh A, Bourauel C, Jäger A. Experimental and numerical determination of initial tooth mobility and material properties of the periodontal ligament in rat molar specimens. *Eur J Orthod*. 2003;25:569-578.
89. Keeling SD, King GJ, McCoy EA, Valdez M. Serum and alveolar bone phosphatase changes reflect bone turnover during orthodontic tooth movement. *Am J Orthod Dentofacial Orthop*. 1993 Apr;103(4):320-6.
90. Keim R. Orthodontic practice study, Part I: trends. *J Clin Orthod* 2009;43:625-34.

91. Keles A, Grunes B, Difuria C, Gagari E, Srinivasan V, Darendeliler MA et al. Inhibition of tooth movement by osteoprotegerin vs. pamidronate under conditions of constant orthodontic force. *Eur J Oral Sci* 2007;115:131-136.
92. Khosla S, Burr D, Cauley J et al. Bisphosphonate-associated osteonecrosis of the jaw: report of a task force of the American Society for Bone and Mineral Research. *J Bone Miner Res.* 2007;22(10):1479-91.
93. Kim JM, Kim SJ, Han I, Shin SW, Ryu JJ. A comparison of the implant stability among various implant systems: clinical study. *J Adv Prosthodont.* 2009 Mar;1(1):31-6.
94. Kim DH, Park YG, Kang SG. The effects of electrical current from a micro-electrical device on tooth movement. *Korean J Orthod.* 2008;38:337-346.
95. Kim TW, Yoshida Y, Yokoya K, Sasaki T. An ultrastructural study of the effects of bisphosphonate administration on osteoclastic bone resorption during relapse of experimentally moved rat molars. *Am J Orthod Dentofacial Orthop* 1999;115:645-653.
96. Kimmel DB. Mechanism of action, pharmacokinetic and pharmacodynamic profile, and clinical applications of nitrogen-containing bisphosphonates. *J Dent Res* 2007;86:1022-1033.
97. King GJ, Keeling SD, McCoy EA, Ward TH. Measuring dental drift and orthodontic tooth movement in response to various initial forces in adult rats. *Am J Orthod Dentofacial Orthop.* 1991 May;99(5):456-65.
98. Kirschneck C, Proff P, Fanghaenel J, Behr M, Wahlmann U, Roemer P. Differentiated analysis of orthodontic tooth movement in rats with an improved rat model and three-dimensional imaging. *Annals of Anatomy.* 2013;195:539-53.

99. Klotzbuecher CM, Ross PD, Landsman PB, Abbott TA, 3rd, Berger M. Patients with prior fractures have an increased risk of future fractures: a summary of the literature and statistical synthesis. *J Bone Miner Res* 2000;15:721-739.
100. Köle H. Surgical operations on the alveolar ridge to correct occlusal abnormalities. *Oral Surg Med Pathol.* 1959;12:515-529.
101. Kobayashi Y, Hiraga T, Ueda A et al. Zoledronic acid delays wound healing of the tooth extraction socket, inhibits-oral epithelial cell migration, and promotes proliferation and adhesion of hydroxyapatite of oral bacteria, without causing osteonecrosis of the jaws in mice. *J Bone Miner Metab* 2010;28:165-75.
102. Kraj M, Ryszard P, Stanislaw M et al. The incidence of jaw osteonecrosis in multiple myeloma patients treated with bisphosphonates. *Acta Pol Pharm* 2006;63:450-452.
103. Krishnan V, Davidovitch Z. On a path to unfolding the biological mechanisms of orthodontic tooth movement. *J Dent Res* 2009;88:597-608.
104. Krishnan V, Davidovitch Z. Cellular, molecular, and tissue-level reactions to orthodontic force. *Am J Orthod Dentofacial Orthop* 2006;129:469 e461-432.
105. Krishnan V, Davidovitch Z. The effect of drugs on orthodontic tooth movement. *Orthod Craniofac Res* 2006;9:163-71.
106. Landesberg R, Eisig S, Fennoy I, Siris E. Alternative indications for bisphosphonate therapy. *J Oral Maxillofac Surg* 2009;67(5 Suppl):27-34.
107. Landesberg R et al. Inhibition of oral mucosal cell wound healing by bisphosphonates. *J Oral Maxillofac Surg.* 2008;66:839-847.

108. Lekic P, McCulloch CA. Periodontal ligament cell population: the central role of fibroblasts in creating a unique tissue. *Anat Rec* 1996;245:327-341.
109. Liberman UA, Weiss SR, Broll J, Minne HW, Quan H, Bell NH, et al. Effect of oral alendronate on bone mineral density and the incidence of fractures in postmenopausal osteoporosis. The Alendronate Phase III Osteoporosis Treatment Study Group. *N Engl J Med* 1995;333:1437-43.
110. Lifshitz AB, Muñoz M. Evaluation of the stability of self-drilling mini-implants for maxillary anchorage under immediate loading. *World J Orthod.* 2010 Winter;11(4):352-6.
111. Lindsay R, Silverman SL, Cooper C, Hanley DA, Barton I, Broy SB et al. Risk of new vertebral fracture in the year following a fracture. *JAMA* 2001;285:320-323.
112. Liou EJ, Huang CS. Rapid canine retraction through distraction of the periodontal ligament. *Am J Orthod Dentofacial Orthop.* 1998;114:372-82.
113. Lioubavina-Hack N, Lang NP, Karring T. Significance of primary stability for osseointegration of dental implants. *Clin Oral Implants Res* 2006;17:244-250.
114. Liu L, Igarashi K, Haruyama N, Saeki S, Shinoda H, Mitani H. Effects of local administration of clodronate on orthodontic tooth movement and root resorption in rats. *Eur J Orthod* 2004;26:469-473.
115. Lo JC, O`Ryan FS, Gordon NP et al. Prevalence of osteonecrosis of the jaw in patients with oral bisphosphonate exposure. *J Oral Maxillofac Surg.* 2010;68(2):243-53.
116. Long H, Pyakurel U, Wang Y, Liao L, Zhou Y, Lai W. Interventions for accelerating orthodontic tooth movement. *Angle Orthod.* 2013;83(1):164-171.

117. . López-Jornet P, Camacho-Alonso F, Vicente-Ortega V et al. An experimental study of bisphosphonate-induced jaws osteonecrosis in Sprague-Dawley rats. *J oral Pathol Med* 201;39:697-702.
118. Lotwala RB, Greenlee GM, Ott SM, Hall SH, Huang GJ. Bisphosphonates as a risk factor for adverse orthodontic outcomes. A retrospective cohort study. *Am J Orthod Dentofacial Orthop* 2012;142:625-34.
119. MacLean C, Newberry S, Maglione M, McMahon M, Ranganath V, Suttorp M et al. Systematic review: comparative effectiveness of treatments to prevent fractures in men and women with low bone density or osteoporosis. *Ann Intern Med* 2008;148:197-213.
120. Majumdar SR, Kim N, Colman I, Chahal AM, Raymond G, Jen H et al. Incidental vertebral fractures discovered with chest radiography in the emergency department: prevalence, recognition, and osteoporosis management in a cohort of elderly patients. *Arch Intern Med* 2005;165:905-909.
121. Manolagas SC. Birth and death of bone cells: basic regulatory mechanisms and implications for the pathogenesis and treatment of osteoporosis. *Endocr Rev* 2000;21:115-137.
122. Marino KL, Zakhary I, Abdelsayed RA et al. Development of a rat model of bisphosphonate-related osteonecrosis of the jaw (BRONJ). *J Oral Implantol* 2012;38:511-518.
123. Marx R. Oral & Intravenous Bipshosphonate-Induced Osteonecrosis of the Jaws. Book Chapter. Quintessence Publishing Co.; Chicago:2007.

124. Marx RE, Sawatari Y, Fortin M, Broumand V. Bisphosphonate-induced exposed bone (osteonecrosis/osteopetrosis) of the jaws: risk factors, recognition, prevention and management. *J Oral Maxillofac Surg.* 2005;63(11):1567-75.
125. Masella RS, Meister M. Current concepts in the biology of orthodontic tooth movement. *Am J Orthod Dentofacial Orthop* 2006;129:458-468.
126. Mattila PT, Svanberg MJ, Jämsä T, Knuuttila ML. Improved bone biomechanical properties in xylytol-fed aged rats. *Metabolism.* 2002;51:92-96.
127. Mavrokokki T, Cheng A, Stein B, Goss A. Nature and frequency of bisphosphonate-associated osteonecrosis of the jaws in Australia. *J Oral Maxillofac Surg* 2007;65:415-423.
128. Miller PD, Ward P, Pfister T, Leigh C, Body JJ. Renal tolerability of intermittent intravenous ibandronate treatment for patients with postmenopausal osteoporosis: a review. *Clin Exp Rheumatol* 2008;26:1125-1133.
129. Mimura H. Treatment of severe bimaxillary protrusion with miniscrew anchorage: treatment and complications. *Aust Orthod J* 2008;24:156-163.
130. Miyawaki S, Koyama I, Inoue M, Mishima K, Sugahara T, Takano-Yamamoto T. Factors associated with the stability of titanium screws placed in the posterior region for orthodontic anchorage. *Am J Orthod Dentofacial Orthop* 2003;124:373-378.
131. Mostafa YA, Mohamed Salah Fayed M, Mehanni S, ElBokle NN, Heider AM. Comparisons of corticotomy-facilitated vs standard tooth-movement techniques in dogs with miniscrews as anchor units. *Am J Orthod Dentofacial Orthop.* 2009;136(4):570-7.

132. Murphy KG, Wilcko MT, Wilcko WM, Ferguson DJ. Periodontal accelerated osteogenic orthodontics: a description of the surgical technique. *J Oral Maxillofac Surg.* 2009;67(10):2160-6.
133. Nakamura K, Sahara N, Deguchi T. Temporal changes in the distribution and number of macrophage-lineage cells in the periodontal membrane of the rat molar in response to experimental tooth movement. *Archives of Oral Biology* 2001;46:593-607.
134. Nancollas GH, Tang R, Phipps RJ, Henneman Z, Gulde S, Wu W et al. Novel insights into actions of bisphosphonates on bone: differences in interactions with hydroxyapatite. *Bone* 2006;38:617-627.
135. Nattrass C, Sandy JR. Adult orthodontics – a review. *Br J Orthod.* 1995;22:331-7.
136. Nelson HD, Haney EM, Chou R, Dana T, Fu R, Bougatsos C. screening for Osteoporosis: Systematic Review to Update the 2002 U.S. Preventive Services Task Force Recommendation [Internet]. Rockville (MD): Agency for Healthcare Research and Quality (US); 2010 Jul. Report No.: 10-05145-EF-1. U.S. Preventive Services Task Force Evidence Syntheses, formerly Systematic Evidence Reviews.
137. NIH Consensus Development Panel on Osteoporosis Prevention, Diagnosis, and Therapy, March 7-29, 2000: highlights of the conference. *South Med J* 2001;94:569-573.
138. Nilforoushan D, Manolson MF. Expression of nitric oxide synthases in orthodontic tooth movement. *Angle Orthod* 2009;79:502-508.
139. Nishimura M, Chiba M, Ohashi T. Periodontal tissue activation by vibration: Intermittent stimulation by resonance vibration accelerates experimental tooth movement in rats. *Am J Orthod Dentofacial Orthop.* 2008;133:572-583.

140. Ohmae M, Saito S, Morohashi T, et al. A clinical and histological evaluation of titanium mini-TSADs as anchors for orthodontic intrusion in the beagle dog. *Am J Orthod Dentofacial Orthop.* 2001;119:489-497.
141. Okazaki J, Komasa Y, Sakai D, Kamada A, Ikeo T, Toda I et al. A torque removal study on the primary stability of orthodontic titanium screw mini-implants in the cortical bone of dog femurs. *Int J Oral Maxillofac Surg* 2008;37:647-650.
142. Osteoporosis prevention, diagnosis, and therapy. NIH Consensus Development Panel on Osteoporosis Prevention, Diagnosis, and Therapy. *JAMA* 2001;285:785-795.
143. Panahifar A, Maksymarych WP, Doschak MR. Potential mechanism of alendronate inhibition of osteophyte formation in the rat model of post-traumatic osteophyte: Evaluation of elemental strontium as a molecule tracer of bone formation. *Osteoarthritis Cartilage.* 2012;20:694-702.
144. Papaioannou A, Morin S, Cheung AM, Atkinson S, Brown JP, Feldman S et al. 2010 clinical practice guidelines for the diagnosis and management of osteoporosis in Canada: summary. *CMAJ*;182:1864-1873.
145. Papapoulos SE, Schimmer RC. Changes in bone remodelling and antifracture efficacy of intermittent bisphosphonate therapy: implications from clinical studies with ibandronate. *Postgrad Med J* 2008;84:307-312.
146. Park HS, Jeong SH, Kwon OW. Factors affecting the clinical success of screw implants used as orthodontic anchorage. *Am J Orthod Dentofacial Orthop.* 2006 Jul;130(1):18-25.
147. Park HS, Kyung HM, Sung JH. A simple method of molar uprighting with micro-implant anchorage. *J Clin Orthod* 2002;36:592-596.

148. Paunovich ED, Sadowsky JM, Carter P. The most frequently prescribed medications in the elderly and their impact on dental treatment. *Dent Clin North Am* 1997;41:699-726.
149. Pautke C, Kreutzer K, Weitz J et al. Bisphosphonate related osteonecrosis of the jaw: a minipig large animal model. *Bone* 2012;51:592-99.
150. Pazianas M, Miller P, Blumentals WA, Bernal M, Kothawala P. A review of the literature on osteonecrosis of the jaw in patients with osteoporosis treated with oral bisphosphonates: prevalence, risk factors, and clinical characteristics. *Clin Ther* 2007;29:1548-58.
151. Penolazzi L, Magri E, Lambertini E, Calo G, Cozzani M, Siciliani G et al. Local in vivo administration of a decoy oligonucleotide targeting NF-kappaB induces apoptosis of osteoclasts after application of orthodontic forces to rat teeth. *Int J Mol Med* 2006;18:807-811.
152. Pozzi S, Marcheselli R, Sacchi S et al. Bisphosphonate-associated ONJ: a review of 35 cases and an evaluation of its frequency in multiple myeloma patients. *Leuk Lymphoma* 2007;48:56-64.
153. Reid IR, Bolland MJ, Grey A. Effect of calcium supplementation on hip fractures. *Osteoporos Int* 2008;19:1119-1123.
154. Reitan K. Clinical and histologic observations on tooth movement during and after orthodontic treatment. *Am J Orthod*. 1967;53(10):721-45.
155. Ren A, Lv T, Kang N, Zhao B, Chen Y, Bai D. Rapid orthodontic tooth movement aided by alveolar surgery in beagles. *Am J Orthod Dentofacial Orthop*. 2007;131:61-8.

156. Ren Y, Maltha JC, Kuijpers-Jagtman AM. The rat as a model for orthodontic tooth movement--a critical review and a proposed solution. *Eur J Orthod* 2004;26:483-490.
157. Ren Y, Maltha JC, Kuijpers-Jagtman AM. Optimum force magnitude for orthodontic tooth movement: a systematic literature review. *Angle Orthod.* 2003 Feb;73(1):86-92.
158. Roberts WE, Marshall KJ, Mozsary PG. Rigid endosseous TSAD utilized as anchorage to protract molars and close an atrophic extraction site. *Angle Orthod.* 1990;60:135-152.
159. Rodan GA, Martin TJ. Therapeutic approaches to bone diseases. *Science* 2000;289:1508-1514.
160. Rodan GA. Mechanisms of action of bisphosphonates. *Annu Rev Pharmacol Toxicol* 1998;38:375-388.
161. Rody WJ, Jr., King GJ, Gu G. Osteoclast recruitment to sites of compression in orthodontic tooth movement. *Am J Orthod Dentofacial Orthop* 2001;120:477-489.
162. Roelofs AJ, Thompson K, Ebetino FH, Rogers MJ, Coxon FP. Bisphosphonates: molecular mechanisms of action and effects on bone cells, monocytes and macrophages. *Curr Pharm Des.* 2010;16(27):2950-60.
163. Rogers MJ, Gordon S, Benford HL, Coxon FP, Luckman SP, Monkkonen J. Cellular and molecular mechanisms of action of bisphosphonates. *Cancer* 2000;88(12suppl):2961-78.

164. Ross PD, Genant HK, Davis JW, Miller PD, Wasnich RD. Predicting vertebral fracture incidence from prevalent fractures and bone density among non-black, osteoporotic women. *Osteoporos Int* 1993;3:120-126.
165. Ruggiero SL. Bisphosphonate-related osteonecrosis of the jaw: an overview. *Ann N Y Acad Sci.* 2011 Feb;1218:38-46. doi: 10.1111/j.1749-6632.2010.05768.x. Epub 2010 Sep 28. Review.
166. Ruggiero S. American Association of Oral and Maxillofacial surgeons position paper on bisphosphonate-related osteonecrosis of the jaws: 2009 update. *J Oral Maxillofac Surg* 2009;67:2-12.
167. Ruggiero S, Fantasia J, Carlson E. Bisphosphonate-related osteonecrosis of the jaw: background and guidelines for diagnosis, staging and management. *Oral Surg Oral Med Oral Pathol Oral Radiol Endod* 2006;102:433-441.
168. Ruggiero SL, Mehrotra B, Rosenberg TJ, Engroff SL. Osteonecrosis of the jaws associated with the use of bisphosphonates: a review of 63 cases. *J Oral Maxillofac Surg.* 2004;62(5):527-534.
169. Russell RG, Watts NB, Ebtino FH, Rogers MJ. Mechanisms of action of bisphosphonates: similarities and differences and their potential influence on clinical efficacy. *Osteoporos Int* 2008;19:733-759.
170. Russell RG. Bisphosphonates: mode of action and pharmacology. *Pediatrics* 2007;119 Suppl 2:S150-62.
171. Russell RG, Rogers MJ. Bisphosphonates: from the laboratory to the clinic and back again. *Bone* 1999;25:97-106.

172. Sarasquete ME, Garcia-Sanz R, Marin L, Alcoceba M, Chillon MC, Balanzategui A et al. Bisphosphonate-related osteonecrosis of the jaw is associated with polymorphisms of the cytochrome P450 CYP2C8 in multiple myeloma: a genome-wide single nucleotide polymorphism analysis. *Blood* 2008;112:2709-2712.
173. Sato Y, Sakai H, Kobayashi Y, Shibasaki Y, Sasaki T. Bisphosphonate administration alters subcellular localization of vacuolar-type H(+)-ATPase and cathepsin K in osteoclasts during experimental movement of rat molars. *Anat Rec* 2000;260:72-80.
174. Sayin S, Bengi AO, Gurton AU, Ortakoglu K. Rapid canine distalization using distraction of the periodontal ligament. a preliminary clinical validation of the original technique. *Angle Orthod.* 2004;74:304-315.
175. Schätzle M, Männchen R, Zwahlen M, Lang NP. Survival and failure rates of orthodontic Temporary skeletal anchorage devices: a systematic review. *Clin Oral Implants Res.* 2009 Dec;20(12):1351-9.
176. Schilling T, Müller M, Minne HW, Ziegler R. Influence of inflammation-mediated osteopenia on the regional acceleratory phenomenon and the systemic acceleratory phenomenon during healing of a bone defect in the rat. *Calcif Tissue Int.* 1998;63(2):160-6.
177. Sebaoun JD, Kantarci A, Turner JW, Carvalho RS, Van Dyke TE, Ferguson DJ. Modeling of trabecular bone and lamina dura following selective alveolar decortication in rats. *J Peridontol.* 2008;79(9):1679-88.
178. Senel FC, KadiogluDuman M, Muci E et al. Jaw bone changes in rats after treatment with zoledronate and pamidronate. *Oral Surg Oral Med Oral Pathol Oral Radiol Endod* 2010;109:385-91.

179. Seres L, Kocsis A. Closure of severe skeletal anterior open bite with zygomatic anchorage. *J Craniofac Surg* 2009;20:478-482.
180. Showkatbakhsh R, Jamilian A, Showkatbakhsh M. The effect of pulsed electromagnetic fields on the acceleration of tooth movement. *World J Orthod*. 2011;11:e52-e56.
181. Sirisoontorn I, Hotokezaka H, Hashimoto M, Gonzales C, Luppapornlarp S, Darendeliler MA, Yoshida N. Orthodontic tooth movement and root resorption in ovariectomized rats treated by systemic administration of zoledronic acid. *Am J Orthod Dentofacial Orthop*. 2012 May;141(5):563-73. doi: 10.1016/j.ajodo.2011.11.016.
182. Skeggs RM, Benson PE, Dyer F. Reinforcement of anchorage during orthodontic brace treatment with TSADs or other surgical methods. *Cochrane Database Syst Rev*. 2007:CD005098.
183. Sonis ST, Watkins BA, Lyng GD, Lerman MA, Anderseon KC. Bony changes in the jaws of rats treated with zoledronic acid and dexamethasone before dental extractions mimic bisphosphonate-related osteonecrosis in cancer patients. 2009;45:164-172.
184. Sturtridge W, Lentle B, Hanley DA. Prevention and management of osteoporosis: consensus statements from the Scientific Advisory Board of the Osteoporosis Society of Canada. 2. The use of bone density measurement in the diagnosis and management of osteoporosis. *CMAJ* 1996;155:924-929.
185. Tang BM, Eslick GD, Nowson C, Smith C, Bensoussan A. Use of calcium or calcium in combination with vitamin D supplementation to prevent fractures and bone loss in people aged 50 years and older: a meta-analysis. *Lancet* 2007;370:657-666.

186. Tomizuka R, Shimizu Y, Kanetaka H, Suzuki A, Urayama S, Kikuchi M et al. Histological evaluation of the effects of initially light and gradually increasing force on orthodontic tooth movement. *Angle Orthod* 2007;77:410-416.
187. Tosi P, Zamagni E, Cangini D. ONJs in newly diagnosed multiple myeloma patients treated with zoledronic acid and thalidomide-dexamethasone. *Blood* 2006;108:3951-62.
188. Vatsa A, Smit TH, Klein-Nulend J. Extracellular NO signalling from a mechanically stimulated osteocyte. *J Biomech* 2007;40 Suppl 1:S89-95.
189. Venkataramana V, Chidambaram S, Reddy BV, Goud EV, Arafath M, Krishnan S. Impact of Bisphosphonate on Orthodontic tooth movement and osteoclastic count: An Animal Study. *J Int Oral Health*. 2014 Apr;6(2):1-8. Epub 2014 Apr 26.
190. Verna C, Dalstra M, Melsen B. The rate and the type of orthodontic tooth movement is influenced by bone turnover in a rat model. *Eur J Orthod*. 2000;22(4):343-52.
191. Viera-Negron YE, Ruan WH, Winger JN, Hou X, Sharawy MM, Borke JL. Effect of ovariectomy and alendronate on implant osseointegration in rat maxillary bone. *J Oral Implantol* 2008;34:76-82.
192. Walter C, Al-Nawas B, Grötz KA, Thomas C, Thüroff JW, Zinser V, Gamm H, Beck J, Wagner W. Prevalence and risk factors of bisphosphonate-associated osteonecrosis of the jaw in prostate cancer patients with advanced disease treated with zoledronate. *Eur Urol*. 2008;54(5):1066-72.

193. Wang L, Lee W, Lei DL, Liu YP, Yamashita DD, Yen SL. Tissue responses in corticotomy- and osteotomy-assisted tooth movements in rats: histology and immunostaining. *Am J Orthod Dentofacial Orthop.* 2009;136(6):770.e1-11.
194. Wawrzinek C, Sommer T, Fischer-Brandies H. Microdamage in cortical bone due to the overtightening of orthodontic microscrews. *J Orofac Orthop* 2008;69:121-134.
195. Weinstein AM, Klawitter JJ, Anand SC, Schuessler R. Stress analysis of porous rooted dental implants. *J Dent Res* 1976;55:772-777.
196. Wilcko W, Wilcko MT. Accelerating tooth movement: the case for corticotomy-induced orthodontics. *Am J Orthod Dentofacial Orthop.* 2013;144(1):4-12.
197. Wilcko MT, Wilcko WM, Pulver JJ, Bissada NF, Bouquot JE. Accelerated osteogenic orthodontics technique: a 1-stage surgically facilitated rapid orthodontic technique with alveolar augmentation. *J Oral Maxillofac Surg.* 2009;67(10):2149-59.
198. Wilmes B, Su YY, Sadigh L, Drescher D. Pre-drilling force and insertion torques during orthodontic mini-implant insertion in relation to root contact. *J Orofac Orthop* 2008;69:51-58.
199. Wilmes B, Su YY, Drescher D. Insertion angle impact on primary stability of orthodontic mini-implants. *Angle Orthod* 2008;78:1065-1070.
200. Wilmes B, Rademacher C, Olthoff G, Drescher D. Parameters affecting primary stability of orthodontic mini-implants. *J Orofac Orthop* 2006;67:162-174.
201. Wise GE, King GJ. Mechanisms of tooth eruption and orthodontic tooth movement. *J Dent Res* 2008;87:414-434.

202. Yamaguchi M, Hayashi M, Fujita S. Low-energy laser irradiation facilitates the velocity of tooth movement and the expressions of matrix metalloproteinase-9, cathepsin K, and alpha(v) beta(3) integrin in rats. *Eur J Orthod.* 2010;32:131-139.
203. Yamaguchi M. RANK/RANKL/OPG during orthodontic tooth movement. *Orthod Craniofac Res* 2009;12:113-119.
204. Ylikontiola L, Sundqvist K, Sandor GK, Tormala P, Ashammakhi N. Self-reinforced bioresorbable poly-L/DL-lactide [SR-P(L/DL)LA] 70/30 miniplates and miniscrews are reliable for fixation of anterior mandibular fractures: a pilot study. *Oral Surg Oral Med Oral Pathol Oral Radiol Endod* 2004;97:312-317.
205. Zahrowski JJ. Optimizing orthodontic treatment in patients taking bisphosphonates for osteoporosis. *Am J Orthod Dentofacial Orthop* 2009;135:361-74.
206. Zervas K, Verrou E, Telejoudis Z, Vahtsevanos K, Banti A, Mihou D, Krikelis D, Terpos E. Incidence, risk factors and management of osteonecrosis of the jaw in patients with multiple myeloma: a single-centre experience in 303 patients. *Br J Haematol.* 2006;134(6):620-3.